The Seoul Journal of Medicine
Vol. 31, No. 1: 11-18, March 1990

Pharmacokinetics of Amitriptyline Demethylation; A Crossover Study with Single Doses of Amitriptyline and Nortriptyline[1]

In-Jin Jang, Jae-Gook Shin, Sang-Goo Shin,[2] Chan-Woong Park, Jae-Jin Kim*, Jong-In Woo* and In-Jun Cha**

Clinical Pharmacology Unit, Seoul National University Hospital and Department of Pharmacology and Psychiatry, Seoul National University College of Medicine*
Seoul 110-460, Korea
*Department of Pharmacology**, Inje University College of Medicine*
Pusan 614-110, Korea

= Abstract =A single dose crossover pharmacokinetic study of amitriptyline and nortriptyline was done to find out the extent of first-pass metabolism to nortriptyline after amitripyline administration, and the contribution of nortriptyline during amitriptyline therapy. Six healthy male volunteers took part in this study and were given single doses (50 mg) of amitriptyline and nortriptyline at more than three-week intervals. Plasma concentrations of the drugs were measured up to 48 hours. Total area under the plasma concentration-time curve (AUC) of amitriptyline (744.6±258.4 ng/ml·h) was smaller than that of nortriptyline (1497.3±589.8 ng/ml·h), and the mean terminal half-life of amitriptyline (21.8±3.9 hr) was shorter than that of nortriptyline (36.8±5.9 h). The total area under the plasma concentration-time curve of nortriptyline produced by amitriptyline administration was 498.1±274.5 ng/ml·h, and the fraction produced by the first-pass of amitriptyline was 33.7±10.5%.

From this data, it can be estimated that the average nortriptyline concentration could be about 40% of the total tricyclic antidepressants present in the plasma of patients taking multiple amitriptyline therapy at steady state. About 34% of nortriptyline is produced by first-pass effect during gastrointestinal absorption of amitriptyline to systemic circulation resulting from N-demethylation of amitriptyline in the liver. Then, the rest of the nortriptyline is formed continuously at a rate proportional to the rate of amitriptyline elimination.

Key Words: ***Amitriptyline, Nortriptyline, First-pass effect, N-demethylation, Pharmacokinetics***

INTRODUCTION

For the treatment of primary unipolar depression, the clinical response of tricyclic antidepressant is reported to be less than 70%(Bennett, 1967). The casuses of modest efficacy of the drugs are thought to be due to the biochemical differences of pathophysiology, low compliance of the depressed patients and pharmacokinetic

Received 5/2/90; revised 28/2/90; accepted 3/3/90

1. This study was supported by the grant from the Basic Research Promotion Fund of College of Medicine, Seoul National University (1989)

2. Author for correspondence.

variability of the drugs. Among these, the interindividual differences of pharmacokinetic properties are currently being emphasized. Some investigators reported that a same-dose regimen of tricyclic antidepressant can result in 30-fold difference in the steady-state total plasma concentration of tricyclic antidepressants, and reports of 5-to-10 fold differences are frequent(Hammer *et al.*, 1967; Asberg, 1976).

Amitriptyline is a tertiary amine tricyclic antidepressant frequently used in depressed patients. The tertiary amine, amitriptyline is metabolized by N-demethylation and benzylic 10-hydroxylation (Bahr, 1972), whereas the demethyl metabolite nortriptyline is primarily metabolized by 10-hydroxylation. The degree of demethylation of amitriptyline might be clinically important because the metabolite formed is active and may reach high concentration in plasma comparable to the parent drug(Braithwaite *et al.*, 1972; Rollins *et al.*, 1980). The variability in this disposition process of amitriptyline can be considered to be the cause of this large interindividual difference in the steady-state total plasma concentration and therapeutic outcome. A considerable portion of nortriptyline product after an amitriptyline dose is suggested to be produced by presystemic elimination during absorption, because amitriptyline shows low bioavailability(30 to 60%) in spite of rapid and complete gastrointestinal absorption(Gram *et al.*, 1975; Jorgensen *et al.*, 1976). However, little attention has been paid to the importance and the degree of the first-pass demethylation of amitriptyline in relation to the nortriptyline concentration during amitriptyline therapy.

The objectives of this study were to define more completely the kinetics of amitriptyline elimination and the interindividual variations of amitriptyline demethlation pathway by crossover pharmacokinetic study with amitriptyline and nortriptyline.

MATERIAL AND METHOD

1. Subjects and study design

Six healthy male adults (age: 25-29, body weight: 55-87 kg) with normal blood chemistry and ECG finding took part in the study. None took any medication for at least one week before this study. Written informed consent was obtained from each subject.

Amitriptyline and nortriptyline 50 mg(25 mg tablet) were administered in a crossover design seperated by more than three-week interval considering the long half-life of the drugs. Drugs were given orally after an overnight fast. No further food or tea was taken for at least four hours. Seventeen samples of venous whole blood were collected up to 48 hr after the drugs were given. An indwelling catheter was inserted into a forearm vein locked with heparin(100 unit/ml), and control blood was drawn before drug administration. Collections of 7 ml blood samples were made at the following times after drug administration: 0.5, 1, 1.5, 2, 2.5, 3, 3.5, 4, 5, 6, 8, 12, 14, 24, 36 and 48 hours. Heparinized blood was centrifuged at 1000 g for 10 minutes immediately after collection, and plasma was stored frozen at −20℃ until plasma drug level determination.

2. Assay of plasma amitriptyline and nortriptyline concentration

Plasma concentrations of tricyclic antidepressants were determined by modifying previously reported HPLC methods (Proeles *et al.*, 1978; Preskorn *et al.*, 1980; Coggins *et al.*, 1980 Suckow *et al.*, 1982) to improve sensitivity. The HPLC system consists of a Gilson 302 pump, Gilson 116 variable wave length UV detector, Rheodyne injector with 100 ul external loop, C-R6A integrator(Shimadzu) and C_{18} reversed phase column (30 cm × 1.9 mm). Potassium phosphate (monobasic), phosphoric acid, hydrochloric acid and sodium hydroxide were all analytical grade, and pentansulfonic acid (Sigma), triethylamine (Aldrich), isoamylalcohol (Merck) and hexane (Aldrich) were used as supplied by the company.

A stock solution (1 mg/ml in 0.1 N HCl) of amitriptyline(Aldrich), nortriptyline(Sigma) and internal standard loxapine (Lederle) were prepared and diluted with 0.01 N HCl solution before use. The extraction procedure of tricyclic antidepressants from plasma was as follows. Two mililiter of plasma, 100 ul internal standard solution(loxapine, 50 ng) and 200 ul 1.5 N sodium hydroxide solution in 15 ml polypropylene conical tube was extracted with 6 ml of 2% isoamylalcohol in hexane. After shaking for 90 minutes and centrifugation at 1000 g for 15 minutes, 5 ml of organic layer were seperated. Two hundred microliters of 0.1 N HCl solution was added to the organic layer and shaken for 30 minutes. After centrifugation, the seperated organic layer was discarded and 100 ul of aqueous layer was injected into the column. The mobile phase of HPLC was 0.1 M KH_2PO_4/Acetonitrile (55/45), pentansulfonic acid 5 mM, triethylamine 10 mM, and pH of the solution was adjusted to 4.0 by phosphoric acid. All the solvent was filtered and degassed

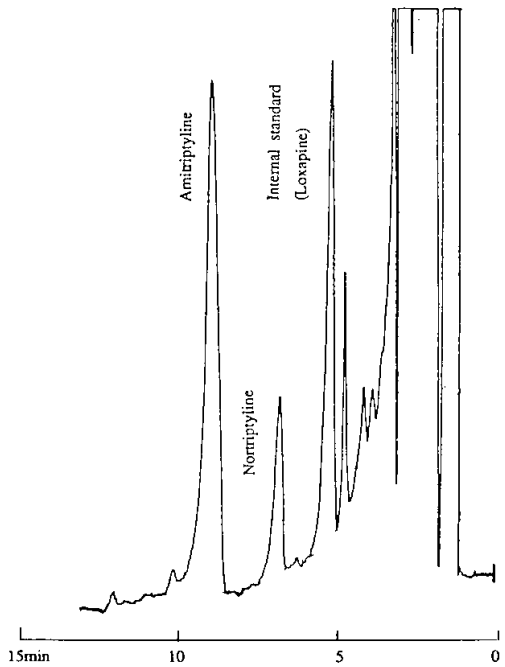

Fig. 1. HPLC chromatogram of extracted plasma after oral administration of 50 mg amitriptyline.

with 0.45 μm pore-sized filter before use. The flow rate of mobile phase was 1.5 ml/min. and wave length of UV detector was set at 214 nm with sensitivity of 0.01 AUFS. The standard curve was linear, from 2 ng/ml to 50 ng/ml. Detection limit of amitriptyline and nortriptyline was about 1 ng/ml, and extraction recovery was about 70%. The representative chromatogram of amitriptyline, nortriptyline and internal standard-(loxapine) from the plasma of study subject is presented in Fig. 1.

3. Pharmacokientic Analysis

Plasma concentrations of amitriptyline and nortriptyline were analyzed by noncompartmental model

1) Calculation of AUC, Clearance, Vd_{area} $t_{1/2\beta}$ and MRT of amitriptyline and nortriptyline

Terminal elimination rate constant(β) of the drugs was obtained by least square method on semilogarithmic plot of plasma concentration and time. Plasma half-life at the elimination phase($t_{1/2\beta}$) was calculated as 0.693/β. AUC(area under the plasma concentration time curve) was calculated by a trapezoidal rule until time to peak concentration and by logarithmic-trapeziodal rule from peak time to the last sampling time. After the last sampling time, AUC was calculated as $C_{p(48)}$ (plasma concentration at 48 hours) divided by β. Clearance(CL/F) after oral does was calculated as the dose divided by the total AUC, and volume of distribution during the elimination phase was calculated as Vd_{area}/F – Dose/β AUC(∞).

2) Analysis of nortriptyline production from the dose of amitriptyline

The total amount of nortriptyline(NT) produced up to time "t" after amitriptyline dose is the amount eliminated until time "t" plus the amount existing in the body.

$$\text{Total NT} = CL_N AUC_N(t) + C_{p.N}(t)\, CL_N/\beta_N \quad (1)$$

Nortriptyline can be expected to be formed in two phases. Some will be formed during the first-pass of amitriptyline through the liver, and subsequently the amount of amitriptyline eliminated from systemic circulation would result in a certain amount of nortriptyline entering the systemic circulation.

Let this fraction to be x, then the amount of nortriptyline formed by amitriptyline elimination from systemic circulation until time "t" is $xCL_A \cdot AUC_A(t)$. If the total amount of nortriptyline produced in the first-pass metabolism of amitriptyline is to be X, then at all times after absorption and first-pass metabolism is complete, the following relation can be derived from equation (1).

$$CL_N AUC_N(A)(t) + C_{p.N}(t) CL_N/\beta_N = X + xCL_A AUC_A(t)$$

$$\text{or } AUC_{N(A)}(t) + C_{p.N}(t)/\beta_N = X/CL_N + x/CL_A / AUC_A(t)/CL_N \quad (2)$$

β_N the elimination rate constant of nortriptyline cannot be obtained from amitriptyline dose. So the crossover administration of nortriptyline is required to know the elimination rate constant of nortriptyline. If β_N is known, the left side of equation(2) can be calculated at each value of "t" and plotted against $AUC_A(t)$. The graph would be a stragiht line when first-pass metabolism is complete. The intercept, X/CL_N is the AUC of nortriptyline formed by the first-pass metabolism of amitriptyline. When "t" approaches infinity, left side of equation is $AUC_{N(A)}(\infty)$, total AUC of nortriptyline formed from amitriptyline dose, and this value determines steady-state average plasma concentration of nortriptyline after multiple amitriptyline therapy

by the relation of

$C_{pss.ave} = AUC_{N(A)}(\infty)/\tau$ (τ = dosing interval).

RESULTS

Representative plasma levels of amitriptyline, nortriptyline and nortriptyline after amitriptyline dose are presented in Fig. 2. After 50mg oral dose, amitriptyline peak plasma concentration is attained before four hours. Then plasma level showed relative rapid declining distribution phase, followed by a linearly declining elimiation phase. Nortriptyline formed after the amitriptyline dose peaked before five hours after dose but did not show definite elimination phase until 48 hours. Same dose of nortriptyline resulted in lower peak plasma level than amitriptyline, and slower decline of plasma level in the elimination phase.

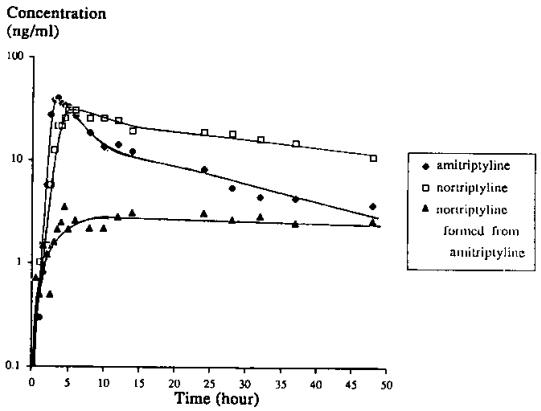

Fig. 2. Plasma concentration time curves of single oral dose of 50 mg amitriptyline and 50 mg nortriptyline in subject 2. Filled triangles are plasma levels of nortriptyline produced after amitriptyline dose.

Pharmacokinetic summary after amitriptyline 50mg single oral dose is summarized in Table 1. Total AUC of amitriptyline was 744.6 ng/ml·h(461.4-1184.9) in average, and mean residence time was 27.8 hours. The terminal half-life averaged 21.8 hours (15.4-25.6), and mean peak concentration and time to peak were 50.7 ng/ml(31.7-89.6) and 2.6 hours(1.5-4), respectively. The volume of distribution(Vd_{area}/F) was 2222 L(1478-3005) and average total body clearance was 73.6 L/h(42.2-108.4).

Pharmacokientic summary of nortriptyline is presented in Table 2. Mean AUC was 1497.3 ng/ml·h(1044.8-2473.3), and mean residence time(MRT) was 53 hours (40.9-66.1) in average. Terminal half-life at elimination phase was 36.8 hours (29.5-42.6). Peak plasma concentration and time to peak plasma concentration were 38.3 ng/ml(21.3-59.3) and 4 hours(3-5), respectively. Volume of distribution(Vd_{area}/F) was 1910

Table 1. Pharmacokinetic summary of amitriptyline after single 50 mg oral dose

Subject No.	Body Weight (kg)	$AUC_A(\infty)$ (ng/ml·h)	MRT_A (h)	$T_{1/2\beta}$ (h)	Vd_{area}/F (L)	CL/F (L/h)	Peak Concentration (ng/ml)	Time to Peak Concentration(h)
1	66	871.7	33.7	25.6	2120	57.36	48.6	2
2	87	592.9	29.6	24.7	3005	84.33	48.6	3.5
3	63	755.3	26.7	21.5	2050	66.20	45.0	3
4	55	601.5	24.1	19.0	2279	83.12	49.4	1.5
5	63	1184.9	31.8	24.3	1478	42.20	89.6	1.5
6	70	461.4	20.8	15.4	2401	108.37	31.7	4
Mean		744.6	27.8	21.8	2222	73.60	50.7	2.6
S.D.		258.4	4.9	3.9	498	23.32	20.2	1.1

$AUC_A(\infty)$: Total area under the plasma amitriptyline concentration-time curve
MRT_A: Mean residence time of amitriptyline
$T_{1/2\beta}$: Terminal half-life of amitriptyline
Vd_{area}/F: Apparent volume of distribution during the β-phase
CL: Total clearance
F: Bioavailability

Table 2. Pharmacokinetic summary of nortriptyline after single 50 mg oral dose

Subject No.	Body Weight (kg)	$AUC_{N(\infty)}$ (ng/ml·h)	MRT_N (h)	$T_{1/2\beta}$ (h)	Vd_{area}/F (L)	CL/F (L/h)	Peak Concentration (ng/ml)	Time to Peak Concentration(h)
1	66	1959.8	66.1	43.8	1611	159.48	47.5	3.5
2	87	1300.5	46.9	29.5	1639	240.38	30.5	5
3	63	1194.0	40.9	30.8	1534	261.73	30.0	4
4	55	1044.8	50.9	37.0	2555	229.13	40.3	3.5
5	63	2473.3	57.0	37.2	1075	126.35	59.3	3
6	70	1010.8	55.9	42.6	3044	309.18	21.3	5
Mean	67.3	1497.3	53.0	36.8	1910	232.7	38.3	4
S.D.	10.8	589.8	8.8	5.9	735	74.6	13.8	0.8

$AUC_N(\infty)$: Total area under the plasma nortriptyline concentration-time curve
MRT_N: Mean residence time of nortriptyline
$T_{1/2\beta}$: Terminal half-life of nortriptyline
Vd_{area}/F: Apparent volume of distribution during the β-phase
CL: Total clearance
F: Bioavailability

Table 3. Nortriptyline production after single 50 mg oral dose of amitriptyline

Subject	$AUC_{N(A)}(\infty)$ (ng/ml·h)	Intercept (ng/ml·h)	Intercept/$AUC_{NA}(\infty)$	$AUC_{N(A)}(\infty)/AUC_A(\infty)$
1	330.2	104.7	0.32	0.38
2	276.5	56.4	0.20	0.47
3	521.5	129.4	0.25	0.69
4	730.4	292.4	0.40	1.21
5	908.4	305.1	0.34	0.77
6	221,4	111.3	0.50	0.48
Mean	498.1	167.1	0.34	0.67
S.D.	274.5	104.7	0.10	0.30

$AUC_{N(A)}(\infty)$: Obtained from the grpah of $AUC_{N(A)}(t) + C_{P\,N}/\beta_N$ against $AUC_A(t)$ (Fig. 3). $AUC_{N(A)}(\infty)$ is the value of the ordinate when abscissa is equal to $AUC_{(A)}(\infty)$.
Intercept: Value of the ordinate when $AUC_A(t)$ is zero (Fig. 3).

L(1075-3044) in average and mean total body clearance was 232.7 L/h(126.4-309.2).

Analysis of nortriptyline production by N-demethylation of amitriptyline dose is presented in Fig. 3. The intercept of vertical axis is the the AUC of nortriptyline formed by the first-pass metabolism of amitriptyline. When the horizontal axis value is the value of the total AUC of amitriptyline, the vertical axis value is the total AUC of formed nortriptyline from the amitriptyline dose. The pharmacokinetic detalis of nortriptyline production from amitriptyline doses in six vounteers are summarized in Table 3. Total AUC of nortriptyline formed from amitriptyline was 498.1 ng/ml·h(221.4-908.4) in average, and the AUC of nortriptyline formed during first-pass of amitriptyline was 167.1 ng/ml·h(56.4-305.1). About 34% of nortriptyline is produced during the first-pass through the liver during absorption of the amitriptyline dose. From the ratio of the total AUC of amitriptyline and nortriptyline after amitriptyline dose, it could be expected that the ratio of the steady state average plasma concentration of amitriptyline and

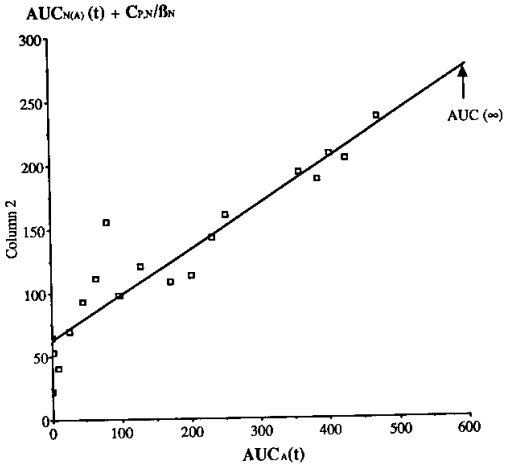

Fig. 3. Analysis of Ist-pass production of nortriptyline after amitriptyline dose: plotting of $AUC_{N(A)}(t) + C_{p,N}/\beta_N$ and $AUC_A(t)$ in subject 2. Intercept/$AUC_A(\infty)$ represents fraction of nortriptyline produced by Ist-pass metabolism. ($AUC_{N(A)}(t)$; area under the plasma concentration-time curve of nortriptyline formed by amitriptyline from time 0 to t, $C_{p,N}$; plasma nortriptyline concentration, β_N; terminal elimination rate constant of nortriptyline)

nortriptyline would be 1.5(0.83-2.63).

DISCUSSION

The plasma concentration-time curve of amitriptyline after single oral dose showed a distinct distribution phase and appeared to be adequately explained by triexponential term, two compartment model. Peak plasma concentration occurred about three hours after dose and coincided with main adverse effects of drowsiness and dry mouth. This fact suggests that amitriptyline is rapidly distributed to the corresponding receptor site from the plasma pool, in contrast with the delayed onset of the antidepressive effect. Adverse effects were present in all the volunteers, and the potency of the subjective symptom seems to be correlated with the peak plasma level of amitriptyline. The plasma concentration-time curve of nortriptyline showed less prominent distribution phase and slower elimination phase. The antihistaminergic and anticholinergic adverse effects, drowsiness and dry month, were much less with nortriptyline than those of amitriptyline in the same oral dose.

The half-lives of amitriptyline and nortriptyline were similar to those reported by other authors after giving single oral dose to healthy subjects(Rollins *et al.*, 1980; Schuz *et al.*, 1983) and depressed patients(Preskorn, 1986). Total area of plasma concentration time curve of amitriptyline and nortriptyline were also similar to other reports(Alexanderson *et al.*, 1972; Gram *et al.*, 1975). The pharmacokinetic parameters of both drugs such as total AUC, peak concentration and volume of distribution, showed large interindividual variations by as much as a three fold difference. This difference is notable considering that the subjects were a relatively homogenous population. However, the individual ratio of amitriptyline total area to nortriptyline total area was relatively constant among subjects, with an average value of 0.5 and a coefficient of variation of 15%, suggesting that the pharmacokientic features of tricyclic antidepressants are an individually determined trait.

The total area of nortriptyline formed after 50 mg amitriptyline dose was 498.1 ng/ml·h in average, and it is 33.3% of total area resulted when the same oral dose of amitriptyline was taken. If oral bioavailability of nortriptyline is assumed to be 50%(Gram *et al.*, 1975), 16.7% of the amitriptyline dose is converted to systemic nortriptyline. Santagostino (1974) reported that nortriptyline metabolites were 59% of the compounds excreted in the urine after single oral dose of amitriptyline and amitriptyline metabolites were 41%. Taken together with our result, a considerable amount of nortriptyline metabolites do not derive from systemic nortriptyline. Presumably, this material is formed by the immediate transformation of nortriptyline as it is formed in the liver and also from demethlation of 10-hydroxy amitriptyline.

From the result of our study, those volunteers with high value of first-pass formation of nortriptyline from amitriptyline tended to have a higher ratio of total area of nortriptyline to amitriptyline after an amitriptyline oral dose ($r = 0.8$). The first-pass demethylation seems to contribute much to the steady-state concentration of nortriptyline in amitriptyline therapy. First-pass production of nortriptyline averaged 34% of the total nortriptyline produced after amitriptyline. However, the variability in first-pass production of nortriptyline was profound, resulting in more

than three fold difference in the ratio of the total amitriptyline area to nortriptyline area (0.8-2.6). Therefore, it seems that the extent of the first-pass metabolism of amitriptyline to nortriptyline contributes much to the plasma concentration of both tricylic antidepressants and also the clinical outcome in amitriptyline therapy. Also, the large interindividual variation of the pharmacokinetic features of amitriptyline can be partly explained by the variability of the first-pass demethylation of the drug.

REFERENCES

Amsterdam J, Brunswick D, Mendels J. The clinical application of tricyclic antidepressant pharmacokinetics and plasma levels. Am. J. Psychiatry. 1980, 137:653-662

Asberg M, Cronholm B, Sjöqvist F, Tuck D. Relationship between plasma level and therapeutic effect of nortriptyline. Br. Med. J. 1971, 3:331-334

Asberg M. Treatment of depression with tricyclic drugs-pharmacokinetic and pharmacodynamic aspect. Pharmacopsychiatr. Neuropsychopharmacol. 1976, 9:18-26

Bennett JF. Is there a superior antidepressant? (in Antidepressant Durgs) edited by GS Duke. Excerpta Medica, 1967

Bertilsoon L, Mellstrom B, Sjöqvist F. Pronunced inhibition of noradrenaline uptake by 10-hydroxy metabolites of nortriptyline, Life Science, 1979, 25:1285-1292

Braithwaite RA, Gonlding R, Theano G. Plasma concentration of amitriptyline and clinical response. Lancet, 1972, 1:1297-1300

Burch JE, Hullin RP. Amitriptyline pharmacokientics. Single does of Lentizol compared with ordinary amitriptyline tablet. Psychopharmacology, 1981, 74:43-50

Carlsson A, Carrodi H, Fuxe K, Hokfelt T. Effect of some antidepressant drugs on the depletion of intraneuronal brain catecholamine stores caused by 4-alpha-dimethyl-meta-tyramine. Eur. J. Pharmacol. 1969, 5:367-373

Gibaldi M, Perrier D. Pharmacokinetics. Marcel Dekker, 1982

Garland WA, Min BH, Birkett DJ. The kinetics of amitriptyline following single oral dose administration to man. Res. Comm. Chem. Path. Pharmacol. 1978, 22:475-484

Gram LF. Metabolism of tricyclic antidepressants: A review. Dan. Med. Bull. 1974, 21:218-228

Gram L, Overo K. First-pass metabolism of nortriptyline in man. Clin. Pharmacol. Ther. 1975, 18:305-314

Gram L. Christansen J. First-pass metabolism of imipramine in man. Clin. Pharmacol. Ther. 1975, 17:555-563

Hammer W, Sjöqvist F. Plasma levels of monomethylated tricyclic antidepressants during treatment with imipraine-like compounds. Life Science, 1967, 6:1815-1903

Hollister LE. Tricyclic antidepressants. N. Engl. J. Med. 1975, 299:1006-1109

Hollister LE. Monitoring tricyclic antidepressant plasma concentrations JAMA. 1979, 241:2530-2533

Jorgensen A. Comparative bioavailability studies with a sustained release preparation of amitriptyline and ordinary tablets given to human volunteers. Eur. J. Clin. Pharmacol. 1977, 12:187-190

Jorgenssen A, Hansen V. Pharmacokinetics of amitriptyline infused intravenously in man. Eur. J. Clin, Pharmacol. 1976, 10:337-341

Jungkunz G. Kuss HJ. Amitriptyline and its demethylation rate. Lancet, 1978, 2:1263-1264

Kuhn R. The treatment of depressive state with G22355(imipramine hydrochloride). Am. J. Psychiatry, 1958, 115:459-464

Kupfer DJ, Hanin I, Spiker DG. Grau T, Coble P. Amitriptyline plasma levels and clinical response in primary depression. Clin. Pharmacol. Ther. 1977, 22:904-912

Mass JW. Biogenic amines and depression. Arch. Gen. Psychiatry, 1975, 32:1357-1361

Preskorn SH, Leonard K, Hignit C. Liquid chromatography of amitriptyline and related tricyclic compounds. J. Chromatogr. 1980. 197:246-250

Preskorn SH. Tricyclic antidepressant plasma level monitoring: an improvement over dose-response approach. J. Clin. Psychiatry, 1986, 47(1. suppl):24-30

Proeles HF, Lohmann HJ, Miles DG. High-performace liquid chromatographic simultaneous determination of commonly used tricyclic antidepressants. Clin. Chem. 1978, 24:1948-1953

Rollins DE, Alvan G, Bertillsson L, Gillette JR, Mellström B, Sjöqvist F, Traskman L. Interindividual differences in amitriptyline demethylation. Clin. Pharmacol. Ther. 1980, 28:121-129

Santagestion G, Facino RM, Pirillo D. Urinary excretion of amitriptyline N-oxide in humans. J. Pharm. Sci. 1974, 63:1690-1692

Schulz P, Tamiyasu KT, Smith G, Giacomini KM, Blaschke TF. Amitriptyline disposition in young and elderly normal man. Clin. Pharmacol. Ther. 1983, 33:360-366

Scoggins BA, Maguire KP, Norman TR, Burrows GD. Measurement of tricylic antidepressants Part I. A review of methodology. Clin. Chem. 1980, 26(1):5-7.

Suckow RF, Cooper TB. Simultaneous determination

tain at present how rare the spontaneous closure rate is and whether all the infundibular ventricular septal defects develop aortic prolapse/insufficiency or some other form of aortic complication, such as sinus valsalva aneurysm in the long run. Sequential observation on the progressive changes in the aortic valve and sinus area, along with a detailed anatomic study of the defect and hemodynamic assessment, seems necessary to understand some uncertainties in the natural history of infundibular ventricular septal defect.

Echocardiography has been very useful in assessing the ventricular septal defect and aortic valve and/or sinus disease (Bierman *et al.*, 1980; Sutherland *et al.*, 1982; Terdjman *et al.*, 1984; Hagler *et al.*, 1985). There have been several reports on the echocardiographic findings of infundibular ventricular septal defect, and these showed that aortic valve prolapse can be diagnosed by echocardiogram (Craig *et al.*, 1986; Menahem *et al.*, 1986; Schmidt *et al.*, 1988). In addition to aortic valve prolapse, an echocardiogram should be able to identify the structure bordering the defect and to show the aortic valve motion and other anatomic changes around the defect. Furthermore, a Doppler study has been used to gather hemodynamic information, and color Doppler has been very useful in assessing valvular insufficiency (Miyatake *et al.*, 1986; Helmcke *et al.*, 1987; Perry *et al.*, 1987).

This study was undertaken to asses the role of echocardiography in infundibular ventricular septual defect and to compare the echocardiographic findings with cardiac catheterization and angiographic and surgical findings.

MATERIALS AND METHODS

All the patients who were operated on for infundibular ventricular septal defect at Seoul National University Children's Hospital from october 1987 to January 1989 were included in this study. The doubly committed subarterial type and the muscular outlet type were inculded, but the perimembranous defect with outlet extension was not included. Severe pulmonic stenosis with cyanosis (tetralogy of Fallot) were excluded, but mild to moderate pulmonic stenosis with a pressure gradient of less than 50 mm Hg were included. It has been our policy to operate on all the infundibular ventricular septal defects in view of possible aortic complications. When patients are symptomatic and fail to thrive, they undergo operations in infancy. When they present an asymptomatic murmur, they usually undergo an operation after one year of age.

All patients had a chest X-ray, an electrocardiogram, an echocardiogram and a cardiac catheterization and angiography before surgery. Echocardiograms were performed using the Aloka 880 color Doppler with a 3.0MHz and a 5.0MHz transducer. The Ultramark 8 of ATL was used for the last few patients. A systemic approach was used for two dimensional echocardiography with special attention given to the structures bordering the ventricular septal defect; the presence or absence of aortic valve prolapse; the aortic valve motion and other structural changes around the defect. Prolapse is regarded to be present when there is a valvular bulge toward the right ventricular side or when the aortic valve looks folded during systole in the long axis view. The infundibular defects were subtyped according to the structure bordering the defect and the presence or absence of the aortic valve prolapse. The defect size was measured from the lower margin of the defect to the the remaining portion of the infundibular septum in the muscular outlet types or to the pulmonary valve annulus in the doubly committed subarterial types. The diameter of the defect was divided by the body surface area for standardization and represented as mm/M2. Subsequently, the Doppler study was performed to measure maximal velocity through the ventricular septal defect using continuous Doppler incorporated in a two dimensional image. In most cases, aortic insufficiency jet was searched for through the color Doppler technique. Aortic insufficiency was considered to be present when a spindle shaped regurgitation jet from the aortic valve was persistently demonstrated in the color flow image. Quantification of the insufficiency was not attempted, but jet distance and jet width were measured in a long axis color flow image, and jet direction was also noted. When the insufficiency jet hit the mitral valve, the jet distance was measured from the aortic valve to the mitral valve. The jet width was measured and divided by the anterior-posterior diameter of the left ventricular outflow tract (Perry *et al.*, 1987). Cardiac catheterization was per formed under ketamine

anesthesia. An assumed oxygen consumption value was used for flow calculation. A long axial oblique view and a right anterior oblique view were used for left ventriculography. An aortic root injection was done in most cases using right anterior oblique and left anterior oblique views. Aortic valve prolapse was assessed (Tatsuno *et al.*, 1973a & b; Menahem *et al.*, 1986), and aortic regurgitation was graded by the usual criteria (Grossman, 1986).

Operation records were reviewed for the size of the defect, structures bordering the defect and for the presence or absence of aortic valve prolapse.

Student T tests were used to measure statistical differences. A P value of <0.05 was regarded as significant. The least square method was used for regression.

RESULTS

There were 80 cases. The male-female ratio was 1.7 to 1 and the age distribution is shown in Table 1. Half of the patients who underwent an operation were below the age of three years.

Table 1. Age distribution

Age (year)	under 1	-2	-3	-4	-7	-10	over 10	Total
No	19	15	6	9	11	8	12	80

For the purpose of description, infundibular septal defects were subclassified into 4 groups according to structures bordering the defect and the presence or absence of the aortic valve prolapse (Fig. 1). In the first group (Group 1), pul-

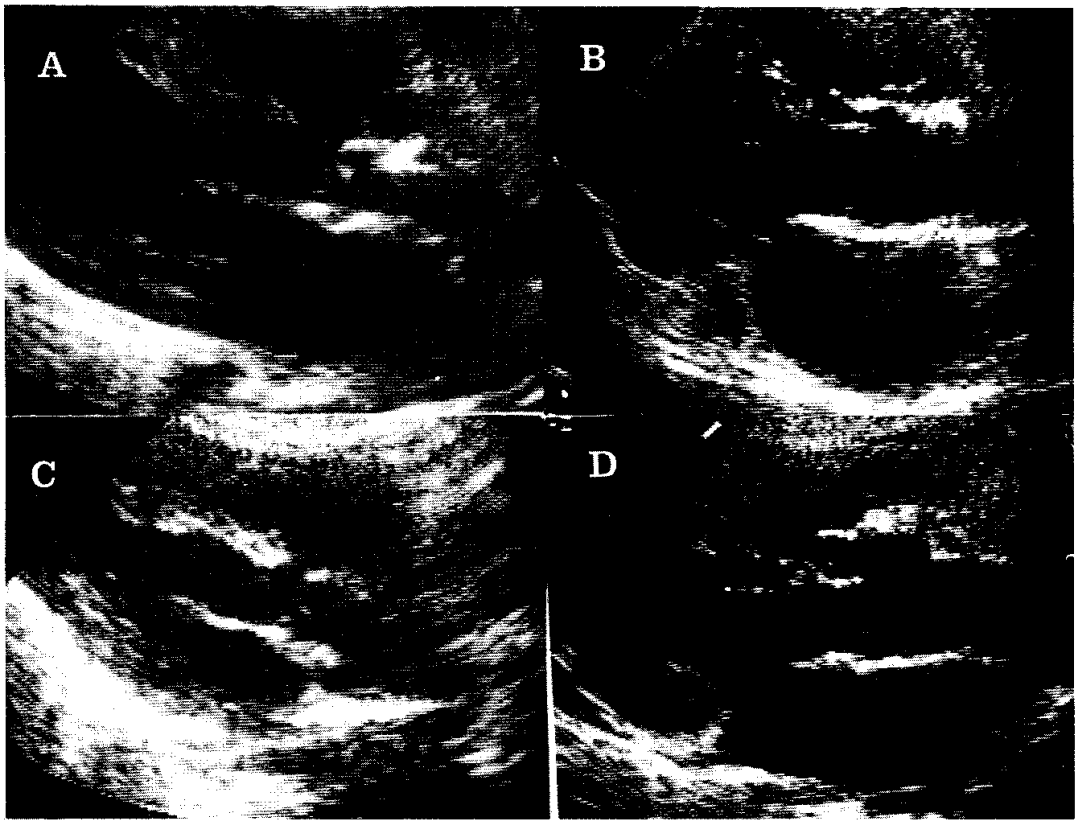

Fig. 1. Echocardiogram of each subtype. A and B are "doubly committed subarterial type," which show continuity between the pulmonic and the aortic valve. There is no aortic valve prolapse in A but there is in B. C and D are "muscular outlet type." There is an intervening muscle strip between the pulmonic vavle and the aortic valve. The prolapse is noted in D but no aortic valve prolapse in C.

monary valve annulus forms in the upper margin of the defect from the right ventricular aspect, and this has been called a doubly committed subarterial defect. Group 1 was divided into two according to the presence or absence of aortic valve prolapse. When there is no prolapse, there is a direct continuity between the pulmonic valve and the aortic valve, and the large functioning defect is roofed by valvi continuity (Group 1a). In some members of this Group 1a, the remaining infundibular septum is deviated posteriorly causing a subaortic obstruction. On the other hand, if there is a prolapse, the pulmonic valve is continuous with the prolapsed protion of the aortic valve and the greater part of the defect is closed by the prolapsed cusp (Group 1b). In the second group(Group 2), the defect is bordered entirely by muscular tissue from the right ventricular aspect, but from the left ventricular side, an aortic valve annulus forms the margin of the defect. This has been called the muscular outlet type. Group 2 was also divided into two according to the presence (Group 2b) or absence (Group 2a) of prolapse. In each case, the defect was subclassified into subtypes on the basis of the surgical findings.

The clinical characteristics of the various subtypes are shown in Table 2. Groups la and 1b (doubly committed subarterial defect) are more common than groups 2a and 2b (muscular outlet type). Group 1a usually presented congestive heart failure in early infancy. The mean pulmonary to systemic flow ratio was 3.4:1 (The cases with another shunt lesion other than ventricular septal defect were excluded from the computation of flow ratio). On the other hand, Group 1b usually presented heart murmur in early childhood with or without a history of congestive heart failure in the infancy period. There is only one case in Group 2a. Group 2b is similiar to Group 1b in the mode of presentation. The mean value of the standardized size of the defect in Group 1 (15.9mm/M2) is larger than in Group 2(10.0mm/M2), but the difference did not reach a significant level. The standardized defect size of Group 1a is bigger than that of Group 1b or 2b. In Group 1a, six cases had associated defects, mostly coarctation of aorta and patent ductus arteriosus. Three cases which had coarctation of aorta also had posterior malalignment of the infundibular septum. In Group lb, six cases had associated anomalies.

The echocardiographic diagnosis of various subtypes was compared with the surgical diagnosis (figure 2). Echocardiographic diagnosis was the same as the surgical diagnosis in 72

Table 2. Clinical characteristics in each subgroup

	Mean Age Range (mo)	Sex Ratio	Qp/Qs Ratio	Incidence of CHF in Infancy	Defect Size (mm/m2)	Assoicated Anomaly
Group 1a(16)*	6 1 ~ 20	1.7:1	3.4:1	100%	32.8	PDA + COA + AS(1)* PDA + COA(1) COA(1) PS(1) PDA(2)
Group 1b(46)	74 7~198	1.6:1	1.2:1	17%	10.1	PS(4) PDA + COA(1) subsortic ridge(1)
Group 2a(1)	12	—	2.5:1	100%	54.1	MR(1)
Group 1b(17)	47 8 ~ 145	2.4:1	1.2:1	29%	7.4	PS(1) subaortic ridge(1)

AS: aortic stenosis, COA: coarctation of aorta, CHF: congestive heart failure, mo: months, MR: mitral regurgitation, PDA: Patent ductus arteriosus, PS: pulmonic stenosis, Qp/Qs: pulmonary/systemic flow ratio

* The numbers in parentheses are the number of cases.

The same abbreviations are used in the other tables.

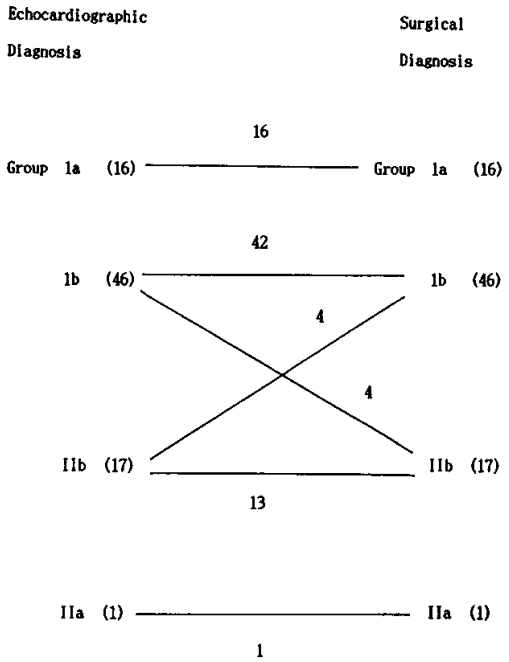

Fig. 2. The echocardiographic diagnosis of the subtype is compared with the surgical diagnosis.

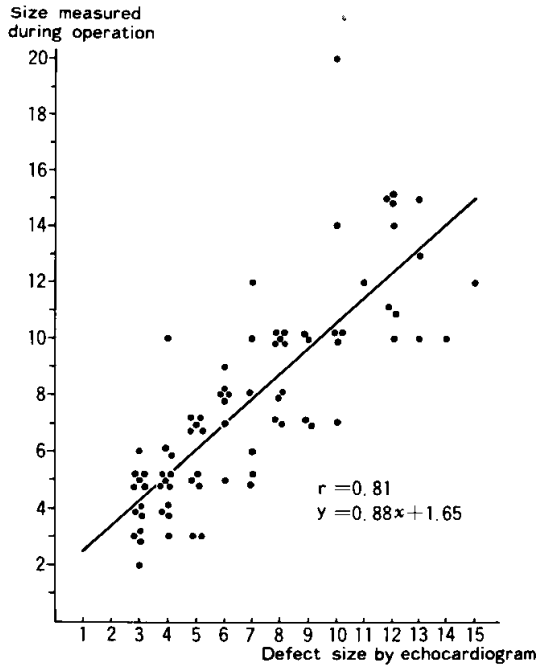

Fig. 3. The defect size measured by the echocardiogram is compared with the size measured during the operation. The regression line is superimposed.

cases. There were eight misdiagnoses. In four cases, the small muscle strip below the pulmonic valve was mistaken for fibrous annulus, and in another four cases, the fibrous annulus was mistaken for the muscle strip, but these two kinds of mistake did not affect the surgical technique.

The defect size measured on the two dimensional still frame was compared with the one measured during the operation(Fig. 3). Generally there was a good correlation between these two measurements. The R value was 0.81 ($P<0.01$). However, there were a few cases which showed significant differences between the two measurements. Review of the echocardiogram in these cases revealed that the maximum diameter of the defect was not shown becasue of a poor echocardiographic window.

Some qualitative changes of the aortic valve motion were assessed on the two dimensional picture. In Group 1a, the aortic valve motion looked normal and the aortic valve hinged from the fibrous raphe between the aortic valve and pulmonary valve. One case in Group 2a also showed normal aortic valve motion. In Groups 1b and 2b, (63 cases) there were three kinds of aortic valve motion(Fig. 4). The most common type (44 cases) was that, with the onset of the ventricular systole, the aortic valve made a bend at the mid-portion and looked folded during systole. Concomitant with this, anterior or downward protrusion usually became more pronounced in systole. In the other 13 cases, however, the prolapsed aortic valve looked fixed at the upper margin of the ventricular septum and did not slide over the defect. The aortic valve hinged from the left ventricular aspect of the ventricular septal crest. In the remaining six cases, a thin echogenic line extended from the right ventricular aspect of the septal crest to the middle of the prolapsed aortic valve. This membrane bulged during systole, and the aortic valve hinged from the point where the membrane was attached to the prolapsed valve. The latter two types of aortic valve motion may be related to fibrotic change.

The degree of aortic valve prolapse was assessed by echocardiography using parasternal long axis and short axis views in the patients

belonging to groups 1b and 2b, and the result was compared with angiographic findings. Groups 1a and 2a were excluded because there was no one who showed prolapse on the two dimensional echocardiogram, and only a few had an aortogram. The grading of aortic prolapse by echocardiography (Fig. 5) is as follows: "DOWNWARD PROLAPSE": During diastole, the aortic valve and sinus wall look noraml, but during systole, the aortic valve looks folded and usually shows a bright dot at the bending point. The portion between the bending point and the anterior aortic wall is very thin, which is certainly abnormal. There is no bulging toward the right ventricular side. "MILD": When there was a small protrusion into the right ventricle and it looked like a so-called "teardrop" in angiography. "MODERATE": The bigger and more anterior protrusion. "SEVERE": The biggest protrusion into the right ventricular side. There usually is a bright dot at the middle of the prolapsed portion. Angiographic findings were assessed according to the degree of the anterior protrusion and the deformity of the aortic valve/sinus area, and these were graded as "no," "mild," "moderate" and "severe". The results of these two studies are compared in Fig. 6. Echocardiographic "DOWNWARD PROLAPSE" was regarded as equivalent to a "no" resulting from aortography. Generally there is a good correlation between the results of these two studies. However, echocardiograms often fail to identify mild prolapse noted by angiography although angiograms occasionally did not show mild prolapse documented by echocardiograms. All the involved cusps were right coronary cusps.

ANGIOGRAPHIC GRADING	Downward prolapse	mild	moderate	severe
severe				5
moderate	3	1	6	5
mild	11	9	1	
No	16	4	1	

ECHOCARDIOGRAPHIC GRADING

Fig. 6. Comparision of the echocardiographic grading of the arotc prolapse with aortograhpic grading in prolapsed cases. One case was omitted because an aortogram was not available.

Some hemodynamic parameters of the prolapsed group are summarized in Table 3 according to the degree of prolapse assessed by combining echocardiography and aortography. When the results of these two studies are the same, the final degree of prolapse is the same as in these two studies. If the results of these two studies are different, then the more severe grade is taken as the final degree of prolapse. As a result, there were 16 cases which showed "downward prolapse" in echocardiography and no abnormality in aortography (no anterior protrusion group). These cases were not different from others from the hemodynamic point of view but their mean age was lower than other groups.

There were three cases with bicuspid aortic valve, and all the rest had three leaflets. Another three cases had thickened and deformed right coronary cusps.

Aortic insufficiency was assessed by a Doppler study and/or aortography in 73 cases. In the remaining seven cases, aortic insufficiency was assessed only by auscultation. Nineteen cases had aortic insufficiency. In 10 cases, insufficiency was found in both aortography and color flow mapping. The color Doppler study identified an additional six cases whose aortogram showed no regurgitation. Table 4 summarizes some of the important findings of the color Doppler study. The jet tends to be narrow and jet direction is central in those who had aortic insufficiency seen only by color Doppler study and not by aortography. In contrast, the jet is thicker and jet direction is toward the mitrial valve in those who had insufficiency identified by Doppler and aortography.

DISCUSSION

The classification of ventricular septal defects has been proposed by many authors. However, there is still no widely-accepted classification (Goor *et al.*, 1970; Soto *et al.*, 1980; Capelli *et al.*, 1983). Therefore different names are applied to the same anatomic defect, and this causes some confusion (Becker and Anderson, 1985). The subject of this study was the infundibular septal defect without involvement of the membraneous septum. These have been variously called "doubly committed subarterial," "subarterial," "subpulmonic," "infundibular," "muscular

Table 3. Hemodynamic parameters according to the final degree of prolapse

	N	Mean Age Range (mo)	Defect Size (mm/m2)	Qp:Qs	Peak Velocity through Defect (m/sec)
No anterior protrusion	16	27 7 ~ 133	10.0	1.34	4.2
Mild	24	84 13 ~ 187	7.3	1.20	4.5
Moderate	12	63 12~202	10.6	1.10	4.2
Severe	11	93 31 ~ 171	11.6	1.16	4.5

Table 4. Color Doppler findings in the cases with aortic insufficiency

Age (months)	Angio Grading	Color Doppler Findings		
		Jet Distance(mm)	Jet Width (%)	Jet Direction
25	0	5	11	C
50	0	5	18	C
65	0	13	18	C
67	0	7	17	C
73	0	14	25	C
105	0	12	18	C
67	1	23	33	M
86	1		pulsed Doppler only	
91	1	9	10	C
187	1		pulsed Doppler only	
19	2	11	33	M
43	2	10	29	M
77	2	12	23	C
160	2	23	39	M
84	3	18	44	M
165	3	18	37	M
178	4	25	50	M
14	Not performed	12	19	C
171	Not performed	23	24	M

Jet width(%) represents percentage of jet width relative to left ventricular ouflow dimension.
"C" and "M" in jet direction indicate "central jet" and "jet toward mitral valve" each.

outlet," or "supracristal" (Goor *et al.*, 1970; Capelli *et al.*, 1983; Van Praagh and McNamara, 1968).

Ventricular septal defect with aortic insufficiency has been the subject of many pathologic and clinical studies (Nadas *et al.*, 1964; Van Praagh and McNamara, 1968; Tatsuno *et al.*, 1973a; Momma *et al.*, 1984; Ando and Takao, 1986). Both perimembraneous and infundibular defect can result in aortic insufficiency, and the right coronary cusp and non-coronary cusp are involved in prolapse. Infundibular defects are more likely to develop aortic insufficiency than perimembranous defects, and a different pathogenesis was suggested for aortic insufficiency according to the anatomic type.

Infundibular ventricular septal defect is important because it develops aortic insufficiency in a significant proportion of cases. The pathophysiology of aortic insufficiency has been discussed in many papers. Both anatomic and hemodynamic factors have been ascribed to the development of aortic insufficiency (Tatsuno *et al.*, 1973a; Ando and Takao, 1986). Recently Momma *et al.* studied the natural history of subarterial infundibular ventricular septal defect and suggested that nearly all cases of infundibular defects ultimately develop some form of aortic complication. However, this study was based on statistics from hospitalized patients and was not a sequential follow-up study. The best way to study the natural history may be through follow up observation on a large cohort of patients. Echocardiography may be best suited for natural history study because it is non invasive, can be repeated and provides not only anatomic information but hemodynamic information (Schmidt *et al.*, 1988).

In this study, infundibular septal defects were classified into four types. We did not intend to make a new classification or nomenclature, but we wanted to make an accurate description. Echocardiograms have been reliable to delineate the anatomy of ventricular septal defects, but so far few have reported their role on infundibular septal defects with or wihout prolapse (Menahem *et al.*, 1986; Craig *et al.*, 1986; Schmidt *et al.*, 1988). This study confirmed that echocardiogram was generally reliable to idnefity structures bordering the defect. However, there were a few mistakes which we think can be solved by a machine with better resolution. The size of the defect can also be measured accurately by echocardiogram except in some instances with poor echocardiographic window.

Those who had a large defect without prolapse usually presented congestive heart failure and failed to thrive so that they needed surgical correction in infancy. But the prolapsed group usually presented heart murmur. Momma *et al.* showed frequencies of various forms of aortic complications according to age group. The proportion of those who had pulmonary hypertension but neither prolapse nor regurgitation (they were similar to our Group 1a) decreased rather sharply from over 90% in the age group of 0-1 years to about 10% in the age group of 5-7 years. The cause of this decrease is not clear, but it may have resulted from early surgical correction, early medical death or development of aortic complication.

Ando and Takao suggested in a recent pathologic paper that the anatomy of the ventricular septal defect may be related to the development of prolapse and aortic insufficiency. In their study, the coarctation type ventricular septal defect, regardless of the location, was not associated with any kind of aortic complication except in one case of prolapse. Nor was there any unsupported sinus wall or aortic valve annulus in the coarctation type ventricular septal defects. In contrast, all the cases of subarterial infundibular punched hole type had not only some form of aortic complication (either prolapse or insufficiency or sinus valsalva aneurysm) but also an unsupported sinus wall and an aortic annulus. The suggestion of Ando and Takao is very interesting in two aspects. First, infundibular septal defects are not a signle entity from the pathologic point of view. Some of them have unsupported sinus wall and aortic valve annulus whereas others do not. The presence of an unsupported structure and the likelihood of aortic insufficiency can be predicted by the status of the septal alignment. It would be very interesting to confrim Ando and Takao's finding through a large scale clinical study, but it would be limited by surgical intervention. In this study material, there were only three cases with significant posterior malalignment, all of which had associated coarctation of the aorta. All three patients had their defects closed so early that it was impossible to see the

progression. Secondly, the simple punched hole type defects usually have an unsupported sinus wall and an aortic valve annulus, which should be in such a state since the completion of cardiac development in fetal life. If so, is it possible to identify an unsupported sinus wall by echocardiography? Furthermore, is it possible to tell an unsupported sinus wall from an aortic valve leaflet by any non-invasive means? To our knowledge, there has not been any study on these matters. In this study, echocardiographic prolapse was defined by a bulging of the aortic valve/sinus area and a careful analysis of the aortic valve motion. The mildest degree of prolapse was labeled "downward prolapse" in which the aortic valve was folded together with a bright dot at the folding point during systole. The bright dot in the middle of the prolapsed valve was also a usual finding in more severe degrees of prolapse (see arrowheads in Fig. 4 and 5.). It is quite tempting to hypothesize that the bright dot is an aortic annulus and that the portion between the bright dot and the anterior aortic wall is an unsupported sinus wall. Thus the "downward prolapse" may be what the simple punched hole type with unsupported sinus wall looks like before significant prolapse develops. Over time and with the Venturi effect, an aortic valve annulus would loosen and elongate, and the entire unsupported sinus wall, annulus and leaflet would prolapse more downward and anteriorward. Schmit *et al.* reported echocardiographic findings similar to our "downward prolapse" group. Actually, they described the early stage of aortic valve prolapse to be subtle and to appear only as a slightly irregular anterior protrusion of the involved sinus. But the pictures in their article (Fig. 3 top and Fig. 6) showed mainly a downward prolapse with little or no anterior protrusion. It is important to diagnose aortic valve prolapse because it is known to precede aortic insufficiency. Aortography and recently echocardiography are used to assess aortic valve prolapse. Though there is some debate on which method is better, aortography has been the standard method (Menahem *et al.*, 1986 Craig *et al.*, 1986). However, there has not been any firm angiographic criteria for aortic valve prolapse, and most of the criteria are vaguely described as "deformity," "irregular contour" or "protrusion beyond natural contour." Furthermore all these criteria describe protrusion of the aortic valve/sinus anteriorly toward the right ventricular side. Though echocardiogram has been used to diagnose aortic prolapse, no one has suggested the criteria for its grading. The criteria used in this study was objective, but it was not difficult to grade prolapse. This study showed that echocardiographic grading of the aortic valve prolapse correlated well with the angiographic grading in moderate and severe prolapse, but in mild prolapse the correlation between the two studies was not good. Neither echocardiograms nor aortograms were sensitive methods for identifying small prolapses. The theoretical advantage of echocardiograms is that they can provide numerous slices. Their limitation is that the area of interest is so close to the transducer that sometimes it is hard to get a good picture. On the other hand, aortography is limited by the number of planes, and if a small protrusion is not profiled it can be missed. Thus it is very difficult to tell which diagnostic method is better, and both methods should be used in doubtful cases.

Aortic valve motion received little attention so far. This study showed three types of motion in a prolapsed valve, and the most common type could be regarded as normal motion of a prolapsed valve. However, in some cases the aortic valve was fixed at the septal crest, whereas in other cases a thin line extended from the right ventricular side of the septal crest to the middle of the prolapsed valve. The mechanism of fixation and the nature of the thin line are not clear, but they may be related to fibrotic change resulting from physical trauma to the prolapsed aortic valve and the septal crest during the cardiac cycle. This fibrotic change may also be responsible for the spontaneous closure of the infundibular defect, which rarely happens (Momma *et al.*, 1984).

Nineteen cases (23.8%) had aortic insufficiency. The incidence of aortic regurgitation depends on the characteristics of the population studied and the diagnostic method. Interestingly there were six cases which showed an regurgitation jet on the color flow image but did not show any regurgitaton on aortography. It seems certain that the regurgitation jet in the color flow image was not an artefact (Takamoto, 1987) because it was persistently seen and showed a typical spindle shaped jet from the aortic valve during di-