

## Glomerular Fingerprint Deposits in Hepatitis B Virus-associated Nephropathy<sup>†</sup>

Gyeong Hoon Kang and Hyun Soon Lee<sup>1</sup>

*Department of Pathology, Seoul National University College of Medicine, Seoul 110-460, Korea*

**=Abstract=**Fingerprint deposits have been considered as a characteristic feature of lupus nephritis. We report such deposits in a case with hepatitis B virus-associated membranoproliferative glomerulonephritis. The patient did not show any sign of systemic lupus erythematosus at time of biopsy or during a 3-year follow-up period.

**Key Words:** *Fingerprint deposits, Hepatitis B virus infection, Membranoproliferative glomerulonephritis*

### INTRODUCTION

Since Grishman *et al.* (1967) reported organized deposits with a fingerprint pattern in kidneys with systemic lupus erythematosus (SLE), they have been regarded as a rare but special ultrastructural feature of lupus nephritis. Yet, these deposits were also described in a few cases with idiopathic membranous nephropathy (Spargo *et al.* 1980), membranoproliferative glomerulonephritis (MPGN) (Davis *et al.* 1976), and Goodpasture's syndrome (Zollinger *et al.* 1978). Alpers *et al.* (1984) reported two patients featuring glomerular deposits with a fingerprint pattern, who did not show any evidence of SLE at time of biopsy but later developed clinical features of SLE. From these observations, they believe that these deposits can be a specific marker for SLE, even when overt clinical signs of SLE are

absent.

We have observed such deposits in renal biopsy material from a patient with hepatitis B virus (HBV)-associated MPGN, who did not show any sign of SLE at time of biopsy or after a follow-up of three years. The extreme rarity of this lesion in renal disease with no evidence of SLE prompted us to report this case. Also, we will discuss the possible pathogenesis of this lesion in this report.

### CASE REPORT

A 55-year-old woman was admitted in August 1988 for evaluation of generalized edema and left flank pain. The edema had begun four years previously, when urinary abnormalities had been detected. She had been intermittently treated with diuretics. Physical examination revealed a slight degree of pitting edema in both extremities. Blood pressure was 160/110 mmHg. All other systems were normal. The laboratory investigation included the following: hemoglobin 13.6 g/dL, leukocyte count 7,500/mm<sup>3</sup>, platelet count 310,000/mm<sup>3</sup>, blood urea nitrogen 4.6 mmol/L urea (13 mg/dL), creatinine 71 μmol/L (0.8 mg/dL), SGOT 25 units/L, SGPT 26 units/L, albumin 2.7 g/dL,

---

Received January 1992, and in final form March 1992.

<sup>†</sup>This work was supported by a grant from Seoul National University Hospital (1989).

<sup>1</sup> Author for correspondence

서울대학교 의과대학 병리학교실 : 강경훈, 이현순

cholesterol 10.4 mmol/L (399 mg/dL). A lupus erythematosus cell test was negative, as were tests for rheumatoid factor, antinuclear and anti-DNA antibodies. Cryoprecipitate was not found in the serum. The circulating hepatitis B surface antigen (HBsAg) and hepatitis B e antigen (HBeAg) were positive, while anti-HBs, anti-HBe, and anti-HBc were negative. Urinalysis showed an average proteinuria of 3.8 g/day and microscopic hematuria. A renal biopsy was performed.

The renal biopsy specimen contained 16 glomeruli, of which two glomeruli (13%) exhibited global sclerosis. The remaining glomeruli were of moderately to severely increased size and slightly hypercellular involving mesangial cells. Mesangial matrix was also increased. There was diffuse mesangial interposition forming a tram-track appearance and lobular patterns (Fig. 1). One glomerulus (6%) showed segmental sclerosis. Ultrastructural examination disclosed localized but heavy subendothelial

and mesangial deposits as well as a few subepithelial deposits. In a focus, mesangial deposits surrounding a cell containing big lipid vacuoles were organized as bundles, featuring fingerprint patterns (Fig. 2). The bundles consisted of six to 12 regularly stacked, curvilinear, electron-dense bands of varying lengths (Fig. 3). Also, capillary lumens contained some cholesterol-ester containing foam cells. By immunofluorescence, the glomeruli revealed a heavy mesangial and peripheral staining of IgA and C1q, with lesser amounts of IgG, IgM and C3 staining. Tubules revealed focal moderate atrophy or loss accompanied by interstitial fibrosis. Small arteries focally exhibited moderate fibrointimal hyperplasia.

Her blood pressure normalized with anti-hypertensive drugs. Repeated tests for lupus were all negative. At the last follow-up three years following biopsy, she showed no clinical sign of SLE but microhematuria and slight proteinuria persisted with HBs antigenemia.

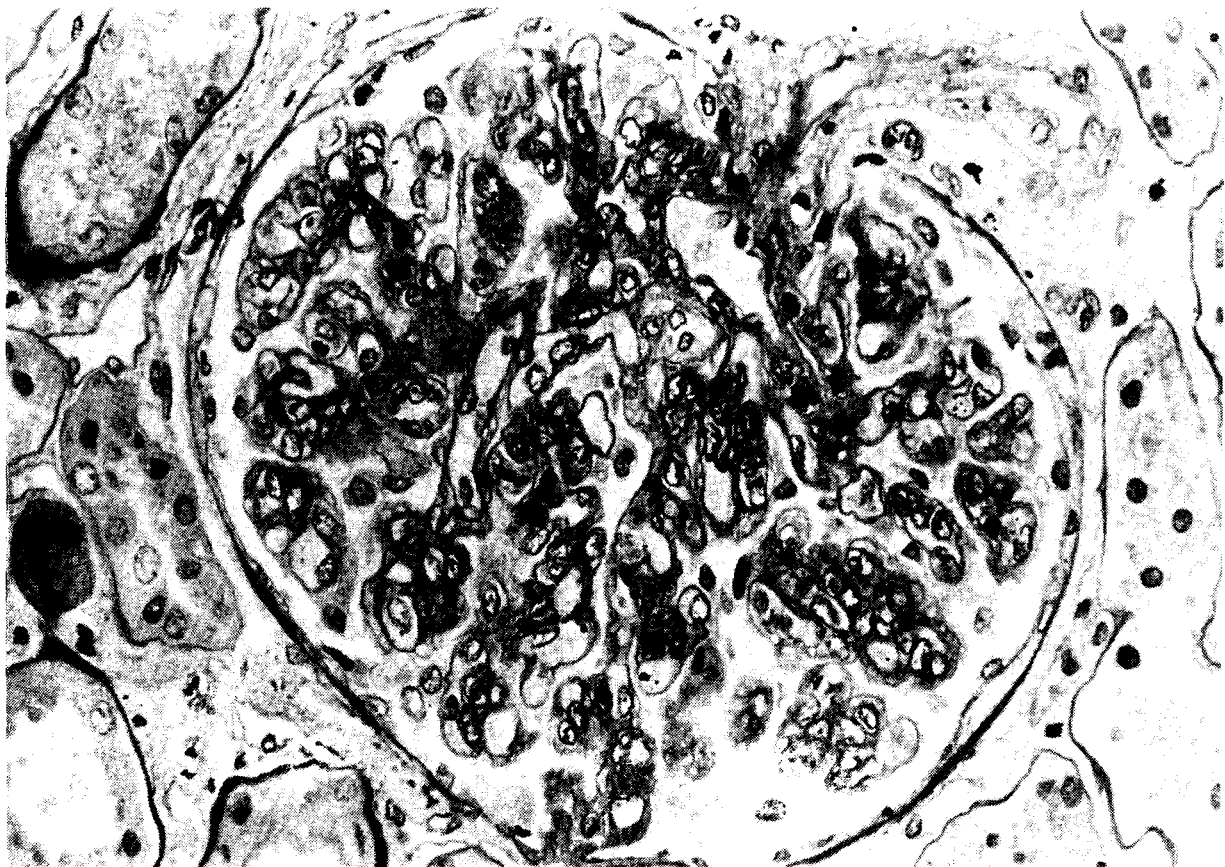


Fig. 1. Light micrograph of a glomerulus showing prominent increase in mesangial substance and localized thickening of peripheral capillary loops with mesangial interposition. PAS stained; original magnification, (x400).

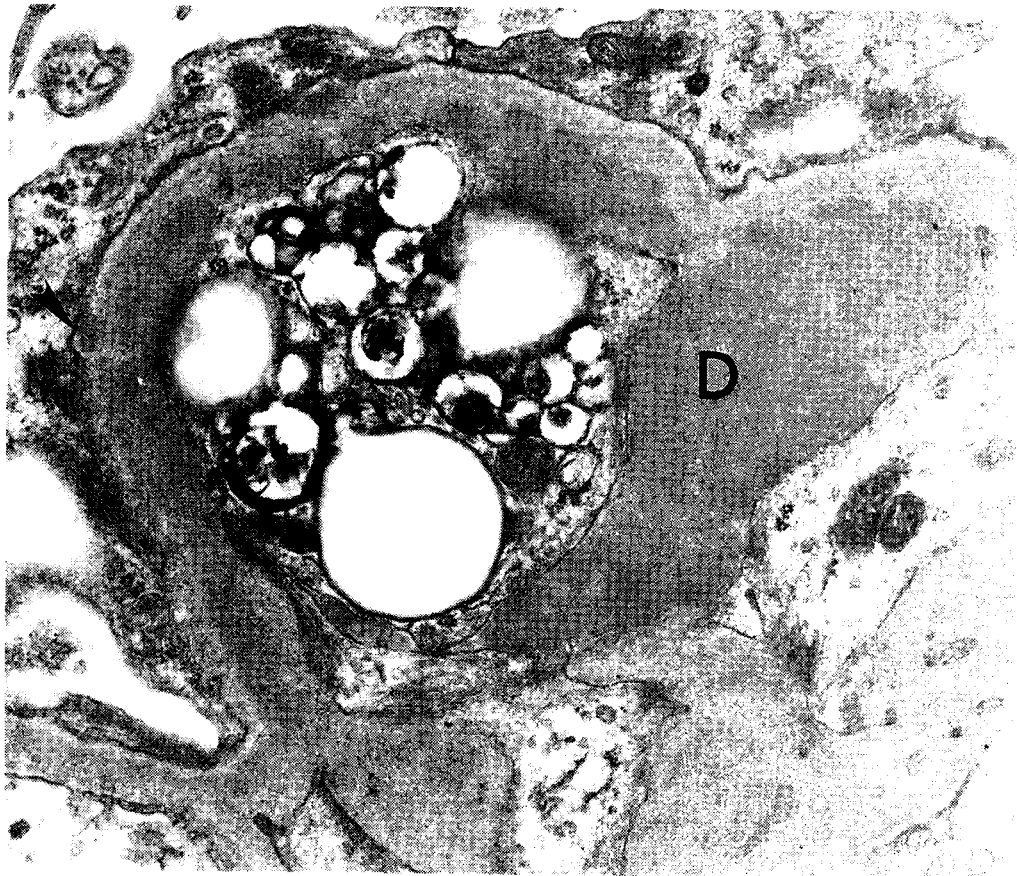


Fig. 2. Electron micrograph of a portion of a glomerulus showing heavy mesangial electron-dense deposits (D). Fingerprint structures are discernible at this magnification. An isometric subepithelial deposit (arrow head) also shows fingerprint organization (x24,000).



Fig. 3. Same glomerulus as in Figure 2 showing bundles of curved electron-dense bands with fingerprint patterns. EM (x39,000).

## DISCUSSION

A fingerprint-like substructural organization of deposits in glomeruli has been considered characteristic of lupus nephritis (Grishman *et al.* 1967), although very rarely has it been observed in other glomerular diseases. We found such deposits in a patient with HBV-associated MPGN. To make a diagnosis of HBV-associated nephropathy, demonstration of HBV antigenic material within the glomeruli of patients is necessary. While glomerular HBe Ag staining was noted in some patients with HBV-associated MN (Hirose *et al.* 1984, Lee and Koh 1989), no antigenic material was shown in cases with HBV-associated MPGN using monoclonal anti-HBs, anti-HBc and anti-HBe (Lee *et al.* 1988). Even though HBV antigenic material was not demonstrable within the glomeruli, the etiologic role of HBV infection in MPGN cannot be excluded. In fact, 88% of the adults with MPGN were HBs Ag carriers in South Korea (Lee *et al.* 1988). In this regard, this case was diagnosed as having HBV-associated MPGN.

Our patient is still being followed three years after biopsy, and there is no evidence to suggest the presence of SLE or other connective tissue disease. Experimentally, the lesions have been produced in animals featuring lupus-like nephritis (Okumura *et al.* 1973) or as part of the host versus graft syndrome (Hard *et al.* 1973). Although these lesions in glomeruli seem to represent the structural organization of immune deposits, it is unclear which factors are related to the alteration of immune deposits.

Ultrastructural examination of mixed IgG-IgM cryoprecipitates from human serum have occasionally showed similar patterns (Stoebner *et al.* 1979). Single IgG kappa lambda 1,3 cryoglobulins, in particular, tended to form filamentous condensation (Stoebner *et al.* 1979). Kim *et al.* (1981) observed fingerprint structures in both the cryoprecipitate and glomerular deposits from a patient with SLE, suggesting that such deposits in lupus nephritis may be

due to the deposition of cryoglobulins. Yet, our case showed no cryoprecipitate in the serum, thus not substantiating the role of cryoglobulins in the genesis of fingerprint deposits.

While most glomerular fingerprint deposits are extracellularly located corresponding to the electron-dense immune deposits, similar structures have also been described within cells of the glomerulus (Zollinger *et al.* 1978) or different organs (Biava *et al.* 1965; Kurokawa *et al.* 1985; Chou *et al.* 1984) and have been interpreted as crystallized lipoprotein (Zollinger *et al.* 1978) or lipofuscin (Biava *et al.* 1965; Kurokawa *et al.* 1984).

The fingerprint structures have been noted in a few cases with SLE in relation to straight or curved tubules which resemble the filamentous forms of reoviruses (Churg *et al.* 1972; Fresco 1970). However, it is doubtful that they are viral in origin. Although there is no hard evidence for the viral-induced pathogenesis of SLE, Christian (1983) suggested that a virus may trigger the activity of the disease leading to syndrome variation in individual patients with SLE. If the subsets of SLE have different etiologies including viral (Christian 1983), we may assume that viruses can play a role in the formation of fingerprint deposits in the limited group of patients with SLE. Further, the presence of these deposits in our patient with HBV-associated MPGN supports the assumption that persistence of virus or viral-associated antigen may be related to the structural alteration of immune deposits to produce fingerprint patterns.

In sum, we demonstrated fingerprint deposits in a case with HBV-associated MPGN. The possible role of a virus in the pathogenesis of these lesions is suggested.

## REFERENCES

- Alpers CE, Hopper J, Bernstein MJ, Biava CG. Late development of systemic lupus erythematosus in patients with glomerular "fingerprint" deposits. *Ann Int Med* 1984; 100:66-8

- Biava C, West M. Lipofuscin-like granules in vascular smooth muscle and juxtaglomerular cells of human kidneys. *Am J Pathol* 1965; 47:287-313
- Chou C-T, Schumacher R. Clinical and pathologic studies of synovitis in polymyalgia rheumatica. *Arthritis Rheum* 1984; 27:1107-17
- Christian CL. Role of viruses in etiology of systemic lupus erythematosus, in Hayslett JP, Hardin JA (eds). *Advances in systemic lupus erythematosus*. Grune and Stratton, New York, NY, 1983: pp 18-22
- Churg J, Grishman E. Ultrastructure of immune deposits in renal glomeruli. *Ann Int Med* 1972; 76:479-86
- Davis BK, Cavallo T. Membranoproliferative glomerulonephritis. Localization of early components of complement in glomerular deposits. *Am J Pathol* 1976; 84:283-98
- Fresco R. Virus-like particles in systemic lupus erythematosus. *N Engl J Med* 1970; 283: 1231-2
- Grishman E, Porush JC, Rosen SM, Churg J. Lupus nephritis with organized deposits in the kidneys. *Lab Invest* 1967; 16:717-25
- Hard RC, Moncure CW, Still WJS. Renal lesions with organized deposits and lipid as part of the host versus graft syndrome in parent/F1, mouse chimeras. *Lab Invest* 1973; 28:468-76
- Hirose H, Udo K, Kojima M, Takahashi Y, Miyakawa Y, Miyamoto K, Yoshizawa H, Mayumi M. Deposition of hepatitis Be antigen in membranous glomerulonephritis : Identification by F(ab')<sub>2</sub> fragments of monoclonal antibody. *Kidney Int* 1984; 26:338-41
- Kim YH, Choi YJ, Reiner L. Ultrastructural "fingerprint" in cryoprecipitate and glomerular deposits: a case report of systemic lupus erythematosus. *Hum Pathol* 1981; 12:86-9
- Kurokawa Y, Ueno T, Nakamura N. Deposits of neuronal ceroid-lipofuscinosis in transitional structures - electron microscopic study. *Folia Psychiat Neurol Jpn* 1985; 39:537-42
- Lee HS, Choi Y, Yu SH, Koh HI, Ko KW. A renal biopsy study of hepatitis B virus-associated nephropathy in Korea. *Kidney Int* 1988; 34:537-43
- Lee HS, Koh HI. Hepatitis Be antigen-associated membranous nephropathy. *Nephron* 1989; 52: 356-9
- Okumura K. Induction of disease resembling systemic lupus erythematosus in C57B/6J mice by prolonged immunization with egg albumin. *Acta Path Jap* 1973; 23:695-704
- Spargo BH, Seymour AE, Ordonez NG. *Renal biopsy pathology with diagnostic and therapeutic implications*. John Wiley and Sons, New York 1980: pp 152-76
- Stoebner P, Renversez JC, Groulade J, Vialtel P, Cordonnier D. Ultrastructural study of human IgG and IgG-IgM crystalcryoglobulins. *Am J Clin Pathol* 1979; 71:404-10
- Zollinger HU, Mihatsch MJ. *Renal pathology in biopsy*. Springer-Verlag, Berlin-Heidelberg-New York, 1978; pp 92-6