

Effect of Apneic Oxygenation via Nasal Prong on Gas Exchange and Vital Signs during Fiberoptic Intubation under General Anesthesia

Sang Chul Lee, Kwang Won Yum* and Kwang Woo Kim

Department of Anesthesiology, Seoul National University College of Medicine,

Seoul 110-744, Korea and

Department of Oral-Maxillofacial Surgery, Seoul National University College of Dentistry,*

Seoul 110-744, Korea

=Abstract=A clinical study for the evaluation of the effect of apneic oxygenation by nasal prong during fiberoptic orotracheal intubation on gas exchange and vital signs has been done on the patients who received tympanomastoidectomy (ASA classification 1 and 2, aged from 20 to 40). Among them, 22 patients were selected whose fiberoptic intubation lasted more than 3 but less than 4 minutes, to observe the changes of PaO₂, PaCO₂, HR, and MAP. 11 patients who underwent fiberoptic orotracheal intubation in apneic state without oxygen administration (Group I) showed similar increases in vital signs to the other 11 patients who received apneic oxygenation (Group II). PaCO₂ increased more in Group I than in Group II, which was not statistically significant. The differences of PaO₂ at 1 and 2 minutes between two groups after removal of oxygen mask and beginning of fiberoptic intubation, were not statistically significant but Group II showed a significantly lesser degree of decrease in PaO₂ at 3 minutes.

We might say that apneic oxygenation during fiberoptic intubation under general anesthesia is useful because it could delay the onset of hypoxia, thereby provide extra time for intubation. Therefore we could attempt intubation up to 3 minutes on the fully relaxed patient, if we give oxygen via nasal prong.

Key Words: *Apneic oxygenation, Nasal prong, Gas exchange, Vital signs, Fiberoptic intubation*

INTRODUCTION

Flexible fiberoptic laryngoscopy and subsequent intubation is a useful method for establishing a safe airway. It is now so important and essential to the administration of high quality anesthesia and intensive care that

every anesthesiologist should know how to perform this technique and when to use rather than reserved for patients in whom rigid techniques have proven to be unsuccessful. There are multiple reasons why fiberoptic equipment improves anesthetic care. First, fiberoptic endoscopy-aided single lumen endotracheal tube intubation in the awake or generally anesthetized patient is recognized as an indispensable tool in the management of the difficult airway. Second, fiberoptic bronchoscopy is considered by most authorities to be the best way to confirm proper position of

Received January 1992, and in final form March 1992.

서울대학교 의과대학 마취과학교실 : 이상철, 김광우
서울대학교 치과대학 구강외과학교실 : 염광원

double lumen tubes and bronchial blockers and endobronchial location of single lumen tubes. Third, fiberoptic bronchoscopy is an extremely important diagnostic tool, both in the operating room and intensive care unit for such conditions as obstructed airways and airway burns. Fourth, fiberoptic bronchoscope permits precise therapeutic lavage, suctioning and reinflation of any specific and/or all parts of the airways.

Fiberoptic laryngoscopy can be performed with relative ease on a patient having a general anesthetic, as long as the following cautions are kept in mind. First, as the patient under a general anesthetic has lost the ability to maintain his own airway, a second pair of hands is often necessary. Second, patients breathing spontaneously under a general inhalational anesthetic still have reactive vocal cords, and may have laryngospasm as the laryngoscope is advanced towards the glottic opening, thus obscuring the view. Third, the patient who has received a full dose of a neuromuscular blocking drug will not be able to oppose his vocal cords, eliminating laryngospasm as an impedance to intubation.

In general, it has been said that attempts at intubating a fully relaxed patient should probably be kept to under 2 minutes (Imai and Kemmotsu 1989). It has been also known that the risk of hypoxia is lessened if oxygen is constantly flowing to the apneic patients (Lehnert *et al.* 1982; Smith *et al.* 1984; Babinski *et al.* 1984; Mackenzie *et al.* 1985; Babinski *et al.* 1985). But there has been no study about the effect of oxygen administration by continuous flow through nasal prong during fiberoptic laryngoscopy under general anesthesia. There is a possibility that apneic oxygenation via nasal prong during fiberoptic laryngoscopy would not give any advantage over the method without oxygen administration, because there is a remarkable distance from the nose to the inlet of the trachea and oxygen flow through nasal prong might be blocked anywhere in the passage to the lung especially in anesthetized patients because of the variable anomalies in

anatomy and the relaxed soft tissues due to deep anesthesia and muscle relaxation.

This study was undertaken to evaluate the effect of oxygen administration via nasal prong during fiberoptic intubation in anesthetized patients through comparing the changes of arterial oxygen tension (PaO_2), arterial carbon dioxide tension (PaCO_2), mean arterial pressure (MAP) and heart rate (HR), thereby showing whether apneic oxygenation during fiberoptic laryngoscopy gives any advantage in improving oxygenation and CO_2 elimination.

MATERIALS AND METHODS

We performed fiberoptic laryngoscopy routinely on every patients who belonged to ASA classification 1 and 2, aged between 20-40, who received elective tympanomastoidectomy due to chronic otitis media at Seoul National University Hospital. Patients taking antihypertensive medication and those with reflux, morbid obesity and airway problems including significant histories of tobacco use were excluded. We usually divided the patients into two groups. The first group (Group I) underwent fiberoptic orotracheal intubation in apneic state without O_2 administration after removal of oxygen mask ventilation, while the other group (Group II) underwent fiberoptic orotracheal intubation with apneic oxygenation of O_2 5 l/min administration via nasal prong just after removal of oxygen mask ventilation. Among them, we selected 22 patients whose fiberoptic intubations lasted more than 3 minutes but less than 4 minutes (Group I; 11 patients, Group II; 11 patients).

All patients were premedicated one and a half hours prior to operation with the usual doses of lorazepam and glycopyrrolate intramuscularly. Continuous EKG monitoring was established after arrival in the operating room. The radial artery was cannulated with 20G teflon catheter. The arterial blood pressure was monitored continuously and the sampling for arterial blood gas analysis was collected from it throughout the whole experiment. Pulse

oximetry was applied to the thumb of the patient to prevent a dangerous drop in arterial oxygen saturation during apneic fiberoptic intubation. If the SaO₂ fell below 90%, the experiment was stopped and the patient was ventilated artificially with 100% oxygen.

Pentothal 4-5mg/kg was given to the patients intravenously after a testing dose to induce anesthesia. As soon as manual ventilation with a face mask was considered satisfactory, vecuronium 0.1mg/kg was given. The controlled ventilation with 100% O₂ and 2-3 vol% isoflurane mixture was given for at least 5 minutes to make the patient relaxed completely for intubation. Fiberoptic intubation was done with the patient in supine position and the operator standing just above the head of the patient. After the endotracheal tube (internal diameter 7.0 for male and 6.5 for female) was mounted on it, the fiberoptic laryngoscope was advanced via mouth opening to the tracheal inlet with the jaw pulled forward by an assistant to widen the retropharyngeal space. After entrance into the trachea, the tip of the fiberoptic laryngoscope was positioned above the carina and the endotracheal tube was slowly and carefully advanced into the trachea. As the endotracheal tube was properly positioned, the fiberoptic laryngoscope was removed gently.

At the time just before the removal of the oxygen mask (control value: V_c), and 1 minute (V₁), 2 minutes (V₂) and 3 minutes (V₃) after removal of oxygen mask, HR and MAP were measured by a KM 5000-Patient Monitor (KOLON) and the sampling of arterial blood was done. Blood gas analysis was done by STAT Profile 5 (NOVA Biomedical). The averages of the measured parameters were arranged as mean ± standard deviation. Differences between two groups were compared by paired t-test and p < 0.05 was considered statistically significant.

RESULTS

There was a similar increasing tendency in MAP and HR after removal of the oxygen mask

in both groups compared with the value just before removal of the oxygen mask (Fig. 1, 2). The greatest increases in MAP and HR occurred at 3 minutes after removal of the oxygen mask (Table 1). PaO₂ decreased from 477.4 ± 60.17mmHg (V_c) to 253 ± 82.7mmHg (V₃) in Group I, while it decreased from 489.7 ± 47.36mmHg (V_c) to 348.4 ± 76.57mmHg (V₃) in Group II (Table 1, Fig. 3).

Table 1. Changes of vital signs and gas exchange during fiberoptic intubation under general anesthesia

time group	MAP	HR	PaO ₂	PaCO ₂
0 I	77.6±14.0	92.5±10.0	477±60	34.8±6.1
0 II	83.0±14.1	89.7±14.1	490±47	35.6±3.4
1min I	103.9±21.1	104.0±13.7	439±58	44.2±7.5
1min II	96.2±13.5	98.2±18.8	448±58	41.6±3.8
2min I	108.0±18.3	105.2±12.5	348±85	49.2±8.4
2min II	116.4±15.1	101.5±13.3	400±65	45.1±4.6
3min I	112.5±23.3	108.1±17.3	253±83	53.4±9.3
3min II	123.4±13.9	109.4±21.5	348±77*	47.7±4.7

Data are mean ± S.D.

Group 1: without oxygen administration

Group 2: with oxygen administration

* p < 0.05 compared with group 1

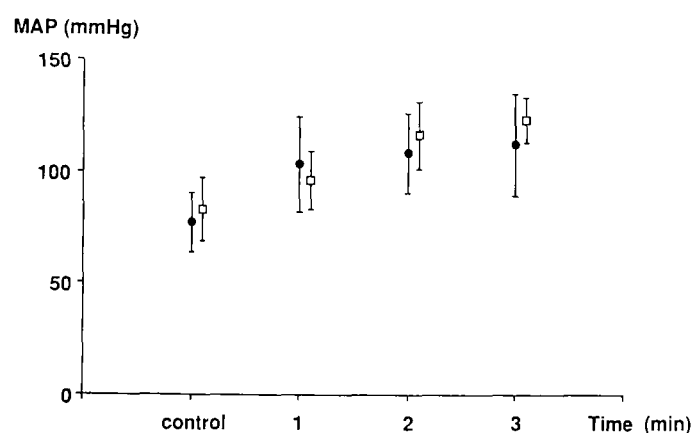


Fig. 1. Mean arterial pressure (MAP) changes during flexible fiberoptic orotracheal intubation under general anesthesia.

Data are mean ± S.D.

● ; without oxygen

□ ; with apneic oxygenation (5 l/min)

The differences between two groups were not significant.

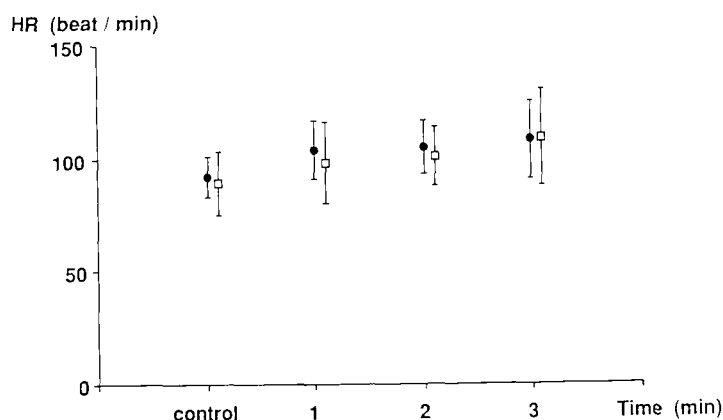


Fig. 2. Heart rate (HR) changes during flexible fiberoptic orotracheal intubation under general anesthesia. Data are mean \pm S.D. ● ; without oxygen □ ; with apneic oxygenation (5 l/min) The differences between two groups were not significant.

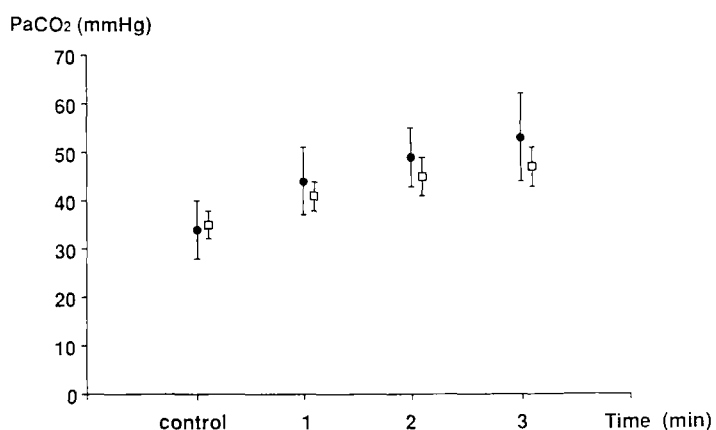


Fig. 4. Arterial carbon dioxide tension (PaCO₂) changes during flexible fiberoptic orotracheal intubation under general anesthesia. Data are mean \pm S.D. ● ; without oxygen □ ; with apneic oxygenation (5 l/min) The differences between two groups were not significant.

PaCO₂ increased from 34.8 ± 6.06 mmHg (V_c) to 53.4 ± 9.32 mmHg (V₃) in Group I and increased from 40.6 ± 3.88 mmHg (V_c) to 52.7 ± 4.71 mmHg (V₃) in Group II. Group II revealed a lesser degree of increase of PaCO₂ than group I, even though this was not statistically significant (Table 1, Fig. 4).

There was no significant difference between the two groups in MAP, HR, and PaCO₂. The differences of PaO₂ at 1 and 2 minutes between the two groups were not statistically significant except only the difference at 3 minutes after removal of the oxygen mask showed a statistical significance ($p < 0.05$).

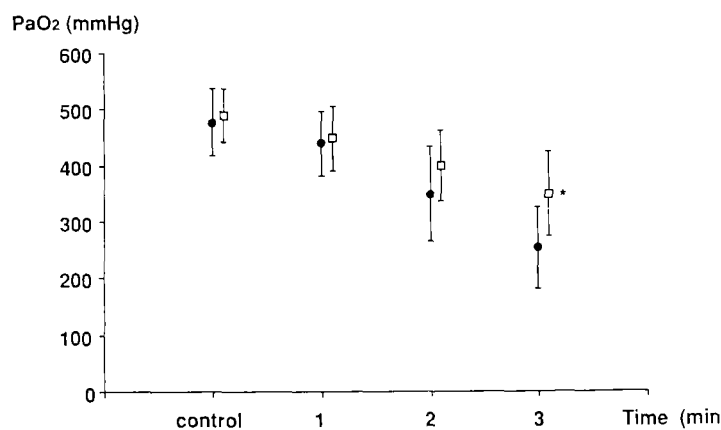


Fig. 3. Arterial oxygen tension (PaO₂) changes during flexible orotracheal intubation under general anesthesia. Data are mean \pm S.D. ● ; without oxygen □ ; with apneic oxygenation (5 l/min) ★ ; $p < 0.05$ comparing with the group without oxygenation.

DISCUSSION

Some anesthesiologists recommended fiberoptic intubation under general anesthesia for the purpose of preventing the cardiovascular response by awake intubation to the patients with increased intracranial pressure or severe hypertension. In our experiment, there was a similar increasing tendency in MAP and HR during fiberoptic intubation under general anesthesia. The degrees of increase were not less than those of the previous studies which were done at our department during awake intubation or rigid technique (Lee and Kim 1985; Oh *et al.* 1990). We could suggest that fiberoptic intubation under general anesthesia would not cause lesser activation of sympathetic nervous system activity during intubation.

Therefore we have to pay special attention when we use this technique as well as with other techniques.

Several methods have been tried to improve oxygenation and carbon dioxide elimination for the procedures in which we could not adequately ventilate the patients. Successful ventilation with a continuous flow of air without respiratory movement was described in dogs by Meltzer and Auer in 1909. Draper and Whitehead (1944) described the successful use of diffusion respiration in dogs, but there was alveolar accumulation of carbon dioxide. In 1946, Comroe and Dripps demonstrated accumulation of carbon dioxide in comatose human subjects using this technique with an oxygen flow as high as 11 l/min into the trachea. Enghoff *et al.* (1951) were the first to introduce diffusion respiration in anesthetized patients, using oxygen at an FIO_2 of 1.0 for ten minutes through a cuffed tracheal tube. An extensive review on the subject of diffusion respiration was presented by Holmdahl in 1956, who introduced apneic diffusion oxygenation (ADO). ADO was used by Frumin *et al.* (1959) and Payne (1962), who observed severe respiratory acidosis in the presence of adequate oxygenation.

Introduction and development of high frequency ventilation (Lunkenheimer *et al.* 1972; Klain and Smith 1977) has renewed interest in the mechanism of gas exchange, particularly using tidal volumes less than dead space. Lehnert *et al.* (1982) studied constant flow endobronchial air ventilation in four apneic dogs. They found normal blood gases could be obtained for as long as 2 hours. We could apply this new methods of gas exchange without respiratory movement for cardiac surgery, pneumonectomy, tracheal or bronchial surgery and treatment of acute respiratory distress syndrome. But because the placement of a catheter into the tracheal lumen is needed for this high frequency ventilation, we could not use it for fiberoptic intubation to improve oxygenation.

In this experiment, we selected the method administering oxygen via nasal prong which is the most simple way we could use anywhere.

This method may not have any advantage over an apneic state without oxygenation because the distance from the nostril to each alveoli is so far and the soft tissue could obstruct the airway under general anesthesia at any time due to relaxation. Also, we used only 5 l/min which was much less than those of other studies to evaluate whether the easy and routinely performed procedure could offer any merits during fiberoptic intubation under general anesthesia.

Because alveolar gas tension is proportional to mixed venous blood gas tension in apneic state, PCO_2 increases and PO_2 decreases (Fraoli *et al.* 1973; Holmdahl 1956). Besides, the general anesthesia usually increases alveolar dead space and shunt, which might have made the situation worse in this experiment. The volume of gas which crosses the alveolar-capillary membrane is proportional to the tension of that gas. The increase of the alveolar oxygen tension by the constant oxygen flow into the alveoli during apneic state might increase the volume of the gas crossing the alveolar-capillary membrane and also improve the elimination of carbon dioxide from capillary blood. But carbon dioxide elimination appears to be related to gas velocity, elimination being increased with increasing velocities and volumes. Therefore we have to give a large volume of oxygen to the alveoli, if we want to improve CO_2 elimination.

From the studies of Frumin *et al.* (1959) and Eger and Severinghaus (1961), the mean rate of rise of $PaCO_2$ in apneic anesthetized man was found to be 3.8 mmHg/min. Group II showed a similar increase of carbon dioxide tension to other studies but Group I revealed more increase than the expected values which might also show the advantage of oxygen administration. Even though it was not statistically significant, if we use more volume of oxygen, we might observe a lesser degree of increase in carbon dioxide tension under similar experimental condition.

There was an interesting report by Mackenzie *et al.* (1985) who observed no advan-

tage in carbon dioxide removal in pigs compared to apneic oxygenation in dogs, which may be due to the species anatomic differences, i. e. pig lungs are lobulated with septa and are without collateral airways. Their result suggest that endobronchial insufflation with or without oxygen supplementation may be an effective means of oxygenation and carbon dioxide removal in humans with COPD but not in neonates. More studies are needed to clarify this complicated issue.

The morbidly obese patient showed a more rapid development of the fall of arterial oxygen saturation comparing with the normal weight person, which is due to low FRC in the obese patient (Jense *et al.* 1988). Therefore we excluded the obesity and other conditions that could have effect on FRC and other respiratory parameters.

Gambee *et al.* (1987) observed the increase in the safety interval until hypoxia occurred during intubation when enough denitrogenation was done with 100% oxygen because the oxygen tension and the degree of denitrogenation at the beginning of apnea had a serious effect on the onset time of hypoxia. We used at least 5 minutes of preoxygenation before trying intubation to improve oxygenation in our practice including this study.

Teller *et al.* (1988) reported that oxygen insufflation via nasopharyngeal cannula (3 l/min) provided at least ten minutes of adequate oxygenation in unintubated, denitrogenated, apneic patients whose airways are unobstructed. They suggested that nasopharyngeal oxygen insufflation may be life-saving by providing extra time to obtain control of the airway in a critical situation by significantly delaying the onset of hypoxia. In our experiment, probably because we gave the oxygen through nasal prong which is far from the tracheal introitus and we could not guarantee the patency of the airway from the nasal prong to the tracheal lumen, we had to give up continuing fiberoptic intubation which lasted more than 4 minutes because various kinds of arrhythmia frequently appeared perhaps due to the elevation of ar-

terial carbon dioxide tension. Imai and Kemmotsu (1989) reported that attempts at intubating a fully relaxed patient should be kept under 2 minutes. But we could suggest that attempts at intubating that patient might be kept until until 3 minutes because our study showed relatively tolerable values of PaO₂, PaCO₂, and vital signs.

The results of our study showed that PaO₂ decreased from 477.4 ± 60.7 torr to 348.4 ± 76.57 torr in Group II. The rate of PaO₂ decrease in Group I was steeper than in Group II as the time went by. The difference of PaO₂ between the two groups at 3 minutes was statistically significant, which was similar to the report of Teller *et al.* (1988). We might say that oxygen administration via nasal prong is helpful in preventing the rapid fall of oxygen tension during fiberoptic intubation in apneic state under general anesthesia even though it was not obviously helpful in improving the elimination of carbon dioxide. At the same time, we can extend intubation time until 3 minutes for attempts on a fully relaxed patient if we administer oxygen via nasal prong.

REFERENCES

- Babinski MF, Sierra OG, Smith RB. Clinical application of continuous flow apneic ventilation. *Acta Anaesth Scand* 1985; 29:750-6
- Babinski MF, Smith RB, Bunegin L. Normocapnia after five hours of continuous flow apneic ventilation in dogs. *Anesthesiology* 1984; 61:A510
- Comroe JH, Jr., Dripps RD. Artificial respiration *J Am Med Assoc* 1946; 130:381-3
- Draper WB, Whitehead RW. Diffusion respiration in the dog anesthetized by pentothal sodium. *Anesthesiology* 1944; 5:262-73
- Enghoff H, Holmdahl MH, Fisholm L. Diffusion respiration in man. *Nature* 1951; 168:830
- Fraioli RL, Sheffer LA, Steffenson JL. Pulmonary and cardiovascular effects of oxygenation in man. *Anesthesiology* 1973; 39:588-95
- Frumin MJ, Epstein RM, Cohen G. Apneic oxygenation in man. *Anesthesiology* 1959; 20:

- 789-98
- Gambee AM, Robert RE, Fisher DM. Preoxygenation techniques: Comparison of three minutes and four breaths. *Anesth Analg* 1987; 66:468-70
- Holmdahl MH. Pulmonary uptake of oxygen, acid-base metabolism, and circulation during prolonged apnea. *Acta Chir Scand* 1956; 212(Suppl):128
- Imai M, Kemmotsu W. Anesthesia adapter for fiberoptic endotracheal intubation for anesthetized patients. *Anesthesiology* 1989; 70:374-8
- Klain M, Smith RB. High frequency percussive transtracheal jet ventilation. *Crit Care Med* 1977; 5:280-7
- Lee SC, Kim SD. The effect of endotracheal intubation and intravenous lidocaine on blood pressure and pulse rate during induction of anesthesia. *Human Science* 1985; 9:575-83
- Lehnert BE, Oberdorster G, Stutsky AS. Constant flow ventilation of apneic dogs. *J Appl Physiol* 1982; 53:483-9
- Lunkenheimer PP, Raffleneul W, Keller H, Frank I, Dickhut HH, Fuhrmann C. Application of transtracheal pressure-oscillations as a modification of "diffusion respiration". *Br J Anaesth* 1972; 44:627
- Mackenzie CF, Shin B, Takeda J, Haris M, Helrich M. Comparison of gas exchange during endobronchial insufflation and apneic oxygenation. *Anesthesiology* 1985; 63:A527
- Meltzer SJ, Auer J. Continuous respiration without respiratory movements. *J Exp Med* 1909; 11:622-5
- Oh YS, Kim JW, Do SH, Lee KH, Yum KW. Clinical study on fiberoptic awake intubation and self pronation in cervical spine disease patients. *J Kor Soc Anesthesiol* 1990; 23:714-8
- Payne JP. Apnoeic oxygenation in anaesthetized man. *Acta Anaesthesiol Scand* 1962; 6:129-42
- Smith RB, Babinski MF, Bunegin L. Continuous flow apneic ventilation. *Acta Anaesth Scand* 1984; 28:631-6
- Teller LE, Alexander CM, Gross JB, Frumin MJ. Nasopharyngeal insufflation of oxygen prevents hypoxia in apneic patients. *Anesthesiology* 1988; 69:A729