

^{111}In Antimyosin Monoclonal Antibody in the Detection of Doxorubicin Cardiotoxicity: a Comparison with Histology and $^{99\text{m}}\text{Tc}$ Pyrophosphate[†]

Myung Chul Lee, June-Key Chung, Dong Soo Lee and Chang-Soon Koh

Department of Internal Medicine, Seoul National University College of Medicine, Seoul 110-744, Korea

= Abstract = **Recently, ^{111}In -antimyosin monoclonal antibodies (^{111}In -AMAb) have been introduced for the diagnosis of myocardial infarction. The purpose of this study was to investigate the feasibility of using this agent for the early detection of cardiac damage induced by doxorubicin. The degree of drug induced change in the myocardium was evaluated histologically. $^{99\text{m}}\text{Tc}$ pyrophosphate ($^{99\text{m}}\text{Tc}$ -PYP), known to preferentially accumulate in Adriamycin caused lesions, was used as a control radiopharmaceutical. Myocardial uptake of ^{111}In -AMAb and $^{99\text{m}}\text{Tc}$ -PYP was measured in 12 controls and 10 Adriamycin treated rabbits. The results indicated the following: 1) ^{111}In -AMAb uptake in the heart correlated well with the degree of pathology ($r=0.95$); 2) $^{99\text{m}}\text{Tc}$ -PYP uptake was also correlated with cardiac damage ($r=0.77$); 3) The uptake ratio (expressed as percent injected dose per gram myocardial tissue) of Adriamycin treated animals vs. controls was 2.7:1 for ^{111}In -AMAb and 9.2 for $^{99\text{m}}\text{Tc}$ -PYP nt 24 and 2 hours after intravenous injection, respectively; 4) considerable non-specific $^{99\text{m}}\text{Tc}$ -PYP accumulation was measured in the lungs and kidneys and was significantly higher in drug treated animals compared to controls. ^{111}In -AMAb accumulation remained unchanged in these organs. We conclude that ^{111}In -AMAb accurately detects cardiac toxicity induced by Adriamycin but that $^{99\text{m}}\text{Tc}$ -PYP still remains an acceptable agent in part because, of its availability and higher tracer concentration in the cardiac lesions.**

Key Words: ^{111}In -antimyosin monoclonal antibody, Adriamycin cardiac toxicity, $^{99\text{m}}\text{Tc}$ -pyrophosphate

INTRODUCTION

Received March 1993, and in final form June 1993.

[†] Supported by Grant No. 02-91-177 from the Seoul National University Hospital Research Fund

서울대학교 의과대학 내과학교실: 이명철, 정준기, 이동수, 고창순

Adriamycin (Doxorubicin hydrochloride), an anthracycline antibiotic, is a highly effective and commonly used chemotherapeutic agent. However, it can cause a severe and fatal form of

delayed irreversible cardiotoxicity. There is no reliable method to predict clinically significant cardiac toxicity and the pathogenic mechanism of Adriamycin induced cardiomyopathy has not been elucidated. Some investigators have utilized left ventricular ejection fraction to determine cardiotoxicity but the method is insensitive because myocardial damage must already be extensively present to depress global function for definite detection.

Infarct-avid radiopharmaceuticals such as ^{99m}Tc -pyrophosphate (PYP) and a newly developed agent, radiolabeled antimyosin antibody (AMAb) have been shown to be useful for the detection of myocardial injury and are used commonly in the diagnosis of acute myocardial infarction (Khaw *et al.* 1976; Khaw *et al.* 1978; Parkley *et al.* 1974; Botvinick *et al.* 1975; Khaw *et al.* 1980; Beller *et al.* 1977; Lee *et al.* 1991).

The purpose of this investigation was to determine the accumulation of ^{111}In -antimyosin monoclonal antibody in rabbit myocardium with experimentally induced cardiac damage caused by the intravenous administration of Adriamycin at doses previously felt to be subtoxic and to compare these results with those of ^{99m}Tc -pyrophosphate accumulation and histologic findings in the same animal.

MATERIALS AND METHODS

The monoclonal antimyosin antibody used in this study was a Fab fragment of IgG derived from BALB/c mice (R11D10), having specific affinity to human cardiac myosin. Two mCi of $^{111}\text{In}-\text{Cl}_3$ were added to an aliquot of 0.5mg of DTPA-R11D10 Fab in 0.1 M citrate buffer (pH 5.0). The reaction mixture was gently mixed at room temperature for 10 minutes. Before administration the labeled antibody was filtered through 0.22 μm micropore protein binding filter (Gelem). The average ^{111}In binding efficiency, measured by Sephadex column chromatography was 90%.

This study was performed in twenty-two

mature New Zealand White rabbits weighing between 8 to 10 pounds. Ten drug treated and 12 control rabbits were used. The treated group of animals received 2.5 mg/kg Adriamycin by intravenous injection once each week for 4 weeks via the marginal ear vein while the control group received the same volume of 0.9% saline solution. Adriamycin was freshly prepared before each injection.

All animals were injected with 40-50 μCi of ^{111}In -antimyosin antibody at 24 hours before scheduled sacrifice and 200-250 μCi of ^{99m}Tc -pyrophosphate at 2 hours before sacrifice. At the end of the experiment, the rabbits were sacrificed by intravenous injection of 120mg of pentobarbitol. The heart was divided into left ventricle, right ventricle, septum and atrial portions and multiple transmural myocardial specimens were obtained. Weighed sections of each organ were counted in a well scintillation counter along with appropriate standards. The percentage of injected dose/gm tissue was calculated. Slices of myocardium and kidney were fixed in buffered neutral formalin, embedded in paraffin, and tissue sections were stained with Masson's trichrome and hematoxyline-eosin. The stained sections were examined by light microscopy and assigned a histologic score without knowledge of treatment category by an expert in cardiac pathology. The following scoring system of the myopathic change adopted from Bristow *et al.* (Bristow *et al.* 1981; Bristow *et al.* 1980) was used: Grade 0=normal myocardium, no Adriamycin effect; Grade I=occasional sparse numbers of foci of vacuolated myocytes and/or minimal interstitial fibrosis; Grade II=moderate number of focal myocytes showing vacuolization and/or myofibril loss; Grade III=many generalized affected myocytes showing vacuolization and diffuse interstitial fibrosis.

Statistical analysis of the data was performed using unpaired Student's t test and Spearman's rank correlation coefficient test for nonparametric data (Snedecor and Cochran 1976).

RESULTS

The biodistribution of ^{111}In -AMAb, in control and Adriamycin-treated groups, expressed as % injected dose/gram tissue(%ID/gm) at 24 hours after injection for the heart and each organ, is shown in Table 1. The mean cardiac uptake of ^{111}In -AMAb was 0.021 in the control group and 0.056 in the Adriamycin-treated group. The difference between the two groups was significant($p<0.005$). The ratio of antibody accumulation of Adriamycin-treated over control rabbit based on the %ID/gm cardiac tissue was about 2.7:1. However, for other organs (lungs, kidneys, liver, spleen and bone) there was little difference between the two groups. Figure 1 presents the distribution of individual data of %ID/gm in each portion of the heart(left ventricle, right ventricle, septum and atrium). In all samples there was a significant increase of ^{111}In -AMAb accumulation in the Adriamycin-treated group compared with controls. Six of 10 rabbits treated with subtoxic doses of Adriamycin developed damaged hearts and had increased cardiac ^{111}In -AMAb activity which was greater than two standard deviations from the mean of control animals.

Table 2 and Figure 2 demonstrate the results

of the biodistribution of $^{99\text{m}}\text{Tc}$ -pyrophosphate in control versus Adriamycin-treated animals in terms of %ID/gm tissue. Mean values of $^{99\text{m}}\text{Tc}$ -PYP uptake in the heart were 0.006 and 0.055 respectively ($p<0.05$). The distribution of individual data of %ID/gm tissue in each specimen of the heart revealed that 8 of 10 rabbits had an accumulation greater than 2 SD of the mean control value. In addition, the kidney and lung also showed significantly higher pyrophosphate uptake in Adriamycin-treated animals. The higher percent uptake of $^{99\text{m}}\text{Tc}$ -PYP in the kidney and lung may correlate with Adriamycin induced renal toxicity and congestive heart failure, respectively.

The histologic changes in the hearts of 15 Adriamycin treated animals were correlated with biodistribution results. As shown in Figures 3 and 4, qualitatively similar findings were observed in these rabbits. There was a strong relationship between both ^{111}In -AMAb and $^{99\text{m}}\text{Tc}$ -PYP uptake and the severity of myocardial damage by microscopic examinations. By Spearman's rank correlation coefficient (r) between ^{111}In -AMAb and histologic grading was 0.95 which was statistically significant ($p<0.001$) and better than the r value between $^{99\text{m}}\text{Tc}$ -PYP and histologic grading which was 0.77 with a statistical significance of $p<0.005$.

Interestingly, there were two rabbits in the

Table 1. Biodistribution of ^{111}In -antimyosin antibody in control and adriamycin-treated groups (Mean \pm 1 SEM)

Organ	% Dose/g tissue at 2 hrs after injection		p value
	Control (n=12)	Adriamycin (n=10)	
Heart	0.021 \pm 0.002	0.056 \pm 0.010	<0.005
Left Ventricle	0.020 \pm 0.002	0.063 \pm 0.010	<0.001
Right Ventricle	0.022 \pm 0.003	0.052 \pm 0.011	<0.01
Septum	0.021 \pm 0.002	0.062 \pm 0.012	<0.005
Atrium	0.023 \pm 0.002	0.050 \pm 0.009	<0.01
Lungs	0.028 \pm 0.002	0.033 \pm 0.003	NS
Kidneys	0.635 \pm 0.069	0.697 \pm 0.114	NS
Liver	0.106 \pm 0.005	0.121 \pm 0.011	NS
Spleen	0.115 \pm 0.008	0.123 \pm 0.017	NS
Rib	0.034 \pm 0.007	0.027 \pm 0.007	NS

NS; not significant

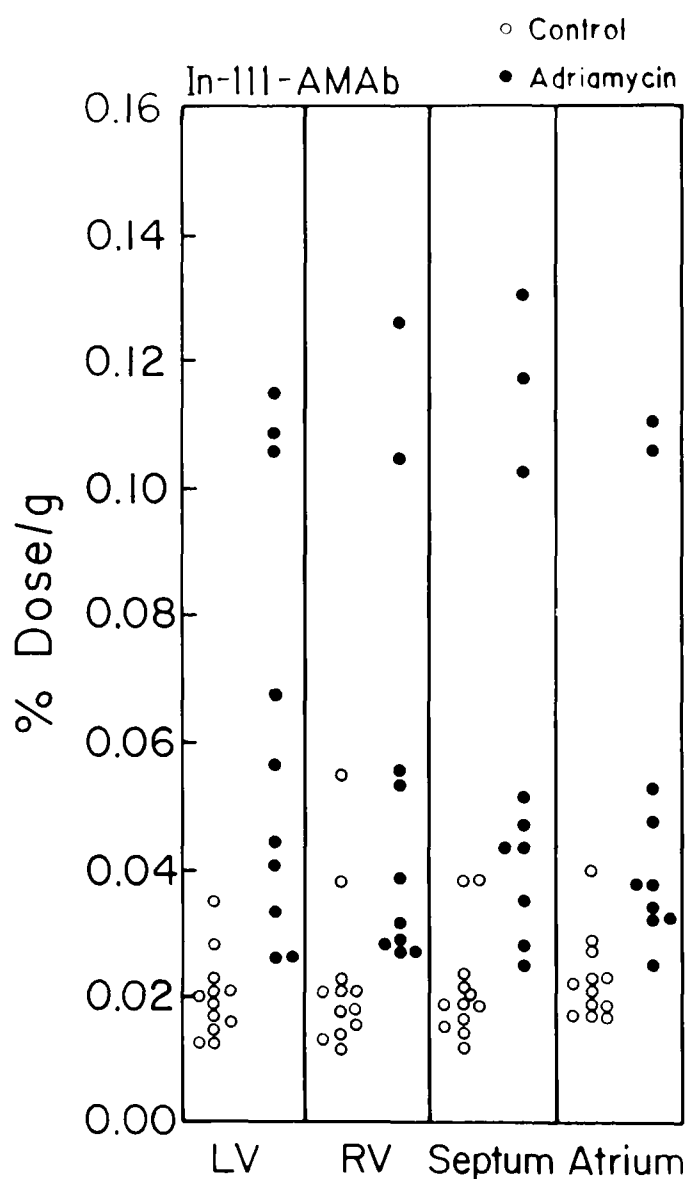


Fig. 1. Distribution of ¹¹¹In-AMAb (ID%/gm) in each portion of the heart.

Adriamycin treated group which showed normal PYP accumulation despite the abnormal histology and one rabbit that showed mild ¹¹¹In-AMAb uptake despite normal histology.

DISCUSSION

Doxocubicin hydrochloride (Adriamycin) has been clearly shown to be one of the most effective antitumor drugs in cancer chemotherapy (Bulum and Carter 1975; Benjamin *et al.* 1974). Its efficacy appears to depend on high cumulative dosages. However, the major dose-limiting side effect which is unique for this antibiotic is the development of

dose related cardiotoxicity (doxorubicin cardiomyopathy) (Lefrak *et al.* 1973; Rinehart *et al.* 1974). The risk of heart failure has been reported to be negligible at total doses of less than 500 mg/m² (0.27%), but is much more likely to occur at doses above that level. The incidence of symptomatic congestive heart failure is approximately 10% of patients who received 550 to 660mg/m² and 35% of patients who received larger doses (more than 650mg/m²) (Bristow 1982). Up to 50% of patients developing Adriamycin related congestive heart failure die of cardiac causes (Lefrak *et al.* 1975; Cortes *et al.* 1975). Jaenke (Jaenke 1976; Jaenke 1974) has described a similar myocardial syndrome from Adriamycin produced experime tally in rabbits. Gorton (Gorton *et al.* 1980) treated rabbits effectively with a dose of 14.4 mg/kg (158 mg/m²), a level analogous to the 550 mg/m² described as the typically safe human dose.

The recognition of the earliest preclinical stages of doxorubicin induced cardiotoxicity must remain a goal for all physicians using this drug. So far, there is no reliable prediction of clinically significant doxorubicin induced cardiotoxicity. The morphologic changes observed in doxorubicin induced cardiotoxicity consist of: 1) cardiac dilatation and mural thrombosis; 2) degeneration and atrophy of cardiac muscle cells and 3) interstitial edema and fibrosis (Fervans 1978). The degeneration of myocardial cells can be characterized by myofibrillar loss and cytoplasmic vacuolization. As shown in this study, one striking finding is the wide range of histologic change and myocardial antimyosin antibody accumulation in the sub-toxic dose of Adriamycin-treated animals, suggesting differing individual sensitivity to Adriamycin. In fifteen animals examined by microscopy, six rabbits had developed mild myocardial lesions (Grade I), two moderate (Grade II) and only one severe (Grade III) at a total Adriamycin dose of 10 mg/kg. Recently cardiac imaging using radionuclide labeled compounds has proven useful for the detection

Table 2. Biodistribution of ^{99m}Tc-pyrophosphate (PYP) in control and adriamycin-treated groups (Mean ± 1 SEM)

Organ	% Dose/g tissue at 2 hrs after injection		p value
	Control (n=12)	Adriamycin (n=10)	
Heart	0.006 ± 0.0003	0.055 ± 0.022	<0.05
Left Ventricle	0.006 ± 0.0002	0.068 ± 0.027	<0.05
Right Ventricle	0.007 ± 0.0004	0.078 ± 0.037	<0.05
Septum	0.007 ± 0.0003	0.046 ± 0.018	<0.05
Atrium	0.008 ± 0.0004	0.039 ± 0.012	<0.01
Lungs	0.010 ± 0.001	0.016 ± 0.002	<0.005
Kidneys	0.209 ± 0.018	0.487 ± 0.078	<0.005
Liver	0.008 ± 0.001	0.014 ± 0.004	NS
Spleen	0.008 ± 0.001	0.014 ± 0.004	NS
Rib	0.074 ± 0.018	0.041 ± 0.009	NS

NS; not significant

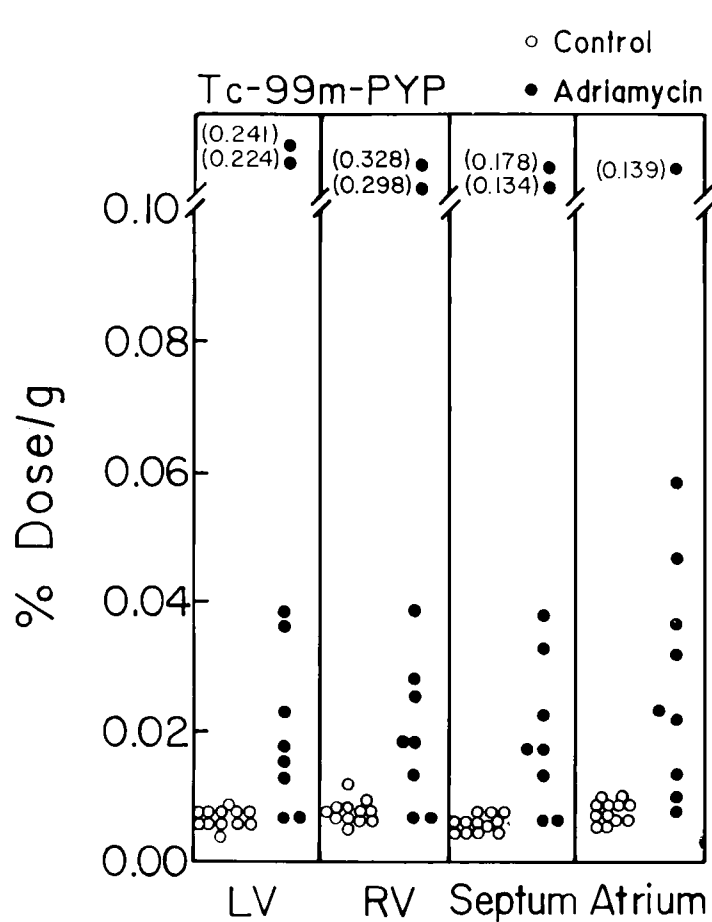


Fig. 2. Distribution of ^{99m}Tc-PYP (ID%/gm) in each portion of the heart.

of myocardial injury. Localization and sizing of acute myocardial infarcts have been done successfully with ^{99m}Tc-tetracycline (Holman *et al.*

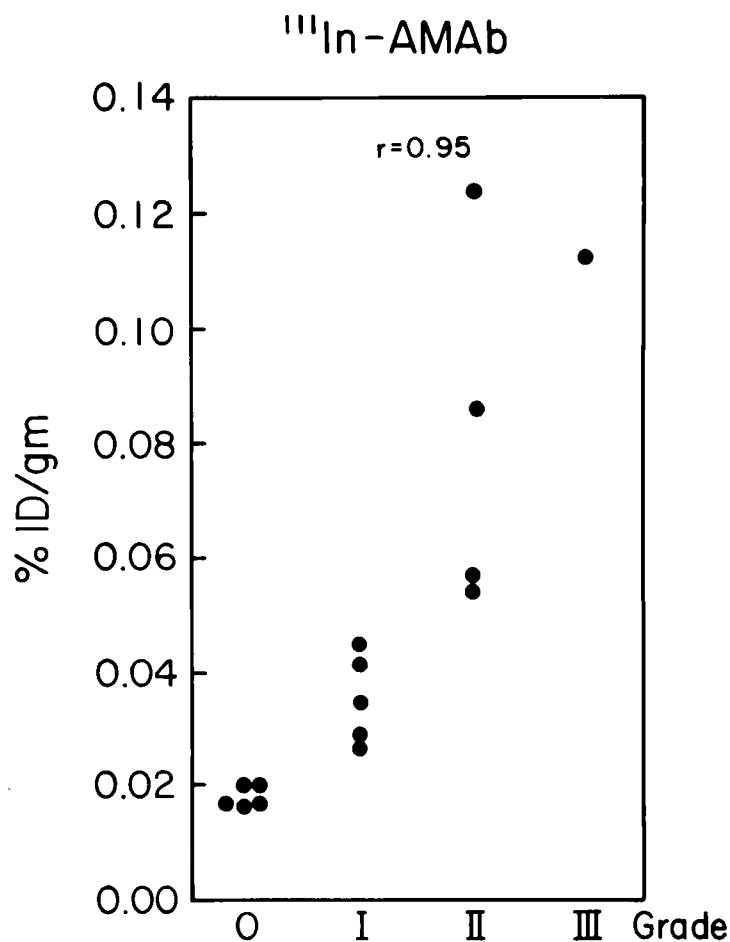


Fig. 3. Correlation between the histologic changes and biodistribution results (ID%/gm) of ¹¹¹In-AMAb.

al. 1973), ^{99m}Tc-glucoheptonate (Rossman *et al.* 1975) and ^{99m}Tc-pyrophosphate (Parkley *et al.*

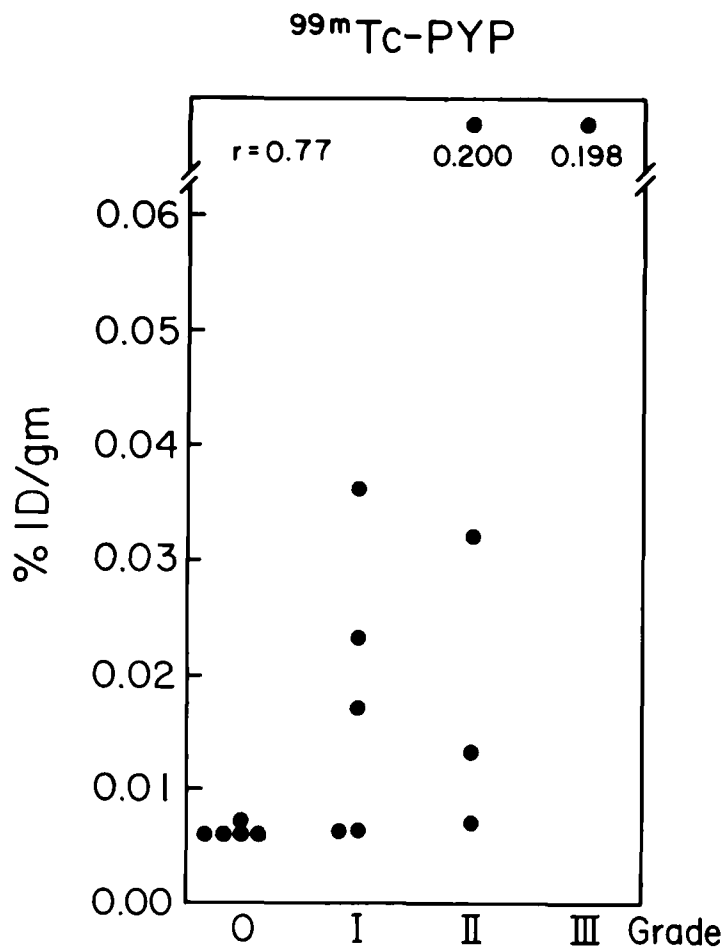


Fig. 4. Correlation between the histologic changes and biodistribution results (ID%/gm) of ^{99m}Tc -pyrophosphate

1974; Coleman *et al.* 1976). Although the exact mechanism of accumulation of $^{99m}\text{Tc-PYP}$ has not been completely defined, it appears to be due in part to the PYP's binding to intracellular components via injured myocardial cell membrane allowing PYP to accumulate in the form of hydroxyapatite-like crystals in mitochondria. This is often associated with cell necrosis and intracellular calcium accumulation (Buja *et al.* 1977). Some investigators (Gorton *et al.* 1980; Chacko *et al.* 1977) have reported that myocardial scanning using $^{99m}\text{Tc-PYP}$ may prove to be a valuable diagnostic tool in monitoring the adverse effects of the Adriamycin. They were able to detect myocardial damage before its clinical appearance. In our study $^{99m}\text{Tc-PYP}$ increasingly accumulated in hearts with Grade 0-III pathology, indicating that this agent can be utilized in staging Adriamycin cardiotoxicity.

More recently Khaw and others (Khaw *et al.* 1976; Khaw *et al.* 1978; Khaw *et al.* 1980; Beller *et al.* 1977; LaFrance *et al.* 1985; Takeda *et al.* 1985) localized myocardial infarcts by using radiolabeled antibodies to cardiac myosin. After intravenous injection of radioiodine-labeled fragments of antibodies that are specific for cardiac myosin, ratios of up to 6:1 between infarcted and normal myocardium were found in animal models. This ratio increased to greater than 20:1 in reperfused myocardial infarctions. Early studies (Khaw *et al.* 1978) used (Fab')₂ while more recent studies used a Fab fragment antibody. With both, (Fab')₂ and Fab, there was an inverse relationship between regional myocardial blood flow and uptake of the tracer. Similar results using $^{111}\text{In-AMAb}$ have been previously reported by our group and other investigators (LaFrance *et al.* 1985; Chacko *et al.* 1977).

In this study we measured the distribution of $^{111}\text{In-antimyosin}$ monoclonal antibody in myocardium of control rabbits and of animals treated with Adriamycin and we compared these results with those of $^{99m}\text{Tc-pyrophosphate}$ accumulation and correlated these results with radiopharmaceutical accumulation histologic findings in the same animals. Whether the ratio of $^{111}\text{In-AMAb}$ accumulation between Adriamycin treated and control rabbits in this study at 24 hours after intravenous injection was due only to lack of specificity of the antibody or was due to other factors was not studied.

The specificity of the human R11D10 antibody towards rabbit tissue also has not been previously evaluated. Investigations in dogs, however, have shown that the affinity of this antibody towards infarcted dog heart was similar to that of humans (Khaw *et al.* 1976).

The use of control rabbits along with histological and PYP comparison of our data revealed that there is some cross reactivity of the rabbit myosin with R11D10 murine antibody directed against human myosin. Since considerable similarities in mammalian myosin structure exist, cross reactivity was unexpected.

Based upon our canine infarction work (LaFrance *et al.* 1985), the ratio of ¹¹¹In-AMAb accumulation in human myocardium damaged by Adriamycin may be similar to those higher ratios since better specificity of R11D10 AMAb exists for human myosin as compared to rabbit myosin.

Whether ¹¹¹In-AMAb levels in Adriamycin damaged myocardium resulting in myocardial necrosis will be greater in humans requires further study.

Using this experimentally induced rabbit model and ¹¹¹In-antimyosin antibody, we were able to detect increased myocardial uptake before clinical appearance. Statistically significant increased accumulation of radioactivity occurred even though these animals had been treated with what had previously been described as a sub-toxic dosage of Adriamycin (10mg/kg), levels previously expected to cause no cardiotoxicity.

The significant correlation between the ¹¹¹In-AMAb in the myocardium will occur at the stage when the damage is still at the cellular level rather than at the global organ level and it may prove to be a valuable tool in monitoring the adverse effects of the anthracycline antibiotics in patients.

In conclusion, this study has demonstrated that (Khaw *et al.* 1976) ¹¹¹In-AMAb accumulation in the heart correlated better than PYP with the degree of pathology ($r=0.95$); (Khaw *et al.* 1978) ^{99m}Tc-PYP uptake was also dependent on degree of cardiac damage ($r=0.77$); and (Parkley *et al.* 1974) however, the more favorable ratio of %ID/gm in the myocardium of treated animals occurred for ^{99m}Tc-PYP than for ¹¹¹In-AMAb to detect Adriamycin induced cardiac damage before the end stage of cardiac toxicity develops. This study supports the need for a similar study in humans to determine the relative advantages of ¹¹¹In-AMAb, ^{99m}Tc-PYP and histology.

REFERENCES

Beller GA, Khaw BA, Haber E, and Smith TW.

- Localization of radiolabeled cardiac myosin-specific antibody in myocardial infarct. *Circulation* 1977; 55: 74-8
- Benjamin RS, Wiernik PH, and Bachur NR. Adriamycin chemotherapy; efficacy, safety, and pharmacological basis of an intermittent scale high dosage schedule. *Cancer* 1974;33 :19-25
- Botvinick EH, Shames D, Lappin H, Tyberg JV, Townsend R, Parmle WW. Noninvasive quantitation of myocardial infarction with technetium-99m-pyrophosphate. *Circulation* 1875; 52:902-15
- Bristow MR. Toxic cardiomyopathy due to doxorubicin. *Hosp Pract* 1982; 101-11
- Bristow MR, Minobe WA, Billingham ME, Marmor JB, Johnson GA, Ishimoto BM, Sageman WS, Daniels JR. Anthracycline-associated cardiac and renal damage in rabbits-evidence for mediation by vasoactive substances. *Lab Invest* 1981; 45:157-68
- Bristow MR, Sageman WS, Scott RH, Billingham ME, Bowden RE, Dernoff RS, Snidow GH, Daniels JR. Acute and chronic cardiovascular effects of doxorubicin in the dog: The cardiovascular pharmacology of drug-induced histamine release. *J Cardiovasc Pharm* 1980; 2:487-515
- Buja LM, Tofe AJ, Kulkarni PV. Sites and mechanisms of localization of technetium-99m phosphorus radiopharmaceuticals in acute myocardial infarcts and other tissue. *J Clin Invest* 1977; 60:742-7
- Bulum RH and Carter SK. Adriamycin: A new anticancer drug with significant clinical activity. *Ann Intern Med* 1975; 80:249-54
- Chacko AK, Gordon DH, Bennett JM, O'Mara RE and Wilson GA. Myocardial imaging with ^{99m}Tc-pyrophosphate in patients on adriamycin treatment for neoplasia. *J Nucl Med* 1977; 18:680-3
- Coleman ER, Klein MS, Roberts R, Sobel BE. Improved detection of myocardial infarction with technetium-99m stannous pyrophosphate and serum MB creatine phosphokinase. *Am J Cardiol*, 1976; 37: 732-8
- Cortes EP, Lutman G, Wanka J, Wang JJ, Pickren J, Wallace J, Holland JF. Adriamycin cardiotoxicity: a clinicopathologic correlation. *Cancer Chem Rep* 1975; 6:215-25
- Fervans VJ. Overview of cardiac pathology in relation to anthracycline cardiotoxicity. *Cancer Treat Rev*

- 1978; 62:955-61
- Gorton SJ, Wilson GA, Sutherland R, Schenk E, Chacko AK, Durakovic A, Bennett JM. The predictive value of myocardial radioisotope scanning in animals treated with doxorubicin. *J Nucl Med* 1980; 21:518-22
- Hall T, Baumgartner W, Borkron AM, LaFrance ND. Diagnosis of acute cardiac rejection utilizing antimyosin monoclonal antibody, phosphorus NMR, 2-D echocardiography and endocardial biopsy. (Accepted for publication) *J of Cardiac Trans*
- Holman BL, Dewanjee MK, Idoine J, Fliegel CP, Davis MA, Treves S, Eldh P. Detection and localization of experimental myocardial infarction with ^{99m}Tc-tetracycline. *J Nucl Med* 1973; 14:595-9
- Jaenke RS. Delayed and progressive myocardial lesions after adriamycin administration in the rabbit. *Cancer Res* 1976; 36:2958-66
- Jaenke RS. An anthracycline antibiotic-induced cardiomyopathy in rabbits. *Lab invest* 1974; 30:292-304
- Jain D, Crawley JC, Iahiri A, Rafley EB. Indium-111 antimyosin images compared with triphenyl tetrazolium chloride staining in a patient six days after myocardial infarction. *J Nucl Med* 1990; 31: 231-3
- John L, Nikos V, Helen P, Peter A, Sofia G, Panos K, and Spyridon M. Doxorubicin cardiotoxicity detected by indium 111 myosin-specific imaging. *Eur J Nucl Med* 1991; 18:225-6
- Johnson LL, Seldin DW, Becker LC, Wall RM, Keller AM. Antimyosin imaging in acute transmural myocardial infarction: results of a multicenter clinical trial. *J Am Coll Cardiol* 1989; 13:27-35
- Khaw BA, Bellar GA, Harber E and Smith TW. Localization of cardiac myosin-specific antibody in myocardial infarction. *J Clin Invest* 1976; 58:439-46
- Khaw B, Yasuda T, Gold H, Leinbach RC, Johns JA, Kanke M, Barlai-Kovach M, Strauss HW, Haber E. Acute myocardial infarct imaging with indium-111 labelled monoclonal antibody fab. *J Nucl Med* 1987; 28:1671-8
- Khaw BA, Beller GA, and Haber E. Experimental myocardial infarct imaging following intravenous administration of iodine-131 labeled antibody (Fab')₂ fragments specific for cardiac myosin. *Circulation* 1978; 57:743-50
- Khaw BA, Fallon JT, Strauss HW, Haber E. Myocardial infarct imaging of antibodies to canine cardiac myosin with indium-111-diethylenetriamine pentaacetic acid. *Science* 1980; 209:295-7
- Khaw BA, Strauss HW, Pohost GM, Fallon JT, Katus HA, Haber E. Relation of immediate and delayed thallium-201 distribution to localization of Iodine-125 antimyosin antibody in acute experimental myocardial infarction. *Am J Cardiology* 1983; 51: 1428-34
- LaFrance ND, Becker L, Takeda K, Goto N, Links J, Ravert H, Wong D, Wagner H. Indium antimyosin antibody for assessing myocardial damage. *J Nucl Med* 1985; 26:33-6
- LaFrance ND, Hall T, Dolher W, Kollev D, Cole P, Barkon A, Traill T, Jacobus W, Norvis S, Hutchins G, Braun J, Baumgartner W, Reitz B, Wagner HN. ¹¹¹In-antimyosin monoclonal antibody (AMAb) in detecting rejection of heart transplants. *J Nucl Med* 1986; 27: 910
- Lee MC, LaFrance ND, Takeda K, Tanada S, Scheffel U, Ravert H, Wagner H. ¹¹¹In-antimyosin monoclonal antibody in the detection of doxorubicin induced cardiac toxicity. *J Nucl Med* 1986; 27:994
- Lee MC, Lee KH, Choi YH, Chung J-K, Park YB, Koh C-S. Quantitative assessment of myocardial infarction by ¹¹¹In antimyosin antibody. *Kor J Nucl Med* 1991, 25:37-45
- Lefrak EA, Ditha J, Rosenheim S and Gottlieb JA. A clinicopathologic analysis of adriamycin cardiotoxicity. *Cancer* 1973; 32:302-11
- Lefrak EA, Pitha J, Rosentheim S, Gottlieb JA. Adriamycin cardiomyopathy. *Can Chem Rep* 1975; 6:203-8
- Parkley RW, Bonte FJ, Meyer SL, Atkins JM, Curry GC, Willerson JC. A new method for radionuclide imaging of acute myocardial infarction in humans. *Circulation* 1974; 50:540-6
- Rinehart JJ, Lewis RP, and Balcerzak SP. Adriamycin cardiotoxicity in man. *Ann Intern Med* 1974; 21:485-8
- Rossmann DJ, Strauss HW, Siegel ME, Pitt B. Accumulation of ^{99m}Tc-glucoheptonate in acutely infarcted myocardium. *J Nucl Med* 1975; 16:875-80
- Snedecor GW, Cochran WG. *Statistical methods*. The Iowa State University Press, Ames Iowa, 1976

Takeda K, LaFrance ND, Gatto N, Dipaula A, Ravert H, Wagner H, Becker L. comparison of ¹¹¹In-antimyosin antibody localization in experimental myocardial infarction. *Circulation* 1985; 72:301-6