

ANTIBREAST CANCER ACTIVITY OF NANOPROPOLIS INDONESIA ON INDUCED MAMMARY GLAND TUMOR BY DMBA IN VIRGIN SPRAGUE-DAWLEY RATS

AKHMAD ENDANG ZAINAL HASAN^{1,2*}, DJUMALI MANGUNWIDJAJA²,
TITI CANDRA SUNARTI², ONO SUPARNO² and AGUS SETIYONO³

¹Department of Biochemistry, Faculty of Mathematics and Sciences, Institut Pertanian Bogor, Bogor 16680, Indonesia

²Department of Agroindustrial Technology, Faculty of Agricultural Engineering and Technology,
Institut Pertanian Bogor, Bogor 16680, Indonesia

³Department of Clinic, Reproduction and Pathology, Faculty of Veterinary, Institut Pertanian Bogor, Bogor 16680, Indonesia

Received 15 March 2015/Accepted 15 May 2016

ABSTRACT

The objective of this study was to determine the effect of nanopropolis to cure cancer induced on rat mammary tumor using 7,12-dimethylbenz(a)anthracene (DMBA). After the first tumors appearance, twenty eight rats were divided into seven groups. Group 1, 2 and 3 served as recipient of nanopropolis dosages 8, 32 and 56 µg/mL treatments; Group 4 served as recipient of propolis dosage of 233 µg/mL treatment; Group 5 served as recipient of doxorubicin treatment; Group 6 served as recipient of DMBA treatment and Group 7 as normal group (control). The effect of nanopropolis dosage of 32 µg/mL and propolis dosage of 233 µg/mL were similar in reducing tumor size, healing the wounds caused by the tumor and eliminating cancer cells. It turns out that there is a relationship between particle size absorbent materials. The study suggested that nanopropolis with small concentration was very effective to treat rat mammary gland tumors and breast cancers.

Keywords: breast cancer, nanopropolis, propolis, Sprague-Dawley rat

INTRODUCTION

Cancer is one of the leading causes of death in the world, especially in developed countries and the second killer in developing countries. Based on data from the Hospital Information System (SIRS) in 2007 until 2013, breast cancer ranks first in hospitalized patients in all hospitals in Indonesia (16.85%), followed by cervical cancer (11.78%) (Ministry of Health 2013). In accordance with opinion of Muir *et al.* (2003), the cause of this disease are a cover of estrogen-dependent pathway, circulating androgen, estrogen and exposure to carcinogenic materials such as smoke, ultraviolet radiation, improper diet and stress; except for age and race that cannot be changed (Bates American Cancer Society 2016). In the early stage, breast cancer is only in the form

of a lump in the mammary tissue and in an advanced stage resulting an injury to the mammary tissue. The ways to treat this disease are the removal of tissue, radiation therapy and chemotherapy. Radiation therapy and chemotherapy are aimed to destroy cancer cells and control the disease so the main tumor will be shrunk, tumor growth will be slowed and spread of cancer cells to other tissues will be prevented.

Nowadays, there have been a lot of researches to obtain cancer medications, either directly for the treatment of cancer or to reduce the side effects of chemotherapy. The use of medications such as doxorubicin is one mean to inhibit cancer growth and reduce the occurrence of new cancers. However, the negative impact of doxorubicin treatment is the occurrence of hair loss, heart rhythm disorders and decreased white blood cell count. There is a challenge to find cancer treatment which is effective and minimize bad effects of the main treatment. One effort is to

* Corresponding author: zainalhasan@ipb.ac.id,
pakzainalhasan@gmail.com

find and develop medication from herbs and to do clinical test on herbal medication. Medication originated from herbs must be tested through a series of studies prior to its usage in cancer therapy. The tests should not involve animals. Abbasalipourkabar *et al.* (2010) and Purushothaman *et al.* (2012) investigated the incidence of breast cancer using virgin rats of Sprague-Dawley strain as test animals.

In-vitro studies showed that the origin of propolis from five locations in Indonesia and nanoproplis from Pandeglang were able to inhibit the growth of MCF-7 cell line. The nanoproplis inhibited the growth of MCF-7 cells at very low concentrations compared to propolis instead of nanoparticles (Hasan *et al.* 2014). The purpose of this study was to examine the *in-vivo* antibreastcancer activity of nanoproplis on the DMBA induced of virgin Sprague-Dawley rats.

MATERIALS AND METHODS

Preparation of Nanoproplis

Nanoproplis were prepared in three stages of homogenization using high speed homogenizer. Some modifications were done for preparing of nanoproplis particle as previously mentioned by Aimi *et al.* (2009), Bhaskar *et al.* (2009), Hasan *et al.* (2012), Chen *et al.* (2006) and Kim *et al.* (2008).

Mammary Tumor Induction

Twenty eight rats were intraperitoneally injected using a mixture of DMBA (with concentration of 25 mg/kgbody weight), olive oil and physiological saline.

Experimental Design

After the first tumors appearance, twenty eight rats were divided into seven groups, with three animals for each group. Group 1, 2 and 3 served as recipient of nanoproplis dosages of 8, 32 and 56 µg/mL treatments; Group 4 served as recipient of propolis dosage of 233 µg/mL treatment; Group 5 served as recipient of doxorubicin treatment; Group 6 served as recipient of DMBA treatment; and Group 7 as a normal group (control).

Tumor

Two dimensional tumor areas were calculated as an ellipse (Abbasalipourkabar *et al.* 2010). The volume of tumor was calculated by the formula of:

$$V = ab^2/2$$

where a = the longest diameter

b = the shortest diameter of tumor

At sacrifice, the tumor were removed for histopathological examination.

Histopathology Analysis

After euthanasia, at the end of the study, the mammary tumor masses of rats were removed. Sample of tissues were fixed immediately in 10% formalin overnight, embedded in paraffin, cut into 4 µm sections and stained with hematoxylin-eosin (HE).

RESULTS AND DISCUSSION

The results of body weight rats measurements after injection and treatment were presented in Figure 1. As seen in Figure 1, normal rat body weight continued to increase with time addition, as well as other treatments. The DMBA treatment showed a decrease in body weight. According to Cordeiro and Kaliwal (2011), effect of DMBA can reduce body weight of rat caused by the nature of its toxicity despite an increase in tumor volume.

Tumor progress can be determined by measuring the volume of test animal tumor (Abbasalipourkabar *et al.* 2010; Purushothaman *et al.* 2012; Martic *et al.* 2011). In the study of Abbasalipourkabar *et al.* (2010), tumor volume was calculated by measuring the length and width of the swelling, while Purushotaman *et al.* (2012) and Martic *et al.* (2011) calculated the tumor volume by measuring the length, width and height of the tumor section. Results in mammary tissue tumor volume of research data using the method of Abbasalipourkabar *et al.* (2010) can be seen in Figure 2. As seen in Figure 2, increasing tumor volume happened in only DMBA treatment without propolis or nanoproplis treatments.

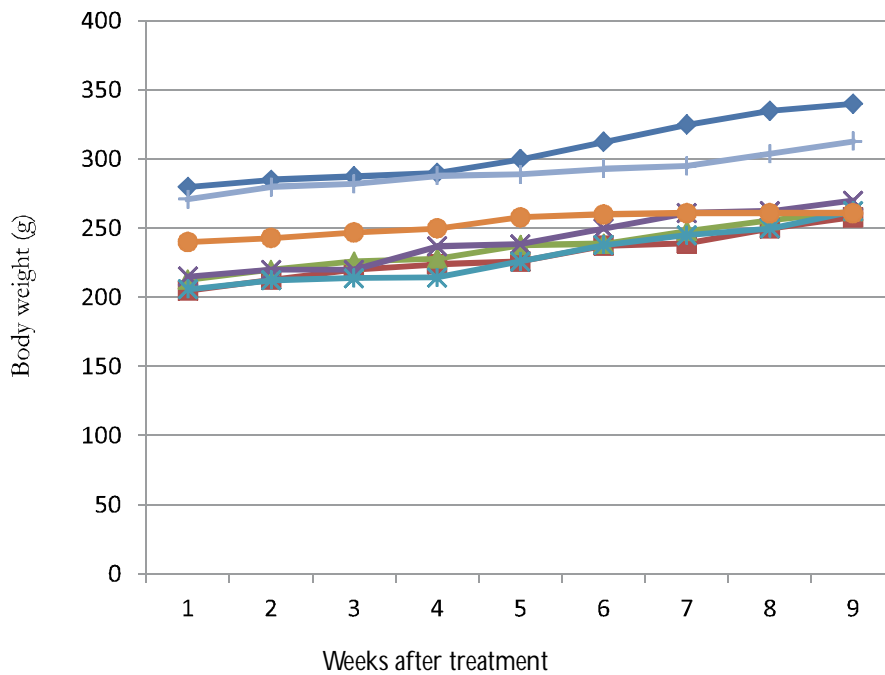


Figure 1 Body weight of rats after induction of DMBA and prior necropsy (1 = groups of nanopropolis 8 µg, 2 = groups of nanopropolis 32 µg, 3 = groups of nanopropolis 56 µg, 4 = groups of propolis 233 µg, 5 = doxorubicin groups, 6 = group of DMBA and 7 = normal control)

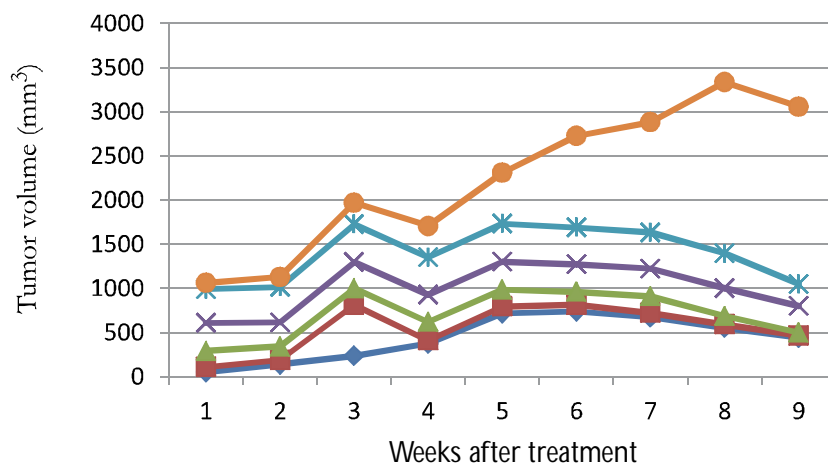


Figure 2 Tumor volume of mice after induction by DMBA prior to necropsy (1 = group of nanopropolis 8 µg/mL, 2 = group of nanopropolis 32 µg/mL, 3 = group of nanopropolis 56 µg/mL, 4 = group of propolis 233 µg/mL, 5 = doxorubicin group, 6 = group of DMBA and 7 = normal control group)

The propolis or nanopropolis treatments performed in rats decreased tumor volume. Even in the 32 and 56 µg/mL nanopropolis treatment and 233 µg/mL propolis treatment there were decline after an increase in tumor volume in the fifth week after being given treatment. When viewed from the point of decline, the injection of 56 µg/mL nanopropolis treatment had sharp corners, the tumor size reduction process occurred very quickly. This occurrence may be due to the relatively high dose (6 x IC₅₀) of the

ingredients in nanopropolis that is sufficient to eliminate cancer cells. Influence of the amount of the active ingredient component in nanopropolis (32 and 56 µg/mL) was instrumental in comparison with the influence of the particle size of the component nanopropolis for the repair tissue from tumor to compare propolis at 56 µg/mL.

Nanopropolis treatment with the concentration of 8 µg/mL had been done to heal cell and to repair tissue, although there are tumor

cells. On treatment with a concentration of 32 $\mu\text{g}/\text{mL}$, formation of intact tissue had occurred to heal and subcutaneous fat was formed and there were presence of intact epidermal glands and many globular epitheliums as well as reversal of intact tumor draining wounds. Similarly, nanopropolis treatment at a concentration of 56 $\mu\text{g}/\text{mL}$ occurred to heal much better than lower concentration of nanopropolis. This result showed that the amount of active ingredient content affected more to the healing rate of cancer. Figure 3 showed the result of administration of nanopropolis on rat mammary tissue (32 and 56 $\mu\text{g}/\text{mL}$) which had repaired skin tissue after being induced by DMBA.

The tissue conditions were better in nanopropolis concentration of 56 $\mu\text{g}/\text{mL}$ (Fig. 4), the formation of new tissue was much more than giving nanopropolis at concentration of 8 and 32 $\mu\text{g}/\text{mL}$. This proved that the administration of nanopropolis increasingly played a role in mammary tissue wounds caused by DMBA induced tumor results. This result showed that the amount of active ingredient affected the

healing rate of cancer. The greater the concentration of nanopropolis used, the greater the effect on tumor tissue healing wounds. The influence of different concentrations and time of administration of propolis against different cancer cells had also been studied by Bufalo *et al.* (2007). Presence of a tumor as a result of wound healing using propolis administration was the formation of epithelial tissues that had been studied by de Moura *et al.* (2011), although using different propolis. This condition was supported by the presence of components of propolis (Hasan *et al.* 2014) or mineral contents (Hasan *et al.* 2013).

At a concentration of 56 $\mu\text{g}/\text{mL}$ the mammary *alveoli* were healthy and aesthetically clean. In Figure 4a it is seen the *alveoli* containing blood plasma (blue arrows pointing) as a result of mammary tissue repair. On the other rats groups (DMBA group or negative control) in which nanopropolis or propolis injection was not performed, mammary tissue condition was still going on angiogenesis and cancer cells enters blood vessels. In this condition, cancer cell

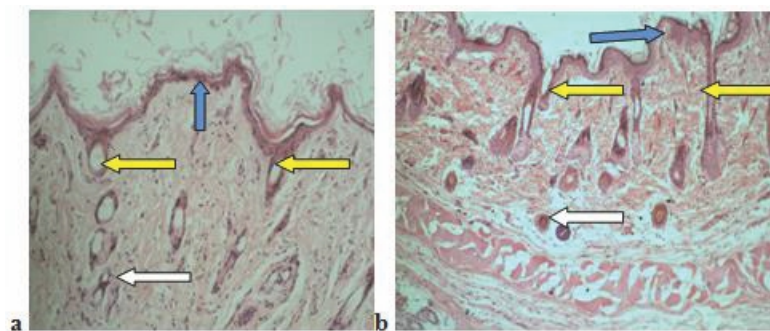


Figure 3 The mammary tissue of virgin rat after being induced by DMBA and received injection treatment of a. nanopropolis (32 $\mu\text{g}/\text{mL}$) and b. nanopropolis (56 $\mu\text{g}/\text{mL}$) (blue arrow = skin epithelium, yellow arrow = normal hair follicles, white arrow = capillary epidermis) (HE staining, 200x)

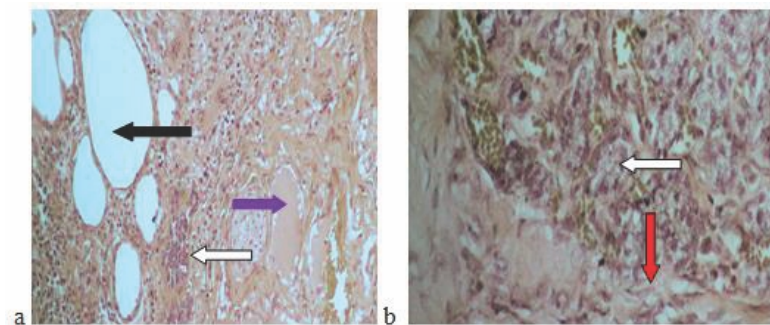


Figure 4 a) The mammary tissue of rats SD induced by DMBA and nanopropolis 56 mg/mL every seven days within two months, b) The mammary tissue of rats SD induced by DMBA and no treatment within two months after induction (black arrow = *alveole*, blue arrow = *alveole* filled with blood plasma, white arrow = cancer cells, red arrow = connective tissue) (HE staining, 200x)

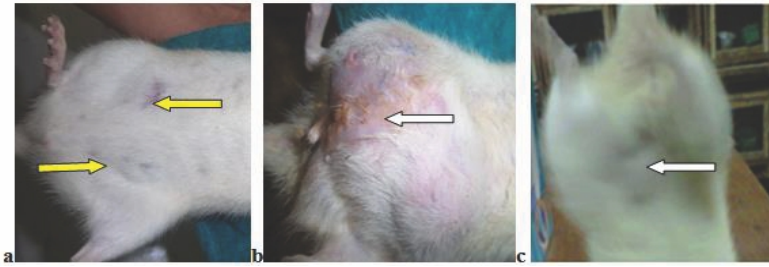


Figure 5 a) The physical condition of the mammary tissue healing can be experienced with drying occurs in an area that has suffered injury due to tumor after injection of nanopropolis 32 $\mu\text{g}/\text{mL}$, b) non treatment or only induction of DMBA, and c) condition before treatment after induction of DMBA for 90 days (yellow arrow = dry wound, white arrow = mammary swelling because of tumor)

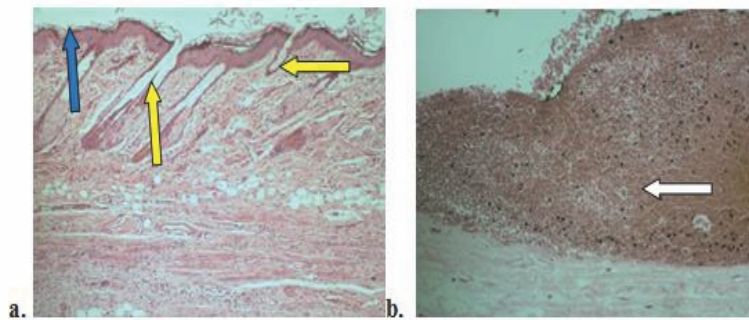


Figure 6 Virgin rat mammary tumor tissue after being induced by DMBA and treated with injection of (a) propolis (233 $\mu\text{g}/\text{mL}$) and (b) Without treatment (positive control) (blue arrow = skin epithelium, yellow arrow = normal hair follicle, white arrow = inflammation) (HE staining, 200x)

spread in so much connective tissue and almost every tissue as is shown in Figure 4b (cancer cells (white arrows) and connective tissue (red arrows)).

The physical condition of the mammary tissue healing can be seen when drying condition occurred in an area that has suffered injury due to the tumor (Fig. 5a). While the mammary tissue was swollen caused by the tumor, the effect of DMBA induced in virgin rats were large swell (Fig. 5b). Even one rat in this group had inflammation of the mammary tissue. This condition can be referred to as stage IV breast cancer.

Tested activities of propolis curing cancer proved that a dosage of 233 $\mu\text{g}/\text{mL}$ can heal damages caused by the tumor tissue compared with the positive control treatment without induction by DMBA treatment. Positive control (without induction by DMBA) does not cure cancer and even developed accumulation of cancer cells and tissue damage (Fig. 6). Inoue *et al.* (2008) showed that the inhibition of cancer growth occurred after propolis concentration of 320 $\mu\text{g}/\text{mL}$. Similarly, Bermúdez *et al.* (2006) reported that wound healing with 10% propolis

only occur as much as 60% only for the occurrence of re-epithelialization. In-breast tissue repair can be seen around the damaged tissue with re-epithelialization (blue arrow) and hair follicles (yellow arrow) in Figure 6a. For the DMBA induced research, mammary wounds were formed in the mammary tissue and there were many cancer cells (Fig. 6b).

Figure 7 shows drying cancer cells condition with black spots on the new blood vessels, but there are still cancer cells expected to remain active. This is because the treatment required quite a long time, so that the healing process was still running and was still not finished. On treatment with propolis dosage of 233 $\mu\text{g}/\text{mL}$, the drying process indicated the healing in tissues affected by cancer.

At dosage of 32 $\mu\text{g}/\text{mL}$ nanopropolis has the ability to cure cancer which has the same effect to as much as 233 $\mu\text{g}/\text{mL}$ of propolis administration. The particle size in nanopropolis is very small, so active ingredient remaining in nanopropolis can log into the network with ease, while the dosage of propolis with 233 $\mu\text{g}/\text{mL}$ which was active against tumor growth is caused

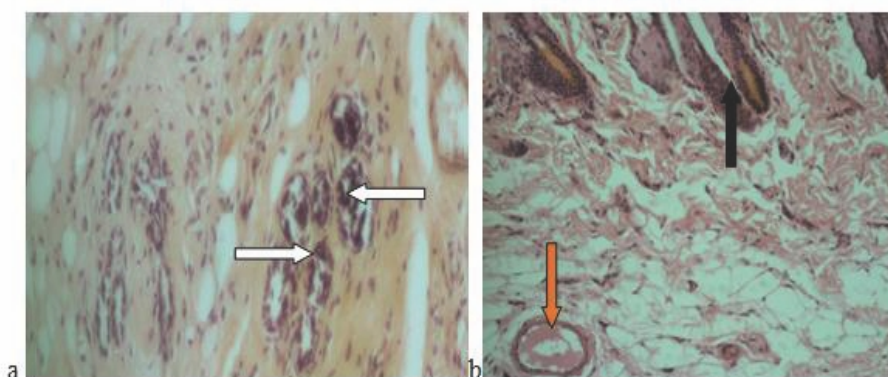


Figure 7 Mammary tissue (a) and skin tissue (b) DMBA-induced SD rats treated with propolis at a dosage of 233 $\mu\text{g}/\text{mL}$ every 7 days within 2 months (red arrows = vein, white arrow = dead cancer cells, black arrow = hair follicle) (HE staining, 200x)

by the presence of the active components in propolis preventing tumor progression. This fact was caused by the presence of compounds in either nanopropolis or propolis, such as organic acids like firulic acid and caffeic acid, polyphenols and flavonoids in propolis which inhibit the proliferation of cancer cells. The role of flavonoids and caffeic acid is to inhibit the formation of protein kinases that are used for cell proliferation which result is going to inhibit cell formation process and induced apoptosis occurrence (Madeo *et al.* 2004). In accordance with the results of de Moura *et al.* (2011), the healing of wounds caused by the tumor may occur due to administration of propolis. Meanwhile, according to Sun *et al.* (2012) crysin components present in propolis can decrease the volume of tumor that occurs in the mammary tissue of DMBA induced mice. The research conducted by Bhattacharjee *et al.* (2012) and Lim *et al.* (2011) states that there is a relationship between particle size absorbent materials on the healing of cancer.

CONCLUSIONS

The effects of nanopropolis with dosage of 32 $\mu\text{g}/\text{mL}$ and propolis with dosage of 233 $\mu\text{g}/\text{mL}$ were the same in reducing tumor size, healing the wounds caused by the tumor and eliminating cancer cells. It turned out that there is a relationship between particle size absorbent materials on the healing of cancer. The study suggested that nanopropolis with small concentration (dosage of 32 $\mu\text{g}/\text{mL}$) was very effective for the treatment of rat mammary gland tumors and breast cancers.

ACKNOWLEDGEMENTS

The authors wish to thank BPPS Fellowship of Indonesian Ministry of Education and Culture, and SEAMEO BIOTROP for their financial supports and Institut Pertanian Bogor for its facilities for conducting this study.

REFERENCES

- Abbasalipourkabir R, Salehzadeh A, Abdullah R. 2010. Antitumor activity of tamoxifen loaded solid lipid nanoparticles on induced mammary tumor gland in Sprague-Dawley rats. *Afr J Biotech* 9(43):7337-45.
- Aimi M, Nemori R, Ogiwara K. 2009. *Casien Nanoparticle*. Inventor.
- Bates American Cancer Society [Internet]. 2016. Causes, Risk Factors, and Prevention Topics. USA: American Cancer Society; [cited 2016 May 31]. Available from: <http://www.cancer.org/cancer/breastcancer/detailedguide/breast-cancer-risk-factors>.
- Bermúdez IC, García GS, Piloto AA, Pérez YF, Valdivieso AG. 2006. Effect of the Cuban propolis collected in Manzanillo area on the wounds healing in rats. *Pharmacol* 3:416-21.
- Bhaskar K, Anbu J, Ravichandiran V, Venkateswarlu V, Rao YM. 2009. Lipid nanoparticles for transdermal delivery of flurbiprofen: formulation, *in-vitro*, *ex-vivo* and *in vivo* studies. *Lipids Health Disease* 8(6):758-76.
- Bhattacharjee S, Erchov D, Fytianos K, van der Gucht J, Alink GM, Rietjens IMCM, Marcelis ATM, Zuillhof H. 2012. Cytotoxicity and cellular uptake of triblock copolymer nanoparticles with different size and surface characteristics. *Particle Fibre Toxicol* 9(11):1-19.

- Bufalo MC, Candeias MGJ, Sforcin JM. 2007. *In vitro* cytotoxic effect of Brazilian green propolis on human laryngeal epidemoid carcinoma (HEP-2) cells. *Advance Access Pub* 6(4):483-7.
- Chen M, Diao G, Zhang E. 2006. Study of inclusion complex of beta-cyclodextrin and nitrobenzene. *Chem* 63:522-9.
- Cordeiro MC, Kaliwal BB. 2011. Antioxidant activity of bark extract of *Bridelia retusa* SPRENG on DMBA induced mammary carcinogenesis in female sprague Dawley rats. *J Pharm* 2(1):14-20.
- de Moura SAL, Negri G, Salatino A, Lima LDC, Dourado LPA, Mendes JB, Andrade SP, Ferreira MAND, Cara DC. 2011. Aqueous extract of Brazilian green propolis: primary components, evaluation of inflammation and wound healing by using subcutaneous implanted sponges. *Evid Based Complement Alternat Med* 2011:1-8.
- Hasan AEZ, Ambarsari L, Artika IM, Julistiono H, Tarunasari D. 2013. Induction resistance of *Candida* sp. Y390 to ethanol stress by kopyor coconut and virgin coconut oil. *Emir J Food Agric* 25(10):790-7.
- Hasan AEZ, Artika IM, Fahri VR, Sari N. 2012. Potency of nanopropolis from stingless bee *Trigona* spp. as antibacteria agents. *Chem Progress* 5(1):1-7.
- Hasan AEZ, Mangunwidjaja D, Sunarti TC, Suparno O, Setiyono A. 2014. Investigating the antioxidant and anticytotoxic activities of propolis collected from five regions of Indonesia and their abilities to induce apoptosis. *Emir J Food Agric* 26(5):390-8.
- Inoue K, Saito M, Kanai T, Kawata T, Shigematsu N, Uno T, Isobe K, Liu CH, Ito H. 2008. Antitumor effects of water soluble propolis on a mouse sarcoma cell line *in vivo* and *in vitro*. *Am J Chin Med* 36(3):625-34.
- Kim DM, Lee GD, Aum SH, Kim HJ. 2008. Preparation of propolis nanofood and application to human cancer. *Biol Pharm Bull* 31(9):1704-10.
- Lim HN, Nurzulaikha R, Harrison I, Lim SS, Tan WT, Yeo MC. 2011. Spherical tin oxide, SnO₂ particles fabricated via facile hydrothermal method for detection of mercury (II) ions. *Int J Electrochem Sci* 6:4329-40.
- Madeo F, Herker E, Wissing S, Jungwirth H, Eisenber T, Frohlich KU. 2004. Apoptosis in yeast. *Current Opinion Microbiol* 7:655–60.
- Martic K, Vlacic Z, Rudman F, Lambasa S, Tomasovic-Loncaric C, Stanec Z. 2011. Tumor and breast volume ratio as a predictive factor for axillary lymph node metastases in T1c ductal invasive breast cancer: prospective observational clinico-pathological study. *Jpn J Clin Oncol* 41(12):1322-6.
- Ministry of Health [Internet]. 2013. Indonesia: Ministry of Health; [cited 2013 June 14]. Available from: <http://www.depkes.go.id/index.php/berita/press-release/2233-seminar-sehari-dalam-rangka-memperingati-hari-kanker-sedunia-2013.html>.
- Muir D, Kanthan R, Kanthan SC. 2003. Male versus female breast cancers. *Arch Pathol Lab Med* 127(1):36-41.
- Purushothaman A, Nandhakumar E, Sachdananram P. 2012. Anticancer effect of shemamrithaa (a phytochemical formulation) on 7,12-dimethyl benz(a)anthracene induced mammary carcinoma in rats. *Asian J Pharm Clinical Res* 5(1):101-7.
- Sun LP, Chen AL, Hung AC, Chien YH, Huang JS, Huang CY, Chen YW, Chen CN. 2012. Chrysin: a histone deacetylase 8 inhibitor with anticancer activity and a suitable candidate for the standardization of Chinese propolis. *J Agric Food Chem* 60:11748-58.