

December 17, 2012

SCIENCE SPOTLIGHT

Breast Imaging In Symptomatic Younger Women: Ultrasound vs. Mammogram?

December 17, 2012

S Lowry

Recent changes in recommendations for routine breast cancer screening practices in younger women have been high-profile and controversial. Less attention has been received by breast imaging recommendations for younger women who are experiencing symptoms, such as breast pain or a palpable lump. The American College of Radiation (ACR) currently recommends that women over the age of 30 who present with focal (localized) symptoms undergo a mammogram. However, breast tissue in women ages 30-39 is extremely dense, which reduces the effectiveness of mammography. In Europe, ultrasound is the primary imaging modality recommended for such women.

Dr. Constance Lehman of Public Health Sciences, SCCA, and UW Department of Radiology, and colleagues, undertook a study to compare the accuracy of breast ultrasound *versus* mammography in women ages 30-39 who were experiencing focal breast symptoms. They used medical records to identify women who underwent both ultrasound and mammogram, excluding those with non-focal symptoms, or those who were undergoing follow-up for a screening mammogram or for a known cancer. They identified breast cancer outcomes via linkage to tumor registry, requiring at least 24 months of follow-up time.

1208 cases of focal breast symptoms were included, in a total of 954 women (some women had multiple instances of symptoms; these were included separately). Of these, 23 (1.9%) were determined to be breast cancer; the rest were benign. Ultrasound was highly sensitive in this population of symptomatic younger women, detecting 95.7% of the cancers, *versus* mammography, which detected only 60.9% of the cancers. The negative predictive value was 99.9% for ultrasound and 99.2% for mammography, meaning that approximately 1 out of 1000 such women would have a false negative test result (*i.e.* a cancer would be missed) by ultrasound, *versus* approximately 1 out of 250 such women would have a cancer missed by mammogram.

Even among symptomatic women at this younger age, the occurrence of breast cancer is relatively low (1.9%). But ultrasound appears to be more effective at catching these cancers than mammograms, because breast tissue is so much more dense in women ages 30-39. Investigators conclude that mammograms add very little whereas ultrasound has great utility, indicating that

perhaps ultrasound, and not mammogram, should be the recommended imaging technique in women ages 30-39 with focal breast symptoms.

[Lehman CD, Lee CI, Loving VA, Portillo MS, Peacock S, Demartini WB](#). 2012. Accuracy and value of breast ultrasound for primary imaging evaluation of symptomatic women 30-39 years of age. *Am. J. Roentgenol.* 5:1169-77.

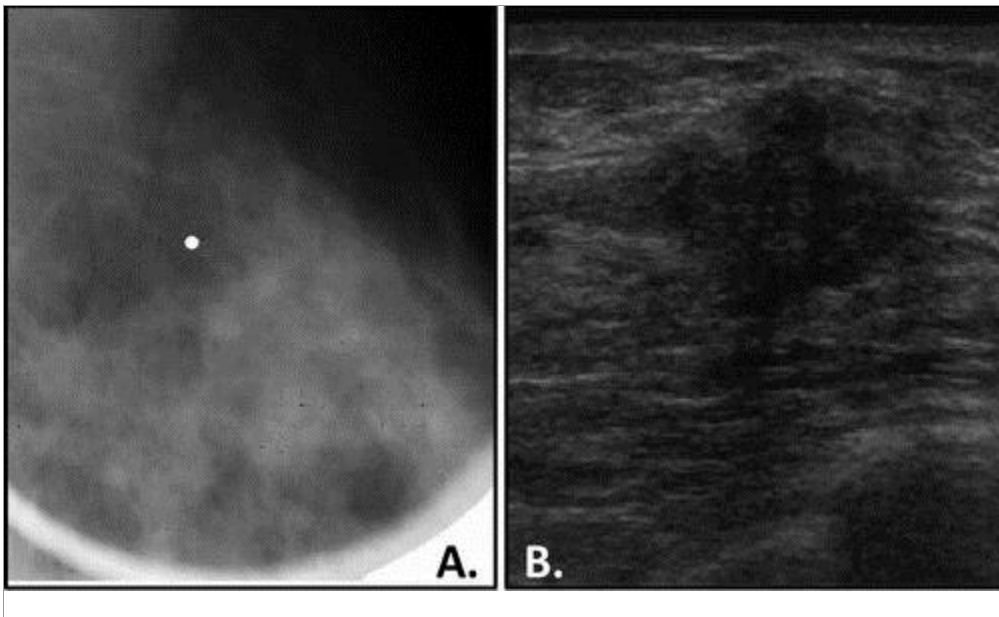


Image adapted from Lehman et al.

35-year-old woman with palpable left breast lump. (A) Whole-breast mediolateral mammographic image reveals no abnormality at area of concern (marked by white point). (B) Targeted ultrasound image shows solid mass with irregular shape and indistinct, angular margins. Histopathology revealed invasive ductal carcinoma.