

The effect of sipatah-patah (*Cissus quadrangularis* Salisb) extract administration on osteoclast formation and osteoporosis treatment in female rats during post menopausal period

M. Sabri

Laboratory of Anatomy, Faculty of Veterinary Medicine, Syiah Kuala University, Banda Aceh, Indonesia. Corresponding author: mustafa_sabriyosa@yahoo.com

Abstract. *Cissus quadrangularis* Linn (Cq) is a rambling shrub, characterized by a thick quadrangular fleshy stem and widely used to cope with joint pain, syphilis, venereal disease, and osteoporosis. This plant is containing calcium, phosphate and phyto-oestrogens. Hence the objective of the present study was to evaluate effect of the *C. quadrangularis* on bone recovery of rat. Blood was drawn once each 30 days to analyze serum calcium and phosphate concentration in blood. Rats were sacrificed to analyze bone histology. Os tibia fibula slice was stained with Hematoxylin Eosin (HE) method to observe osteoblast and osteoclast density, and Masson trichrome to observe trabeculae structure. ESP administration at longer period on treatment rats (OV-2) leads to more radiopaque bone mass than other groups including control group but osteoclast density is lower.

Introduction

Osteoporosis is a common disease characterized by low bone mass and structural deterioration of bone tissue leading to bone fragility and an increased susceptibility to fractures. This occurs due to declining of estrogen amount particularly at postmenopause women which is very necessary in forming osteoblasts at red marrow myloid tissues in mature (Smith 1993).

Cissus quadrangularis Linn (Cq) is a rambling shrub, characterized by a thick quadrangular fleshy stem and widely used to cope with joint pain, syphilis, venereal disease, and osteoporosis (Shirwaikar 2003). In Aceh, *Cissus quadrangularis* Salisb has long been known with sipatah-patah plant containing calcium, phosphate and phyto-oestrogens that are very potent drug for bone fracture. This research aimed to study the effects of sipatah-patah extract (ESP) administrations on bone recovery in efforts to treat osteoporosis during postmenopausal period. The result provides information for knowledge in preventing and treating osteoporosis with traditional medicine (herb).

Materials and Method

Blood was drawn once each 30 days to analyze serum calcium and phosphate concentration in blood. Rats were sacrificed to analyze bone histology. Os tibia fibula slice was stained with Hematoxylin Eosin (HE) method to observe osteoblast and osteoclast density, and Masson trichrome to observe trabeculae structure.

Results and Discussions

Rat of OV-0 group, concentration of calcium in serum tends to be konstan between initial and the end of research about $11,89 \pm 0,36$ mg/dl. Group OV-1, concentration of calcium in serum tends to decrease during treatment. However, rats of OV-2, concentration of calcium at initial and final research were 10,13 mg/dl and 10,48 mg/dl respectively (increase 3,45%), Those rats were group having the highest concentration of calcium at the end of research. Rats of OV-3 given *Cissus Quadrangularis* (ESP) during 90 days and 120 days, concentration of calcium increase by 0,58% and 1,10% respectively. In general, Administration of ESP on ovariectomized rats increase concentration of calcium in serum significantly at the end of research ($P < 0.05$) (Table 1).

Table 1. Percentage of calcium and phosphate serum level change on rats during ESP administration.

Group	Period of ESP administration (days)	calcium mg/dl			Phosphate mg/dl		
		initial	final	change (%)	initial	final	change (%)
OV-0	(sham)	11,62±0,47	11,89±0,36	4,04	7,46±0,34	,58±0,30	3,21
OV-1	(control)	10,08±0,54	9,33±0,52	-7,44	7,43±0,22	,13±0,52	4,03
OV-2	120	10,13±0,17	10,48±0,32	3,45	7,46±0,16	,62±0,13	2,14
OV-3	90	10,23±0,49	10,29±0,43	0,58	7,46±0,13	,57±0,12	1,47
OV-4	60	9,94±1,36	10,05±0,85	1,10	7,51±0,29	,57±0,27	0,79

Note: OV-0= sham rats; ovariectomized rat not given ESP (OV-1) , Given ESP during 120 days (OV-2), 90 days (OV-3), and 60 days (OV-4). Modified by Sabri 2011

Similar to calcium, concentration of phosphorous in serum on rat of OV-2, OV-3, and OV-4 also increase during administration of ESP. Although the concentration of phosphorous rats of OV-2, OV-3 and OV-4 at the end of treatment was not as high as sham.

Table 2. Osteoblasts and osteoclasts density of ovariectomized rats (OV) on day-180

group	Osteoblasts		Osteoclasts
	Active	Passive	
OV-0	30,75±19,16 ^c	41,79±17,37 ^b	3,21±2,19 ^c
OV-1	28,17±14,79 ^c	38,00±14,52 ^b	16,00±3,32 ^a
OV-2	57,19±18,67 ^a	67,31±18,45 ^a	6,68±3,35 ^b
OV-3	38,46±8,36 ^b	45,75±10,45 ^b	7,67±2,59 ^b
OV-4	28,39±15,55 ^c	36,39±16,97 ^b	9,06±3,67 ^b

Note: OV-0= sham rats; ovariectomized rat not given ESP (OV-1) , Given ESP during 120 days (OV-2), 90 days (OV-3), and 60 days (OV-4). Modified by Sabri 2011

Otherwise, concentration of phosphorous OV-1 tends to decrease. Ovariectomized rats given ESP for 120 days underwent the increase of concentration of phosphorous by 2,14% , whereas rat given ESP for 90 and 60 days also increase by 1,47 and 0,79% respectively. Administration of ESP on ovariectomized rats (OV-2, OV-3 and OV-4) leads to concentration of phosphorous at the end of research higher than those of OV-1 , and similar to sham. Figure 1 showed that rats given ESP have bone mass more radiopaque than those of control group. But it was similar to shams. Rats given ESP for 120 have bone mass more radiopaque than other group including control group. Ovariectomized rat given ESP for 120 days showed that osteoclast density is lower (6,68 ± 3,35) than those of control group (16,00 ± 3,32), and other treatment groups (OV-3 and OV-4) (P<0,05). While osteoclast density with shorter period of ESP administration showed that osteoclast density is higher than those of longer period (Table 2 and Figure 2).

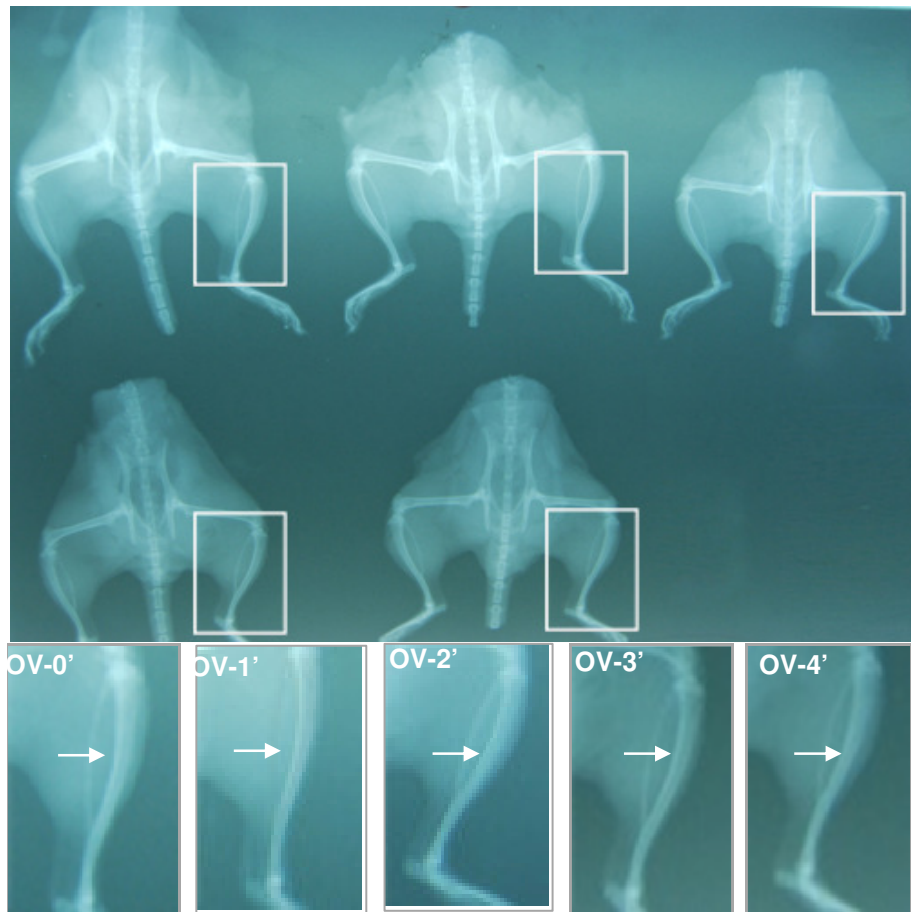


Figure 1. Radiography of ovariectomized rat tibia bone with ESP administration treatment at 90, 120 and 150 day old. Insert: arrow shows *radiolucent* (OV-1'), dan *radiopaque* (OV-2'), with decreasing *radiopaque* degree at OV-3'- OV- 4' compared to OV-2'. Bar: 5 mm OV-0= sham; ovariectomized rat not given ESP (OV-1) , Given ESP during 120 days (OV-2), 90 days (OV-3), and 60 days (OV-4) (Modified by Sabri 2011).

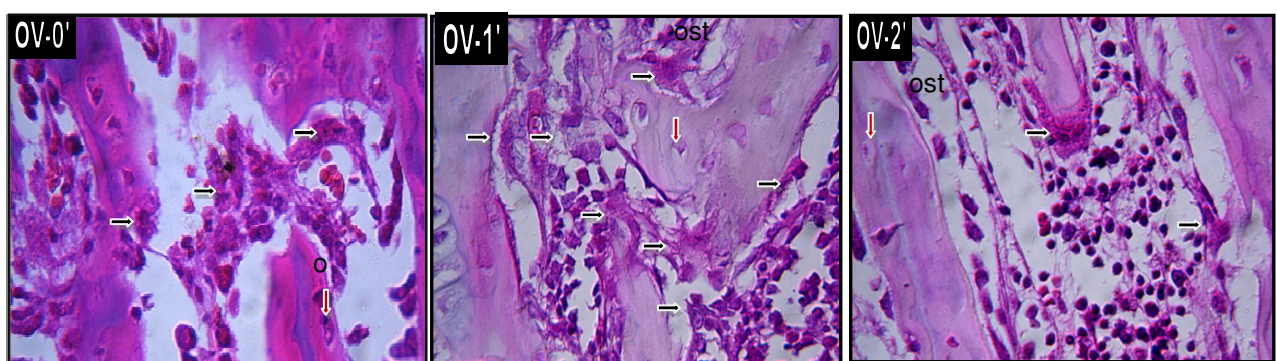


Figure 2. Osteoclast density of ovariectomized rat tibia bone with ESP administration at the age of 90,120, and 150 days. Insert: showed osteoclast cell OV-0': *sham*, OV-1': ovariectomized rat not given ESP showed the increase of osteoclast cell: OV-2', given ESP during 120 days, osteoclast (black arrow), osteositis (red arrow). HE staining. Bars: 50 μ m (OV-0, OV-1, OV-2), and 20 μ m (OV-0', OV-1', OV-2'). (Modified by Sabri 2011)

Conclusion

ESP administration at longer period on treatment rats (OV-2) leads to more radiopaque bone mass than other groups including control group but osteoclast density is lower.

References

- Kiernan JA. 1990. *Histological & histochemical methods: Theory & Practice*. 2nd Ed. England: Pergamon Pr.
- Sabri M. 2011. The Activity of Ethanol-extract of Sipatah-patah (*Cissus quadrangula* Salisb) as an Antiosteoporosis on Female Rats (*Rattus norvegicus*). Disertasi
- Shirwaikar A, Khan S, Malini S. 2003. Antiosteoporotic effect of ethanol extract of *Cissus quadrangularis* Linn on ovariectomized rat. *J Ethnopharmacol* 89: 245-250.
- Smith R. 1993. Bone physiology and the osteoporotic process. *Resp Med* 87 (Suppl A). 3-7