

Protective role of nanoemulsion containing roman chamomile oil against mitomycin C-induced toxicity in Ehrlich ascites carcinoma bearing mice

Waad A Al-Otaibi^{1,2}, Mayson H Alkhatib^{1,3*} & Abdulwahab Noor Wali^{3,4}

¹Department of Biochemistry, Faculty of Science, King Abdulaziz University, Jeddah-21589, Saudi Arabia

²Department of Chemistry, College of Science and Humanities, Shaqra University, Shaqra, Saudi Arabia

³Regenerative Medicine Unit, King Fahd Center for Medical Research, Jeddah-21589, Saudi Arabia

⁴Department of Clinical Biochemistry, Faculty of Medicine, King Abdulaziz University, Jeddah-21589, Saudi Arabia

Received 29 March 2019; revised 02 October 2019

Mitomycin-C (MC), an anticancer agent, induces oxidative stress in normal tissues causing severe toxicity. The present study aimed to evaluate whether the side effects of MC may be diminished by the incorporation of MC into nanoemulsion containing Roman chamomile oil (RCM-NE). Fifty mice were equally divided into five groups. The first and second groups were the control and the untreated Ehrlich ascites carcinoma bearing mice (EAC), respectively, while the other three groups were EAC-bearing mice treated once intraperitoneally with a dose of 200 μ L of RCM-NE, 1 mg/kg^{-1} MC/200 μ L normal saline, and 1 mg/kg^{-1} MC/200 μ L RCM-NE. The protective effect of the RCM-NE was examined by measuring the alterations in complete blood count, organs weight indices, and levels of serum biochemical parameters. The oxidative stress was assessed by measuring lipid peroxidation and enzyme activities of catalase, superoxide dismutase, glutathione reductase, and thioredoxin reductase-1. MC-RCM-NE has significantly reduced the toxicity of MC on the white blood cells and platelets. It improved the renal and cardiac biomarker levels and the antioxidants of the kidney, heart, and thymus. The protective effect of the RCM-NE on the blood and organs against MC toxicity was associated with the decreasing of oxidative stress and maintaining the activity of the antioxidants.

Keywords: Cardiotoxicity, Nephrotoxicity, Oxidative stress, Thymic atrophy

Mitomycin-C (MC) is an antineoplastic xenobiotic that belongs to aziridine-containing natural products. MC exhibits activity against broad kinds of tumors¹. Upon bioreductive activation of MC, it is transformed into a highly reactive bis-electrophilic intermediary compounds that alkylate DNA, these intermediates including reactive oxygen species (ROS) are toxic to normal cells^{2,3}. Also, MC intermediates were found to react with the selenothiol moiety of TrxR-1 and inhibit rRNA⁴. In spite of its wide range activity, the therapeutic uses of MC have been limited due to its toxic effects on the hematopoietic system⁵ and vital organs such as kidney, heart^{6,7}, and thymus⁸. To overcome these complications, many attempts are needed to create a novel antioxidant nanocarrier against the oxidative stress-caused toxicity in chemotherapy.

Essential oils (ESSOs) are natural products that have got extracted from various kinds of plants containing numerous volatile compounds⁹. Roman chamomile (RCM) oil possesses different pharmacological functions such as antiproliferative¹⁰, anti-inflammatory, and antioxidant activities¹¹. Unfortunately, the poor water solubility and instability of ESSOs resulted in poor oral bioavailability, which limits their clinical applications. Therefore, several attempts were implemented to encapsulate ESSOs into NEs to diminish their volatility, improve their water solubility and therapeutic efficacy¹²⁻¹⁴. NE-based ESSOs may have unlimited medical uses in drug delivery as they can be administered through various routes. As a consequence, the incorporated MC into NEs- based RCM oil would enhance the quality patient's life by producing protective and effective anticancer agents.

The possible protective effect of the MC-loaded RCM-NE was investigated in the blood, kidney, heart, and thymus of Ehrlich as cites carcinoma (EAC) bearing mice.

*Correspondence:

Phone: +966599240526 (Mob);

Fax: + 966 26400376

E-mail: mhalkhatib@kau.edu.sa

Materials and Methods

Chemicals

Roman Chamomile (RCM) oil, 100% pure, steam distilled essential oil, extracted by the *Anthemis nobilis* plant's flowers, was obtained from Sukar Nabat (Jeddah, Saudi Arabia). Mitomycin-C (MC) was supplied from Korea United Pharma, Inc. Polyoxyethylene-20-sorbitan monooleate (T₈₀) and Sorbitan laurate (SP₂₀) were obtained from Al-rowad establishment for the medical instruments and supplies.

Animals

Nine weeks old healthy female Swiss albino mice (n=50) with a body mass of (25-30) g were used. Mice were acclimatized as recommended by King Abdul-Aziz University's policy in polypropylene cages. The procedures involving the care and use of mice were permitted by King Abdul-Aziz University's policy and the international ethical guidelines¹⁵. The ethical approval was obtained from the research ethics committee in the Faculty of Medicine at King Abdul-Aziz University.

Tumor cells

Ehrlich ascites carcinoma (EAC) cells were originally obtained from America Type Tissue Culture Collection (Manassas, VA, USA). They were maintained by weekly intraperitoneal inoculation of 1×10^6 cells in stock mouse¹⁶.

Production of RCM-NE and MC-RCM-NE formulations

Nanoemulsion of Roman chamomile oil (RCM-NE) was prepared by mixing of T₈₀/ SP₂₀: RCM oil: distilled water in weight fractions of 0.36: 0.05: 0.914, respectively. The resulted mixture was heated at 70°C with incessant mixing until a monophasic solution was produced. After that, this produced mixture was mixed and heated incessantly until a clear and translucent liquid of NE was formed.

Mice sampling and administration

Ten normal mice served as the control (negative group) while 40 mice were intraperitoneally transplanted with EAC cells (2.5×10^6 cells/mouse). After 48 h, mice were randomly divided into equal four groups (n=10). One of the group served as the untreated positive control (EAC) while the other treated groups of Free MC, RCM-NE, and MC-RCM-NE were given once intraperitoneal of (200 µL normal saline contained 1 mg/kg⁻¹ MC)¹⁷, (200 µL of RCM-NE) and (200 µL RCM-NE contained 1 mg/kg⁻¹ MC), respectively. The experiment was followed for 7 consecutive days.

At the 9th day mice of all groups were anesthetized by diethylether and the blood was withdrawn from the venous sinus and collected either in blood collecting tubes for further CBC test or in plain tubes and allowed to clot at room temperature (25°C). After centrifugation of samples at 2500 rpm for 5 min, serum was collected and stored at -20°C for further biochemical analysis. Immediately after blood collection, mice were killed by cervical dislocation. Kidneys, heart and thymus were collected, washed with phosphate buffer saline (PBS, pH= 7.4) and were homogenized with an ultrasonic homogenizer in cold (phosphate buffer, pH= 7.0) for measuring of malondialdehyde (MDA), catalase (CAT), superoxide dismutase (SOD), glutathione reductase (GR) and thioredoxin reductase-1 (TrxR-1).

Evaluation of the hematological parameter

The influence of drug formulations on the hematopoietic system was evaluated by the CBC test using an automated hematology analyzer (Sysmex Corporation, Kobe, Japan).

Evaluation of organs indices

Organs indices give a general impression of organ toxicity. The indices of heart, kidney, and thymus were calculated according to the formula:

$$\text{organ index} = \frac{\text{organ weight (g)}}{\text{body weight (g)}} \times 100$$

Evaluation of biochemical analysis

Serum samples were utilized to evaluate the alkaline phosphatase (ALP), creatinine (CRE), blood urea nitrogen (BUN), creatinine kinase-MB, creatinine kinase (CK), lactate dehydrogenase (LDH), cholesterol and triglycerides (TAG) from Bio-diagnostic lab for diagnostic and research reagents (Cairo, Egypt).

Evaluation of lipid peroxidation and antioxidant activities

The tissue homogenates of kidney, heart, and thymus were used to estimate the levels of MDA, CAT, SOD, and GR that were supplied from the Biodiagnostic lab for diagnostic and research reagents (Cairo, Egypt) and TrxR-1 activity kit (ab83463) from (Abcam, USA).

Histopathological Studies

Tissue specimens of kidney, heart, and thymus from the mice groups were kept in a 10% neutral pH of formalin. The tissue slides were prepared

according to the standard techniques for staining by Hematoxylin and Eosin.

Statistical Analysis

Statistical analyses were performed using Mean \pm Sem or Mean \pm SD (n=10) using the MegaStat Excel (version 10.3, Butler University, Indianapolis, IN). The variances among the experimental groups were measured by one way ANOVA followed by Turkey post-hoc test. The variances were considered significant if values of $P < 0.05$.

Results

Hematological profile

Hematological parameters were examined in the experimental groups on the 9th day and summarized in (Table 1). When compared to the control group, the WBCs level was markedly elevated in the EAC group followed by free MC and RCM-NE groups while it was restored to a similar level in the MC-RCM-NE group. The lymphocytes were considerably decreased in EAC and all the treated groups relative to the control group. In contrast, the EAC group and the free MC group have revealed a remarkable elevation in neutrophils while no changes were reported in RCM-NE and MC-RCM-NE groups relative to the control. The monocyte counts were only raised in the free MC group. On the other hand, the platelet level was considerably lowered in free MC, EAC, and MC-RCM-NE groups relative to the control and RCM-NE groups. In terms of the RBCs and hemoglobin amounts, there were no considerable variations between the experimental groups.

Organ indices

The influence of the drug treatment on the WI of the internal organs was evaluated as shown in (Fig. 1). As compared to the control, the free MC group exhibited the least weight index of the kidney while EAC, RCM-NE, and MC-RCM-NE groups were comparable to the control. Regarding the WI of the thymus gland, EAC and MC-RCM-NE groups were similar to the control group contrary to the free MC group, which has revealed the least WI of the thymus. The WIs of the heart were not influenced by any of the formulations.

Biochemical parameters

In Figure 2, serum CRE and BUN were estimated to detect kidney injury there were no significant variations in the amount of BUN among all the groups. In the case of CRE, the inoculation of the tumor into mice induced a remarkable elevation in serum CRE by two-fold when compared to the control group. Besides, MC failed to restore the CRE level to be comparable to the control group. In contrast, RCM-NE and MC-RCM-NE groups have levels of CRE comparable to the control.

To detect the heart function, the levels of ALP, CK, CK-MB, and LDH were measured. Regarding the serum ALP levels, the EAC group has the highest level whereas the free MC group has the least level. The free MC group revealed the highest CK level relative to the other groups. On the other hand, all experimental groups have comparable CK-MB values. The LDH levels were significantly elevated in EAC and the treated groups when compared to the

Table 1 — The serum analysis of the hematological parameters of the experimental groups on day 9. Data were expressed as $\bar{X} \pm SD$. ANOVA test followed by Turkey's multiple comparison test and measuring the P -values for the pairwise t -test. The significant differences between the groups were classified statistically according to the * $P < 0.01$, ** $P < 0.001$ and *** $P < 0.0001$. The superscript letters (^{a,b,c,d}) refer to EAC, Free MC, RCM-NE and MC-RCM-NE, respectively

Parameters	P	Groups (n=10)				
		Control	EAC	Free MC	RCM-NE	MC-RCM-NE
WBCs $\times 10^3/\mu\text{L}$	0.0001***	*(c)**(b)***(a) 2.43 \pm 0.21	***(d) 4.65 \pm 0.37	** (d) 3.98 \pm 0.71	*(e) 3.56 \pm 0.27	2.47 \pm 0.63
Lymphocytes (%)	0.0006***	*** (a,b,c,d) 37.3 \pm 4.8	*(d) 22.00 \pm 1.1	*(e) 24.8 5 \pm 2.45	*(e) 24.1 \pm 1.00	15.15 \pm 2.45
Neutrophils (%)	0.007**	*(a)**(b) 4.05 \pm 0.50	*(c,d) 7.05 \pm 1.06	** (d,e) 8.15 \pm 2.05	4.41 \pm 0.41	4.15 \pm 1.63
Monocytes (%)	0.0004***	*** (b) 0.2 \pm 0.08	*** (b),*(d) 0.18 \pm 0.08	*** (c),** (d) 0.6 \pm 0.14	*(d) 0.14 \pm 0.01	0.35 \pm 0.70
Platelets $\times 10^3/\mu\text{L}$	0.006**	*(d)**(a)*** (b) 909 \pm 19.00	*(c) 839 \pm 16.00	*(d)**(c) 820.5 \pm 15.41	884 \pm 33.70	854.5 \pm 4.50
RBCs $\times 10^6/\mu\text{L}$	0.21	8.66 \pm 0.31	9.11 \pm 0.02	9.11 \pm 0.60	8.62 \pm 0.55	9.53 \pm 0.65
Hemoglobin(g/dL)	0.53	15.13 \pm 0.11	14.45 \pm 0.21	15.1 \pm 0.42	14.4 \pm 0.70	15 \pm 1.27

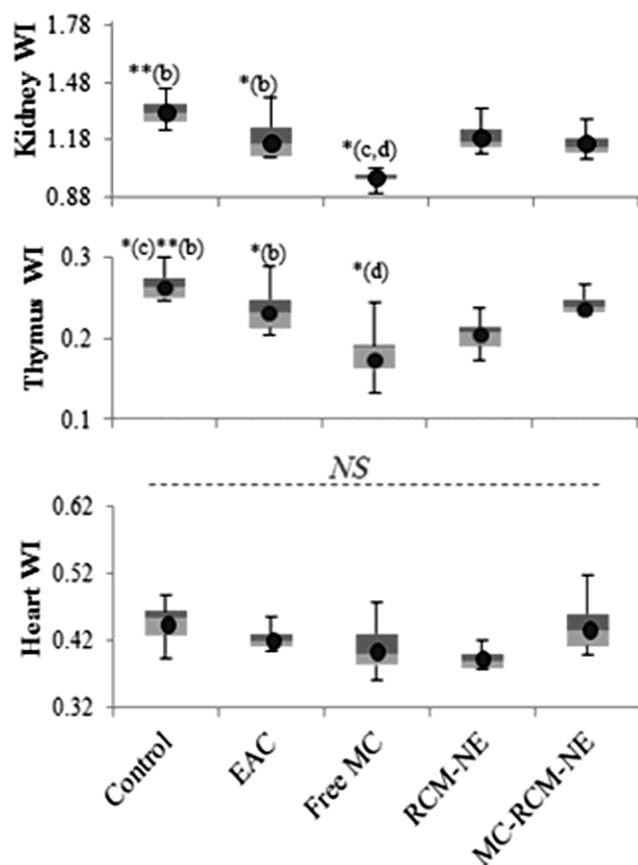


Fig. 1 — Box plots showing the weight index (WI) of kidney, heart and thymus for the experimental groups on day 9 of experiment after treated with different drug formulations. ANOVA test followed by Turkey's multiple comparison test and measuring the P -values for the pairwise t -test. The significant differences between the groups were classified statistically according to the NS : no significance, * $P < 0.01$, ** $P < 0.001$ and *** $P < 0.0001$. The superscript letters (^{a,b,c,d}) refer to EAC, Free MC, RCM-NE and MC-RCM-NE, respectively

control group. In particular, the free MC group has the highest LDH value while RCM-NE, MC-RCM-NE, and EAC groups have comparable LDH levels.

In terms of the lipid profile, the levels of cholesterol and TAG were significantly increased in the EAC group relative to the other groups. In fact, all of the treated groups have comparable cholesterol values. In contrast, the free MC group has less amount of TAG than the other treated groups.

Lipid peroxidation and antioxidant activities evaluation

Figure 3 depicts the antioxidant enzymes in the kidney, thymus and heart tissues in the experimental groups. All the treated groups have considerable high MDA levels in the kidney when compared to the control. In comparison to the EAC group, the

MC-RCM-NE group revealed a remarkable reduction in the MDA level of the kidney tissue, followed by RCM-NE and free MC groups which have similar MDA levels. Regarding the heart tissue, the free MC group has the highest MDA level among all of the experimental groups whereas the RCM-NE and MC-RCM-NE treated groups have revealed MDA levels comparable to the EAC and control groups. In terms of the thymus tissue, the administration of RCM-NE and MC-RCM-NE revealed a similarity in their levels of the MDA when compared to the EAC and control groups, while the thymus MDA in the free MC group was significantly higher than the control and EAC groups.

Regarding the CAT levels, the treated groups did not reveal any remarkable changes relative to the EAC group in the kidney tissues. In terms of the heart CAT, the levels were markedly increased in RCM-NE and MC-RCM-NE groups relative to the EAC group but they were similar in the free MC group. In the thymus tissue, the free MC group showed the highest level of CAT followed by MC-RCM-NE and RCM-NE groups when compared with EAC and control groups.

The SOD level in the kidney of the EAC group exhibited a considerable reduction relative to the control and the treated groups while no significant changes in the SOD of heart and thymus tissues were reported between the experimental groups. The GR levels in the three organ homogenates of the EAC group did not exhibit variations from the control. The administration of the free MC into the mice revealed the least level of GR in the entire tested organs when compared to the other groups. Subjecting MC-RCM-NE into the mice has caused a marked elevation in GR levels of the entire tested organs when compared to the free MC and RCM-NE groups. When compared to the same organ of the control group, the MC-RCM-NE group has lowered kidney GR level but it has comparable levels of heart and thymus GR levels.

When compared to the TrxR-1 with their levels of the same organ tissue of the EAC and control groups, the TrxR-1 levels of the free MC group were comparable in the kidney, increased in the heart and reduced in the thymus. In contrast, the MC-RCM-NE group has the highest level of TrxR-1 in the kidney and thymus among all of the experimental groups. In terms of the heart TrxR-1 level, it was raised in the MC-RCM-NE group when compared to the

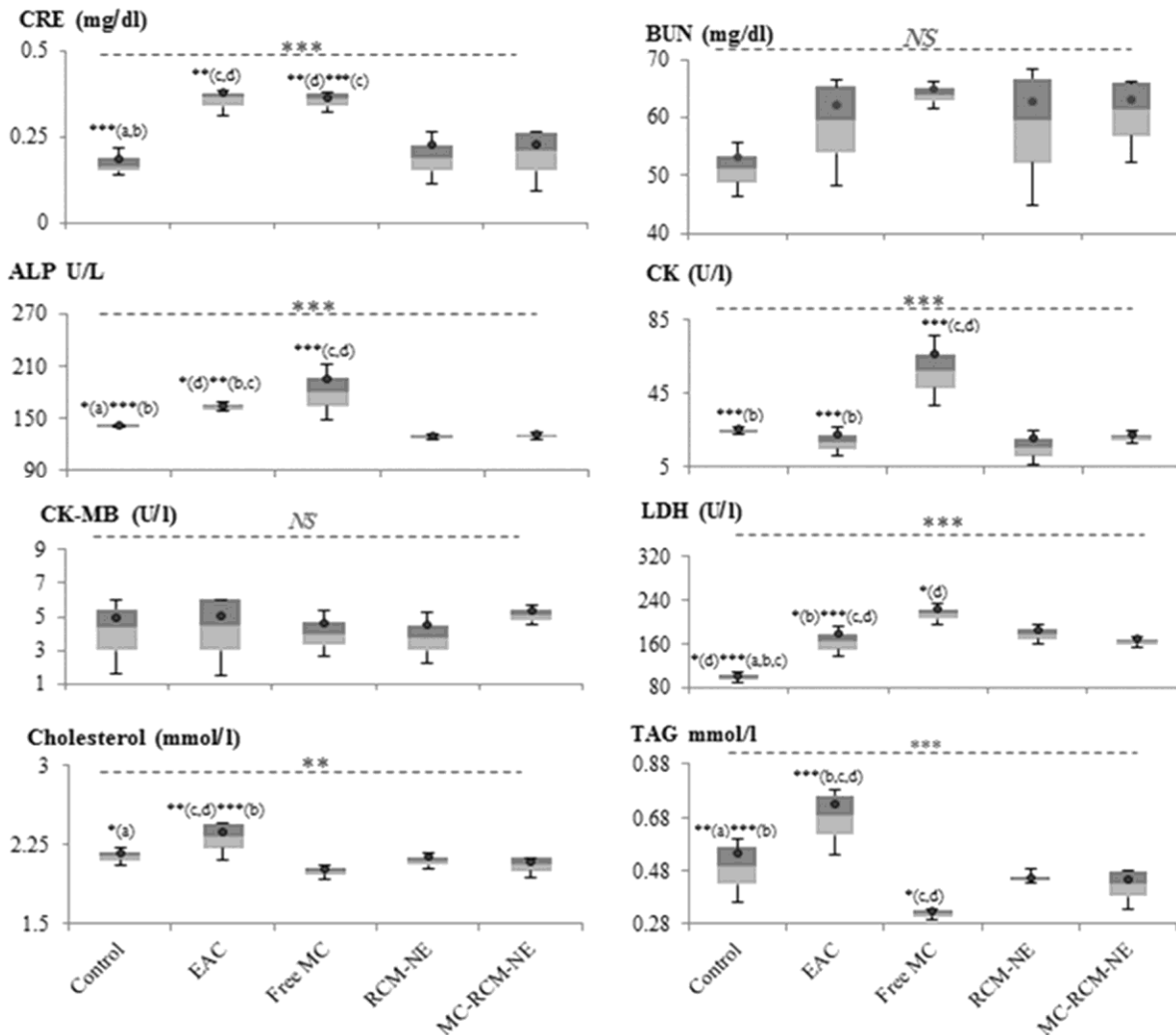


Fig. 2 — Box plots (median, interquartile range, 10 to 90th percentile and the blue dots which indicate the variable mean) showing the analysis of biochemical parameters in the experimental groups after treated with different drug formulations. ANOVA test followed by Turkey's multiple comparison test and measuring the *P*-values for the pairwise *t*-test. The significant differences between the groups were classified statistically according to the NS: no significance, **P* < 0.01, ***P* < 0.001 and ****P* < 0.0001. The superscript letters (a,b,c,d) refer to EAC, Free MC, RCM-NE and MC-RCM-NE, respectively

other tested groups except the free MC group has higher levels.

Histopathological examination

The histology of kidney in EAC bearing mice revealed almost similar kidney architecture as shown for the control group (Fig. 4A & B). The free MC treatment triggered degeneration, partial hyalinization of the glomerular tuft, the formation of fibrin thrombi in glomerular capillaries typical of thrombotic microangiopathy, and marked the degeneration of the renal tubules (Fig. 4C). However, the RCM-NE and MC-RCM-NE tissues showed the normal structure of the kidney and renal tubular cells with no glomerular damages (Fig. 4D & E).

Myocardium sections from EAC mice revealed nuclear changes in the form of pyknosis, karyolysis (Fig. 5A & B). In terms of free MC, the treated mice exhibited obvious widen spaces between the cardiac myocytes, nuclear changes in the form of pyknosis, karyolysis, presence of an infiltrated mononuclear cells and myocyte degeneration (Fig. 5C). However, the heart tissues of RCM-NE and MC-RCM-NE groups displayed cardiac myocytes nearly like that of the normal but certain nuclear changes in the form of pyknosis and karyolysis (Fig. 5D & E).

Examination of thymus tissue in the control mice exhibited the characteristic of the well-defined thymus architecture (Fig. 6A). EAC bearing mice have tissue architecture, (Fig. 6B), nearly like that of

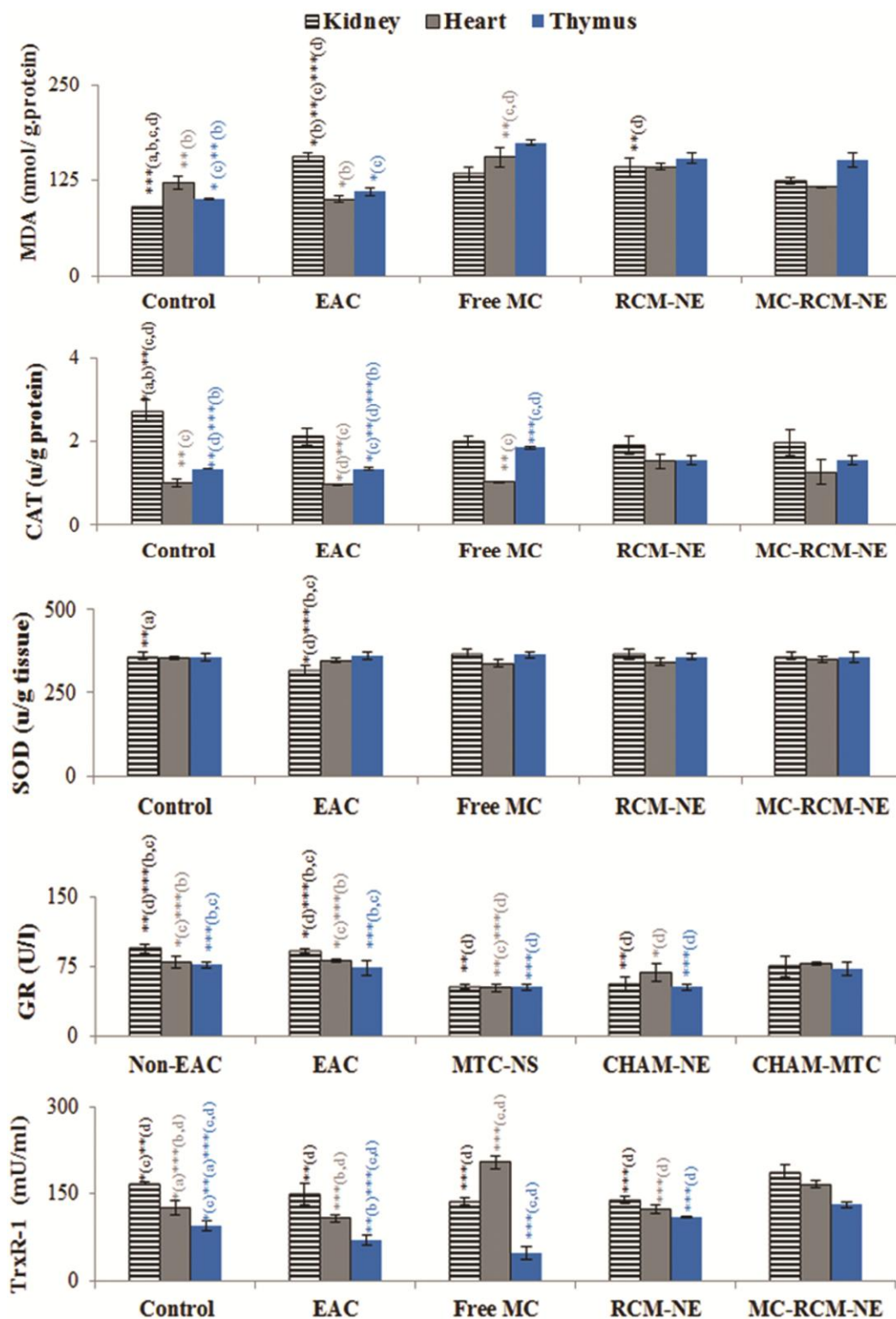


Fig. 3 — Analysis of antioxidant enzymes and lipid peroxidation levels from the kidney, heart and thymus homogenate of the experimental groups after treated with different drug formulations. Data were expressed in mean \pm SE, (n= 10). ANOVA test followed by Turkey's multiple comparison test and measuring the *P*-values for the pairwise *t*-test. The significant differences between the groups were classified statistically according to the **P* < 0.01, ***P* < 0.001 and ****P* < 0.0001. The superscript letters (^{a,b,c,d}) refer to EAC, Free MC, RCM-NE and MC-RCM-NE, respectively

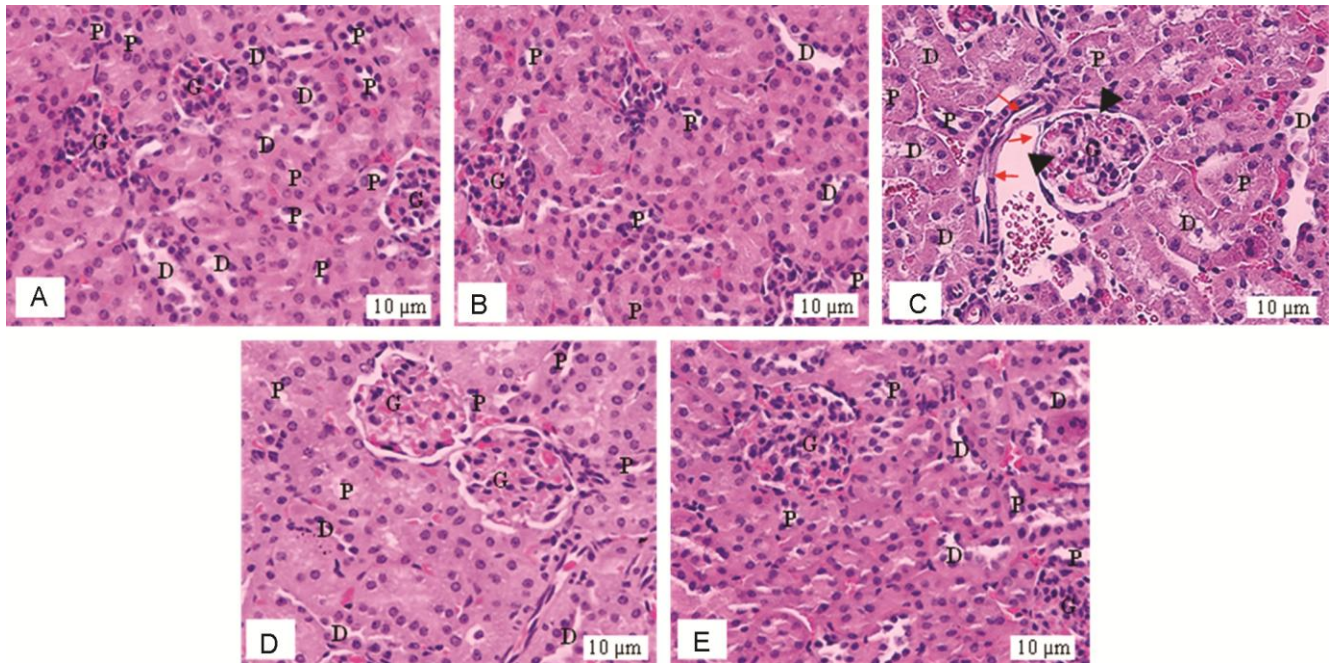


Fig. 4 — Photomicrographs of the kidney tissues stained with H and E stain ($\times 600$). (A) Control; (B) EAC mouse shows no histopathological changes in the glomeruli (G) and renal tubules (RT); (C) The kidney tissues of the EAC mouse received free MC shows degeneration and partial hyalinization of glomerular tuft, the presence of fibrin thrombi in glomerular capillaries typical of thrombotic microangiopathy (black arrows) and a marked degeneration of the renal tubules (red arrows). Kidney sections of the EAC mouse received; (D) RCM-NE; and (E) MC shows no histopathological changes

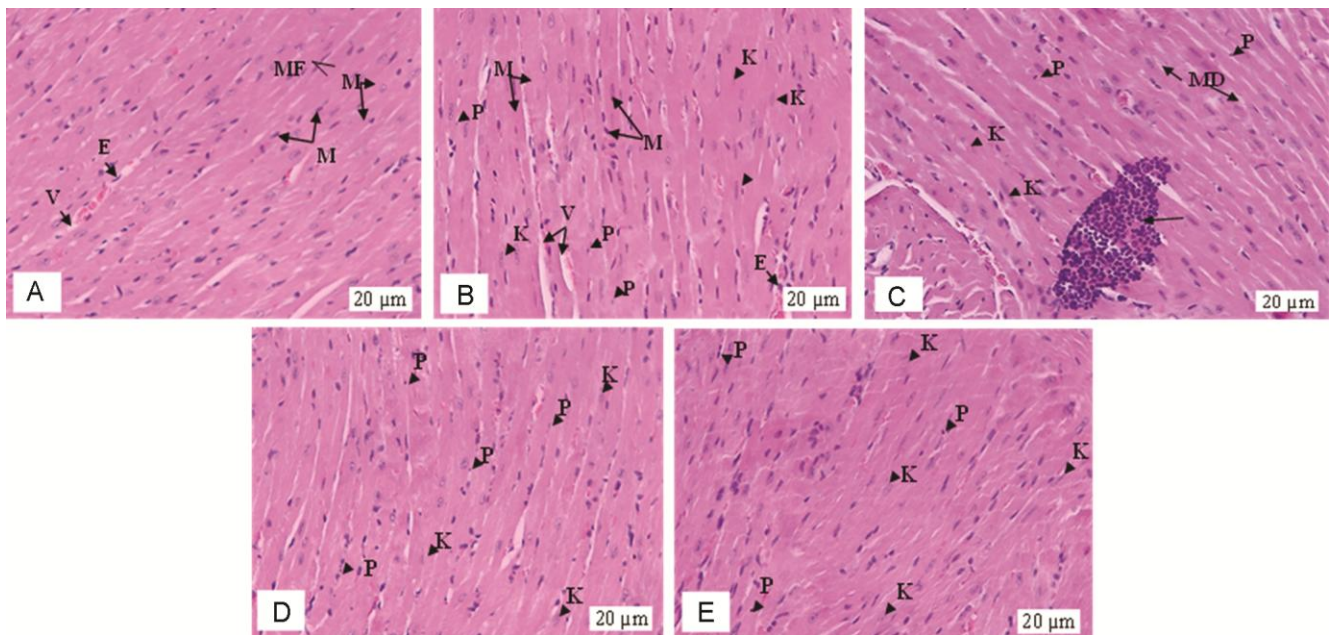


Fig. 5 — Photomicrographs of the myocardium tissue stained with H and E stain ($\times 400$). (A) Control; (B) EAC mouse shows normal architecture; microfibrils (MF); Myocytes (M); (MN) Myocytes Nuclei; (V) blood vessel; (EN) endothelial nuclei; (C) the myocardium tissue of EAC mouse treated with free MC shows widen spaces between the cardiac myocytes and nuclear changes in the form of pyknosis (P), karyolysis (K) and presence of a mononuclear infiltration with associated myocyte degeneration (MD); (D) RCM-NE; and (E) MC-RCM-NE shows cardiac myocytes nearly like that of the normal but nuclear changes in the form of pyknosis (P), karyolysis (K)

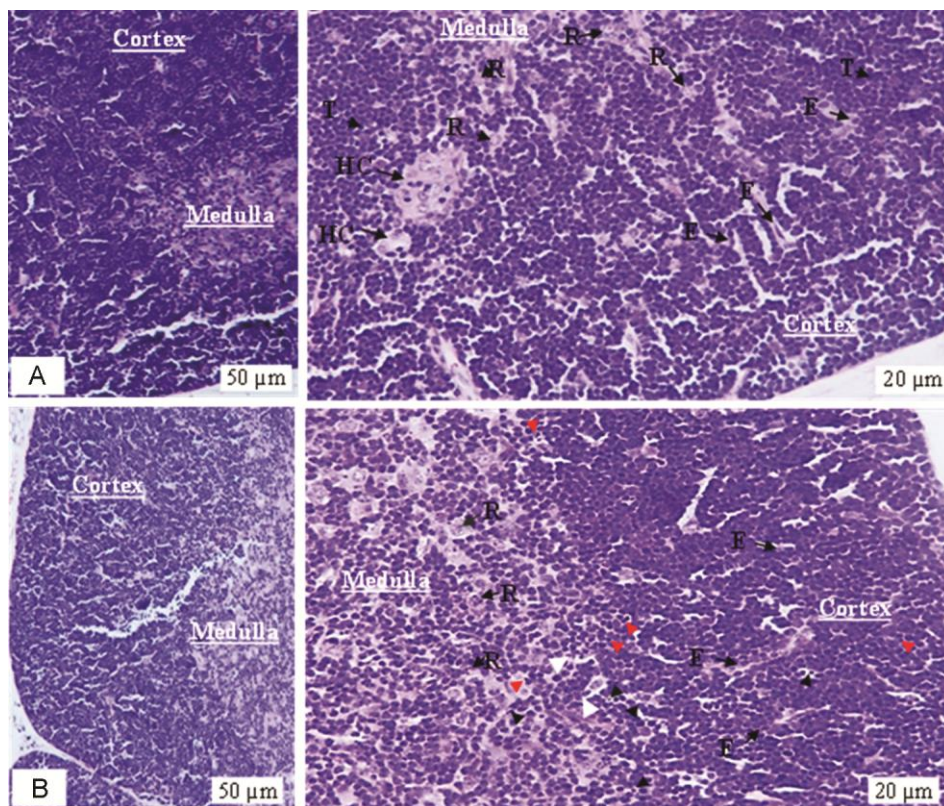


Fig. 6 —Photomicrographs of the cross-section in the thymus of control (A) and (B) EAC mouse stained with H and E stain ($\times 200$ & $\times 400$). The thymus cortex of control mice is condensed with thymocytes (T) along with a smaller amount of associated epithelial cells (E). Fewer thymocytes, reticuloendothelial cells (R) and Hassall's corpuscle (HC) are found in the medullary area. EAC mouse shows tissue architecture nearly like that of the control but there is shrinkage of individual thymocytes (redhead arrows), condensation of nuclear chromatin (pyknotic nuclei) and cytoplasmic organelles (blackhead arrows), which are subsequently phagocytized by macrophages (white arrows)

the normal but they revealed apoptosis in certain thymocytes compared with the control tissue. Thymus from the free MC treated mouse, shown in (Fig. 7A), exhibited obvious atrophy and the cortex becomes progressively thinner due to the strong depletion in the number of cortical thymocytes, leading to less distinct in the cortical-medullary junction. RCM-NE and MC-RCM-NE treated mice have revealed nearly similar thymus structure to the control (Fig. 7B & C).

Discussion

In the present study, the induction of tumor resulted in a remarkable elevation in the total count of WBCs and neutrophils relative to the control group as a result of a defensive mechanism towards the tumor cells¹⁸. On the other hand, the reduction in the lymphocytes of the EAC-bearing mice might stem from the immunosuppression induced by EAC progression¹⁹. One of the major standards for judging the effects of the compound is that its ability to

ameliorate the effect of cancer or chemotherapeutics on the blood of the tumor-bearing animals²⁰.

The administration of MC into the mice did not improve the hematological parameters induced by the tumor. The level of the inflammatory biomarker, monocytes that play important roles in the immune defense, inflammation²¹, and heart tissue remodeling²², was markedly enhanced in the free MC group relative to the EAC group which can be attributed to the cardiotoxicity induced by MC^{6,7}. In agreement with other previous works, the free MC group has the least platelet level among the experimental groups which might increase the risk of bleeding⁵.

In contrast to the free MC group, the administration of MC-RCM-NE into the mice has restored the WBCs, neutrophils, and monocytes towards the mean values of the control, implying that the mice started fighting off-tumor progression²³. Besides, the presence of RCM oil that has an anti-inflammatory

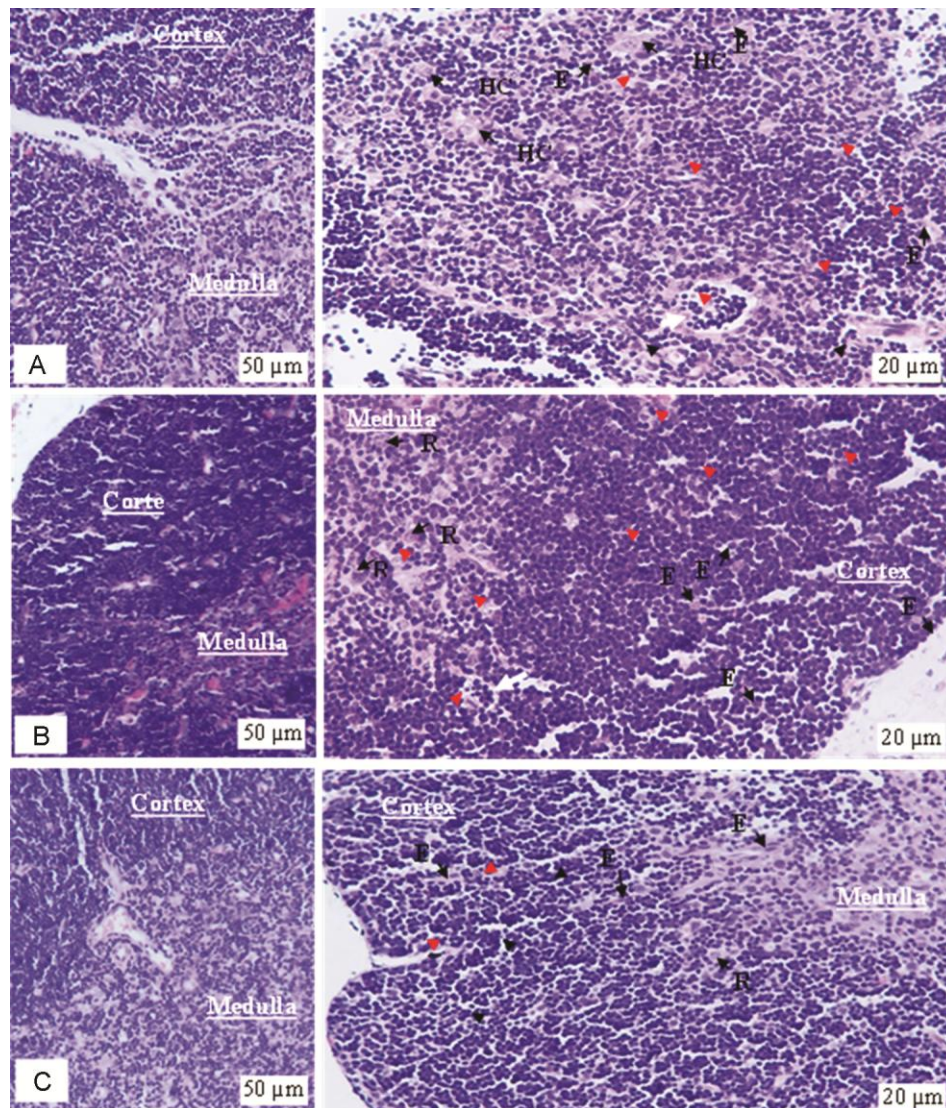


Fig. 7 — Photomicrographs of the cross-section in thymus stained with H and E stain ($\times 200$ & $\times 400$). (A) The thymus of EAC mouse received free MC shows thymic atrophy and the distinction between the thymic cortex and medulla is no longer visible due to thymocyte depletion. There is shrinkage of individual thymocytes and condensation of nuclear chromatin (redhead arrows), which are subsequently phagocytized by macrophages (white arrows) and increase the numbers of apoptotic thymocytes and macrophages (containing stainable bodies or cellular debris) giving this tissue a classic “starry sky” appearance at low magnification; (B) Thymus of EAC mouse received RCM-NE ;and (C) MC-RCM-NE, shows tissue architecture nearly like that of the control but there is shrinkage of certain individual thymocytes and condensation of nuclear chromatin (redhead arrows)

property in the combination formula may play a role in diminishing the hematotoxic effect of MC²⁴.

To evaluate the effect of the tested formulas on the kidney and heart, the WIs of these organs and the levels of selected biochemical parameters were estimated. Moderate toxicity was observed after free MC treatment, which produced an obvious reduction in WI of kidney relative to the other experimental groups. However, free MC failed to restore the elevation of CRE and ALP levels to be similar to the control which might be considered as an indication of

nephrotoxicity⁶. The impairment in renal functions after MC treatment was accompanied by significant elevation of tissue lipid peroxidation as reflected by an increase in kidney MDA level². Furthermore, the reduction in renal antioxidant enzymatic protection of CAT, GR and TrxR-1 could aggravate the oxidative damage. These observations are correlated with the renal histological findings which appeared as marked degeneration of the renal tubules, degeneration and the partial hyalinization of glomerular tuft and formation of fibrin thrombi in the glomerular

capillaries typical of thrombotic microangiopathy that resulted from the antiplatelet effect of MC²⁵.

The reduction of the TAG level after the MC treatment may be resulted from its inhibitory effect of lipid synthesis by lowering the activity of fatty acid synthase to reduce the tumor growth²⁶. The low serum TAG was found to increase the risk of cardiovascular death²⁷. In particular, the significant increase in cardiac MDA levels after free MC administration is an important pathogenic event in cardiotoxicity⁶. In terms of antioxidants measurements, the reduction of GR in the heart tissue was observed which is contributed to cellular detoxification of electrophilic substrates by conjugation reaction with reduced glutathione (GSH). In contrast GR, TrxR-1 was elevated in the free MC-treated group which is particularly important because its product, reduced thioredoxin (Trx-SH₂), serves as the principle reductant of GSH instead of the exhausted GR. Therefore, the elevation of MDA may be due to the potential role of MC to induce oxidative stress by the generation of free radicals that oxidize the polyunsaturated fatty acids in the cellular membrane, causing an outflow of the LDH and CK out the cardiomyocytes and increasing their levels in serum². Although the heart indices have not differed from the other experimental groups, the histology of heart showed morphological changes in myocardium appeared in widen spaces between the cardiomyocytes, changes of nuclei pyknosis or karyolysis form, presence of inflammatory mononuclear cells infiltrate and degeneration of myocytes.

In terms of the administration of MC-RCM-NE into the mice, the elevation of CRE and ALP were reduced while the normal level of CAT, GR and TrxR-1 were restored in the kidney to be comparable to the levels of the control. Regarding the heart of MC-RCM-NE, the CK, GR and TrxR-1 levels were comparable to the control. Although all treated groups have revealed a significant increase in serum LDH levels, the MC-RCM-NE group has the least LDH among the treated groups. Besides, mice receiving MC-RCM-NE has more TAG level than free MC. The restoration in the biochemical parameters and antioxidant system of the MC-RCM-NE group can be due to the inclusion of RCM oil in the subjected formula that contains phenolics which have potential reno- and cardioprotective effects^{11, 29}.

To declare the cytotoxic effect of MC in the thymus, the levels of MDA, CAT, SOD, GR, and TrxR-1 were measured. The results revealed a

remarkable inhibition of GR and TrxR-1 activity that lead to the breaking down of the defense system in thymocytes against the oxidative stress resulted from ROS and MDA levels raise³⁰. GR and TrxR-1 are the principle enzymes providing reducing equivalents to several cellular processes which are important for antioxidant defense, cell proliferation, and redox signaling³¹. Although the ROS plays as signaling molecules in immune cells and plays vital roles to regulate various cellular processes, thymocytes are particularly sensitive to oxidative stress³².

Also, increasing the CAT level in the free MC group may be considered as a way to protects thymocytes from MC-induced apoptosis³³. agreement with the antioxidant results, histology of thymus section obtained from MC-treated mouse exhibits thymic atrophy, reduction in weight index compared to the other treated groups which resulted from depleting of thymocytes in response to MC toxicity⁸. Therefore, injury to this lymphoid organ causes severe immunosuppression and affects negatively on the treatment by leaving the mice susceptible to infection.

In the case of MC-RCM-NE treatment, solubilizing of the MC into RCM-NE demonstrated the protective effect and a remarkable elimination of MC-induced oxidative stress and thymus toxicity by reducing the level of MDA along with improving the antioxidant levels CAT, GR and of TrxR-1. As a result, reversed thymus WI, and ameliorate the histological structure.

Conclusion

In this study, MC-RCM-NE attenuated the MC-induced oxidative stress and toxicity in the blood, kidney, heart, and thymus by inhibition of the level of MDA and improving the antioxidant enzyme system in the tested organs. The results were confirmed by histological improvements in the tested organs of treated mice and recovering of the organ weight indices. Our findings raise the possibility that RCM-NE combined with free MC or other types of chemotherapeutics may improve the quality and outcome of life for patients having cancer. However, the mechanisms at molecular levels behind the protective function and therapeutic efficacy of RCM-NE in combination with free MC treatment in the EAC-bearing mice need further studies.

Acknowledgment

The authors wish to express a sincere thanks and appreciation to King Abdul-Aziz City for Science and

Technology for its financial support to the research project designated by a number (1-17-01-009-0066).

Conflict of Interest

All authors declare no conflict of interest.

References

- Ko JC, Chen JC, Wang TJ, Zheng HY, Chen WC, Chang PY & Lin YW, Astaxanthin down-regulates Rad51 expression via inactivation of AKT kinase to enhance mitomycin C-induced cytotoxicity in human non-small cell lung cancer cells. *Biochem Pharmacol*, 105 (2016) 91.
- Maatouk M, Mustapha N, Mokdad-Bzeouich I, Chaaban H, Ioannou I, Ghedira K, Ghoul M & Chekir-Ghedira L, Heated naringin mitigate the genotoxicity effect of Mitomycin C in BALB/c mice through enhancing the antioxidant status. *Biomed Pharmacother*, 97 (2018) 1417.
- Shrivastava A, Aggarwal, LM, Mishra, SP, Khanna, HD, Shahi, UP & Pradhan S, Free radicals and antioxidants in normal versus cancerous cells—an overview. *Indian J Biochem Biophys*, 56 (2019) 7.
- Paz MM, Zhang X, Lu J & Holmgren A, A new mechanism of action for the anticancer drug mitomycin C: mechanism-based inhibition of thioredoxin reductase. *Chem Res Toxicol*, 25 (2012) 1502.
- Fang YP, Hu PY & Huang YB, Diminishing the side effect of mitomycin C by using pH-sensitive liposomes: *In vitro* characterization and *in vivo* pharmacokinetics. *Drug Des Devel Ther*, 12 (2018) 159.
- Rjiba-Touati K, Ayed-Boussema I, Belarbia A, Mokni M, Achour A, Bacha H & Abid S, Role of recombinant human erythropoietin against mitomycin C-induced cardiac, hepatic and renal dysfunction in Wistar rats. *Hum Exp Toxicol*, 34 (2015) 468.
- Madeddu C, Deidda M, Piras A, Cadeddu C, Demurtas L, Puzzone M, Piscopo G, Scartozzi M & Mercurio G, Pathophysiology of cardiotoxicity induced by nonanthracycline chemotherapy. *J Cardiovasc Med*, 17 (2016) S12.
- Wang J, Zhuo Y, Yin L, Wang H, Jiang Y, Liu X, Zhang M, Du F, Xia S & Shao Q, Doxycycline protects thymic epithelial cells from mitomycin C-mediated apoptosis *in vitro* via Trx2-NF- κ B-Bcl-2/Bax axis. *Cell Physiol Biochem*, 38 (2016) 449.
- El Asbahani A, Miladi K, Badri W, Sala M, Addi EA, Casabianca H, El Mousadik A, Hartmann D, Jilale A & Renaud F, Essential oils: from extraction to encapsulation. *Int J Pharm*, 483 (2015) 220.
- Tawfik S, Ahmed M, Said Z & Mohamed M, Cytogenetic and biochemical competency of chamomile essential oil against γ -rays induced mutagenic effects in mice. *Int J Radiat Res*, 16 (2015) 55.
- Al-Snafi AE, Medical importance of *Anthemis nobilis* (*Chamaemelum nobile*)-a review. *Asian J Pharm Sci Technol*, 6 (2016) 89.
- Alkhatib MH, Al-Otaibi WA & Wali AN, Antineoplastic activity of mitomycin C formulated in nanoemulsions-based essential oils on HeLa cervical cancer cells. *Chem Biol Interact*, 291 (2018) 72.
- Al-Otaibi WA, Alkhatib MH & Wali AN, Cytotoxicity and apoptosis enhancement in breast and cervical cancer cells upon coadministration of mitomycin C and essential oils in nanoemulsion formulations. *Biomed Pharmacother*, 106 (2018) 946.
- Tubtimsri S, Limmatvapirat C, Limsirichaikul S, Akkaramongkolporn P, Inoue Y & Limmatvapirat S, Fabrication and characterization of spearmint oil loaded nanoemulsions as cytotoxic agents against oral cancer cell. *Asian J Pharm*, 13 (2018) 425.
- Council NR. Guide for the care and use of laboratory animals: (National Academies Press) 2010.
- Thummar VR, Parasuraman S, Basu D & Raveendran R, Evaluation of *in vivo* antitumor activity of cleistanthin B in Swiss albino mice. *J Tradit Complement Med*, 6 (2016) 383.
- Devbhuti D, Gupta J & Devbhuti P, Studies on antitumor activity of *Bryophyllum calycinum* Salisb. against Ehrlich ascites carcinoma in Swiss albino mice. *J Pharma Sci Tech*, 2 (2012) 31.
- Salem ML, Shoukry NM, Tebeb WK, Abdel-Daim MM & Abdel-Rahman MA. *In vitro* and *in vivo* antitumor effects of the Egyptian scorpion *Androctonus amoreuxi* venom in an Ehrlich ascites tumor model. *Springer Plus*, 5 (2016) 570.
- Soliman AM, Fahmy SR&El-Abied SA, Anti-neoplastic activities of *Sepia officinalis* ink and *Coelatura aegyptiaca* extracts against Ehrlich ascites carcinoma in Swiss albino mice. *Int J Clin Exp Pathol*, 8 (2015) 35.
- Kundusen S, Bala A, Kar B, Bhattacharya S, Mazumder UK, Gupta M & Haldar PK, Antitumor potential of *Citrus limetta* fruit peel in Ehrlich ascites carcinoma bearing Swiss albino mice. *Altern Med Stud*, 2 (2012) 48.
- Chughtai A, Hasan W, Mahdi AA & Islam N, Effect of resveratrol on the biomarkers of oxidative stress and inflammation in monocyte cultures from pbmc's of patients with myocardial infarction. *Indian J Biochem Biophys*, 55 (2018) 328.
- Yang J, Zhang L, Yu C, Yang XF & Wang H, Monocyte and macrophage differentiation: circulation inflammatory monocyte as biomarker for inflammatory diseases. *Biomark Res*, 2 (2014) 21.
- Uribe-Querol E & Rosales C, Neutrophils in cancer: two sides of the same coin. *J Immunol Res*, 2015 (2015) 22.
- Aremu O, Tata C, Sewani-Rusike C, Oyedeji A, Oyedeji O & Nkeh-Chungag B, Phytochemical composition, and analgesic and anti-inflammatory properties of essential oil of *Chamaemelum nobile* (*Asteraceae* L All) in rodents. *Trop J Pharm Res*, 10 (2018) 1939.
- Matsumoto M, Fujimura Y, Wada H, Kokame K, Miyakawa Y, Ueda Y, Higasa S, Moriki T, Yagi H, Miyata T & Murata M, Diagnostic and treatment guidelines for thrombotic thrombocytopenic purpura (TTP) 2017 in Japan. *Int J Hematol*, 106 (2017) 3.
- Navarrete A, Armitage EG, Musteanu M, García A, Mastrangelo A, Bujak R, López-Casas PP, Hidalgo M & Barbas C, Metabolomic evaluation of Mitomycin C and rapamycin in a personalized treatment of pancreatic cancer. *Pharmacol Res Perspect*, 2 (2014) 67.
- Kozdag G, Ertas G, Emre E, Akay Y, Celikyurt U, Sahin T, Gorur G, Karazum K, Yilmaz I & Ural D, Low serum

- triglyceride levels as predictors of cardiac death in heart failure patients. *Tex Heart Inst J*, 40 (2013) 521.
- 28 Madonna R, Early diagnosis and prediction of anticancer drug-induced cardiotoxicity: from cardiac imaging to “Omics” technologies. *Rev Esp Cardiol*, 70 (2017) 576.
- 29 Ojha S, Azimullah S, Al Taei H & Meeran M, Cardioprotective effect of (-)- α -Bisabolol in animal model of myocardial infarction. *Planta Medica Int Open*, 4 (2017) 83.
- 30 Premkumar K, Pachiappan A, Abraham SK, Santhiya S, Gopinath P & Ramesh A, Effect of *Spirulina fusiformis* on cyclophosphamide and mitomycin-C induced genotoxicity and oxidative stress in mice. *Fitoterapia*, 72 (2001) 906.
- 31 Witte AB, Anestål K, Jerremalm E, Ehrsson H & Arnér ES, Inhibition of thioredoxin reductase but not of glutathione reductase by the major classes of alkylating and platinum-containing anticancer compounds. *Free Radic Biol Med*, 39 (2005) 696.
- 32 Circu ML & Aw TY, Reactive oxygen species, cellular redox systems, and apoptosis. *Free Radic Biol Med*, 48 (2010) 749.
- 33 Tome ME, Baker AF, Powis G, Payne CM & Briehl MM, Catalase-overexpressing thymocytes are resistant to glucocorticoid-induced apoptosis and exhibit increased net tumor growth. *Cancer Res*, 61 (2001) 2766.