

CASE REPORT

A Unique Presentation of Concomitant Hypo-Hyperdontia in Seven Year Old Child: A Rare Report

Sreekanth K. Mallineni¹, Azher Mohiuddin², Anil K. Patil¹, Ranvitha P. Kodali³

¹*Department of Pedodontics and Preventive Dentistry, SDDCH, Parbhani, MS, India*

²*Consultant Oral Surgeon, Vasan Dental Care Hyderabad, Telangana, India*

³*SRM Dental College, Ramapuram, Chennai, TN, India*

Correspondence e-mail to: drmallineni@gmail.com

ABSTRACT

Numerical variations of teeth are common. Hypodontia considered being presence of less number of teeth in normal complement while extra teeth to normal dentition are considered as hyperdontia. Hypodontia and hyperdontia are two opposite numerical variations of human dentition and occurrence of these two conditions is called as concomitant hypo-hyperdontia. The occurrence of hypo-hyperdontia in a patient is common. This report describes a rare occurrence of conical shape supernumerary teeth in premolar region and agenesis of tooth 55 and 81 in primary dentition and teeth 15, 25 and 41 in permanent dentition.

Keywords: agenesis, hypodontia, hyperdontia, hypo-hyperdontia, teeth

INTRODUCTION

Congenital missing of one or multiple teeth is called hypodontia. The absence of one, or more teeth has been called oligodontia, while, anodontia is total absence of dental structures. The prevalence of hypodontia ranges from 0 to 4.1% in the primary dentition¹ and 2.3-11.3% in permanent dentition.² Hypodontia is commonly seen in anterior region that the posterior region in primary dentition. Mandibular arch frequently affected than the maxillary arch.³ Mandibular incisors are common missing tooth type in primary dentition,³ and mandibular second premolars followed by mandibular incisors in permanent dentition.⁴

Hyperdontia refers to more or extra teeth to normal complement, or abnormal teeth. These supernumerary teeth can arise as a result dichotomy, or extra budding of the dental lamina and the exact etiology is not clearly documented.⁵ Several reports have indicated that there is a racial difference in the incidence of hyperdontia. The literature indicates a range from 0.1 to 7.8% in primary dentition¹ and 0.4-3.4% in permanent dentition.² Boys are frequently effected in primary dentition and permanent dentition.² Supernumerary teeth are commonly seen in the anterior region of the

maxilla, and conical shaped mesiodens is frequent type. However, occurrence of conical shaped supernumerary tooth in premolar region is extremely rare.

Hypodontia and hyperdontia are two extreme alterations in the development of the dentitions. The term “concomitant hypo-hyperdontia” has been used to describe the presentation of hypodontia and hyperdontia in the same individual.⁶ Concomitant occurrence of both hypodontia and hyperdontia in the same individual (hypo-hyperdontia) is a condition of mixed numeric variation. Although, the existing literature shows exclusively either hypodontia or hyperdontia, however, only a few case studies and reports have been accounted the occurrence of both these numeric anomalies in the same individual.^{7,8} Therefore, the purpose of this report is to describe a rare case of concomitant hypo-hyperdontia involving agenesis of both second premolars and primary second molar in maxillary arch and mandibular incisor in both primary and permanent dentitions with the presence conical shaped supernumerary tooth in premolar region.

CASE REPORT

A 7-year-old boy visited pediatric dental clinic with the chief complaint of unerupted teeth upper front region. His medical and dental histories were noncontributory and he is first child to a non-healthy couple. Extra oral examination showed a symmetrical face, competent lips with convex profile. Intra-orally he presented with early mixed dentition and his oral hygiene was fair. No active carious lesions noted. Clinically tooth 55 and one mandibular primary incisor were congenitally missing and hypoplastic spot was observed on tooth 85 (Figure 1). Radiographic examination revealed congenitally missing teeth 55 in primary dentition, teeth 15, 25, and 41 were missing in permanent dentition (Figure 2) and teeth 16, and 26 exhibited taurodontism. Additionally a conical shaped impacted supernumerary tooth was present in tooth premolar region (Figure 3). Parents confirmed only tooth in lower arch and three teeth in upper arch were exfoliated in recent days, which helped the diagnosis of congenitally missing incisor in mandibular arch. Based on clinical and radiographic findings along with dental history the diagnosis was made concomitant hypo-hyperdontia. The findings were explained to the patients parents and patient monitored for eruption of maxillary incisors. Composite restoration was done on tooth 85 and fissure sealants were placed on all permanent molars. Subsequently, teeth 11, 21 were erupted and patient is under review, in our pediatric dental clinic.

DISCUSSION

The reported prevalence range from 0.002 to 3.1% and most of the reported cases of concomitant hypo-hyperdontia involved both the maxillary and the mandibular arches.^{7,8} Most of the cases with concomitant hypo-hyperdontia were identified accidentally on regular examination. It has been reported by several authors the combination of both hypodontia and hyperdontia in both arches.⁷⁻⁹ The etiology of concomitant hypo-hyperdontia remains unclear and it is not clearly documented. Although, several theories, including atavism, dichotomy, hyperactivity of the dental lamina, and the concept of multi-factorial inheritance, have been proposed to explain the etiology of supernumerary teeth are common in males.⁵ Similarly, several hypotheses have been disseminated on the selectivity of tooth agenesis; the concept of a polygenic multi-factorial model of etiology still provides a good explanation for hypodontia, which are common in females.^{4,10} Furthermore, syndromic hypo-hyperdontia also has been reported.⁹ This rare identity in two siblings which may suggest further research on genetic inheritance and familial occurrence of concomitant occurrence of hypo-hyperdontia.^{11,12} A recent study from Poland showed that concomitant hypo-hyperodontia is rare

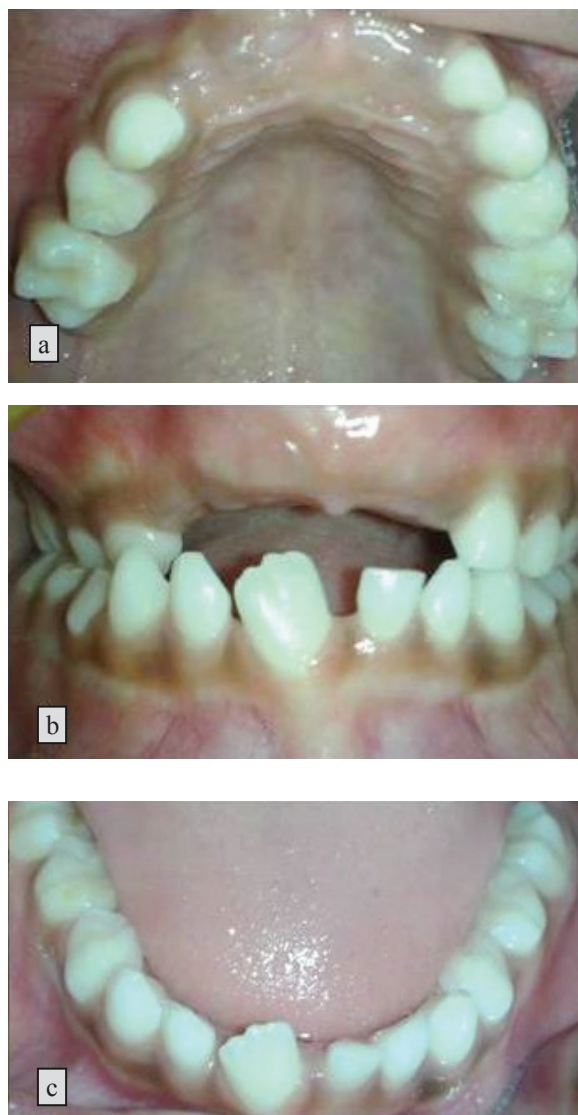


Figure 1. Intra-oral views of maxillary and mandibular arch

and sex-related, with predominance of hypodontia.¹⁰ Although, genetic and environmental factors have been proposed to explain both hypodontia and hyperdontia; while same identities have been adapted for this concomitant occurrence.⁷⁻⁹

Supernumerary teeth may be single or multiple, unilateral or bilateral in distribution, can occur in both dental arches, and either in the primary mixed or permanent dentitions.^{5,7,8} The mesiodens are the most commonly occurring supernumerary teeth followed by mandibular supplemental premolars.¹³ Surprisingly, the patient in the present report exhibited conical shape supernumerary tooth in the premolar region of the maxillary arch. A recent meta-analysis for the Caucasian population reported that the mandibular second premolars were the most frequently missing permanent tooth after the third molars, and mandibular

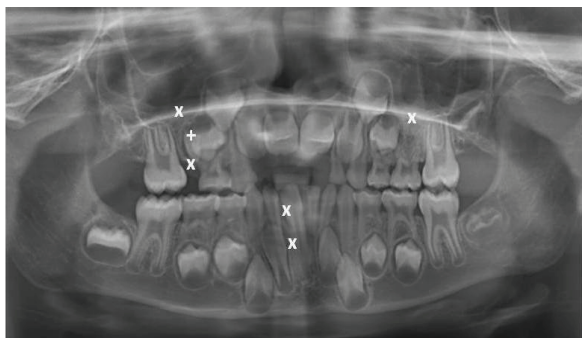


Figure 2. Panoramic radiograph showing agenesis of teeth 15, 55, 25, 81 and 41 (X) and presence of conical shaped supernumerary tooth (+) in premolar region

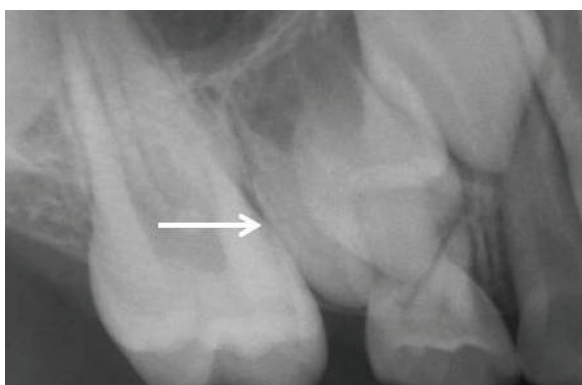

Figure 3. Intra-oral periapical radiograph showing conical shaped supernumerary tooth in premolar region

incisors in Asian populations.⁴ It has also been reported that the unilateral form of dental agenesis was more common than the bilateral version.^{4,14,15} Single mandibular central incisor in mandible has been reported and authors stated found the association with chromosome 18p.¹⁶ Similarly, in the present case unilateral absence of central incisor was evident in both primary and permanent dentition. However, genetic analysis has not been taken place. Previous dental history is necessary to eliminate the possibility of extraction of a normal tooth before diagnosis of hypodontia.¹⁷ In our case extraction of any tooth has not taken place, which was informed by parents. Contrarily, in present case two second premolars in maxillary arch and one mandibular incisor in mandibular arch were congenitally missing along with presence of conical shape supernumerary teeth in premolar region.

Most recently, the association among concomitant hypo-hyperdontia and taurodontism has been documented.¹⁸ Also, dens evaginatus¹⁹ and double tooth²⁰ have been reported in association with concomitant hypo-hyperdontia. Likewise, in present case patient exhibited enamel hypoplasia in tooth 85 and taurodontism teeth

16, and 26, may be these findings are coincidental. Kan and colleagues²¹ reported that taurodontism is associated with nonsyndromic hypodontia. They concluded children with multiple teeth missing are more prone to taurodontism compared to children who are missing only a single tooth. Similarly, in our case taurodontism was evident due multiple missing teeth.

The diagnosis of concomitant hypo-hyperdontia in our case was only an incidental finding, which is similar to most of the findings that has been reported. Moreover, it has been stated that a high proportion of patients with concomitant hypo-hyperdontia may remain undiagnosed in the population.^{7,8,22} The case in present report created a dilemma in diagnosis of missing central incisor in primary dentition however, past dental history helped in diagnosis. The first instance in clinical scenario and it is very difficult to diagnosis the concomitant hypo-hyperdontia in a growing child. It also been stated that use of radiographs may enhances the detection of concomitant hypo-hyperdontia and leads to changes in the path of management.^{7,9,22} Early diagnosis is a key for the triumphant management, since it permits the clinician to implement the most apt treatment options for the patient. The treatments may differ from individual to individual Change the sentence to: Studies showed low reliability of panoramic radiograph for diagnosis of supernumerary teeth along with clinical examination.

To the best of the author's knowledge concomitant hypo-hyperdontia involving both dentition and both arches involving both anterior and posterior region has not been reported. Interestingly, in present case tooth 55 in primary dentition and tooth 15 in permanent dentition were congenitally missing and additional to that conical shaped supernumerary tooth was present in that region. These findings itself are novel presentations for existing literature. Supernumerary tooth in premolar region would monitor until eruption and considered for extraction. Presently patient was kept under review.

CONCLUSION

Concomitant hypo-hyperdontia is an uncommon finding. This is only a case of rare presentation of conical shape supernumerary tooth in maxillary premolar region and agenesis of second primary molar and maxillary second premolars and mandibular incisors. The associations of taurodontism and enamel hypoplasia with this condition were reported for the first time. Besides, this condition which might be diagnosed by routine clinical and radiographic examinations along with past dental history. The present case is unique presentation of hypo-hyperdontia.

REFERENCES

1. King NM, Tongkoom S, Itthagaran A, Wong HM, Lee CK. A catalogue of anomalies and traits of the primary dentition of southern Chinese. *J Clin Pediatr Dent.* 2008;32:139-46.
2. Tsai SJ, King NM. A catalogue of anomalies and traits of the permanent dentition of southern Chinese. *J Clin Pediatr Dent.* 1998;22:185-94.
3. Brook AH. Dental anomalies of number, form and size: their prevalence in British schoolchildren. *J Int Assoc Dent Child.* 1974;5:37-53.
4. Polder BJ, Van't Hof MA, Van der Linden FP, Kuijpers-Jagtman AM. A meta-analysis of the prevalence of dental agenesis of permanent teeth. *Community Dent Oral Epidemiol.* 2004;32:217-26.
5. Mallineni SK. Supernumerary teeth: Review of the literature with recent updates. *Conference Papers in Science.* 2014, Article ID 764050, 6; 2014. doi: 10.1155/2014/764050.
6. Camilleri GE. Concomitant hypodontia and hyperdontia: Case report. *Br Dent J.* 1967;123:338-9.
7. Anthonappa RP, Lee CK, Yiu CK, King NM. Hypohyperdontia: literature review and report of seven cases. *Oral Surg Oral Med Oral Pathol Oral Radiol Endod.* 2008;106: e24-30.
8. Mallineni SK, Jayaraman J, Yiu CK, King NM. Concomitant occurrence of hypohyperdontia in a patient with Marfan syndrome: a review of the literature and report of a case. *J Investig Clin Dent.* 2012;3:253-7.
9. Varela M, Arrieta P, Ventureira C. Non-syndromic concomitant hypodontia and supernumerary teeth in an orthodontic population. *Eur J Orthod.* 2009;31:632-7.
10. Zadurska M, Sieminska-Piekarczyk B, Maciejak D, Wyszomirska-Zdybel B, Kurol J. Concomitant hypodontia and hyperodontia-An analysis of nine patients. *Acta Odontol Scand.* 2012;70:154-9.
11. Hattab FN, Yassin OM, Sasa IS. Oral manifestations of Ellis-van Creveld syndrome: report of two siblings with unusual dental anomalies. *J Clin Pediatr Dent.* 1998;22:159-65.
12. Sharma A. A rare case of concomitant hypohyperdontia in identical twins. *J Indian Soc Pedod Prev Dent.* 2008;26(Suppl):S79-81.
13. Mallineni SK, Nuvvula S. Management of supernumerary teeth in children: A narrative overview of published literature. *J Cranio-Max Dis.* 2015;4:62-8.
14. Mallineni SK, Yiu CK, King NM. Schwartz-Jampel syndrome: a review of the literature and case report. *Spec Care Dentist.* 2012;32:105-11.
15. Nuvvula S, Kiranmayi M, Shilpa G, Nirmala SV. Hypohyperdontia: Agenesis of three third molars and mandibular centrals associated with midline supernumerary tooth in mandible. *Contemp Clin Dent.* 2007;1:136-41.
16. Pfeiffer RA, Hertrich K, Cohen M. Single mandibular incisor in a patient with del (18p) anomaly. *Clin Genet.* 1994;46:430-2.
17. Grahnen H, Granath LE. Numerical variations in primary in primary dentition and their correlation with the permanent dentition. *Odontol Revy.* 1961;12:348-57.
18. Nirmala SV, Mallineni SK, Nuvvula S. Pre-maxillary hypo-hyperdontia: Report of a rare case. *Rom J Morphol Embryol.* 2013;54:443-5.
19. Manjunatha BS, Nagarajappa D, Singh SK. Concomitant hypo-hyperdontia with dens invaginatus. *Indian J Dent Res.* 2011;22:468-71.
20. Sharma A. Concomitant hypo-hyperdontia: Report of two cases. *Indian J Dent Res.* 2012; 23:700.
21. Kan WY, Seow WK, Holcombe T. Taurodontism in children with hypodontia and supernumerary teeth: a case control study. *Pediatr Dent.* 2010;32:134-40.
22. Mallineni SK, Nuvvula S, Cheung A, Kunduru R. A comprehensive review of the literature and data analysis on hypo-hyperdontia. *J Oral Sci.* 2014;56:295-302.

(Received September 7, 2015; Accepted October 30, 2015)