

Journal of Dentistry Indonesia 2014, Vol. 21, No. 1, 27-31
doi:10.14693/jdi.v0i0.175

CASE REPORT

Valacyclovir in the Management of Recurrent Intraoral Herpes Infection

Manuel DH. Lugito¹, Siti A. Pradono²

¹Oral Medicine Residency Program, Faculty of Dentistry, Universitas Indonesia, Jakarta 10430, Indonesia

²Department of Oral Medicine, Faculty of Dentistry, Universitas Indonesia, Jakarta 10430, Indonesia

Correspondence e-mail to: mdhlcc@yahoo.com

ABSTRACT

Infection by Herpes Simplex Virus (HSV) type I and II cause a worldwide medical problems. HSV-I infections are common in oral and perioral area. After primary infection, HSV becomes latent in the dorsal root ganglia and recurrences are caused by many stimuli. Antiviral agents, prevention of transmission, suppression of recurrences are current management of HSV infection. **Objective:** to discuss the management of Recurrent Intraoral Herpes (RIH) infection. **Case report:** a 21 years old female patient came to hospital with irregular painful ulcers in her mouth preceded by prodrome, followed with eruption and outbreak of vesicles. The first laboratory examination confirmed high titer of reactive Immunoglobulin M (IgM) and IgG of anti HSV-I and HSV-II. She was diagnosed to have RIH and treated with oral Acyclovir, multivitamins, immune stimulant and 0.2% chlorhexidine gargle with good healing. Oral Valacyclovir was given after she had another recurrence, with the result of low episodes of RIH and continuous titer improvement of reactive IgM and IgG of anti HSV-I and HSV-II. **Conclusion:** Oral administration of Valacyclovir as a the oral prodrugs of Acyclovir is effective prophylactic and therapeutic option with many advantages against HSV infection.

ABSTRAK

Penatalaksanaan infeksi Herpes berulang dengan valacyclovir. Infeksi *Herpes Simplex Virus* (HSV) tipe I dan II mengakibatkan masalah kesehatan di seluruh dunia. Infeksi HSV-I sering mengenai daerah oral dan perioral. Setelah infeksi primer, HSV menjadi laten di ganglion dorsal dan kambuh yang dipicu oleh berbagai stimuli. Penatalaksanaan infeksi HSV adalah pemberian obat antivirus, pencegahan transmisi, penurunan tingkat kekambuhan. **Tujuan:** membahas penatalaksanaan infeksi Herpes intraoral berulang. **Laporan kasus:** pasien perempuan 21 tahun datang ke rumah sakit dengan ulser ireguler yang sakit di rongga mulut dan didahului oleh gejala prodromal, timbulnya vesikel yang kemudian pecah. Hasil pemeriksaan laboratorium menunjukkan titer Immunoglobulin (Ig) M dan IgG anti HSV-I dan II yang reaktif. Acyclovir, multivitamin, stimulus imun, obat kumur klorheksidin 0,2% diberikan dan pasien sembuh. Valacyclovir oral diberikan setelah pasien mengalami kekambuhan dengan hasil penurunan tingkat rekurensi dan perbaikan titer reaktif IgM dan IgG anti HSV-I dan II. **Simpulan:** valacyclovir oral sebagai obat *prodrug* Acyclovir yang efektif dalam terapi dan profilaksis dengan berbagai keuntungan dalam mengobati infeksi HSV.

Key words: acyclovir, recurrent intraoral herpes, valacyclovir.

INTRODUCTION

The Herpes Simplex Viruses type I (HSV-I) and type II (HSV-II) belong to the α – Herpesviridae and cause a wide variety of clinical disorders.¹⁻⁶ HSV infections on humans are depending on the antigenic type of the virus, site of inoculation and response of host immune.⁷ Recurrent intraoral herpes (RIH) infection is less common in an immunocompetent host than Recurrent Herpes Labialis (RHL). HSV-II infection is the most

prevalent cause of genital ulcerations of sexual nature worldwide.¹ The prevalence of HSV-I infection is 45% to 98% of the world population and increases from childhood to adulthood (70-80%) with seroprevalence higher in lower socioeconomic groups. The HSV-II seroprevalence has increased with 20% to 25% of US adult have positive for HSV-II antibodies by the age of 40.^{1,5}

Primary HSV-I (90% of cases) and HSV-II (occasionally) infection in human oral site is known as primary herpetic gingivostomatitis and transmitted by direct contact of mucous membranes or abraded skin to the lesions or mucosal secretions of an active primary or recurrent infection.^{1,8} HSV invades epithelial cells and replicate intracellular at site of primary exposure.¹

After primary infection, HSV ascends through the periaxonal sheath of sensory nerves to the trigeminal, cervical, lumbosacral or autonomic ganglia of the host nervous system.^{1,6} Virus replicates and exists in an immunologically shielded state until reactivation is triggered spontaneously sometimes periodically by different stimuli e.g exposure to ultraviolet light, mechanical trauma, cosmetic disfigurement, psychological distress, fever, dietary factors and immunosuppression.^{1,3,5}

Current management of HSV infection is to prevent transmission, suppress of recurrence, attenuate of clinical course, viral shedding complications, palliation, avoidance of trigger factors and promotion of healing. Antiviral agents ec Acyclovir and Valacyclovir have been used in the treatment of HSV infections.¹⁻⁶

In this case report, we discuss the management of a 21 years old immunocompetence female patient with RIH who has frequent recurrent episodes. She was treated with systemic Acyclovir, immune supplement and then Acyclovir was replaced with Valacyclovir and instruction to prevent transmission.

CASE REPORT

Female patient, 21 years old came to the Oral Medicine Clinic RSCM with chief complaint of painful ulcers in her mouth since 3 days ago. Previously, she had prodrome symptoms followed by vesicles eruption on labial, buccal mucosa, lateral and dorsum of the tongue then ruptured in 1-2 days after forming irregular pattern (Figure 1). Tenderness and swelling of submandibular and servical lymph nodes were documented. The patient always has a recurrent oral ulcers before menstruation and often get cough, flu, sleep disturbance. Previously in 2010, she had Herpes infection according to the dermatologist. The immunology examination of serum specimen confirmed seropositive 2.46x increase in titer of Immunoglobulin M (IgM) of anti HSV-I and 7.03x titer of Immunoglobulin G (IgG) of anti HSV-I, 1.02x titer of IgM of anti HSV-II and 1.72x titer of IgG of anti HSV-II (normal range titer : <0.9). The haematology examination showed low count of Hemoglobin (Hb) and Eritrocyte Sedimentation Rate (ESR). She was diagnosed to have RIH infection.

Acyclovir 200mg 5 times a day for 10 days, multivitamins, and 0.2% Chlorhexidine were given and after 10 days, the ulcers were healed. We instructed the patient to avoid sun exposure and use sunscreen. Two months later, new vesicles were found on palatal, labial mucosa, dorsum and lateral of the tongue. The patient's obedience to accomplish Acyclovir 5 times a day was poor. Acyclovir was substituted with Valacyclovir 500mg twice a day for 15 days with the result no new vesicles were erupted and the ulcers were healed. Unfortunately the patient's condition was exhausted with sleep disturbance and new vesicles were found on labial mucosa, dorsum and ventral and apex of the tongue although the patient continued with Acyclovir 200 mg 5 times a day after Valacyclovir was run out. She still consumed immune supplement 3 times a day. The recurrence of HSV infection on lateral of the tongue need to be treated again with Valacyclovir 500mg 3 times a day for two weeks with the result of no new vesicles and ulcers. Episodes of recurrent of HSV infection were decreased into 1 episode per month and Acyclovir 200mg 3 times a day for 28 days was given as prophylaxis treatment.

We performed Polymerase Chain Reaction (PCR) to detect DNA of HSV on an lower labial mucosa ulcer by swabbing vigorously using sterile cotton swab and immediately sent the sample to the Departement of Microbiology FKUI/RSCM using freezed container. The result of PCR was negative with no finding of DNA band of HSV. The immunology examination of serum specimen confirmed seropositive 5.75x increase in titer of IgM of anti HSV-I, 1.99x IgG of anti HSV-I, 0.44x IgM of anti HSV-II, 0.94x IgG of anti HSV-II (normal range titer: <0.9). The haematology examination showed low count of hematocrit (Ht), neutrophils and increased of Erythrocyte Sedimentation Rate (ESR), monocyte, blood creatinine.

Because of low patient's obedience and suspected clinical resistance of Acyclovir, the medication was substituted with Valacyclovir 500mg twice daily for one month as prophylactic therapy for HSV infection with under supervision for any side effects of Valacyclovir. After a month of Valacyclovir, the immunology examination confirmed seropositive 2.74x increase in titer of IgM of anti HSV-I, 4.65x IgG of anti HSV-I, 0.66x IgM of anti HSV-II, 0.93x IgG of anti HSV-II (normal range titer :<0.9). The haematology examination showed low count of Hematocrit (Ht), neutrophils and increased of Eritrocyte Sedimentation Rate (ESR), while the screening test for HIV antibody was negative, CD4 count was 753cells/ μ L (normal range 410 – 1590), CD8 count was 683cells/ μ L (normal range 190-1140). Figure 2.

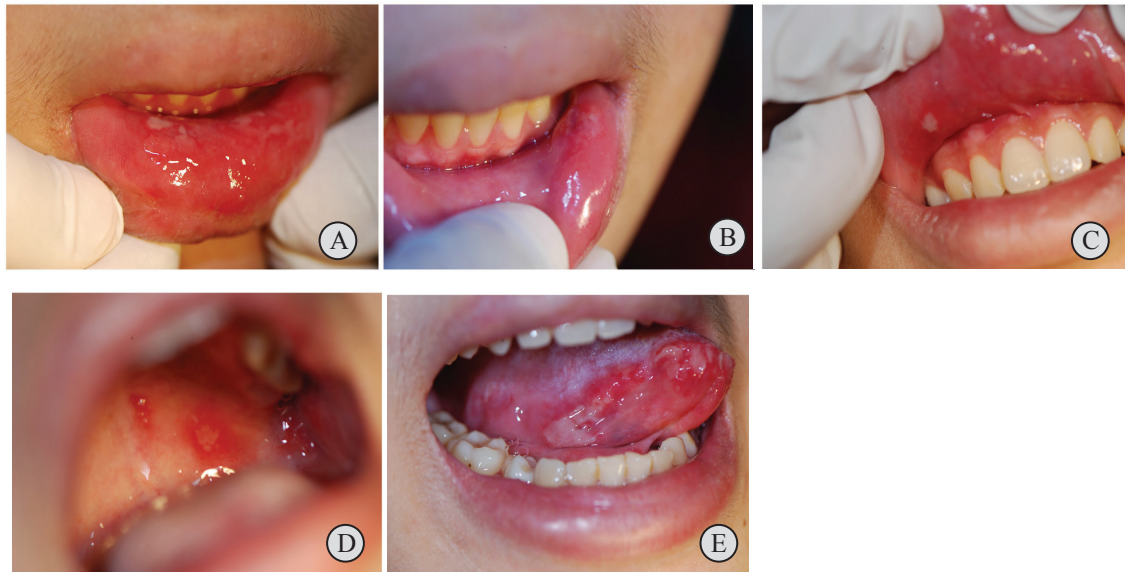


Figure 1. Painful multiple irregular ulcers surrounded by erythematous area on various areas of oral mucosa. (A-E)

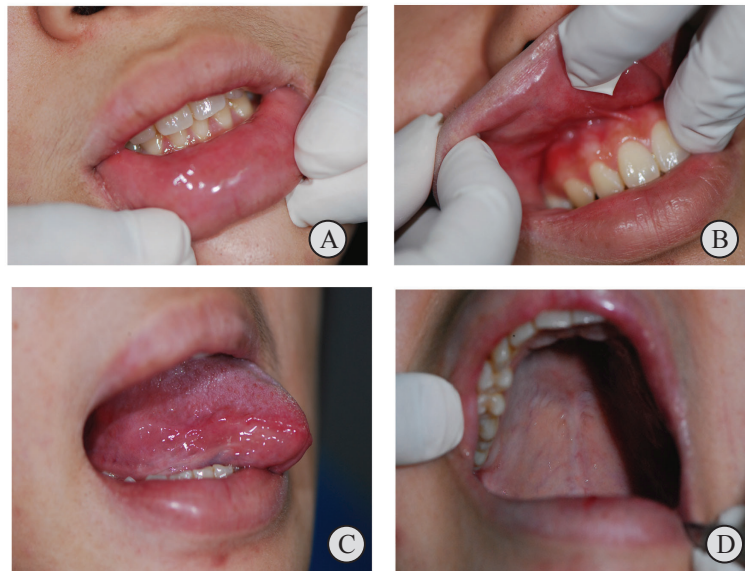

Figure 2. Ulcerated oral mucosa healed after treatment with two weeks of 500mg Valacyclovir (A-D).

DISCUSSION

Recurrence of HSV infection is a reactivation of HSV lead to asymptomatic viral shedding; recrudescence is a viral reactivation with clinical manifestations. Recurrence is triggered by internal and external trigger and leading to proliferative state.^{1,3} In our patient, we suggest that physiological stress, fatigue and menstruation as triggering factors of recrudescence of HSV infection. Infection in the mouth is less common than herpes labialis and unusual in otherwise healthy persons.⁴

The seropositive of IgM and IgG antibodies to HSV-I and HSV-II in our patient can be a marker of HSV-II

induced recurrent orofacial disease although it is rare.¹ Although presence of IgG doesn't indicate reinfection, recurrent infection or immunity. Immunoglobulin M can be demonstrated for weeks after primary infection.⁹ Reactivation are less frequent after the age of 35 and contrary more frequent before the age of 35 as it happens in our patient. Recurrent episodes are milder and shorter in duration with minimal systemic involvement. Oedem on upper lips in our patient known as RHL which typically affects the outer vermilion border and adjacent cutaneous region. Recurrent Intraoral Herpes typically located on tongue and keratinized mucosa of the hard palate and attached gingiva.¹

Realtime amplification techniques (PCR) is a high specificity and sensitivity test which can detect small piece of DNA of the virus and low levels of HSV shedding. Because of the rapid development of the vesicle stage (<12 h) and the fast decrease in detectable virus after 48 h may be the reasons why the result is negative although viral shedding still continues for 3 to 8 days after the lesions have resolved.^{1,3,9} Many antiviral drugs have been used to overcome and inhibit the viral DNA synthesis. It can be achieved by a variety of process: direct inhibition of the viral DNA polymerase by competition with the natural nucleoside triphosphate (dGTP in the case of the triphosphate of Acyclovir, ganciclovir and penciclovir), chain termination of the growing viral DNA (acyclovir) or DNA strand breakage after incorporation of the unnatural nucleotide in the viral DNA.¹⁻⁴

Acyclovir {9-[(2-hydroxyethoxy)methyl]guanine} is a nucleoside analogue of guanosine and by phosphorylation transformed its active state by viral thymidine kinase (TK). The affinity of Acyclovir for herpesvirus encoded TK is approximately 200 times greater than for human TK, thus phosphorylation of Acyclovir by the human enzyme occurs at a negligible rate. This selective affinity results in the activation and concentration of Acyclovir in virus-infected cells.⁴ Following phosphorylation to Acyclovir monophosphate (aciclo-GMP), normal host cellular enzymes catalyse the sequential phosphorylation to Acyclovir diphosphate (aciclo-GDP) and Acyclovir triphosphate (aciclo-GTP); this nucleoside triphosphate is a potent inhibitor of viral DNA synthesis as it competes with viral nucleotides for incorporation into viral DNA. Once incorporated, it terminates DNA chain synthesis (and thus inhibits viral replication), giving rise to nonfunctional DNA strands.⁴

The antiviral activity of Acyclovir may be effective in reducing the duration of symptoms of recurrent HSV-1 infection, although the optimal timing and dose of the treatment are uncertain. Intravenous Acyclovir will still the first line for the management of severe cases which require hospitalization such as neonatal herpes, HSV encephalitis or disseminated HSV infections in immunocompromised hosts^{3,4}

The prophylactic oral Acyclovir with adjustment to the many situations can reduce the frequency and severity of recurrent attack of herpetic infection in immunocompromised patients, although the dose, optimal timing and duration of treatment is uncertain and can vary in different situations.⁴ Titer of IgM, IgG of anti HSV-I and HSV-II from the 1st and 2nd result showed decreased titer count because of the use of Acyclovir prophylactic therapy for 1 month.⁹

Herpes simplex virus type 1 infection in immunocompetent patients usually requires short-term antiviral therapy, thus HSV drug resistance is unlikely to arise

(less than 3%) and the incidence of resistant HSV-I strains remains low (0.5% in immunocompetent patients).^{2,5} We suspected our patient had clinically resistant HSV to Acyclovir because Acyclovir did not reduce the vesicles formation, severity and duration of the symptoms. These may be caused by one or more of the following mechanisms: complete deficiency in viral TK activity, decreased production of viral TK (TK low producer virus), viral TK protein with altered substrate specificity (Tk altered virus; the enzyme is able to phosphorylate thymidine not Acyclovir), or a viral DNA polymerase with altered substrate specificity (DNA pol altered). A TK-deficient phenotype has been observed in 95% of Acyclovir-resistant isolates. However, several reports have demonstrated that at least some TK activity is needed for HSV reactivation from latency in neural ganglia.⁴

Valacyclovir is the L-valine ester prodrug of Acyclovir and has the same mechanism of action, requiring Tk dependent conversion to the monophosphate form. Valacyclovir is absorbed from the gastrointestinal tract and converted to Acyclovir by intestinal and hepatic first pass metabolism. Sixty-three percent of the Valacyclovir oral dose is absorbed and converted to Acyclovir, compared with the 15–21% absorption of orally administered Acyclovir. Acyclovir is detected in plasma 15 min after Valacyclovir administration. Thus, Valacyclovir is increasing the limited oral bioavailability of Acyclovir three to five-fold. Valacyclovir has a safety profile similar to Acyclovir, with mild neurotoxicity and severe nephrotoxicity in animals at single doses of 1 and 2–5g/kg) respectively.⁴

Nowadays, systemic Valacyclovir is effective for the treatment of herpes labialis especially when started during the prodrome of the disease eventhough the optimal dose is still unkwon. It has more convenient dosing regimen (once, twice or three times daily compared with five times daily for Acyclovir) and it is likely that Valacyclovir will finally replace Acyclovir in the oral treatment of HSV or VZV infections in immunocompetent persons.⁷ For these advantages, we choose Valacyclovir for the prophylactic therapy of recurrent HSV infection with supportive treatment such as immune supplement, topical 0.2% chlorhexidine. Chlorhexidine digluconate is effective against gram-positive organisms, gram-negative organisms, aerobes, facultative anaerobes, and yeast.¹¹ We also gave instruction to take good rest, avoid sun exposure and prevent cross infection by avoid kissing anyone, share kitchen or bathroom utensils.³

The adverse events and drug-related adverse events of Acyclovir and Valacyclovir are headache, nausea, diarrhoea, nephrotoxicity and a small number of cases of rash, hallucinations, confusion, dyspepsia, dry mouth and flatulence.⁴ It is important to follow up the patient's condition when long term or prophylactic therapy with the laboratory examination of kidney and liver function.

CONCLUSION

Current therapeutic modalities include preventive measures, non specific immune stimulation, topical applications of antiseptic, antiviral agents. Oral administration of VCV as a the oral prodrug of ACV is effective prophylactic and therapeutic option with many advantages against HSV infection and nowadays is replacing ACV.

ACKNOWLEDGEMENT

We would like to thank drg Anandina Irmagita, SpPM, drg Indriasti Wardhany, SpPM, drg Endah Ayu, SpPM for excellent support.

REFERENCES

1. Fatahzadeh M, Schwartz RA. Human herpes simplex virus infections: Epidemiology, pathogenesis, symptomatology, diagnosis and management. *J Am Acad Dermatol.* 2007;57:737-63.
2. Kleymann G. Agents and strategies in development for improved management of herpes simplex virus infection and disease. *Expert Opin Investig Drugs.* 2005;14:135-61.
3. Westley S, Seymour R, Staines K. Recurrent intra-oral herpes simplex 1 infection. *Dent Update.* 2011;38:368-70.
4. Arduino PG, Porter SR. Oral and perioral herpes simplex virus type I (HSV-I) infection : review of its management. *Oral Dis.* 2006;12:254-70.
5. Greabu M, Battino M, Mohora M, Totan A, Didilescu A, Spinu T, Totan C, Miricescu D, Radulescu R. Saliva--a diagnostic window to the body, both in health and in disease. *J Med Life.* 2009;2:124-32.
6. Tovar S, Parlatescu I, Tovar M, Cionca L. Primary herpetic gingivostomatitis in children and adults. *Quintessence Int.* 2009;40:119-24.
7. Cunningham A, Griffiths, Leone P, Mindel A, Patel R, et al. Current management and recommendations for access to antiviral therapy of herpes labialis. *J Clin Virol.* 2012;53: 6-11.
8. Gold D, Corey L. Acyclovir prophylaxis for herpes simplex virus infection. *Antimicrob Agents Chemother.* 1987;31:361-7.
9. Kaufman H, Azcuy AM, Varnell ED, Sloop GD, Thompson HW, Hill JM. HSV-1 DNA in tears and saliva of normal adults. *IOVS.* 2005; 46:241-7.
10. Wallach J. Interpretation of Diagnostic Test, 7th edition. Philadelphia : Lippincott Williams and Wilkins, 2000 :848-9.
11. Scully C. Oral and maxillofacial medicine the basis of diagnosis and treatment 2nd edition. London : Churchill Livingstone Elsevier, 2010.