

Poster Presentation (PF-35)

Spider Silk (*Nephila* sp.) as Suture Material on Blood Vessel SurgeryS. W. Cheng¹, B. J. Widyananta², B. P. Priosoeryanto³¹Faculty of Veterinary Medicine in Bogor Agricultural University (IPB), INDONESIA; ²Division of Veterinary Surgery, Faculty of Veterinary Medicine in Bogor Agricultural University (IPB), INDONESIA; ³Division of Veterinary Pathology, Faculty of Veterinary Medicine in Bogor Agricultural University (IPB), INDONESIA**Keywords:** jugular vein, pathology, rabbits, spider silk, surgery.**INTRODUCTION**

Surgical suture is a medical device used to hold body tissues together after an injury or surgery. Application generally involves using a needle with an attached length of thread. Surgical sutures are normally classified into two types, absorbable and non-absorbable. They can also be classified based on their construction, either monofilament or multi-filament and also whether they are made from natural or synthetic materials. Sutures can also be classified according to their usage e.g. cardiovascular sutures, ophthalmic sutures, general sutures, orthopaedic sutures etc. Common problems associated with the choice of suture material include increased risk of infection, foreign body reactions, and inappropriate mechanical responses, particularly decreases in mechanical properties over time. Improved suture materials are therefore needed. As a high-performance material with excellent tensile strength, spider silk fibres are an extremely promising candidate for use in surgical sutures. However, the biochemical behaviour of individual silk fibres braided together has not been thoroughly investigated. In the present study, we characterise the inflammatory response produced from silk sutures and absorbance time.

Figure 1. *Nephila* sp.**MATERIALS AND METHODS**

Silk Rearing and Storage: The spider is placed on a table without the use of anaesthesia. Silk was pulled out of the major ampullate gland, which is an adequate stimulus for production.

Dragline fibres were reared manually on a piece of aluminium coil of 15cm in diameter. The bundles of silk were stored up to 1 month before being processed into sutures, several layers of the spider silks were combined together under sterile conditions and fixed to a suture needle.



Figure 2. Several layers of spider silks were fixed to a suture needle

Surgery: There are three New Zealand White rabbits that were used in this research. The jugular veins of the three rabbits were incised then sutured with the spider silks. The rabbits were killed and observed in the 1st week, 3rd week, and 5th week post-surgery respectively.

Histopathology: Jugular vein was harvested and fixed with 10% formalin, embedded in paraffin, and then manually sectioned with a microtome to obtain 4-5 µm-thick paraffin sections (1). Dewaxed sections are then stained with hematoxylin and eosin (H&E) (2). Light microscope photographs were taken using camera and images were analysed using Image J.

RESULT AND DISCUSSION

Pathology Anatomy: Based on the gross anatomy changes from the samples obtained from all the rabbits, there are left over silks on both jugular veins from 1st and 3rd week of post-surgery. Without blood vessel suppression nor constriction of the venous lumen. Thus no congestion was found as blood flow was normal.

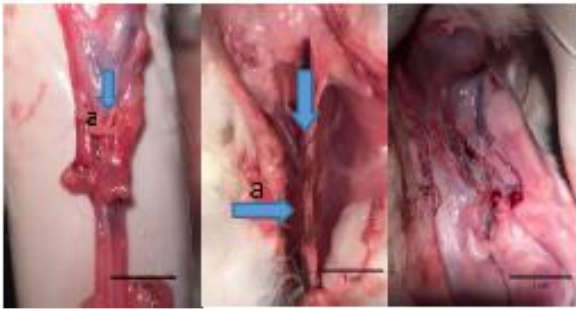


Figure 3. Jugular vein from 1st week, 3rd week, and 5th week post-surgery respectively

Histopathology: Histopathology results from 1st week post-surgery rabbit showed that the venous wall which consisted of tunica intima, tunica media and tunica adventitia no longer displayed proper shape and structure due to trauma from incision during surgery. The trauma of incision caused inflammatory cells accumulated on the incised area. There are least inflammatory cells happened around left over silk, due to spider silk functioned as anti-inflammation (3).

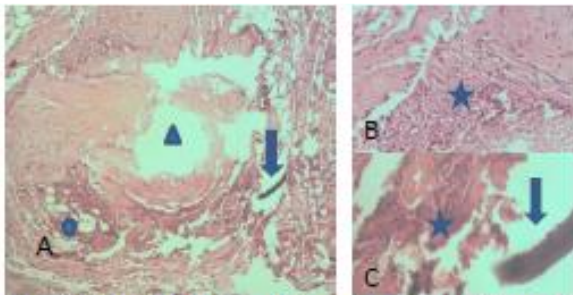


Fig 4: Histopathology of jugular vein on 1st week post-surgery; magnification 100x (A) and 400x (B)(C), H&E staining. Left over spider silk (↓), Lumen of jugular vein (▲), inflammatory cells (★), fatty cell (●).

Results from 3rd week post-surgery rabbit showed that blood clotting occurred without existence of fibrin. In this case, spider silk rich in vitamin K (4), hence it can become blood clotting factor in this research. The jugular vein on 3rd week post-surgery left little inflammatory cells as the results of spider silk is functioning well on jugular vein after 3 weeks of post-surgery.

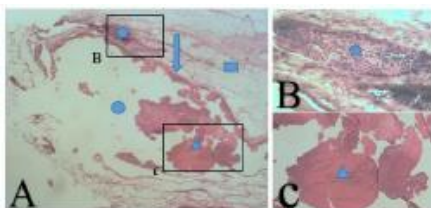


Fig 5: Histopathology of jugular vein on 3rd week post-surgery; magnification 40x (A) and 100x (B)(C). Endothelial cell from tunica intima (↓), inflammatory cell (★), lumen from jugular vein (▲), erythrocyte (●), tunica media (■).

whereas 5th week post-surgery rabbit showed that the wound healing process was good and appeared as if it has not been sutured before.

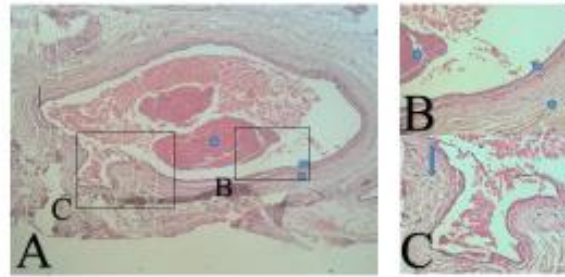


Fig 6: Histopathology of jugular vein on 3rd week post-surgery; magnification 40x (A) and 100x (B)(C). Fibroblast (↓), erythrocyte (★), Tunica intima (▲), tunica media (●).

It can be concluded that the spider silks were biocompatible which functions as antimicrobial, biodegradable between 3 to 5 weeks of post-surgery and caused minimal inflammatory reactions. It support the healing of incision from surgery. Therefore, the spider silk can be concluded as a suitable suture material for vascular surgery.

REFERENCES

- [1] Samuelson DA. 2007. Textbook of Veterinary Histology, Missouri (US): Saunders, St. Louis. pp. 147-151.
- [2] Cooksey C. 2010. Hematoxylin and related compounds: An annotated bibliography concerning their origin, properties, chemistry and certain applications. *Biotechnic & Histochemistry*. 85(1): 65-82.
- [3] MacIntosh, Ana C., Keans VR, Crawford A, Hatton PV. 2008. Skeletal Tissue Engineering Using Silk Biomaterials. *Journal of Tissue Engineering and Regenerative Medicine*. 2(3): 71-80.
- [4] Jackson, Robert R. 1974. Effects of d-amphetamine sulfate and diazepam on thread connection fine structure in a spider's web. *J. Arachnol*. 2:37-41.