

Oral Presentation (SA-14)

Fracture of the Infraglenoid Tubersity in CanineRama Arge Frismana^{1*}, Albiruni Haryo², Hendrik Saputra²¹FKH Universitas Nusa Tenggara Barat, ²Praktik Dokter Hewan Bersama Satwa Sehat*Corresponding author's email: dvmfrismana@gmail.com**Keywords:** Fracture, Intraglenoid, Scapula, Canine.**INTRODUCTION**

A broken bone or which was usually called bone fracture had been a medical condition in which there was an incomplete or complete break in the continuity of the bone. There are many different kinds of fracture. The Glenoid Fracture of Os scapula is a very rare occurrence that these fractures have only been described in some series of cases often as a part of scapular fracture series, therefore it was difficult to interpret (1).

In most incidents of ligaments or tendon injuries, fracture or luxation was involved (2). Tuber glenoid fracture often occurs in juvenile animals, it's because they are very lively and often caused following faulty landing to a jump (3).

CASE REPORT**Signalements**

A male 6 years old mix breed dog of 15 kg in weight with golden yellow color visited "Satwa Sehat" Animal Clinic in Malang city. This animal had a limp and lameness on his left foreleg; it was lifted when he was walking around.

Anamneses

The owners reported that their pet dog was limping due to get hit by a car accidently. After being hit by car, this dog was immediately carried to the Vet. His body condition was normal and didn't change too much. It's just that the dog seemed to have limp and abnormal walk.

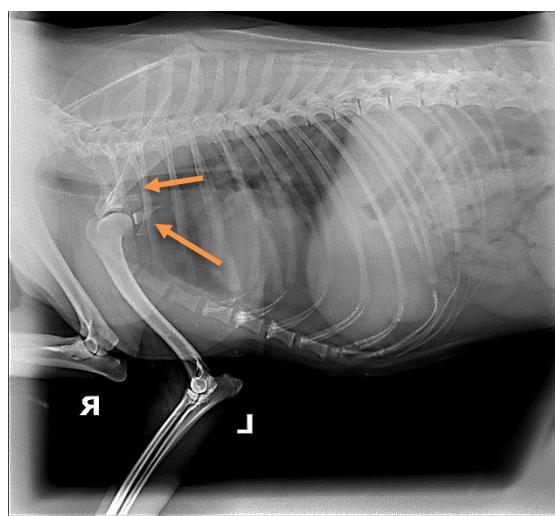
Clinical symptoms

After this dog was brought to the Vet, this animal got checked immediately; foreleg palpation and a gait test was done to see which leg was going wrong. We also got the result that this dog had swollen. When the leg was palpated, abnormalities were obtained; the result was that the dog responded painfully on the shoulder and abnormalities in his extremities.

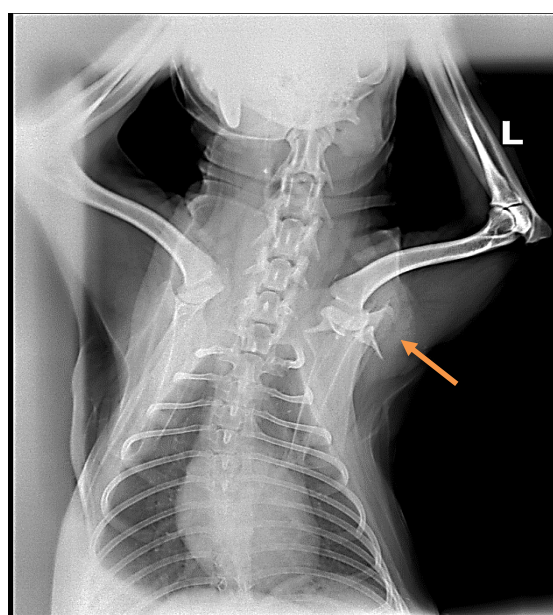
Lab test result

Lab test was carried out by x-ray irradiation to see whether there was an abnormality in the limb system or not. Then, a blood test was conducted to find out about other disorders. X ray irradiation was carried out in a

sideways position as usually called lateral position (picture 1a) and dorsal position (VD) (picture 1b). The x-ray result showed that there was broken leg on the bone of os scapula in fossa glenoid distal side until columnar caudal os scapula.



Picture 1a. X-ray lateral sideways, yellow arrow shows the bone fracture.



Picture 1b. X ray dorsal sideways (VD), yellow arrow shows the bone fracture.

Table 1. Blood test result.

| Examination | result | Unit | normal |
|----------------------------|--------|---------------------|----------------|
| Hematology | | | |
| white blood cell (wbc) | 30.1 | 10 ³ /μl | 6.0 - 17.0 |
| red blood cell (rbc) | 8.57 | 10 ⁶ /μl | 5.5 - 8.5 |
| hemoglobin (hb) | 12.1 | g/dL | 12.0 - 18.0 |
| hematokrit (hct) | 57 | % | 37.0 - 55.0 |
| MCV | 66.5 | fL | 60.0 - 77.0 |
| MHC | 14.1 | pg | 19.5 - 24.5 |
| MCHC | 21.2 | g/dL | 32.0 - 36.0 |
| thrombocytes | 165 | 10 ³ /μl | 200 - 500 |
| Lymphocytes | 5.9 | % | 12.0 - 30.0 |
| Monocytes | 5.2 | % | 3.0 - 10.0 |
| Granulocytes | 88.9 | % | 60.0 - 80.0 |
| Lymphocytes | 1.6 | 10 ³ /μl | 1.0 - 4.8 |
| Monocytes | 1.4 | 10 ³ /μl | 0.15 - 1.35 |
| Granulocytes | 27.1 | 10 ³ /μl | 3.5 - 14.0 |
| RDW-CV | 14.9 | % | 12.0 - 16.0 |
| RDW- SD | 42.1 | fL | 35 - 56 |
| PCT | 0.124 | % | 0.0 - 2.9 |
| MPW | 7.5 | fL | 6.7 - 11.0 |
| PDW | 7.6 | % | 0.0 - 5.0 |
| P-LCR | 11.7 | % | 13.0 - 43.0 |
| blood biochemistry | | | |
| ALT/SGPT | 40 | U/L | 8.2 - 57.3 |
| Ureum (BUN) | 12 | mg/dL | 10.0 - 20.0 |
| Creatinine | 1.2 | mg/dL | 1.0 - 2.0 |
| Total Protein | 7.6 | g/dL | 5.4 - 7.5 |
| Albumin | 2.5 | g/dL | 2.6 - 4.0 |
| Globulin | 5.1 | g/dL | 2.7 - 4.4 |
| Ratio A/G | 0.49 | | 0.6 - 1.1 |
| Total bilirubin | 0.3 | mg/dL | 0.07 - 0.61 |
| Alkaline Phosphatase (ALP) | 89 | U/L | 10.6 - 100.7 |
| Glukosa | 100 | mg/dL | 60.0 - 100 |
| Amilase | 894 | U/L | 269.5 - 1462.4 |
| Elektrolit | | | |
| Natrium/sodium | 143 | mmol/L | 140 - 153 |
| Kalium/potasium | 5.3 | mmol/L | 3.8 - 5.6 |
| Calcium | 10.6 | mg/dL | 8.7 - 11.8 |
| Phosphor | 5.5 | mg/dL | 2.6 - 6.8 |

Blood test result from table 1 was additional data as a confirmation of diagnosis. Abnormalities of blood test can be seen in table 1. In the table 1 shows that there was no fracture due to internal factor, such as microbial infection which can cause bone structure become abnormal. Hematology test or blood test also aimed to prepare animals prior to anesthesia, whether the animal was ready for anesthesia before bone surgery or not.

Differential Diagnosis

Extremities disorder often occurs in juvenile dogs, the disorder that occurs can be fractures, joint dislocations, lack of calcium, and lameness. When reviewing the x-ray result, it was found that the occurrence of an extremity disorder was due to a foreleg fracture. The foreleg fracture can occur in various bones, such as the bones of the humerus, radius-ulna, scapula, carpal and metacarpal.

Prognose

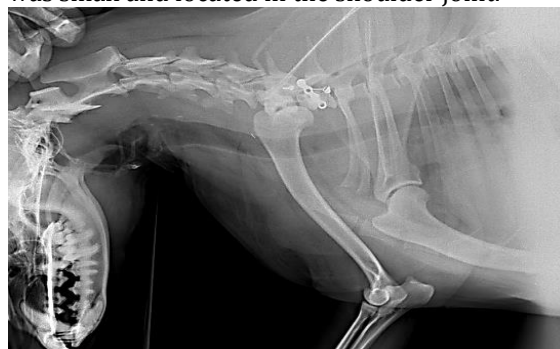The healing process in the case of a fracture takes various times depending on the severity and location of the fractures. The lameness is caused by pain due to instability of the

infraglenoid tuberosity that caused micro-movements at the level of the fracture line. Moreover, the pull due to the biceps branchii tendon during flexion of the shoulder has created continue micro-fractures that could have affected the healing process [5]. When a joint is involved in the fracture, it indicates the need of surgery, and the prognosis will be classified as guarded [8].

Therapy

In the case of an extremity fracture, surgery should be performed immediately because if surgery was not performed immediately it would form a callus which can cause the imperfect healing process. In preparation for a general anesthetic, the dog must not eat for at least 10 to 12 hours beforehand so their stomach is empty. This should be done to prevent vomiting under anesthesia and the risk of inhaling food down into the lung. Once the dog was stable, a premedication injection was given. Injection premedication was using xylazine 2mg/kg IM (@interchemie, Netherland). This premedication provides pain relief, minimizes the amount of inducing agent required and for smoother maintenance. General anesthesia was induced with 5.5mg/kg ketamine (@kepro, Holland). After inducing general anesthesia, the Vet gave catheter for liquid therapy with the aim that the dog would not be shocked during the surgery. We made an incision on the shoulder, then looking for the broken part of the bone of os scapula. After an incision, then it was rinsed with NaCl solution to be able to see the broken part of the bone, this could make it easier during the bone surgery process.

Bone grafting was conducted using combination of locking plate and wire. The plate was attached to the columnar os scapula and tuberglenoid, then to reinforce and make it flexible we added wire mounting across the plate (picture 2). After breaking a bone grafting done, the muscle was stitched by using polyglactin suture as well as in the subcutaneous section. Then for the skin was stitched by using silk suture. This surgery took approximately four and half an hour. This bone grafting was very difficult because the broken bone was small and located in the shoulder joint.



Picture 2. Post-operative after tuberglenoid fixation

After bone surgery was done completely, then the dog was given phenylbutazone 20mg/kg IV. It aimed to reduce the swelling that occurs before and after surgery. One week after the surgery, the dog was already able to move his leg on the floor. During the second week, the dog was able to walk well, but still not perfect.

DISCUSSION

Tuber glenoid is the side of origin of the *Biceps brachii* muscle and develops as a separate center ossification, usually fusing on the scapula by 5 months of age. Although a fracture is infrequent [4], it generally occurs as a result of a direct force exerted on the shoulder region; on the contrary, the avulsion fracture of glenoid tuberosity appears to be due to an indirect force [6]. In this case, the fracture occurs as a result of an external factor, the dog got hit by a car causing broken bone of the glenoid tuberosity to columnar of os scapula. On the other hand, the pull due to the biceps brachii tendon during flexion of the shoulder has created continue micro-fracture that could have affected the healing process[5]. Such injury or trauma like that can be detected using radiography. In this case, the radiography result shows a fracture in tuberosity glenoid to columnar os scapula.

Regardless of the treatment method, isolated glenoid fracture generally has a good clinical outcome with good function and less risk of early degeneration[9]. In this case, using two stages of grafting; first by using a screwed bone plate, and the second using a wire. Bone plates are one of the strongest and most effective methods of fixing a fracture. They counteract bending, compression, twisting and pulling force. They are strong not bulky and relatively lightweight. Bone plate is also perfect for animal that are extremely active. The wire for fixation in patients with poor bone quality was made flexible, because the fracture was in the joint area.

CONCLUSION

The fracture tuberosity glenoid is a rare case of fractures. In most cases, the foreleg fracture can occur in various bones, such as the bones of the humerus, radius-ulna, scapula, carpal and metacarpal. In this case, the fracture occurs on tuberosity infraglenoid to columnar os scapula. During the connecting or grafting the bones, we should be more careful because the fracture lies in the joints. The thing that needs to be considered in connecting the bone is the power of grafting and elasticity.

There are a huge variety of different types of fractures, and these all have different treatments and carry different outlooks. Although having a fracture can be very traumatic for both pet and the owner, the good news is that with the correct treatment most fractures in dogs and cats will heal

well and most animals can regain normal use of their limbs.

ACKNOWLEDGMENTS

The authors acknowledge the support from "Satwa Sehat" Animal Clinic, Faculty of Veterinary Medicine, Nusa Tenggara Barat University.

REFERENCES

- [1] Kavanagh B, F. Bradway J, K. Cofield R, H. 1993. Open reduction and internal fixation of displaced intra-articular fractures of the glenoid fossa. *J Bone Joint Surg Am.* 75: 479-484.
- [2] Innes JF, Brown G. Rupture of the biceps brachii tendon sheath in two dogs. *J Small AnimPract* 2004; 45: 25-8.
- [3] Leijnen M, Steenvoorde P, Da Costa A, et al. 2009. Isolated apophyseal avulsion of the coracoid process: case report and review of literature. *Acta OrthopBelg*; 75: 262-4.
- [4] chris P, susan P. 1999. tschauner's guide to small animal clinics. Sudzpubllizing. America
- [5] Deneuche AJ, Viguier E. 2002. Reduction and stabilisation of a supraglenoid tuberosity avulsion under arthroscopic guidance in a dog. *J Small AnimPract*; 43: 308-11.
- [6] Binnington AG. 1974. Fractures of the scapular tuberosity. *Can Vet J*; 15: 152-5.
- [7] Denny HR, Butterworth SJ. 2000. A guide to canine and feline orthopedic surgery. 4th ed. Oxford: Blackwell Science: 303-40.
- [8] Johnston SA. 1993. Articular fractures of the scapula in the dog: a clinical retrospective study of 26 cases. *J Am Anim Hosp Assoc*; 29: 157-64
- [9] Goss Tp. 1992. Fracture of glenoid cavity. *J bont joint surg Am*;74 : 299-305.