

Oral Presentation (PAT-1)

Case report: Metastatic ganglioneuroma in a Sumatran TigerE Handharyani^{1*}, DR Agungpriyono¹, RW Wiranti¹, GK Suryaman¹, S Edwar³, E Rumiya³, A Winarto²¹Division of Pathology; ²Division of Anatomy Histology and Embriology, Faculty of Veterinary Medicine, Bogor Agricultural University, ³Ragunan Zoo, Jakarta, Indonesia*Corresponding author's email: ekowatieko@apps.ipb.ac.id**Keywords:** ganglioneuroma, malignant, metastatic, Sumatran tiger, tumor.**INTRODUCTION**

Neuroblastic tumors, which are uncommon tumors of nerve cell origin, are classified into neuroblastoma, ganglioneuroblastoma, and ganglioneuroma depending on the degree of maturation of neoplastic neuroblasts and development of schwannian stroma [2,4,7]. Ganglioneuroma is a rare neuroectodermal tumor of the peripheral nervous system. Ganglioneuromas generally are considered to be benign neoplasms composed of both mature ganglion cells and nerve fascicles with axons, Schwann cells, fibroblasts, and other connective tissue elements [1]. The aim of this study is to clarify the pathomorphological feature of a subcutaneous ganglioneuroma which occurred in a Sumatran tiger.

CASE REPORT

A 11-year-old male Sumatran tiger (*Panthera tigris sondaica*) has two month history of nodular mass which located at subcutaneous area of the left caudo-ventral abdominal. The veterinarian applied antibiotic, anti-inflammatory and supplement to improve the health condition. And after long discussion, surgical work was performed to pull-off the mass, and a routine procedure for histopathological examination was done. About one year later, the condition of the tiger became weakness and extremely emaciated, revealed severe pale mucosa with failure of respiration. After one month treatment, unfortunately the tiger was dead. Necropsy procedure was performed to evaluate the pathological changes. A complete necropsy was performed, and the gross findings found that the lung had more than hundred multiple white nodular masses, up to 5.0 cm in diameter, firm in consistency, white in color, and disseminated throughout the lung's lobes. The samples from most important organs, including lung, spleen, liver, spleen, and brain, were collected, fixed in 10% neutral buffered formalin, processed routinely, and embedded in paraffin. Three-five micrometer thick sections were cut and subjected to hematoxylin eosin (HE) and Masson Trichrome staining. Additional formalin-fixed paraffin

embedded sections were stained by streptavidin biotin complex (SAB) immunoperoxidase method. The primary antibodies employed were the following: mouse anti-*vimentin* (Dako Cytomation, Denmark), mouse anti-*desmin* (Dako Cytomation, Denmark), mouse anti-*proliferating cell nuclear acid/PCNA* (Dako Cytomation, Denmark), rabbit anti-*S-100 protein* (Dako Cytomation, Denmark), rabbit anti-*glial fibrillary acidic protein/GFAP* (DAKO, Carpinteria) and rabbit anti-*protein gene product/PGP 9.5*. (Cell Marque, USA).

RESULTS

The surgical work was performed to remove the subcutaneous mass, and observed that the mass was oval-shaped, 9.5 x 7.0 x 5.0 cm in size, has conspicuous margin, firm, greyish-white in color with scanty hemorrhagic streaks. The other two small masses (about 0.5 cm in diameter), closed to the origin mass as metastatic areas were also removed. Cross section of the present mass demonstrated a multinodular pattern, greyish-white in color with focal extensive of necrotic area.

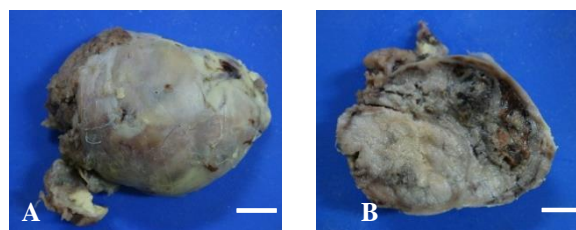


Figure 1. Gross appearance of subcutaneous oval-shaped mass, firm in consistency, and greyish-white in color (A). Cross section (B) revealed multi-nodular pattern with focal extensive necrotic area (arrow); (formalin-fixed, Bar = 20 mm)

Histopathologically, a densely cellular, encapsulated, well demarcated, multifocally necrotic, was observed in the subcutaneous mass of. The tumor was consisted of three types of neoplastic cells: small undifferentiated cells, large polygonal cells and spindle cells. These cells were separated with various degree of collagen fibers using Masson Trichrome stain. In several areas of the mass revealed hemorrhages and necrotic zones.

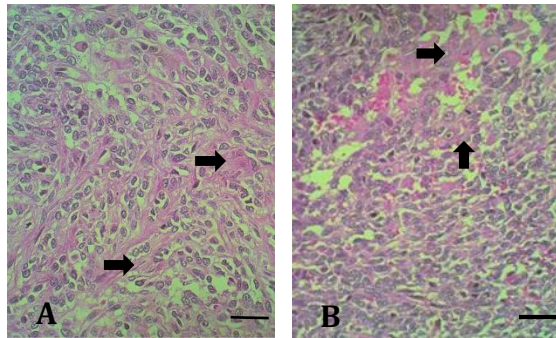


Figure 2. Histopathological features of subcutaneous mass. The mass is composed of undifferentiated small cells, separated with various degree of collagen fibers (A, arrow). Large polygonal eosinophilic cells with vesicular nuclei are observed in other areas (B, arrows). HE staining, Bar = 60 μ m

The predominant cell population in the present tumor is small undifferentiated cells. Individual cells had a single, round, centrally located nucleus with little apparent chromatin and a scant amount of eosinophilic cytoplasm. The large polygonal cells were scattered and formed small aggregates in the tumor. Individual polygonal cells had large, single, oval to vesicular, eccentric nucleus with nucleoli and abundant eosinophilic cytoplasm. The last cellular population was composed of spindle cells. The mass also contained small numbers of scattered large polygonal cells with abundant pale eosinophilic cytoplasm and large oval hypochromatic, often eccentric nuclei; these cells were suggestive of immature neuronal cell bodies (Fig. 2B).

Moderate anisocytosis and anisokaryosis were observed. Mitoses were rarely observed in the large polygonal cells, spindle and small cell populations. Immunohistochemical staining indicated that the tumor cells were positive for vimentin, S-100 protein, and PGP 9.5 protein. All neoplastic cells lacked specific labeling for desmin and GFAP. The large polygonal cells were negative for PCNA, but the small undifferentiated and spindle cells were positive immunoreactivities. The tumor cells of the origin and metastatic lesions showed positive staining for PGP9.5.

Table 1. Results of immunohistochemistry

Antibodies	Small cells	Large cells	Spindle cells
Vimentin	+	+	+
Desmin	-	-	-
GFAP	-	-	-
S-100 protein	++	++	++
PGP9.5	+	+	+
PCNA	+	-	+

DISCUSSION

The subcutaneous and multinodular masses of the lung have same characteristic in histomorphological patterns and immunohistochemistry. In addition, there were also showed that tumor cells frequently found in blood vessels. These findings indicated that the present subcutaneous tumor which occurred in Sumatran tiger was a malignant tumor with metastatic potential. There are similarities of immunohisto-chemical characteristic of present neoplastic cells and previous studies of ganglioneuroma [3,6]. The immunehistochemical results were indicative of neuronal differentiation of the neoplastic cells. The spindle and large polygonal/pleomorphic [6] cells corresponded to Schwann cells and ganglion cells, respectively. The morphological, and immunohisto-chemical characteristics of the present tumor were indicative of ganglioneuroma. These characteristics were different with ganglioneuroma that evaluated previously in a dog which has positive immune-reactivity for GFAP [7]. Ganglioneuroma is regarded as a benign tumor in human beings and animals, including one previous report in a cat [3]. Pulmonary metastases observed in this case suggested that a diagnosis of malignant ganglioneuroma might be possible.

CONCLUSION

In conclusion, the morphological and immuno-histochemical characteristics of the neoplastic cells in Sumatran tiger were consistent with ganglioneuroma, with metastatic potential to the pulmonary parenchyma. The present case is a very rare malignant neoplasm which occurred in a wild animal.

REFERENCES

- [1] Hawkins KL, Summer BA. 1987. Mediastinal ganglio-neuroma in a puppy. *Vet Pathol* 24:283-285.
- [2] Koestner A, Higgins RJ. 2002. Tumors of the nervous system. pp. 697-738. In: *Tumors in Domestic Animals*, 4th ed. (Meuten DJ. ed.), Iowa State Press, Ames, Iowa.
- [3] Kobayashi R *et al.* 2012. A malignant and metastasizing feline cardiac ganglioneuroma. *J Vet Diagn Invest* 24(2) 412-417.
- [4] Koestner A *et al.* 1999. *Histological Classification of Tumors of the Nervous System of Domestic Animals*, Armed Forces Institute of Pathology, Washington, D. C.
- [5] Koestner A, Higgins RJ. 2002. Tumors of the nervous system. pp. 697-738. In: *Tumors in Domestic Animals*, 4th ed. (Meuten DJ. ed.), Iowa State Press, Ames, Iowa.
- [6] Murphy BG, Shivaprasad HL. 2008. Ganglioneuroma of the brachial plexus in two

cockatiels (*Nymphicus hollandicus*). *Vet Pathol* 45:690-692.

- [7] Sakai H *et al.* 2011. Ganglioneuroma in the Urinary Bladder of a Dog. *J Vet Med Sci* 73(6): 801-803.