

THE EFFECT OF THE DURATION OF INHALED NICOTINE EXPOSURE TO THE NUMBER OF LEYDIG, SPERMATOGONIUM, AND SERTOLI CELLS ON THE SPRAGUE-DAWLEY STRAIN WHITE RATS

¹Fadil Pramudhya, ¹Doddy M. Soebadi, ¹Wahjoe Djatisoesanto.

¹Department of Urology, Faculty of Medicine/Universitas Airlangga, Soetomo General Hospital, Surabaya.

ABSTRACT

Objective: To analyze the differences of the number of Leydig, spermatogonium, and Sertoli cells in mice, after being given nicotine inhalation, and the effect of recovery when nicotine stopped. **Material & Methods:** This is experimental studies with a post-test only control group design. The sample used was 36 adult male mice (10-12 weeks) (*Rattus Norvegicus*) Sprague-Dawley strain, which were divided into three groups. P1 group was given nicotine inhalation at a dose of 4 mg/kg/day for 15 days, P2 group was given nicotine inhalation at a dose of 4 mg/kg/day for 15 days and was free of treatment for 15 days. The control group (NC) has no treatment at all. Histological examination and calculation of Sertoli cells, Leydig cell, and spermatogonium were processed within 1 hour after testicular sample collection. Then carried out to statistical analysis. 100x and 400x magnification is used to obtain the histopathological. **Results:** Post-hoc LSD test for each variable (Leydig cells, Sertoli cells, and spermatogonium), showed that the NC group had a significantly higher number compared to group P1. P2 group has a significantly higher number compared to group P1. There is no significant difference between the NC group and the P2 group. There was a structural difference in the sample testicles which exposed to nicotine. **Conclusion:** Nicotine exposure with a dose of 4 mg/kg/day for 15 days has a significant effect on decreasing the number of Leydig cells, spermatogonium cells, and Sertoli cells in rats and giving a free-treatment period for 15 days, giving the testis time to do recovery and regeneration (the reversible damage of testicular structure).

Keywords: Nicotine, Leydig cells, Sertoli cells, spermatogonium, reversible damage.

ABSTRAK

Tujuan: Menganalisis perbedaan jumlah sel Sertoli, sel spermatogonium, dan sel Leydig pada hewan coba, setelah diberi nikotin secara inhalasi, serta efek pemulihan yang terjadi saat pemberian nikotin dihentikan. **Bahan & Cara:** Penelitian ini merupakan studi eksperimental laboratorium dengan post-test only control group design. Hewan uji pada penelitian ini adalah tikus jantan (*Rattus Norvegicus*) strain Sprague-Dawley dewasa (10–12 minggu), sejumlah 36 ekor terbagi dalam 3 kelompok. Kelompok P1 diberikan nikotin secara inhalasi dengan dosis 4 mg/kg/hari selama 15 hari, kelompok P2 diberikan nikotin secara inhalasi dengan dosis 4 mg/kg/hari selama 15 hari dan bebas perlakuan selama 15 hari. Kelompok kontrol (NC) tidak terdapat perlakuan sama sekali pada kelompok ini. Dalam kurun waktu 1 jam setelah sampel testis kiri diambil, akan diproses untuk pemeriksaan histologi dan penghitungan jumlah sel sertoli, sel leydig, dan spermatogonium. Data kemudian dilakukan uji statistik menggunakan SPSS 20. Gambaran histopatologis testis diambil dengan pembesaran 100x dan 400x. **Hasil:** Uji post-hoc LSD pada masing-masing variabel (sel leydig, sel sertoli, dan spermatogonium), menunjukkan kelompok NC memiliki rerata jumlah yang lebih tinggi secara signifikan dibandingkan dengan kelompok P1. Kelompok P2 memiliki rerata jumlah yang lebih tinggi secara signifikan dibandingkan dengan kelompok P1. Tidak terdapat perbedaan yang signifikan antara kelompok NC dengan kelompok P2. Terdapat perbedaan struktur pada testis sampel yang terpapar nikotin. **Simpulan:** Paparan nikotin dengan dosis 4 mg/kg/hari selama 15 hari berpengaruh signifikan terhadap penurunan jumlah sel Leydig, sel spermatogonium, dan sel Sertoli pada tikus. Pemberian jeda selama 15 hari, memberikan waktu kepada testis untuk melakukan pemulihan dan regenerasi (efek kerusakan terhadap struktur testis yang reversible).

Kata Kunci: Nikotin, sel Leydig, sel Sertoli, spermatogonium, kerusakan reversibel.

Correspondence: Wahjoe Djatisoesanto; c/o: Department of Urology, Faculty of Medicine/Universitas Airlangga, Soetomo General Hospital, Surabaya. Jl. Mayjen. Prof. Dr. Moestopo 6-8 Surabaya 60286. Phone: +62315501318; Fax: +62315024971. Mobile phone: +628123577947. Email: djatisoe@gmail.com.

INTRODUCTION

Infertility is the inability of couples who are sexually active without using contraception, to get a pregnancy within one year. About 15% of couples in their first year do not get pregnant and seek expert help for infertility problems. One in eight couples encountered issues when trying to get pregnant in the first child and one in six couples when attempting a second child's pregnancy. Infertility affects both men and women.^{1,3} Factors that play a role in the occurrence of infertility include infection, drugs, radiation, hormones, and exposure to chemical compounds, which can interact with the endocrine system, one of the chemical compounds that are considered toxic and can cause infertility is nicotine. Today, nicotine abuse by cigarette smoking is a big problem for public health. 85% of households in Indonesia are exposed to cigarette smoke; the estimation is eight smokers die because of active smokers; one passive smoker dies from exposure to secondhand smoke. Based on the calculation of this ratio, at least 25.000 deaths in Indonesia occur due to cigarette smoke from the other people.⁴

Cigarette smoke contains up to hundreds of chemicals, including nicotine, carbon monoxide, and several identifiable carcinogens and mutagens. The components possessed by cigarettes consist of benzopyrene, nicotine, cadmium, and lead; these components release toxins that have been studied could affect infertility in men.⁵ These effects can occur in the form of changes in nicotine to cotinine, which affects the decrease in testosterone levels, which decreases sperm quality and affects histopathological studies of the reproductive organs.^{6,7} In another study that examined nicotine administration in male rats, there was a significant reduction in Leydig cells, spermatogonium cells, Sertoli cells, and but improved after being given a 15-day lag for recovery and regeneration.^{8,9}

Previous studies have found an association between exposure to 4 mg of nicotine inhalation to the number of Leydig cells, spermatogonium cells, and Sertoli cells in white rats of the Sprague-Dawley strain.¹⁰ Based on this condition, this study wanted to prove the effect of prolonged exposure to 4 mg of inhalation nicotine on the number of Leydig cells, spermatogonium cells, and Sertoli cells as well as the impact of their recovery when nicotine exposure was stopped.

OBJECTIVE

To analyze the differences in the number of spermatogonium, Leydig cells and Sertoli cells in

young age Sprague-Dawley rats after given inhaled nicotine, and the effect of recovery that occurs when the nicotine exposure is stopped.

MATERIAL & METHODS

This type of study is an experimental study using white rats (*Rattus Norvegicus*) strains of young male Sprague-Dawley as animal testing. The treatment is in the form of inhaled nicotine to see the effect on the number of spermatogonium, Leydig cells, testicular Sertoli cells, and the expected recovery effect when the administration of nicotine inhalation is stopped. The research design used was an experimental laboratory study with post-test only control group design, with measurements of the number of spermatogonium, Leydig cells, Sertoli cells, and spermatogenesis carried out after the experimental animals were treated, experimental grouping by repetition of 12 experimental animals in each group and there is a control group as a comparison (negative control).

The sample used in this study was the young Sprague-Dawley white strain, which has the following criteria: age 8-12 weeks, weight 250-300 grams, healthy without defects, obtained from the Animal Laboratory, Faculty of Veterinary Medicine, Universitas Airlangga, Surabaya.¹¹ The sample in this study is the Sprague-Dawley white rat that has fulfilled the criteria mentioned above, grouped randomly into 3 groups using random numbers to increase internal validity because the research is a causality study. The white rat samples that were recently obtained from the Animal Laboratory, Faculty of Veterinary Medicine, Universitas Airlangga, Surabaya, were first adapted in a cage/research environment (in the laboratory section of the Animal Laboratory, Faculty of Veterinary Medicine, Universitas Airlangga, Surabaya) for 2 weeks with a 12-hour bright cycle, and 12-hour dark period.

There were two treatment groups, group P1 where in this group was given inhaled nicotine at a dose of 4 mg/kg/day for 15 days, then the left testis was taken, the second treatment group P2 wherein this group was given inhaled nicotine at a dose of 4 mg/kg/day for 15 days and free treatment for 15 days, then the left testicle was taken. Left orchidectomy is done in rats by positioned supine in ketamine 75 mg/kgBW intraperitoneal, scrotum skin is incised until the left testis and funiculus is apparent, the funiculus is inside the skin at 2 adjacent and cut places including, proximal pieces tied with 3-0 silk thread (Ethicon Inc., Johnson & Johnson Co., Somerville), the clamps were removed and the testis

samples were taken and immediately fixed using ph-buffer formaldehyde 7.4, the incision on the scrotal skin was sewn back with one layer using 3-0 plain catgut thread (Ethicon Inc., Johnson & Johnson Co., Somerville). Within 1 hour after the testicular sample is taken, it will be processed for histology by making paraffin blocks, where the sample will be cut to a thickness of 4 microns. To see spermatogonium, Leydig cells, Sertoli cells, and spermatogenesis, Hematoxylin-Eosin (HE) staining was used in the testicular preparations. After all the research process ends, the experimental animal will be left alive. All actions are carried out using aseptic methods.

From the results of calculating the number of Sertoli cells, Leydig cells, and the number of spermatogonium (numerical variables), a normality test will be carried out (to know the data distribution is normal or not) and variance test (to find out whether the data variants are the same or not) If the data distribution is normal and homogeneous, parametric hypothesis testing (one way ANOVA) is

used. If the data distribution is not normally distributed and homogeneous, then an alternative non-parametric test (Kruskal-Wallis) is chosen.^{12,13}

The hypothesis is determined based on the obtained significance value. This study was significant if the value of $p < 0.05$. All technical data processing is analyzed using statistical software product and service solution 20 for Windows (SPSS 20).^{12,13}

RESULTS

The samples of the study were adult (10-12 weeks) male Sprague-Dawley rats with 12 rats in each group. The primary characteristics can be seen in table 1. The table shows that there was no significant difference in body weight, final body weight, and testicular weight in the entire study sample.

In this study, the data normality test on the number of spermatogonium cells uses the Shapiro-

Table 1. The basic characteristic of the sample.

Variable	Group (Mean ± SD)			p value
	NC	P1	P2	
Final Weight (gr)	254.92 ± 16.161	245.83 ± 28.99	245.33 ± 29.181	0.670
Testicular Weight (gr)	1.312 ± 0.182	1.279 ± 0.206	1.229 ± 0.223	0.610

* $p < 0.05$, significantly different by statistic.

Table 2. Comparison of the spermatogonium cell numbers in each group.

Group	n	Mean ± SD	Normality	p value	Homogeneity
NC	12	40.983 ± 12.219	0.055	0.002*	0.157
P1	12	27.492 ± 7.814	0.639		
P2	12	36.200 ± 4.318	0.458		

* $p < 0.905$, significantly different by statistic.

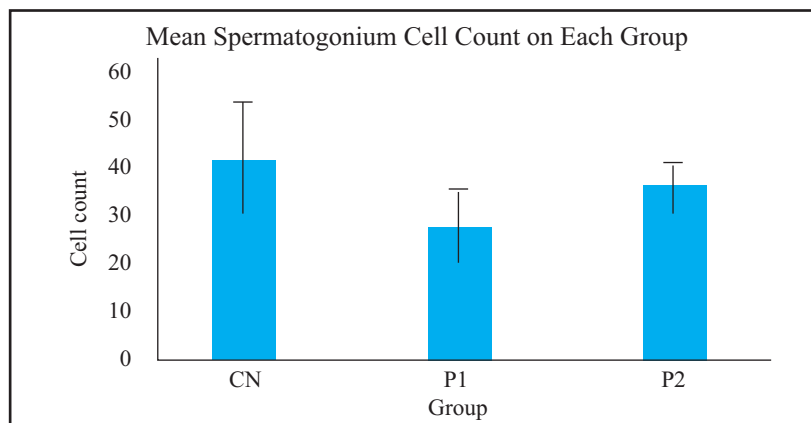


Figure 1. The mean of spermatogonium cells counts in each group.

Wilk test. The results showed that the data on the number of spermatogonium cells in each group was normally distributed with a value of $p > 0.05$. The analysis was continued by using the One-Way ANOVA test and showed a significant difference in the number of spermatogonium cells ($p = 0.002$). Homogeneity tests were also conducted to determine the selection of the post-hoc test method. In this study, the variant of the spermatogonium cell data was homogeneous ($p = 0.157$). Therefore, the analysis continued with the post-hoc LSD test.

The post-hoc LSD test showed a difference in the mean spermatogonium cell count between the negative control group (NC) and the group receiving inhaled nicotine exposure for 15 days (P1) (40.983 vs. 27.492). The NC group had a significantly higher number of spermatogonium cells compared to group P1 ($p = 0.001$). There was also a difference between

groups who only received inhaled nicotine exposure for 15 days (P1) with a group that received exposure to inhaled nicotine for 15 days and was given a delay of 15 days lag before an orchidectomy (P2) (27.449 vs. 36.200). P2 group had a significantly higher number of spermatogonium cells compared to group P1 ($p = 0.020$). There was no significant difference between the NC group and P2 group (40.983 vs. 36.200; $p = 0.189$).

The data normality on the number of Leydig cells was tested by the Shapiro-Wilk test; the results showed that each group was normally distributed ($p > 0.05$). The analysis was continued by the One-Way ANOVA test and showed a significant difference in the number of Leydig cells ($p = 0.002$). In this study, the data variant of the spermatogonium cell was homogeneous ($p = 0.913$). Therefore the analysis was continued with the post-hoc LSD test.

Table 3. Post-hoc LSD analysis for the comparison of the Spermatogonium cells number.

Comparison between Groups	Mean difference	CI95%		p value
		Lower Bound	Upper Bound	
NC vs P1	13.492	6.235	20.748	0.001*
NC vs P2	4.783	-2.473	12.040	0.189
P1 vs P2	-8.708	-15.965	-1.452	0.020*

* $p < 0.05$, significantly different by statistic

Table 4. Comparison of the Leydig cells number in each group.

Group	n	Mean ± SD	Normality	p value	Homogeneity
NC	12	47.629 ± 6.212	0.308	0.002*	0.913
P1	12	37.942 ± 6.945	0.375		
P2	12	46.092 ± 6.871	0.374		

* $p < 0.05$, significantly different by statistic.

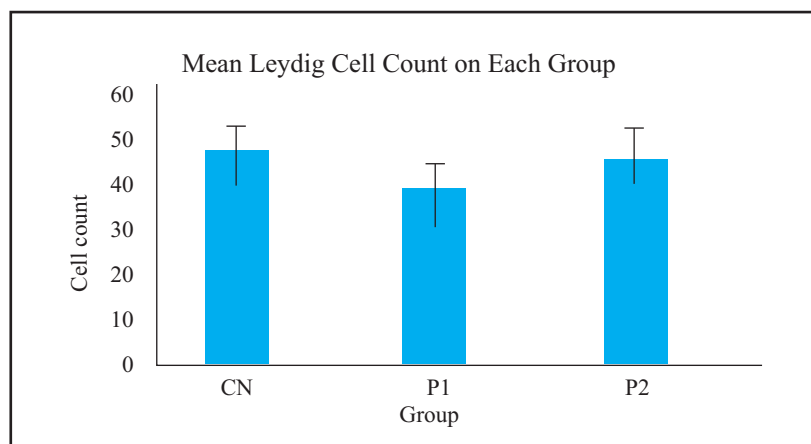


Figure 2. The mean of Leydig cells count in each group.

The post-hoc LSD test showed that the NC group had a significantly higher number of Leydig cells compared to group P1 (47.629 vs. 37.942; $p=0.001$) and group P2 also had a significantly higher number of Leydig cells compared to group P1 (46.092 vs. 37.942; $p=0.005$). There was no significant difference between the NC group and P2 group (47.629 vs. 46.092; $p=0.577$)

The data normality on the number of Sertoli cells was tested using the Shapiro-Wilk test; the results showed that each group was normally distributed ($p>0.05$). The analysis was continued by the One-Way ANOVA test and showed a significant difference in the number of Sertoli cells ($p=0.002$). The homogeneity test was also conducted to determine the selection of the post-hoc test method

Table 5. Post-hoc LSD analysis for the comparison of the Leydig cells number.

Comparison between Groups	Mean difference	CI95%		p value
		Lower Limit	Upper Limit	
NC vs P1	9.688	4.136	15.239	0.001*
NC vs P2	1.538	-4.014	7.089	0.577
P1 vs P2	-8.150	-13.702	-2.598	0.005*

* $p<0.05$, significantly different by statistic.

Table 6. Comparison of the Sertoli cells number in each group.

Group	n	Mean \pm SD	Normality	p value	Homogeneity
NC	12	27.442 \pm 6.493	0.800	0.002*	0.282
P1	12	19.533 \pm 4.112	0.172		
P2	12	25.217 \pm 4.670	0.141		

* $p<0.05$, significantly different by statistic.

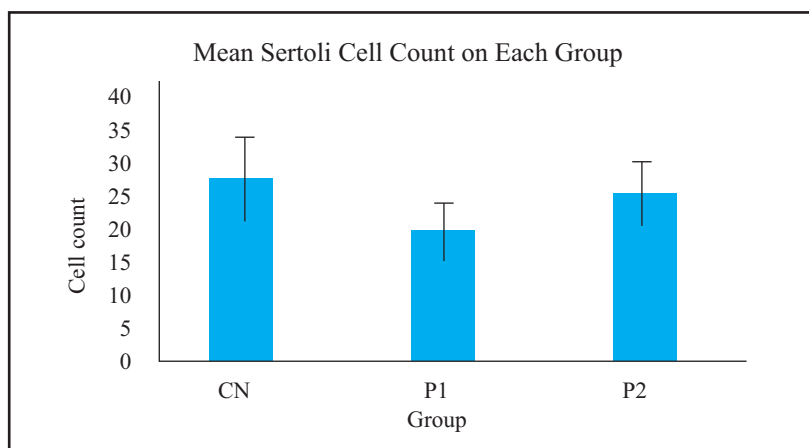


Figure 3. The mean of Sertoli cells count in each group.

Table 7. Post-hoc LSD analysis for the comparison of the Sertoli cells number.

Comparison between Groups	Mean difference	CI95%		p value
		Lower Limit	Upper Limit	
NC vs P1	7.908	3.596	12.221	0.001*
NC vs P2	2.225	-2.088	6.538	0.301
P1 vs P2	-5.683	-9.996	-1.371	0.011*

* $p<0.05$, significantly different by statistic.

and obtained a variant of homogeneous spermatogonium cell data ($p=0.282$). Therefore, the analysis continued with the post-hoc LSD test.

The post-hoc LSD test showed that the NC group and P2 group had significantly higher Sertoli cell counts compared with P1 group (27.442 vs. 19.533; $p=0.001$; 25.217 vs. 19.533; $p=0.011$). There

was no significant difference between the NC group and P2 group (26.367 vs. 24.778; $p=0.555$).

The following is the testicular histopathological picture in each group. All images are taken with 100x (left) and 400x (right) magnification using the Nikon Eclipse Ci microscope with a 16.25 Megapixel DS-Ri camera along with Image Raster 3 software.

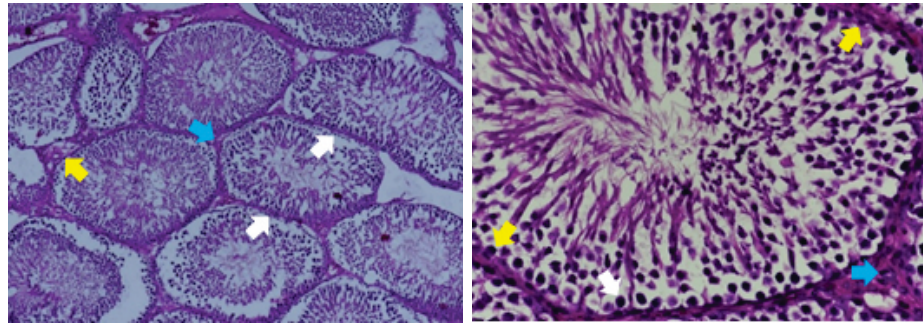


Figure 4. Microscopic description of the cross-section of the seminiferous tubules in the CN group. (White arrows: spermatogonium cells, blue arrows: Leydig cells, yellow arrows: Sertoli cells).

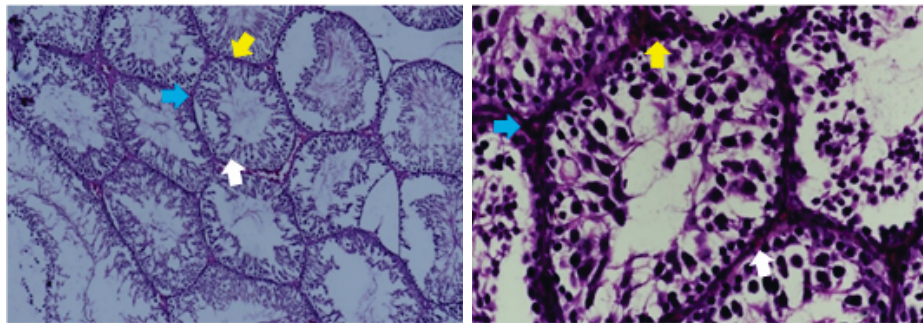


Figure 5. Microscopic description of the cross-section of the seminiferous tubules in group P1. (White arrows: spermatogonium cells, blue arrows: Leydig cells, yellow arrows: Sertoli cells).

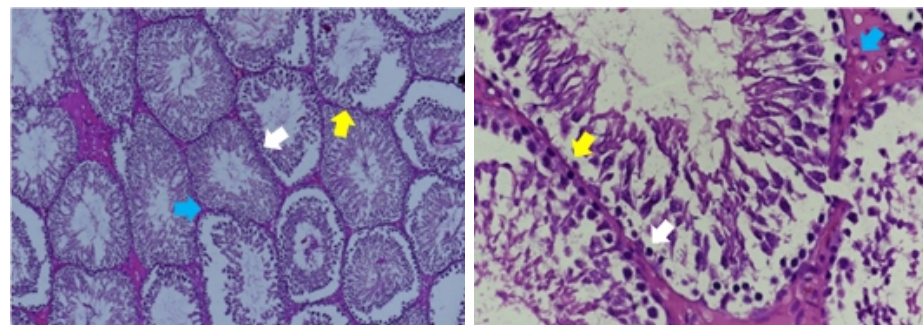


Figure 6. Microscopic description of the cross-section of the seminiferous tubules in P2 group. (White arrows: spermatogonium cells, blue arrows: Leydig cells, yellow arrows: Sertoli cells).

DISCUSSION

Nicotine is metabolized in the liver. The involvement of the kidney and lungs in the metabolism was also noticed.¹⁴ In the male reproductive system, nicotine will be oxidized into its metabolite form cotinine, which has a longer half-life than nicotine itself. Nicotine and cotinine affect spermatogenesis, epididymal sperm count, motility, and potential fertilization of sperm.^{15,16} Nicotine also affects histopathological changes in the testes. There are structural differences in testicles exposed to nicotine, thickening of tunica propia, degeneration of Sertoli cell tight junction, germinal and spermatid cells with irregular shape and no nucleus, and cytoplasm which contain roughly degenerate mitochondria.¹⁷

Harmful effects of nicotine exposure are based on the mechanism of oxidative stress that occurs due to an imbalance between ROS and antioxidant inside the body.¹⁸ This causes lipid peroxidation, DNA damage, and apoptosis of male reproductive cells, including the testicles. In this study, the negative control group (CN) had the highest number of Leydig cells, spermatogonium cells, and Sertoli cells compared to treatment group 1 (P1) and treatment group 2 (P2). These results suggest that exposure to inhaled nicotine can cause decreased Leydig cells, spermatogonium cells, and Sertoli cells in mice. The results of this study are consistent with the research of Rizaldi et al. who previously examined nicotine doses of Leydig cells, spermatogonium cells, and Sertoli cells. This study showed that nicotine exposure could cause decreased Leydig cells, spermatogonium cells, and Sertoli cells in rats.¹⁰

In this study, descriptively, there were differences in the mean number of spermatogonium cells. The highest number of spermatogonium cells was found in the negative control group, then the P2 group and the lowest was in the P1 group (41.156 vs. 37.511 vs. 27.311). However, after analysis, there were only significant differences in the CN vs. P1 group ($p=0.007$) and P1 vs. P2 ($p=0.041$).

The same results were found in the number of Leydig cells and Sertoli cells. The highest mean number of Leydig cells and Sertoli cells was found in the negative control group, then in the P2 group and the lowest was found in the P1 group (Leydig, 48.544 vs. 46.967 vs. 38.822; Sertoli, 26.336 vs. 24.778 vs. 18.556). However, after a post-hoc

analysis, there were only significant differences in the number of Leydig cells and Sertoli cells that were significant in the CN vs. P1 group (Leydig, $p=0.011$; Sertoli, $p=0.030$) and P1 vs. P2 (Leydig, $p=0.007$; Sertoli, $p=0.028$). These results illustrate that administration of nicotine inhalation can cause a decreased Leydig cells, spermatogonium cells, and Sertoli cells, but in the group given a 15-day lag without nicotine exposure before orchidectomy, Leydig cells, spermatogonium cells, and Sertoli cells increased compared with groups not given time lags and the numbers differ significantly. The same results were also found in the study of Nesseim et al. and Kanwal et al. Nesseim et al., found that a significant decreased of spermatogonium cells, and Sertoli cells in the nicotine group were compared to the control group.⁹ Kanwal et al. Found that there was a significant reduction in Leydig cells in the nicotine group compared with the control group.¹⁹ Nicotine activates caspase-3 via the bax-dependent pathway, which induces apoptosis in Leydig cells.²⁰

Nicotine causes severe histological damage at the level of rat spermatogenesis. According to Mosadegh et al.'s study, nicotine increases the expression of p53 and caspase-3 and causes a significant decrease in bcl-2 at the level of mRNA and protein.²¹ Bcl-2 is a protein that plays an important role in the cell apoptosis pathway because it has an anti-apoptotic mechanism. If there is a decrease in the expression of bcl-2, cell apoptosis will be easier to occur because there is nothing that inhibits the apoptotic pathway. On the other hand, p53 can also directly interfere with bcl-2 activity. The overexpression of p53 caused by exposure to nicotine acts as an antagonist of bcl-2 anti-apoptotic activity.²² Caspase is an important mediator of apoptosis. Among other caspases, caspase-3 is the most activated cell death protease known as the caspase executioner. Increased caspase-3 expression, which causes more chromosome DNA degradation, so that it will ultimately increase cell apoptosis.²³

In this study, we can be concluded that nicotine can trigger the apoptotic pathway by reducing the expression of bcl-2 and increasing the expression of p53 causing caspase-3 overexpression. In the end, the combination of a decrease in bcl-2, an increase in p53 and caspase-3 affected the increase in cell apoptosis. Nicotine also induced cell damage by increasing the levels of ROS that affect the structure of DNA adversely, RNA, proteins, and lipids.^{16,24}

Increased ROS attacks plural polyunsaturated fatty acids (polyunsaturated fatty acids) in the testicular membrane, which results in structural and testicular function damage.²⁵ Based on the result of this study, although nicotine can be damage due to a combination of a decreasing in bcl-3, an increase in p53 and caspase-3, testicular histological damage can also be caused by an increase in testicular RNA damage caused by the pathological production of ROS.

Another important thing was the mean number of Leydig cells, spermatogonium cells, and Sertoli cells in the given a 15-day lag time that was not significantly different from the negative control group. It can be assumed that Providing a 15-day delay without nicotine exposure provides an opportunity for Leydig cells, spermatogonium cells, and Sertoli cells to restore and regenerate, and concludes that 15-day nicotine exposure has acute damage to Leydig cells, spermatogonium cells, and Sertoli cells that are reversible.

The same results were also shown in the study of Nesseim et al. The group that was given a 15-day lag before the examination, found a recovery of testicular histological structure.⁹ Another study that observed the effect of this recovery was Oyeyipo et al., but they only observed the impact of nicotine on testosterone levels of rats. Nicotine also significantly reduced testosterone levels in mice compared to the control group. This is associated with the effects of nicotine, which causes damage to the testicular structure, especially in Leydig cells, which are the testosterone producers. In the Oyeyipo et al. study, it was found that administration of the recovery time lag had a positive effect on testosterone levels compared to groups not given a recovery time lag.^{26,27} So, from the results of this study and the research of Oyeyipo et al., it can be concluded that 15 days of nicotine exposure might illustrate the effect of nicotine damage on the testes, which is still temporary or reversible.

CONCLUSION

Nicotine exposure at a dose of 4 mg/kg/day for 15 days decreases the number of Leydig cells, spermatogonium cells, and Sertoli cells in mice. Decreasing expression of bcl-2, increasing of p53, and Caspase-3 results in excessive production of ROS in Rat Testicle, these conditions cause more apoptosis in rat testicle. Giving a time lag of 15 days before the examination provides the testis with time

to recover and regenerate. Besides, it can be concluded that nicotine exposure for 15 days has the reversible effect of testis structural damage.

REFERENCES

1. WHO. WHO Manual for the Standardized Investigation and Diagnosis of the Infertile Couple. Cambridge: Cambridge University Press; 2000.
2. Dohle GR, Colpi GM, Hargreave TB, Papp GK, Jungwirth A, Weidner W, et al. EAU guidelines on male infertility. *Eur Urol.* 2018; 48(5): 703-11.
3. Purnomo BB. Infertilitas pada Pria. In: *Dasar-Dasar Urologi.* 3rd ed. Jakarta; 2011. p. 305-17.
4. Pusat Data dan Informasi Kementerian Kesehatan Indonesia. *Perilaku Merokok Masyarakat Indonesia;* 2015.
5. Harlev A. Smoking and Male Infertility?: An Evidence-Based Review. *Smok Male Infertil An Evidence-Based Rev.* 2015; 33.
6. Mahanem MN, Nor-Asmaniza AB, Phang HT, Muhammad HR. Effects of Nicotine and Co-Administration of Nicotine and Vitamin E on Testis and Sperm Quality of Adult Rats. 2006; 35(2): 47-52.
7. Ahmadnia H, Ghanbari M, Moradi MR, Khaje-Dalouee M. Effect of cigarette smoke on spermatogenesis in rats. *Urol J.* 2007; 4(3): 159-63.
8. Oyeyipo IP, Maartens PJ, du Plessis SS. In vitro effects of nicotine on human spermatozoa. *Andrologia.* 2014; 46(8): 887-92.
9. Nesseim WH, Haroun HS, Mostafa E, Youakim MF, Mostafa T. Effect of nicotine on spermatogenesis in adult albino rats. *Andrologia.* 2011; 43(6): 398-404.
10. Rizaldi A, Soebadi DM, Soetojo. Pengaruh Paparan Kronis Nikotin secara Inhalasi terhadap Jumlah Sel Spermatogonium, Sel Sertoli dan Sel Leydig Tikus Putih Strain Wistar Usia Muda (Penelitian Laboratoris Eksperimental). *Univ Airlangga.* 2018.
11. Balai Pengujian Hewan. *Teknis Pemeliharaan Hewan Percobaan Untuk Pengujian Mutu Obat Hewan.* Jakarta: Departemen Pertanian; 1989. p. 8-11.
12. Dahlan S. *Statistik untuk kedokteran dan kesehatan: Uji hipotesis.* Jakarta: Bina Mitra Press; 2006.
13. Snedecor G. Ten thousand randomly assorted digits. In: *Statistical Methods.* Iowa: The Iowa State University Press; 1974. p. 543.
14. Henkel RR. Leukocytes and oxidative stress: dilemma for sperm function and male fertility. *Asian J Androl.* 2011 Jan; 13(1): 43-52.
15. Aydos K, Güven MC, Can B, Ergün A. Nicotine toxicity to the ultrastructure of the testis in rats. *BJU Int.* 2001; 88(6): 622-6.
16. Jana K, Samanta PK, Kumar De D. Nicotine diminishes testicular gametogenesis, steroidogenesis, and steroidogenic acute regulatory protein expression in adult albino rats: Possible influence on pituitary gonadotropins and alteration of

- testicular antioxidant status. *Toxicol Sci.* 2010; 116(2): 647-59.
17. Agarwal A, Saleh RA, Bedaiwy MA. Role of reactive oxygen species in the pathophysiology of human reproduction. *Fertil Steril.* 2003 Apr; 79(4): 829-43.
 18. Esteves SC. Effect of cigarette smoking on levels of seminal oxidative stress in infertile men: a prospective study. *Int Braz J Urol.* 2002; 28(5): 484-5.
 19. Kanwal S, Ameer MK, Mehboob F. Toxic effect of nicotine on leydig cell count & testosterone levels in adult albino mice & its protection by date palm pit powder. *Pakistan J Med Heal Sci.* 2016; 10(4): 1356-9.
 20. Kim KH, Joo KJ, Park HJ, Kwon CH, Jang MH, Kim CJ. Nicotine induces apoptosis in TM3 mouse Leydig cells. *Fertil Steril.* 2005; 83(4 SUPPL.): 1093-9.
 21. Mosadegh M, Hasanzadeh S, Razi M. Nicotine-induced damages in testicular tissue of rats; evidences for bcl-2, p53 and caspase-3 expression. *Iran J Basic Med Sci.* 2017; 20(2): 199-208.
 22. Asl SS, Farhadi MH, Moosavizadeh K, Saraei ASK, Soleimani M, Jamei SB, et al. Evaluation of Bcl-2 family gene expression in hippocampus of 3, 4-methylenedioxymethamphetamine treated rats. *Cell J.* 2012; 13(4): 275-80.
 23. Susan E. Apoptosis: A Reveiw of Programmed Cell Death. *Toxicol Pathol.* 2007; 35(4): 496-516.
 24. Saleh RA, Agarwal A, Sharma RK, Nelson DR, Thomas AJ. Effect of cigarette smoking on levels of seminal oxidative stress in infertile men: a prospective study. *Fertil Steril.* 2002; 78(3): 491-9.
 25. Budin SB, Kho JH, Lee JH, Ramalingam A, Jubaidi FF, Latif ES, et al. Low-dose Nicotine Exposure Induced the Oxidative Damage of Reproductive Organs and Altered the Sperm Characteristics of Adolescent Male Rats. *Malaysian J Med Sci.* 2017; 24(6): 50-7.
 26. Oyeyipo IP, Raji Y, Emikpe BO, Bolarinwa AF. Effects of nicotine on sperm characteristics and fertility profile in adult male rats: A possible role of cessation. *J Reprod Infertil.* 2011; 12(3): 201-7.
 27. Oyeyipo IP, Raji Y, Bolarinwa AF. Nicotine alters male reproductive hormones in male albino rats: The role of cessation. *J Hum Reprod Sci.* 2013; 6(1): 40-4.