

Mucosal Mast Cells Response in the Jejunum of *Ascaridia galli*-Infected Laying Hens

Darmawi^{a*}, U. Balqis^a, M. Hambal^a, R. Tiuria^b, Frengki^a, & B. P. Priosoeryanto^b

^aFaculty of Veterinary Medicine, Syiah Kuala University

Jln. Tgk. H. Hasan Krueng Kale No. 8 Darussalam, Banda Aceh 23111, Indonesia

^bFaculty of Veterinary Medicine, Bogor Agricultural University

Jln. Agatis, Kampus IPB Dramaga Bogor 16680, Indonesia

(Received 26-06-2013; Reviewed 06-09-2013; Accepted 17-09-2013)

ABSTRACT

Intestinal defense mechanism against helminthes parasitic nematode to be associated with mucosal mast cells reaction. The aim of this research was to examine the effect of infection by *Ascaridia galli* parasite to trigger mucosal defense based on mucosal mast cells response in laying hens. Amount of ten head laying hens 12-wk old were divided into two groups containing five chickens of each. The first group, chickens were left as un-infected controls. The second group, chickens were infected orally with 1,000 embryonated eggs of *A. galli*. Mucosal mast cell responses were assayed by in situ jejunal mast cell counts in stained serial histological sections with Alcian blue (pH 0.3) and Safranin-O (pH 0.1) of the jejunum. Mucosal mast cells response were observed and counted on days 14 post infection. The result showed that *A. galli* infection was able to increase significantly ($P < 0.05$) mast cells response. This research concluded that the *A. galli* infection can trigger the involment of mucosal mast cells response in jejunal defense of laying hens against parasitic diseases caused by *A. galli*.

Key words: Ascaridia galli, laying hen, mucosal mast cell

ABSTRAK

Mekanisme pertahanan intestinal terhadap cacing nematoda parasitik berkaitan dengan reaksi sel mast mukosa. Tujuan riset ini adalah menguji pengaruh infeksi parasit *Ascaridia galli* dalam merangsang pertahanan mukosa berdasarkan respons sel mast mukosa pada ayam petelur. Sebanyak sepuluh ekor ayam petelur yang berumur 12 minggu dibagi menjadi dua kelompok, masing-masing kelompok terdiri atas lima ekor ayam. Kelompok pertama, ayam tidak diinfeksi sebagai kontrol. Kelompok kedua, ayam diinfeksi melalui oral dengan 1.000 telur berembrio *A. galli*. Respons sel mast mukosa diuji *in situ* dengan menghitung sel mast pada jejunum melalui pewarnaan serial histologik dengan Alcian blue (pH 0,3) dan Safranin-O (pH 0,1) dari sediaan preparat jejunum. Respons sel mast mukosa diamati dan dihitung pada hari ke-14 pascainfeksi. Hasil menunjukkan bahwa infeksi *A. galli* dapat meningkatkan respons sel mast mukosa secara signifikan ($P < 0,05$). Riset ini menyimpulkan bahwa infeksi cacing *A. galli* dapat merangsang keterlibatan respons sel mast mukosa pada pertahanan jejunum ayam petelur terhadap penyakit parasitik yang disebabkan oleh *A. galli*.

Kata kunci: Ascaridia galli, ayam petelur, sel mast mukosa

INTRODUCTION

Ascaridia galli is one of the major nematode parasites causing substantial economic losses in domestical chickens farming worldwide. The normal habitat of the parasitic stages of *A. galli* is in the small intestine of

poultry. Sexual reproduction of *A. galli* nematodes leads to release of eggs through feces into the environment. These eggs to become embryonated and resulting larval transmission stages reinfect the host by oral ingestion. Although *A. galli* adult worms survive in the lumen of intestine, Luna-Olivares *et al.* (2012) found that *A. galli* larvae had penetrated in the epithelium and were positioned in the lamina propria. To undertake "histotrophic phase", the *A. galli* larvae were localized within the epithelium or in the lumen of the crypts at 3 d post

*Corresponding author:
E-mail: d_darmawi@yahoo.com

infection. Thus, *A. galli* was capable of developing in the lumen but could also enter the lining intestinal with migration to the tissue.

Characteristic immune responses occur during parasite infection in the small intestine. It has long been known that the mast cells are contributed in defense mechanism against parasite infection, particularly in locations that are in close contact with the external environment such as intestines (Urb & Sheppard, 2012), with these responses peaking at the time of parasite expulsion from the host (McDermott *et al.*, 2003), but the mucosal mast cells precise mechanisms involved have remained obscure. Infection induces mucosal mast cells degranulation in the intestinal that is considered to be a host defense mechanism against the parasite. In support of this hypothesis, various authors described that mast cells involved in mucosal defense mechanism. Li *et al.* (2004) showed that mast cells are important for rapidly controlling murine infection with the protozoan parasite *Giardia lamblia*. Okayama & Kawakami (2006) described that the number of mast cells in inflamed tissue can be regulated by proliferation, migration, and survival (and apoptosis). Anthony *et al.* (2007) explained that many of effector cells are activated in response to most helminth infections including mast cells. Mucosal mast cells contribute to expulsion of a number of gastrointestinal nematode parasites (Afferson *et al.*, 2012).

Mast cells differentiate from multipotent hematopoietic stem cells in the bone marrow that give rise to committed mast cell progenitors in the blood and are recruited to tissues, where they mature. Franco *et al.* (2010) suggested that mast cell development is most closely associated with the megakaryocyte/erythrocyte lineage. The lambs infected with *Haemonchus contortus* had significantly greater numbers of mucosal mast cells in abomasal mucosa of lambs (Shakya *et al.*, 2009). Ortolani *et al.* (2013) investigated the greater number of mucosal mast cells was able to decrease worm burden in the abomasums of sheep infected with *H. contortus*. Onah & Nawa (2004) observed that mastocytosis occurred in jejunal sections of mice challenged with *Strongyloides venezuelensis*.

Currently, little information is available describing the effects of *A. galli* infection on the mucosal defense regarding mast cells response of small jejunal of laying hens. Reference to mucosal mast cells mediate *Trichinella spiralis*, the nematode resides within enterocytes of the jejunum, expulsion from the intestine of mice has been reported (Ierna *et al.*, 2005; Suzuki *et al.*, 2008; Afferson *et al.*, 2012); however, De-yuan *et al.* (2003) reported that the mucosal mast cells in jejunum of chickens infected with *A. galli* were increased with no significantly difference but a remarkable decrease of mast cells in the thymic medulla. Thus, the aim of the current study was to investigate the effects of *A. galli* infection on the mucosal defense based on mucosal mast cells response in jejunal of laying hens. Therefore, we investigated the distribution of mucosal mast cells in laying hens whether these mucosal mast cells are strong associated for mucosal defence in the jejunal against *A. galli* infection.

MATERIALS AND METHODS

Chickens

Ten heads Isa Brown laying hens aged 12 wk were used in this study. All chickens maintained individually in *laying hens battery cages* at Faculty of Veterinary Medicine, Bogor Agricultural University. Feed and water were supplied *ad libitum*. Anthelminticum albendazole (PT. Mensana Aneka Satwa, Indonesia) dose 25 mg in 0.25 mL of each was given to all chickens to ensure that they were free of helminth infection 2 wk before infection carried out.

Ascaridia galli Parasite

A. galli adult worms were procured from the intestine of freshly slaughtered chickens. They were brought to the laboratory from local restaurant. Worms were washed with phosphate buffered saline (PBS). For collecting the egg worms, the selected *A. galli* female adult worms were wounded in half of body length using a needle with sharp tip under stereo microscope. The eggs obtained from uteri female adult worms were incubated in sterile aquadestilata at room temperature for 20-31 d till to develop embryonated eggs. The eggs were counted under stereomicroscope for preparing doses of 1,000 embryonated *A. galli* eggs (Darmawi *et al.*, 2007; Balqis *et al.*, 2009).

Ascaridia galli-Infected Laying Hens

The laying hens divided into two groups contained five chickens of each. First groups, the chickens were introduced with 0.5 mL PBS. Second group, the chickens were orally infected with doses of 1,000 embryonated *A. galli* eggs contained in 0.5 mL PBS and introduced directly into the oesophagus using a needle with blunt oval tip (Darmawi *et al.*, 2007).

Tissue Preparation for Mast Cells Protocol

Intestines were divided into 3 segments, namely duodenum, jejunum, and ileum. Jejunum of laying hens were taken because the normal habitat of the parasitic stages of *A. galli* infection is mainly located in the jejunum as described by Luna-Oliveres *et al.* (2012). Jejunum's segment was dissected, flushed with cold sterile saline solution, opened longitudinally, and placed, mucosa side up, onto small pieces of blotting paper. The segments were then fixed in 10% buffered normal formalin. This process was performed for each laying hen using sterile instruments for each dissection. Fixed samples were dehydrated in the ascending concentrations of ethanol (50%, 60%, 70%, 80%, 96% (1), 96% (2), and 100%). The samples were cleared in xylol and were embedded in paraffin wax as described by Darmawi *et al.* (2012) with certain modifications. Three of each histological sections (3-5 μm of thickness) were stained with Alcian blue (pH 0,3) and Safranin-O (pH 0.1)

(Sigma). After washing, sections were counterstained with eosin and mounted. The number of mast cells per 10 villus crypt units (VCUs) was counted on each section. Mast cell counts were performed under light microscopy using an eyepiece square graticule (eyepiece $\times 10$, objective $\times 40$), and data expressed as mean number of mucosal mast cells (MMC) per VCU as described by previous authors (McDermott *et al.*, 2003; Noviana *et al.*, 2004; Li *et al.*, 2004; Königová *et al.*, 2008) with certain modifications.

Statistical Analysis

The MMC responses in different groups of laying hens were analyzed by the Student t test, where t test was used for comparisons of mast cell numbers. *P* value of <0.05 was taken to indicate a significant difference.

RESULTS AND DISCUSSION

The simplest interpretation of the finding as seen in Figure 1, is that at least some mast cells go through mucosae in close contact with the external environment, jejunum, mediating the expulsion of *A. galli* from the intestine. Staining with Alcian Blue–Safranin O revealed mast cells in all the organs examined. Mast cells were identified as blue granules against a pale brown background. Here, we regarded them as mucosal mast cell. Two major subtypes of mast cells have been identified in dogs: connective tissue type, particularly localized in skin, around blood vessels, and in the peritoneal cavity; and mucosal type, which is associated with mucosal surfaces such as those in the gut or airways (Noviana *et al.*, 2004). Regarding the distribution of mast cells within the various locations similar for and support those of Königová *et al.* (2008), who observed mucosal in the lamina propria mucosae, meanwhile connective tissue mast cells were found in the tela submucosa in the stomach of Mongolian gerbils. In the present study, we recorded degranulated mucosal mast cells in jejunum of laying hens. The present study clearly demonstrate that the embryonated eggs of *A. galli* stimulated the immune mechanism particularly in mucosal defense by mean of

mucosal mast cells response in the jejunal of infected laying hens.

Embryonated eggs of *A. galli* were hatched in the small intestinal of chickens. The previous study demonstrated that the *A. galli* larvae were successfully isolated from intestinal of *Isa brown* laying hens infected with the ascending dose embryonated eggs of *A. galli* (Darmawi *et al.*, 2007). In this study, we agree with and support those of Luna-Olivares *et al.* (2012) who found that the normal habitat of the parasitic stages of *A. galli* is in the profound crypt zone of the mucosa and in the tissue of the jejunum in layer pullets. However, the young larvae grown and survived in the lumen to achieved adult worm. The worm parasitic established in definitive host released antigenic materials in relationship between host-parasite interaction. Previously, investigators reported that the proteins were secreted by females and males adult worm of *Syngamus trachea* throughout amphidial glands, excretory/secretory gland cells, pharyngeal glands (Rica *et al.*, 2005).

The common antigenic substances in many parasites were found in both somatic and excretory/secretory products. This hypothesis supported by many previously reports exist about the role of somatic and or excretory/secretory released by nematode. Our previous investigation showed that excretory/secretory protein released by *A. galli* could be applied for generating the immune response by mean of immunoglobulin yolk (IgY) antibody formation in egg yolks (Darmawi *et al.*, 2008; 2010) and serum (Darmawi *et al.*, 2013) of immunized laying hens. Karimi *et al.* (2008) reported that in excretory/secretory and somatic of *Ornithobilharzia turkistanicum* contained material antigenic substances, similar to the findings of Prasad *et al.* (2008) successfully purified the fraction of excretory/secretory antigen of *H. contortus* in sheep. In the study of Smith *et al.* (2009) analyzed of excretory/secretory products released by *Teladorsagia circumcincta*. In another study using excretory/secretory antigen of *Toxocara vitulorum* infective larvae, Hassan & Aziz (2010) noticed that the antigen was able to detect toxocariasis in buffalo calves. Previously, Rokni & Kia (2005) have been reported the excretory/secretory and somatic antigen of *Strongyloides stercoralis* in human

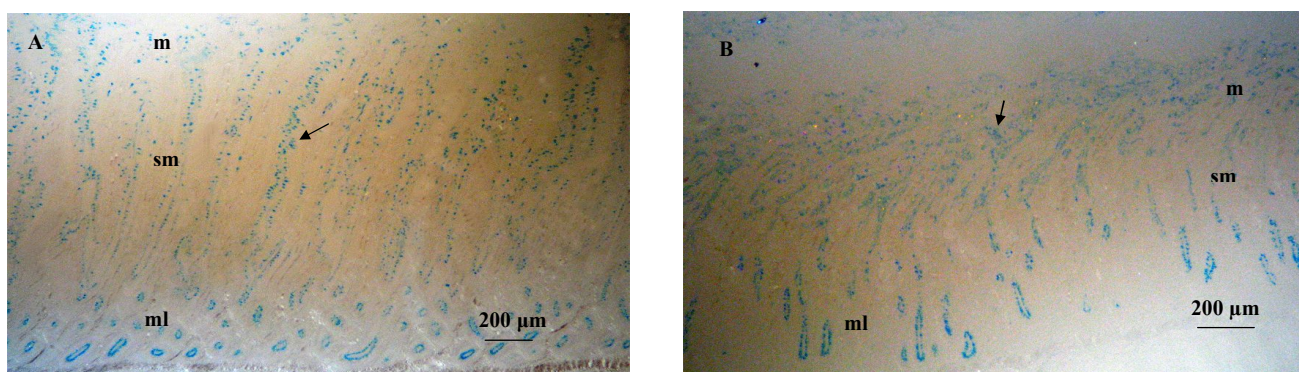


Figure 1. Mast cells were identified as blue granules. The section was stained with Alcian Blue–Safranin O, m: mucosa, sm: submucosa, ml: muscularis, bar = 200 μm . A= Mast cells in jejunal of uninfected chicken (arrow); B= Mast cells in jejunal of infected with dose 1,000 embryonated of *A. galli* (arrow).

intestinal nematode infection. More previously, Choi *et al.* (2003) reported that the excretory/secretory antigen to be a better antigen for a serodiagnosis of clonorchiasis.

There are numerous studies regarding the secretory products of parasites involved in the stimulating of immune response. Excretory/secretory product of *T. circumcincta* were potentially involved in immunity so targets of local immunoglobulin A (IgA) responses in mucus from sheep rendered immune to infection (Smith *et al.*, 2009). **Venom allergen-like (VAL) proteins from gastrointestinal nematode *Heligmosomoides polygyrus*** allow functional testing of the various potentially immunomodulatory (Hewitson *et al.*, 2011). In confirmation of our previous study, we found that IgY antibody formation in egg yolk of laying hens stimulated by excretory/secretory was able to recognized the antigen in the tissue of *A. galli* (Darmawi *et al.*, 2012).

In this study, the jejunal of both normal and infected chicken groups, mast cells were found in three tissue layers. Large numbers of mast cells were observed in the mucosa. Fewer mast cells were apparent in the submucosa and tunica muscularis/serosa, respectively. We recorded that the mast cells degranulated in lamina propria mucosae. The result showed that in laying hens infected with embryonated eggs of *A. galli*, significantly more mucosal mast cells were found in the lamina propria mucosae in comparison with mucosal mast cell numbers in laying hens uninfected with the *A. galli* within the first 14 days p.i. as seen in Table 1. This reflect that the mast cell progenitors are released from the bone marrow into the blood from where they localize to different tissues including in the mucosae throughout the body. Various authors described that multipotent hematopoietic stem cells give rise to committed mast cell progenitors under the influence of growth factors. Once in the tissues, mast cell maturation proceeds, with local factors determining the mature phenotype appropriate for the particular location (Okayama & Kawakami, 2006; Franco *et al.*, 2010).

In normal and infected laying hens, staining with Alcian Blue–Safranin O revealed mast cells in all the organs examined. However, their numbers varied widely and they distributed within the layer of jejunum (Figure 1). In the jejunal tract of both normal and infected laying hens, mast cells were found in lamina propria mucosae tissue layers. Large numbers of mast cells were observed in the jejunum of infected laying hens (Table 1). We described that laying hens infected with embryonated eggs of *A. galli* accumulated mast cells in the jejunum.

Increased numbers of mucosal mast cells are often observed in affected tissues during helminth infections. On the other hand, the number of mucosal mast cells in healthy individuals is stable, but their numbers increase in helminth infection. This phenomenon support that the mast cells play an important role for controlling of *A. galli* infection. Similarly with many previous reports exist about the role of parasite in attracting mast cells in the tissue. Under various experimental conditions, there were shown that mast cell is important in the immune response in mice against *S. venezuelensis* (Onah & Nawa, 2004), *G. lamblia* (Li *et al.*, 2004), *Fasciola hepatica* (Vukman *et al.*, 2013), *Acanthocheilonema viteae* (Ball *et al.*, 2013). The similar phenomenon observed by Deyuan *et al.* (2003) in chickens against *A. galli*, Suzuki *et al.* (2008) in rats against *T. spiralis*, Königová *et al.* (2008) in Mongolian gerbils against *H. contortus*, and the data presented here argue that mast cells are also involved in laying hens against *A. galli* infection.

In the gastrointestinal defense literature, it is well known that mast cells are key effector cells in mediating worms expulsion from the small intestine, and the increase in parasite loss may therefore be explained by the correlation with the enhanced mastocytosis. Importantly, mast cells can regulate both innate and adaptive immune responses of host defense against helminth infection. Galli & Tsai (2010) explained that mast cells can participate in direct killing of organisms by phagocytosis and reactive oxygen species production. Mast cells can modulate host innate immune responses through the release of granular and secreted mediators. However, Urb & Sheppard (2012) described that mast cells contribute to host defense by mean of to serve as immune sentinel cells to both respond directly to pathogens and send signals to other tissues to modulate both innate and adaptive immune responses. Moreover, our results in this study agree with and support those of Galli *et al.* (2008) who showed that mast cells are also able to influence disease directly via the release of pro-inflammatory mediators. Therefore, those data suggest that mast cells might be responsible for the gastrointestinal helminth expulsion. Indeed, Suzuki *et al.* (2008) showed that, in rats as well as in mice infected with *T. spiralis*, the mast cells other than the IgE antibody are an important effector for worm expulsion.

Upon helminthes stimuli cause synchronous development of new population of mast cells, antibodies-producing plasma cells, and plasma cells synthesizing antibodies prosing an anti-worms effect. The immuno-

Table 1. Mucosal mast cell number/10 villus crypt unit (mean \pm SD) in the jejunum from laying hens infected orally with 1,000 embryonated eggs of *A. galli*

Groups	Jejunum layer			
	Mucosa	Submucosa	Muscularis	Total
Uninfected	73.40 \pm 16.59*	160.60 \pm 20.83*	58.60 \pm 9.45	292.60 \pm 35.85*
Infected	140.00 \pm 24.78*	212.40 \pm 16.29*	64.60 \pm 10.19	417.00 \pm 21.83*

Note: *Significantly different from uninfected and infected chickens (P<0.05). Results shown are representative of two independent experiments. MMC/10VCU \pm SD

globulin recognizes, and binds on worm surface antigen by mean of fragment antibody (Fab) and therefore can potentially respond to opsonized organisms. Meanwhile, fragment crystallible (Fc) of immunoglobulin plays a role in stimulating for mast cell migration. Mast cells can be activated by aggregation of surface Fc receptors, including the cell-surface expression of the high-affinity Fc receptor (FcR) for IgE (FcεR1) (Anthony *et al.*, 2007). The presence of chickens IgY antibody homologous to mammalian IgE. The Fc region of IgY mediates most biological effector functions in the chicken, such as complement fixation, opsonization, and anaphylactic reactions, a function that is attributed to IgE in mammals. In many ways IgY combines the functions associated with mammalian IgG and IgE in the chicken (Hau & Hendriksen, 2005; Kazimierczuk *et al.*, 2005; Lee *et al.*, 2009; Chalghoumi *et al.*, 2009; Diraviyam *et al.*, 2011; Darmawi *et al.*, 2012).

Mast cells can be activated by directly interacting with pathogens through pattern recognition receptors. Selective engagement of pattern recognition receptors is also an important mechanism in governing the type of mast cell response. Regarding migration of mast cells in the tissue, Okayama & Kawakami (2006) explained that critical signals for homing and recruitment of mast cells to various tissues are also provided by stem cell factor (SCF). The membrane bound SCF and/or its soluble isoform is chemotactic for mast cells and their progenitors; SCF not only elicits adhesion of mast cells, but also facilitates their proliferation and sustains their survival, differentiation, and maturation. Vukman *et al.* (2013) reported that the *F. hepatica* tegumental coat antigen indirectly induces mast cell migration by dendritic cell-derived chemokines. Urb & Sheppard (2012) described that the binding of an antigen by FcεRI-bound specific IgE leads to FcεRI clustering, which in turn induces downstream signalling events and ultimately the release of mediators. Monomeric IgE binding to FcεR1 enhances mast cell survival mainly by an autocrine production of IL-3 (Okayama & Kawakami, 2006). The release of these mediators is induced by mast cell degranulation, which in turn is induced by mast cell activation triggered by cross-linking of the FcεRI with an antigen-IgE immune complex. Recently, Ball *et al.* (2013) described that the product excretory/secretory-62 secreted by filarial nematodes, *A. viteae*, was an immunomodulator at least in part by inducing the desensitisation of FcεRI-mediated mast cell responses.

Mast cells undergo a degranulation process, release histamine, and proteases, and give rise to globule leucocytes. Various authors explained that histamine and other vasoactive mediators increases vascular permeability and local blood flow, and can act on smooth muscle to increase the expulsion of mucosal parasites (Okayama & Kawakami, 2006; Anthony *et al.*, 2007; Urb & Sheppard, 2012). In addition, Urb & Sheppard (2012) described that mast cell production of chemotactic factors can enhance the recruitment of multiple inflammatory cells including eosinophils (eotaxin), natural killer (NK) cells (interleukin namely IL-8), and neutrophils (IL-8 and tumor necrosing factor namely TNF-α). Mast cell granules

contain an array of mediators such as biogenic amines (typically histamine), proteoglycans, and neutral proteases (Noviana *et al.*, 2004). Weller *et al.* (2005) suggested that leukotriene (LT) B₄ released from activated mature mast cells may also have an important autocrine role in regulating the release of mast cell progenitors from the bone marrow and/or their recruitment into tissues before maturation. Interestingly, because of the various mediators they produce, mast cells are potent immune effector cells involved in cuticle degradation and worm expulsion, important modulatory cells that help link innate and adaptive immunity in the fight against helminthes.

CONCLUSION

The *A. galli* infection can trigger the involment of mucosal mast cells response in mucosal defense of jejunum in laying hens against parasitic diseases caused by *A. galli*.

ACKNOWLEDGMENT

We wish to thank the Ministry of Research and Technology, Republic of Indonesia for funding the work from the Riset Unggulan Terpadu (No. 47/H11.2/PL/RUT-L/I/2007). We also thank Mr. Sulaeman, Mr. Kosasih, and Mr. Kasnadi, Faculty of Veterinary Medicine of Bogor Agricultural University, for their expert technical help in the materials preparation.

REFERENCES

- Afferson, H. C., E. Eleftheriou, M. E. Selkirk, & K. Gounaris. 2012. *Trichinella spiralis* secreted enzymes regulate nucleotide-induced mast cell activation and release of mouse mast cell protease 1. *Infect. Immun.* 80: 3761–3767. <http://dx.doi.org/10.1128/IAI.00411-12> [14-05-2013].
- Anthony, R. M., L. I. Rutitzky, J. F. Urban Jr., M. J. Stadecker, & W. C. Gause. 2007. Protective immune mechanisms in helminth infection. *Nat Rev Immunol.* 7: 975–987.
- Ball, D. H., H. K. Tay, K. S. Bell, M. L. Coates, L. Al-Riyami, J. R. W. Harnett, & M. M. Harnett. 2013. Mast cell subsets and their functional modulation by the *Acanthocheilonema viteae* product ES-62. *J. Parasitol. Res.* 1-13. <http://dx.doi.org/10.1155/2013/96126> [15-05-2013].
- Balqis, U., Darmawi, M. Hambal, & R. Tiuria. 2009. The development of *Ascaridia galli* infective eggs by *in vitro* culture. *JKH.* 3: 183-189.
- Chalghoumi, R., Y. Beckers, D. Portetelle, & A. Théwis. 2009. Hen egg yolk antibodies (IgY), production and use for passive immunization against bacterial enteric infections in chicken: a review. *Biotechnol. Agron. Soc. Environ.* 13: 295-308.
- Choi, M. H., I. C. Park, S. Li, & S. T. Hong. 2003. Excretory-secretory antigen is better than crude antigen for the serodiagnosis of clonorchiasis by ELISA. *The Korean J. Parasitol.* 41: 35-39. <http://dx.doi.org/10.3347/kjp.2003.41.1.35>
- Darmawi, U. Balqis, R. Tiuria, R. D. Soejoedono, & F. H. Pas-
aribu. 2007. L₃ Population in laying hens infected with 6,000 L₂ of *Ascaridia galli*. *JKH* 1: 47-52.
- Darmawi, U. Balqis, R. Tiuria, M. Hambal, & Samadi. 2008. Study of antibody titre in yolk from immunized chickens with excretory/secretory of stage L₃ *Ascaridia galli*. *J. Agric.* 8: 21-26.
- Darmawi, U. Balqis, R. Tiuria, M. Hambal, & Samadi. 2010.

- Purification of yolk immunoglobulin of hens vaccinated against excretory/secretory *Ascaridia galli* L₃ larvae stage. *J. Agric.* 10: 9-15.
- Darmawi, U. Balqis, M. Hambal, R. Tiuria, B. P. Priosoeryanto, & E. Handharyani. 2012. The ability of immunoglobulin yolk recognized the antigen in the tissue of *Ascaridia galli*. *Med. Pet.* 35: 190-195. doi: 10.5398/medpet.2012.35.3.190 [15-05-2013].
- Darmawi, U. Balqis, R. Tiuria, R. D. Soejoedoen, F. H. Pasaribu, M. Hambal, & R. Daud. 2013. Antibody responses of laying hens treated with excretory/secretory and challenged with infective eggs of *Ascaridia galli*. *JKH* 7(2): (*In Press*).
- De-yuan, O. U., G. A. O. Deng-hui, W. A. N. G. Kai-gong, & X. U. Le-ren. 2003. Mast cells in the thymic medulla and jejunal mucosa of chickens infected experimentally with *Ascaridia galli*. *Chinese Journal of Veterinary Science*. Abstract. http://en.cnki.com.cn/Article_en/CJFDTOTAL-ZSYX200301017.htm [15-09-2013].
- Diraviyam, T., T. Jeevitha, P. Saravanan, A. Michael, & S. Meenatchisundaram. 2011. Preparation of chicken (IgY) antibodies consortium for the prevention of enteric infections in poultry. *J. Microbiol. Biotech. Res.* 1(4):95-103.
- Franco, C. B., C. C. Chen, M. Drukker, I. L. Weissman, & S. J. Galli. 2010. Distinguishing mast cell and granulocyte differentiation at the single cell level. *Cell Stem Cell.* 6: 361-368. <http://dx.doi.org/10.1016/j.stem.2010.02.013> [15-05-2013].
- Galli, S. J., M. Grimbaldston, & M. Tsai. 2008. Immunomodulatory mast cells: negative, as well as positive, regulators of immunity. *Nat. Rev. Immunol.* 8: 478-486. <http://dx.doi.org/10.1038/nri2327>
- Galli, S. J., & M. Tsai. 2010. Mast cells in allergy and infection: Versatile effector and regulatory cells in innate and acquired immunity. *Eur. J. Immunol.* 40: 1843-1851. <http://dx.doi.org/10.1002/eji.201040559> [15-05-2013].
- Hassan, S. E. & M. M. A. Aziz. 2010. Detection of antibody to excretory/secretory antigen of *Toxocara vitulorum* infective larvae in buffalo calves by ELISA. *Glob. Vet.* 4: 97-102.
- Hau, J. & C. F. M. Hendriksen. 2005. Refinement of polyclonal antibody production by combining oral immunization of chickens with harvest of antibodies from the egg yolk. *ILAR J.* 46: 294-299. <http://dx.doi.org/10.1093/ilar.46.3.294>.
- Hewitson, J. P., Y. Harcus, J. Murray, M. van Agtmaal, K. J. Filbey, J. R. Grainger, S. Bridgett, M. L. Blaxter, P. D. Ashton, D. A. Ashford, R. S. Curwen, R. A. Wilson, A. A. Dowle, & R. M. Maizels. 2011. Proteomic analysis of secretory products from the model gastrointestinal nematode *Heligmosomoides polygyrus* reveals dominance of Venom Allergen-Like (VAL) proteins. *J. Proteom.* 74: 1573-1594. <http://dx.doi.org/10.1016/j.jprot.2011.06.002>
- Ierna, M. X., H. E. Scales, H. Schwarz, C. Bunce, A. McIlgorm, P. Garside, & C. E. Lawrence. 2005. OX40 interactions in gastrointestinal nematode infection. *Immunology.* 117: 108-116. <http://dx.doi.org/10.1111/j.1365-2567.2005.02271.x>
- Karimi, G. R., M. Abdigoudarzi, M. Valizadeh, & H. Miranzadeh. 2008. Comparison of excretory-secretory and somatic antigens of *Ornithobilharzia turkestanicum* in agar gel diffusion test. *Iranian J Parasitol.* 3: 19-22.
- Kazmierczuk, K., L. Cova, B. Ndeboko, U. Szczyrk, A. Targosz, T. Brzozowski, & A. Sirko. 2005. Genetic immunization of ducks for production of antibodies specific to *Helicobacter pylori* UreB in egg yolks. *Acta Biochim. Polon.* 52: 261-266.
- Königová, A., G. Hrcková, S. Velebný, J. Corba, & M. Várady. 2008. Experimental infection of *Haemonchus contortus* strains resistant and susceptible to benzimidazoles and the effect on mast cells distribution in the stomach of Mongolian gerbils (*Meriones unguiculatus*). *Parasitol. Res.* 102: 587-595. <http://dx.doi.org/10.1007/s00436-007-0792-4> [28-05-2013].
- Lee, S.H., H.S. Lillehoj, D.W. Park, S.I. Jang, A. Morales, D. Garcia, E. Lucio, R. Larios, G. Victoria, D. Marrufo, & E. P. Lillehoj. 2009. Induction of passive immunity in broiler chickens against *Eimeria acervulina* by hyperimmune egg yolk immunoglobulin. *Biotechnol. Agron. Soc. Environ.* 13: 295-308.
- Li, E., P. Zhou, Z. Petrin, & S. M. Singer. 2004. Mast cell-dependent control of *Giardia lamblia* infections in mice. *IAI.* 72: 6642-6649. <http://dx.doi.org/10.1128/IAI.72.11.6642-6649.2004> [22-05-2013].
- Luna-Olivares, L. A., T. Ferdushy, N. C. Kyvsgaard, P. Nejsun, S. M. Thamsborg, A. Roepstorff, & T. M. Iburg. 2012. Localization of *Ascaridia galli* larvae in the jejunum of chickens 3 days post infection. *Vet. Parasitol.* 185: 186-193. <http://dx.doi.org/10.1016/j.vetpar.2011.10.025>
- McDermott, J. R., R. E. Bartram, P. A. Knight, H. R. P. Miller, D. R. Garrod, & R. K. Grencis. 2003. Mast cells disrupt epithelial barrier function during enteric nematode infection. *PNAS.* 100: 7761-7766. <http://dx.doi.org/10.1073/pnas.1231488100> [15-05-2013].
- Noviana, D., K. Mamba, S. Makimura, & Y. Horii. 2004. Distribution, histochemical and enzyme histochemical characterization of mast cells in dogs. *J. Mol. Histol.* 35: 123-132. <http://dx.doi.org/10.1023/B:HIJO.0000023377.70443.08>
- Okayama, Y. & T. Kawakami. 2006. Development, migration, and survival of mast cells. *Immunol. Res.* 34: 97-115. <http://dx.doi.org/10.1385/IR.34.2:97>
- Onah, D.N. & Y. Nawa. 2004. Mucosal mast cell-derived chondroitin sulphate levels in and worm expulsion from FcR γ -knockout mice following oral challenge with *Strongyloides venezuelensis*. *J. Vet. Sci.* 5: 221-226.
- Ortolani, E. L., M. L. Leal, A. H. Minervino, A. R. Aires, R. L. Coop, F. Jackson, & N. F. Suttle. 2013. Effects of parasitism on cellular immune response in sheep experimentally infected with *Haemonchus contortus*. *Vet. Parasitol. Abstract.* <http://dx.doi.org/10.1016/j.vetpar.2013.02.014>. [15-05-2013].
- Prasad, A., A. Nasir, & N. Singh. 2008. Detection of anti-*Haemonchus contortus* antibodies in sheep by dot-ELISA with immunoaffinity purified fraction of ES antigen during prepatency. *Indian J. Exp. Biol.* 46: 94-99.
- Rica, E., R. N. Perry, J. Barrett, & M. R. L. Johnston. 2005. Biochemical analyses on single amphidial glands, excretory-secretory gland cells, pharyngeal glands and their secretions from the avian Nematode *Syngamus trachea*. *Inter. J. for Parasitol.* 25: 1151-1158.
- Rokni, M. B. & E. B. Kia. 2005. Evaluation of enzyme-linked immunosorbent assay, using somatic and excretory-secretory antigens of *Strongyloides stercoralis* for the serodiagnosis of Strongyloidosis. *Iranian J. Publ. Health.* 34: 8-12.
- Shakya, K. P., J. E. Miller, & D. W. Horohov. 2009. A Th2 type of immune response is associated with increased resistance to *Haemonchus contortus* in naturally infected gulf coast native lambs. *Vet. Parasitol.* 163: 57-66. <http://dx.doi.org/10.1016/j.vetpar.2009.03.052> [15-05-2013].
- Smith, S. K., A. J. Nisbet, L. I. Meikle, N. F. Inglis, J. Sales, R. J. Beynon, & J. B. Matthews. 2009. Proteomic analysis of excretory/secretory products released by *Teladorsagia circumcincta* larvae early post-infection. *J. Parasite Immunol.* 31: 10-19. <http://dx.doi.org/10.1111/j.1365-3024.2008.01067.x>
- Suzuki, T., T. Sasaki, H. Takagi, K. Sato, & K. Ueda. 2008. The effectors responsible for gastrointestinal nematode parasites, *Trichinella spiralis*, expulsion in rats. *Parasitol. Res.* 103:1289-1295. <http://dx.doi.org/10.1007/s00436-008-1130-1> [28-05-2013].

- Urb, M. & D. C. Sheppard.** 2012. The role of mast cells in the defence against pathogens. *PLoS Pathogens*. 8: 1–3. <http://dx.doi.org/10.1371/journal.ppat.1002619> www.plospathogens.org [15-05-2013].
- Vukman, K. V., P. N. Adams, D. Dowling, M. Metz, M. Maurer, & S. M. O'Neill.** 2013. The effects of *Fasciola hepatica* tegumental antigens on mast cell function. *Int. J. Parasitol.* 43: 531–539. <http://dx.doi.org/10.1016/j.ijpara.2013.01.011> [15-05-2013].
- Weller, C. L., S. J. Collington, J. K. Brown, H. R. P. Miller, A. Al-Kashi, P. Clark, P. J. Jose, A. Hartnell, & T. J. Williams.** 2005. Leukotriene B₄, an activation product of mast cells, is a chemoattractant for their progenitors. *JEM*. 201: 1961–1971. <http://dx.doi.org/10.1084/jem.20042407>