

Transaminase Enzyme and Liver Histological Profile of Mice Administered Extract of Pegagan (*Centella asiatica* (L.) Urban)

B. Muchtaromah*, Kiptiyah, & T. K. Adi

Department of Biology, Faculty of Science and Technology
University of Islamic State Maulana Malik Ibrahim Malang
Jln. Gajayana 50 Malang, East Java, Indonesia
(Received 01-10-2010; accepted 09-06-2011)

ABSTRAK

Tujuan dari penelitian ini adalah untuk mengkaji apakah pegagan menimbulkan efek toksik pada hati. Penelitian ini menggunakan rancangan acak lengkap dengan empat perlakuan, yaitu 125, 200, 275 mg/kg BB, dan kontrol, masing-masing perlakuan terdiri atas enam ulangan. Variabel yang diamati adalah kadar enzim *glutamate pyruvate transaminase* (GPT), *glutamate oxaloacetic transaminase* (GOT) dan profil histologis hati. Kadar enzim GPT dan GOT dianalisis dengan analisis varian tunggal 0,05. Gambaran histologi hati termasuk pelebaran vena sentralis, peradangan, dan kerusakan pada struktur sel hati dievaluasi secara deskriptif. Ekstrak daun pegagan tidak menunjukkan pengaruh nyata terhadap kadar enzim GPT dan GOT dalam hati tikus, sedangkan hasil pengamatan gambaran histologi hati tidak terlihat adanya kerusakan sel hati, baik pada perlakuan maupun kontrol. Pemberian ekstrak pegagan sampai dosis 275 mg/kg BB aman dan tidak menimbulkan kerusakan pada sel hati.

Kata kunci: ekstrak pegagan, GPT, GOT, histologi hati, mencit

ABSTRACT

The purpose of this study was to determine whether pegagan caused toxic effects on the liver. This study used completely randomized design with four treatments, ie 125, 200, 275 mg/kg BW and control, each treatment consisting of six replicates. Variables observed were the level of GPT, GOT and histological profile of liver. GPT and GOT levels were analyzed by analysis of single variant of 0.05. Histological picture of the liver include central venous dilation, inflammation, and damage to the structure of liver cells were performed by descriptive evaluation. Pegagan leaf extract did not show significant effect on GPT and GOT level in the liver of mice, whereas the histology results did not reveal any visible damage to liver cells in each dose. Administration of pegagan extract up to dose of 275 mg/kg BW was safe and would not cause damage to the liver cells.

Key words: pegagan extract, GPT, GOT, liver histology, mice

INTRODUCTION

Contraceptive hormones have mark effect on liver function (Katzung, 2002). This effect could occur in long-term oral contraceptive use or in those who have experienced jaundice during pregnancy. Liver damage can be detected by measuring levels of liver transaminase enzymes. According to Aminah (2006), the existence of damages of the liver parenchymal cells or the membrane permeability would lead glutamate oxaloacetic transaminase (GOT) and glutamate pyruvate transaminase

(GPT), argianase, lactate dehydrogenase and gamma glutamyl transaminase to be expelled out of the cell, so that enzyme in the blood exceeds the normal levels. Both GOT and GPT enzymes will rise first with higher increase among other enzymes.

A plant that allegedly had the potential as a contraceptive substance was pegagan (*Centella asiatica* (L.) Urban) (Zheng *et al.*, 2007). Based on the previous research, pegagan at dose of 75 mg/kg BW raised the number of primary, secondary, and tertiary follicles, but at dose 100 mg/kg BB and 125 mg/kg BW tended to decrease the number of primary, secondary, and de Graff follicles. The number of follicles increased due to the presence of these active substances in the extracts of pegagan, especially asiaticoside and madecassoside

* Corresponding author:
Phone/ fax: 0341 558933; e-mail: bayyinatul_uin@yahoo.co.id

(Biswas & Mukherjee, 2000). Both substances had an important role in accelerating the synthesis of collagen (Schaneberg *et al.*, 2003) which was essential for the formation of connective tissue cells in the cortex as the place to the development of ovarian follicles. Decreasing the number of follicles, allegedly was because of the role of the active substances on hormonal metabolism, particularly related to the metabolism and synthesis of reproductive hormones. The existence of an active substance in high doses is presumably capable of causing negative feedback on gonadotropin-releasing hormone.

Triterpenoid lipids are derivatives compounds that are considered to have a role as intermediate compounds in the biosynthesis of steroids (Tisnajaya, 2005). Large amounts of triterpenoid active substance which is allegedly capable of causing lipid derivatives inhibition of LH and FSH release. At high doses, the active substance can stimulate the formation of triterpenoids suspected estrogen, so that high estrogen levels in the blood will affect the hypothalamus to reduce the release of LH and FSH to inhibit follicle growth.

The present research was design to clarify the effects of high doses extract of pegagan leaves (*C. asiatica* (L.) Urban) on GPT and GOT levels and profile of histological liver of *Mus musculus*, considering the liver represents the largest gland in the body which occupies the first place get the toxic effects of foreign compounds.

MATERIALS AND METHODS

Experimental Design

This study applied a complete randomized design (CRD) with six replications. The treatment was oral administration extract of pegagan (*C. asiatica* (L.) Urban) as follows: 0, 125, 200, and 275 mg/kg BW. The variables measured were levels of GPT, GOT, and histological profile of mice liver.

Preparation and Feeding Treatment

C. asiatica leaf powder that has been finally macerated with 70% ethanol solvent for 24 hours while occasionally stirred, then macerated and filtered with a funnel bunchner. The filtrate was concentrated by using rotary evaporator 40 °C until thick extract obtained.

The female mice (*M. musculus*) strain Balb C, age \pm 4 months and weight 20-30 g, were adapted for two weeks before treated for the acclimatization process. This study used four treatment groups, each group consisted of six mice as repetition.

Treatment groups were divided as follows: group 1 (control) mice were given 0.5 ml 0.5% CMC Na, group 2 mice were given a pegagan extract at a dose of 125 mg/kg BW dissolved in 0.5 ml 0.5% CMC Na, group 3 mice were given pegagan extract at a dose of 200 mg/kg BW dissolved in 0.5 ml 0.5% CMC Na, and group 5 mice were given a pegagan extract at a dose of 275 mg/kg BW dissolved in 0.5 ml 0.5% CMC Na. Estrous synchronization was carried out by injecting prostaglandin 0.5 mg per head intramuscularly.

Preparations 0.5% CMC (carboxymethyl cellulose) Na solution was made by adding 500 mg of sodium CMC into 10 ml of hot distilled water, then left for approximately 15 min until translucent colored and shaped like a gel. Further stirring until a homogeneous mass measuring flask and diluted with distilled water until the volume of 100 ml.

Pegagan extract was given orally to fertile females 3 days after injection of the prostaglandin hormone. The extract was made for 30 days by weighing the condensed extract in appropriate dose and diluted with 0.5% CMC Na solution of 0.5 ml.

Transaminase Enzyme Profile

Mice were dissected on the heart. The liver was washed with 10 mM PBS solution and weighed up to 0.5 g, then crushed with a mortar. Furthermore, 0.9% NaCl was added 10 times and homogenized. The homogenate liver was centrifuged at 5009 G for 10 min. Supernatant was separated by pellets and placed in a tube ependorf.

Reagent 1 and reagent 2 were separated with a ratio 4 : 1. Reagent 2 was mixed with 100 μ l supernatant and homogenized with a reagent. The absorbance was measured by using a spectrophotometer at a wavelength of 365 nm.

Histological Observations

Surgery was carried out after 30 days of treatment with following steps: anesthesia by inhalation using chloroform. Surgery was performed vertically from the posterior toward the anterior abdominal area with open area of the abdominal cavity and chest cavity. Liver was fixed in 10% formalin solution and made histological preparation. Preparations were observed through a binocular microscope Nikon E 100 to see the liver histology of mice (*M. musculus*) females that were administered with high dose of pegagan (*C. asiatica* (L.) Urban) leaf extracts (Jones *et al.*, 2001).

Data Analysis

A single varians analysis test was used to determine the effect of high dose of pegagan leaf extracts (*C. asiatica* (L.) Urban) on GPT and GOT levels. If the ANOVA test results showed a difference, further tests will be conducted using DMRT (Duncan Multiple Range Test) 5%. The damage or liver abnormalities, include central venous dilation, inflammation, and damage to the structure of liver cells were observed under microscope and were analyzed descriptively.

RESULTS AND DISCUSSION

GPT and GOT Levels

The GPT levels after administration of pegagan leaf extract as an antifertility substances were 24.54 \pm 4.09 U/I for the control; treatment 1 at 49.54 \pm 4.29 U/I; treatment 2 at 69.10 \pm 4.47 U/I; treatment 3 at 65.90 \pm 3.39 U/I. The

average data of GOT enzyme levels were the control at 24.83 ± 6.48 U/I; treatment 1 at 38.99 ± 2.32 U/I; treatment 2 at 61.49 ± 4.27 U/I; and treatment 3 at 42.90 ± 5.07 U/I (Figure 1). There were no significant effect of pegagan leaf extract as an antifertility substances on liver enzyme levels of GPT and GOT in mice.

Based on the previous research, in terms of fertility, pegagan extract was effective to increase the number of primary follicles, secondary and tertiary at a dose of 75 mg/ kg BW. However, at doses of 100 and 125 mg/kg BW pegagan extract tended to decrease the number of primary follicles, secondary, tertiary, and de Graff. Similarly, in a preliminary study, high doses of pegagan extract (125, 200, and 275 mg/kg BW) was effective to reduce the number of primary, secondary, tertiary follicles, and even the development of ovarian follicles do not reach the follicle de Graff.

The decrease number of follicles, allegedly because of the role of the active substances of hormonal metabolism, particularly related to metabolism and synthesis of reproductive hormones. The existence of an active substance in high doses presumably was able to cause negative feedback on gonadotropin-releasing hormone (Gill *et al.*, 2002). The active ingredient pegagan as a material suspected of potential antifertility is triterpenoid saponin which is one of the steroid derivatives. Steroids have antigonadotropin effectiveness. Therefore, Gill *et al.* (2002) stated that the steroids in the high dosage would result in hypothalamic pituitary disorders in the next lane resulted in interruption GnRH secretion; it would affect the formation of follicular development and maturation.

GPT and GOT levels in the treated mice tended to increase, while usually on liver disease in liver enzyme levels decreased due to a damaged liver cells so that the enzymes leaking into the cell and in plasma. Intracellular levels of both enzymes remained high in liver cells suspected of pegagan extract doses administered over 30 days did not cause damage to liver cells and did not cause leakage of the cell. According to Katzung (2002), liver cell damage caused by various things, including

viral hepatitis, total serum ALT increases precede other symptoms, such as yellow (jaundice). This increase could reach 100 times the highest normal value. Although the majority found was between 20-50 times.

Aspartate aminotransferase (AST) is known by another name GOT. This is the first intracellular enzyme which proves that the measurement of intracellular enzyme activity in the blood can indicate damage to the home network of the enzyme source. These enzymes are spread in various tissues. However, the highest specific activity of the enzyme AST is found in the heart. AST contained in the mitochondria and cytosol (Balasubramanian & Chaterjee, 2010). Both types of enzymes (GPT-GOT) contained in the cells of the liver in high concentrations. GOT might also be present in other tissues in the increased permeability of cell membranes, enzymes can get out of the cell.

Based on several studies, in addition to triterpenoid saponins alleged potential as antifertility substances, *C. asiatica* was also reported containing numerous flavonoid, that were quercetin, kaempferol, catechin, rutin, and naringin as a mayor part of the total phenolic contentivity of *C. asiatica* (Zainol *et al.*, 2003).

Liver Histological Profile

The result images of liver preparation showed that treatment 1 (125 mg/kg BW), treatment 2 (200 mg/kg BW), and treatment 3 (275 mg/kg BW) were similar to controls (Figure 2). These treatments did not seem to damage the liver cells. Based on the hypothesis, free radical was mediated toxicity in oxidative stress process and depending on its antioxidant properties. *C. asiatica* showed antilipid peroxidative and free radical scavenging activities (Wong *et al.*, 2006; Hussin *et al.*, 2007).

Isoflavones, a class of flavonoids, are substances similar to estrogen, but unlike the OH bond. In the body of isoflavones is similar to estrogen. According to Shetty *et al.* (2006), natural or synthetic estrogens could affect physiological processes and functions that the liver is an important organ in the process of metabolism. Using

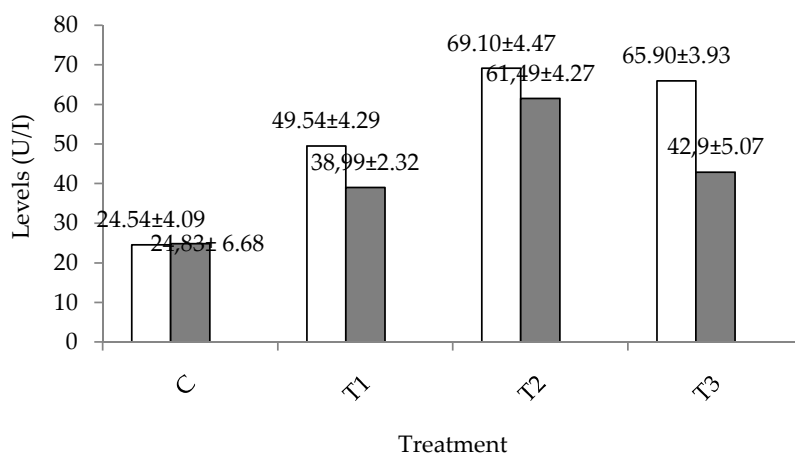


Figure 1. Level of glutamate pyruvate transaminase (GPT= □) and glutamate oxaloacetic transaminase (GOT= ■) after administration of pegagan (*Centella asiatica* (L.) Urban) leaf extract (C= control; T1= 125 mg/kg BW; T2= 200 mg/kg BW; T3= 275 mg/kg BW).

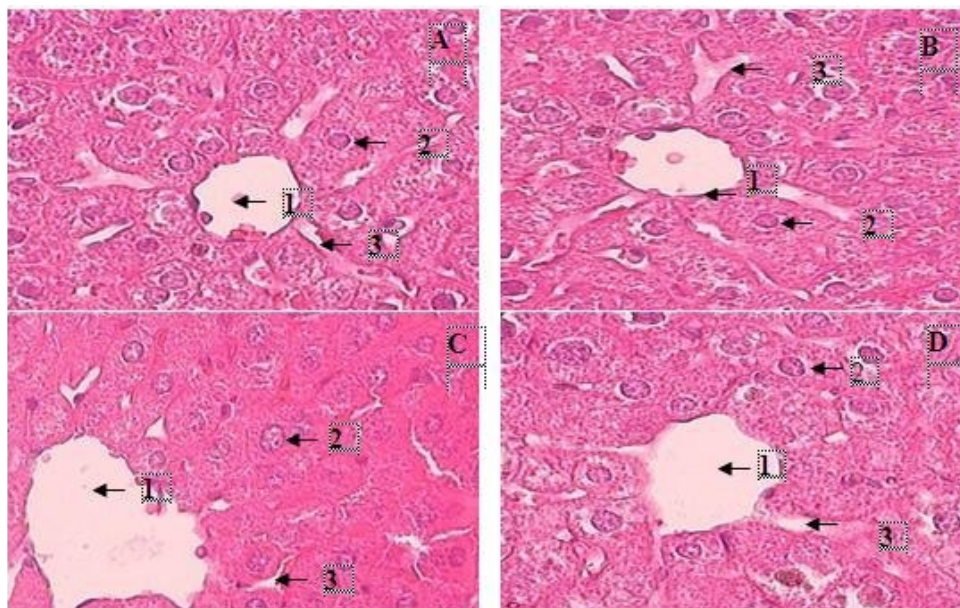


Figure 2. The histology of liver tissue of mice administered pegagan (*Centella asiatica* (L.) Urban) extract. 1= Central venous, 2= Hepatocytes, 3= Sinusoids; A= Control; B= 125 mg/kg BW; C= 200 mg/kg BW; D= 275 mg/kg BW.

a large dose of estrogen over long periods can cause obstacles bile secretion, bile acid and bilirubin excretion, and metabolism bromsulfatalein. Impaired bile secretion due to oral contraceptives is very complex process and can represent the end result of sex hormone effects on metabolism in parenchymal liver cells.

Impaired liver function test which caused these contraceptives would disappear when drug use ceases. At a certain dose of suspected flavonoids can repair damaged liver cells and cause a near-normal enzyme levels. Flavonoids are phenolic substances characterized for a low molecular weight and they are abundant in plant tissues (Erkoc *et al.*, 2003; Wolfe *et al.*, 2003) with multiple and sometimes opposing activities: iron chelation, protein kinase C (PKC) inhibition, inhibition of lipoxygenases and antioxidant. In the human body they show a lot of biological properties such as antioxidants, antiallergenic, antibacterial, antifungal, antiviral, and anticarcinogenic agents (Lekka *et al.*, 2009; Malesev & Kuntic, 2007). The mechanism by which flavonoids carry out their properties, mainly their antioxidant power, is either by inhibiting the formation or activity of reactive oxygen species, or by directing interaction with DNA, enzymes, and membrane receptors (Sergio *et al.*, 2010). This is apparently because of the active ingredients contained in the leaves of pegagan in addition to triterpenoid saponins and flavonoids are asiaticoside and madekossida (Siddiqui *et al.*, 2006). Asiaticoside and madekossida can stimulate collagen synthesis and repair damaged cells (Shetty *et al.*, 2006). Fibroblasts is very important in the formation of collagen fibers, collagen protein, and nurtured over 30% of whole body protein of mammals. Therefore, collagen fibers play a role in the wound healing or tissue damage.

Recent studies have led to the isolation of other triterpenes with healing potential, namely, terminolic

acid, madecassoside, and asiaticosdie-B (Schaneberg *et al.*, 2003). Scaffoleoside A and saponins (centella saponins B, C, and D) with four ursane- and oleanane-type triterpene oligoglycosides were isolated from *C. asiatica* growing in Sri Lanka by Matsuda *et al.* (2001). Extensive clinical investigation on *C. asiatica* has led to the use of the plant in managing diabetics (Cesarone *et al.*, 2001), hypertension, and edema (De Sanctis *et al.*, 2001; Incandela *et al.*, 2001a,b) in addition to its evaluations in wound treatment. Besides the influence of some active ingredients of pegagan, the absence of liver cell damage caused liver has an amazing ability to regenerate. In mice, the liver can regenerate lost 75% weight in one month (Suzuki *et al.*, 2008).

CONCLUSION

The extract of *C. asiatica* (L.) Urban dose up to 275 mg/kg did not affect the enzyme levels of GPT and GOT in mice. But the average GPT-GOT enzyme levels tended to increase, although still within the normal range. The extract of *C. asiatica* (L.) Urban did not cause damage to liver cells up to dose of 275 mg/kg BW and that were similar to controls.

REFERENCES

- Aminah, N. 2006. Perbandingan kadar Pb, Hg, fungsi hati dan fungsi ginjal pada karyawan BBKTL Surabaya. *Jurnal Kesehatan Lingkungan* 2: 111-120.
- Balasubramanian, T. & T. P. Chatterjee. 2010. Hepatoprotective and antioxidant effects of *Stereospermum suaveolens* on carbon tetrachloride-induced hepatic damage in rats. *Journal of Complementary and Integrative Medicine*. 7: 22-38.
- Biswas, T. K. & B. Mukherjee. 2000. Plant medicines of Indian origine for wound healing activity: a review. *Int. J. Low Extrem Wounds* 2: 25-39.

- Cesarone, M. R., L. Incandela, M. T. De Sanctis, G. Belcaro, P. Bavera, M. Bucci, & E. Ippolito.** 2001. Evaluation of treatment of diabetic microangiopathy with total triterpenic fraction of *Centella asiatica*: A clinical prospective randomized trial with a microcirculatory model. *Angiology* 52 (Suppl 2): S49–54.
- De Sanctis, M. T., G. Belcaro, L. Incandela, M. R. Cesarone, M. Griffin, E. Ippolito, & M. Cacchio.** 2001. Treatment of edema and increase capillary filtration in venous hypertension with total triterpenic fraction of *Centella asiatica*: A clinical, prospective, randomized, dose ranging trial. *Angiology* 52 (Suppl 2): S55–59.
- Erkoc, S., F. Erkoc, & N. Keskin.** 2003. Theoretical investigation of quercetin and its radical isomers. *J. Mol. Struct - Theochem.* 631:141-146
- Gill, S., J. L. Sharpless, K. Rado, & J. E. Hall.** 2002. Evidence that GnRH decreases with gonadal steroid feedback but increases with age in oestropausal women. *J. Clin. Endocrinol. Metab.* 87:2290-2296. doi:10.1210/jc.87.5.2290.
- Hussin, M., A. Hamid, & S. Mohammad.** 2007. Protective effect *Centella asiatica* extract and powder on oxidative stress in rats. *J. Food Chemical.* 100: 535-541.
- Incandela, L., M. R. Cesarone, M. Cacchio, M. T. De Sanctis, C. Santavenere, M. G. D'Auro, M. Bucci, & G. Belcaro.** 2001a. Total triterpenic fraction of *Centella asiatica* in chronic venous insufficiency and in high perfusion microangiopathy. *Angiology* 52 (Suppl 2): S9–13.
- Incandela, L., G. Belcaro, M. T. De Sanctis, M. R. Cesarone, M. Griffin, E. Ippolito, M. Bucci, & M. Cacchio.** 2001b. Total triterpenic fraction of *Centella asiatica* in treatment of venous hypertension: A clinical, prospective, randomized trial using a combined microcirculatory model. *Angiology* 52 (Suppl 2): S61–67.
- Jones, M. L., J. D. Bancroft, & M. Genble.** 2001. *Connective Tissue and Stains. Theory and Practice of Histological Techniques.* 6th ed. Churchill Livingstone. Elsevier. Pp. 135-160.
- Katzung, B. G.** 2002. *Farmakologi Dasar dan Klinik.* Salemba Medika, Jakarta.
- Lekka, C. E., J. Ren, S. Meng, & E. Kaxiras.** 2009. Structural, electronic and optical properties of representative Cu-flavonoid complexes. *J. Phys. Chem. B.* 113:6478-6483.
- Matsuda, H., T. Morikawa, H. Ueda, & M. Yoshikawa.** 2001. Medicinal foodstuffs. Saponin constituents of gotu kola : Structure of new ursane and oleanane type triterpene oligoglycosides, centella saponins B, C and D, from *Centella asiatica* in Sri Lanka. *Chem. Pharm. Bull. (Tokyo)* 49: 1368–1371.
- Malesev, D. & V. Kuntic.** 2007. Investigation of metal-flavonoid chelates and the determination of flavonoids via metal-flavonoid complexing reactions. *J. Serb. Chem. Soc.* 72: 921-939.
- Schaneberg, B. T., J. R. Mikell, E. Bedir, & I. A. Khan.** 2003. An improved HPLC method for quantitative determination of six triterpenes in *Centella asiatica* extracts and commercial products. *Pharmazie* 58: 381–384.
- Sergio A Payan-Gomez, Norma Flores-Holguin, Antonino Perez-Hernandez, Manuel Pinon-Miramontes, & Daniel Glossman-Mitnik.** 2010. Computational molecular characterization of the flavonoid rutin. *Chem. Cent. J.* 4:12. doi:10.1186/1752-153X-4-12
- Shetty, B. S., S. L. Udupa, A. L. Udupa, & S. N. Somayaji.** 2006. Effect of *Centella asiatica* L (Umbelliferae) on normal and dexamethasone-suppressed wound healing in wistar albino rats. *Int. J. Low Extrem. Wounds* 5:137-143. DOI: 10.1177/1534734606291313.
- Siddiqui, B. S., H. Aslam, S. T. Ali, S. Khan, & S. Begum.** 2006. Chemical constituent of *Centella asiatica*. *J. Asian Nat. Prod. Res.* 9: 407-414.
- Suzuki, K., M. Tanaka, N. Watanabe, S. Saito, H. Nonaka, & A. Miyajima.** 2008. p75 Neurotrophin receptor is a marker for precursors of stellate cells and portal fibroblasts in mouse fetal liver. *Gastroenterology* 135:270–281. doi:10.1053/j.gastro.2008.03.075.
- Tisnajaya, D.** 2005. Pengkajian kandungan fitosterol pada tanaman kedawung (*Parkia roxburghii* G. Don). *Jurnal Biodiversitas Lembaga Ilmu Pengetahuan Indonesia.* 7: 21-24
- Wolfe, K., X. Wu, & R. H. Liu.** 2003. Antioxidant activity of apple peels. *J. Agric. Food Chem.* 51: 609-614
- Wong, S. P., L. P. Leong, & J. H. W. Koh.** 2006. Antioxidant activities of aqueous extracts of selected plants. *J. Food Chemical.* 99: 775-783.
- Zainol, M. R., A. Hamid, & S. Yusuf.** 2003. Antioksidative activity and total phenolic compound of leaf, root and petiole of four accessions of *Centella asiatica* (L) Urban. *J. Food Chem.* 81: 575-581.
- Zheng, C. J. & L. P. Qin.** 2007. Chemical components of *Centella asiatica* and their bioactivities. *Zhong Xi Yi Jie He Xue Bao* 5: 348-351. DOI.10.3736/JCJM 20070324.
- Yanagimachi, R.** 1994. Mammalian Fertilization. In: Knobil, E. & J. D. Neill. *The Physiology of Reproductive.* Vol. 1. The Physiology of Reproduction. Raven Press, Ltd. New York. Chapter 5: 135 – 185.