

CASE REPORT

Orbital cellulitis as a complication of odontogenic infection

Puji Yuli Christiani Purba*✉, Melita Sylviana**, Endang Syamsudin**, Rani Seprina***

*Study Program of Oral and Maxillofacial Surgery, Faculty of Dentistry, Padjajaran University, Bandung, West Java, Indonesia

**Department of Oral and Maxillofacial Surgery, Faculty of Dentistry, Padjajaran University, Bandung, West Java, Indonesia

***Department of Plastic and Reconstructive Surgery, Faculty of Medicine, Padjajaran University, Bandung, West Java, Indonesia

*JI Raya Bandung Sumedang, Bandung, West Java, Indonesia; ✉ correspondence: purbapuji@gmail.com**Submitted: 2nd August 2018; Revised: 27th December 2018; Accepted: 11st March 2019****ABSTRACT**

Orbital cellulitis is uncommon sequelae of the spread of odontogenic infection to adjacent maxillary sinuses or to distant sites such as the orbits. Once it happened, the spread of such infection can be of serious complication such as complete blindness or even more serious and life threatening situations as cavernous sinus thrombosis, intra-cranial abscess, or even death. This paper aimed to expose the guideline treatment of orbital cellulitis as a complication of odontogenic infection. It reported one case of orbital cellulitis in the emergency unit of Hasan Sadikin hospital Bandung, with complaints of pain, swelling at cheek and periorbital region, and the history of toothache. The treatment include incision drainage, extraction of tooth, and parenteral administration of antibiotic and analgesic. Odontogenic infections are derived from dental infection and can potentially spread rapidly to be ascending infection like orbital cellulitis. Odontogenic infection and orbital cellulitis should be adequately treated with incision drainage, extraction of tooth and parenteral administration of antibiotic, steroid and analgesic. Without immediate treatment, odontogenic infection can lead to ascending infection. Orbital cellulitis due to spreading of odontogenic infection is a rare case. In this case report, the patient had a significant improvement due to immediate and proper treatment.

Keywords: ascending infection; odontogenic infection; orbital cellulitis**INTRODUCTION**

Orbital cellulitis is an infection that affects the soft tissues of the orbit, including fat and muscle with the posterior orbital bone to the orbital septum.¹ Orbital cellulitis can occur in all age groups but is more common in the pediatric population. Clinical features of orbital cellulitis include swelling in the orbital region, proptosis, chemosis, and increased orbital and intraocular pressure.² Orbital cellulitis can cause blindness and life-threatening complications, including optic neuropathy, encephal meningitis, cavernous sinus thrombosis, sepsis, intracranial abscess formation until death.^{3,4} Orbital cellulitis is associated with significant complications, so it is necessary to establish an immediate and accurate diagnosis and treatment to reduce the occurrence of complications. Orbital cellulitis commonly occurs from paranasal sinus infection, trauma, entry of

foreign objects into the eye, and odontogenic infections.

Odontogenic infection is one of the most common infections of the alveoli, jaw, or face that originates from the teeth or from a supportive structure. Odontogenic infections commonly occur from dental caries, deep fillings or failed root canal treatment, pericoronitis and periodontal disease. When microorganisms enter the periapical tissues through the apical foramen, the microorganism induces an inflammatory process that can lead to abscess formation.⁵ Odontogenic infections that most often lead to facial spaces infection are complications of periapical abscesses. Odontogenic infection or infection affecting the tooth structure (pulp and periodontal) expands to the periapical region and extends to the oral cavity by penetrating the vestibular cortical layer and the

periosteum from the jaw bone. Without immediate treatment, odontogenic infection may turn into a focal infection that can spread through the blood vessels and lymph vessels and affect several facial spaces and go downward (descending infection), as well as upward spread (ascending infection), such as the case of cellulitis orbita.⁶ Odontogenic infections may expand to orbital infection through several pathways. The root tip of the tooth is anatomically attached to the connective tissue and sinuses. The most common cause is the spread through the maxillary sinus to the inferior part of the orbit, through the inferior orbital fissure, or through a defect at the orbital base.⁷ Generally, 2-5% of orbital cellulitis cases comes from odontogenic infection.⁸

METHODS

This case study reported a 65-year-old female patient who came with chief complaints of swelling in the right eye since 5 days prior to admission followed by toothache in the upper jaw. The patient went to the general practitioner and was given 3 types of medicine (the patient could not tell the name of the medicine). One day prior to admission, the swelling in the right eye got bigger, so she could barely open her eyes. Then, the patient went to the dental hospital and was given 3 types of medicine (amoxicillin + paracetamol + sodium diclofenac), and was directly referred to emergency unit of Dr. Hasan Sadikin hospital Bandung. History of sinusitis and systemic disease was denied. Patient had a history of using dentures since ± 5 years ago. Before clinical examination and treatment, patient

received procedure of treatment and potential risks and signed informed consent.

The physical examination indicated that the patient was fully alert, looked moderate to pain, pain (VAS 4/10). Vital signs showed the temperature of 36.6 °C, pulse of 84x/minute, respiration of 22x/minute, and blood pressure of 130/80 mmHg. Extraoral examination reveal asymmetrical form with swelling in the right canine fossa region extending into the periorbital region (Figure 1A). The palpation indicated warmth, pain, and fluctuations. Intraoral examination indicated visible radices of 16, 14, 13, 12, 11, 21, 22, 36, 34, 33, 32, 43, 45, 46 (Figure 1B). Laboratory results showed leukocytosis of (13.840/mm³), while others was within normal limit. Then, the patient was consulted to the ophthalmology department. The visual examination found VOD 20/400 and VOS 20/100. It showed proptosis in palpebra superior and inferior, blepharospasm, edema, hyperemia and pain in tenderness on right orbital (Figure 1C).

Based on clinical and supporting examination (Figure 2), the patient was diagnosed with canina fossa abscess due to radices 13 and orbital cellulitis. The ophthalmology department status diagnosed this patient with orbital celulitis on right orbital and immature senile cataract. The patient was carried out by the source control and drainage incision in local anesthesia. Pus aspiration was previously carried out for bacterial culture and antibiotic sensitivity. The result of bacterial culture and antibiotic sensitivity was obtained on day 7-10.

Patient was extracted on all teeth with radices and an intraoral drainage incision was performed

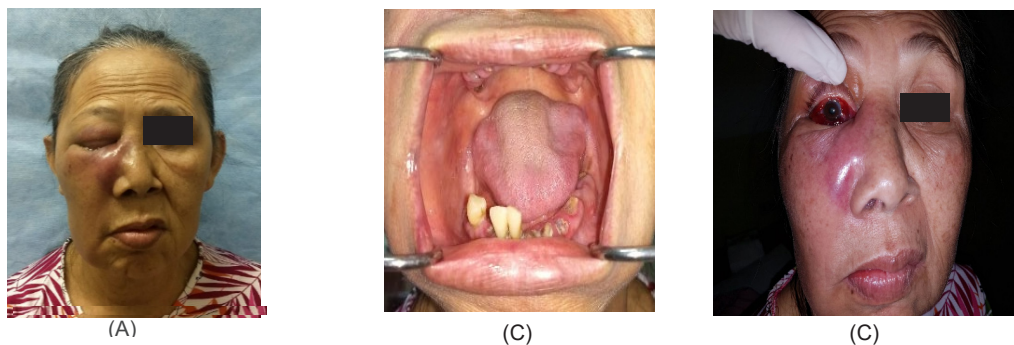


Figure 1. Preoperative at the emergency (A and B) extraoral profiles showed swelling in the canine fossa right to right periorbital (C) Intraoral photos showed a lot of radices

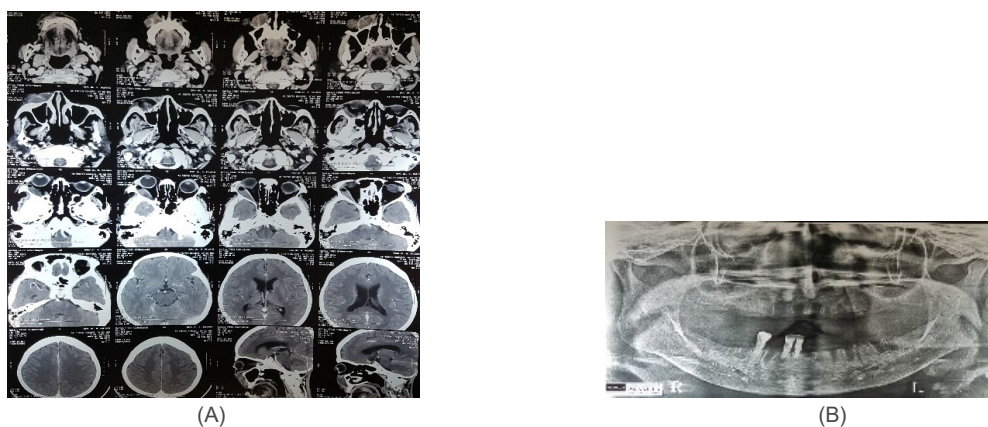


Figure 2. CT Scan of the Head Orbita with Contrast (after 8 days), showing right lateral retrobulber cellulitis accompanied by gas formation and proptosis on right orbital, not visible signs of sinusitis (A) Panoramic Photo Post extraction (after 1 day) (B)

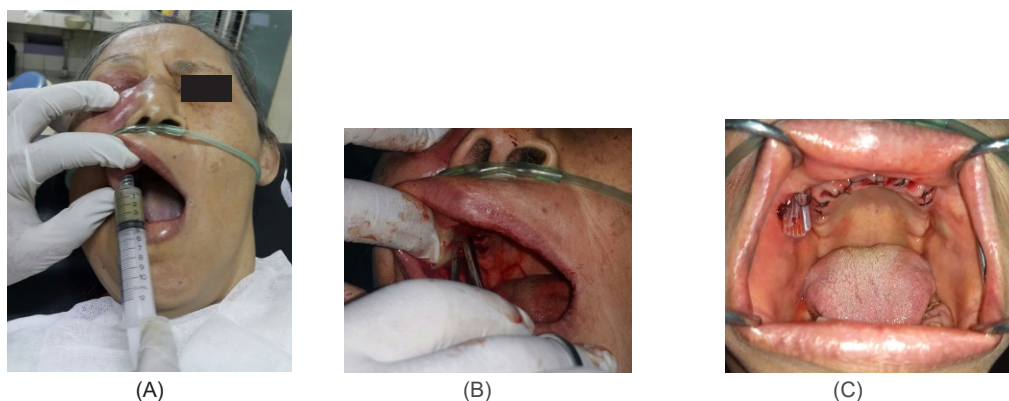


Figure 3. Pus aspiration in the right canine fossa region (A) Incision drainage in the right fossa region (B) Application of Intraoral drain (C)

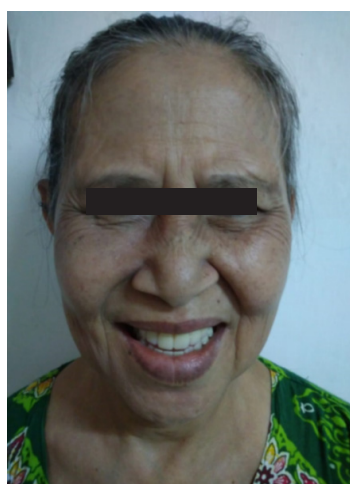

Figure 4. Clinical features in 3-month control, symmetrical face, no signs of infection, eyes can see normally. Patients already uses dentures.

on the right canine fossa area (\pm 20 mLpus) and maintained with intraoral drainage (Figure 3C). In addition, antibiotics, high-dose steroids and analgesics were given parenterally. The patient experienced significant improvement, and began to receive outpatient care on day 5. Figure 4 shows the clinical condition of the patient after the procedure.

DISCUSSION

Orbital cellulitis is an infection that affects the soft tissues of the orbit, including fat and muscle with the posterior orbital bone to the orbital septum.¹ The clinical picture of orbital cellulitis includes swelling in the orbital region, proptosis, chemosis, and increased orbital and intraocular pressure.² According Chandler's classification, clinically orbital cellulitis is divided into 5 stages namely stage 1 (inflammatory edema), stage 2 (orbital cellulitis), stage 3 (periosteal abscess), stage 4 (orbital abscess), and stage 5 (cavernous sinus thrombosis). Whereas radiologically, orbital cellulitis is classified into 3 main categories, namely diffuse fat tissue infusion, subperiosteal abscess, and orbital abscess.⁷ Clinically and radiologically, this case is classified as stage 2. Orbital cellulitis can cause blindness and life-threatening complications, including optic neuropathy, encephal meningitis, cavernous sinus thrombosis, sepsis, intracranial abscess formation until death.^{3,4}

In this case, the patient experienced a decrease in right eye vision until she could not see. Without immediate and proper treatment, it can lead to permanent blindness. Corticosteroids are known to have anti-inflammatory effects that can reduce the worst risk until death. Research conducted by Pushker N, et al (2013) states that corticosteroid use along with antibiotics has a very good advantage in acute orbital cellulitis. The addition of steroids can help reduce inflammation and improve patient recovery.⁹ This is in accordance with the case of this patient, which was given steroids in the form of dexametasone, ceftriaxone antibiotics and metronidazole as empirical antibiotics. The steroid administration was proven to rapidly decrease inflammation in the patient's right eye. Empirical antibiotics were given after waiting for the

results of pus culture and antibiotic sensitivity. The results of culture found gram-positive coagulase-negative staphylococci (CoNS) bacteria. This result is consistent with the research conducted by Teweldemedhin et al (2017) that coagulase-negative staphylococci (CoNS) is one of the bacteria that is often found on the ocular surface of the eye.¹⁰ From the results of antibiotic sensitivity cultures, sensitive results were found in all classes of antibiotics, and thus ceftriaxone and metronidazole administration is appropriate. In addition to parenteral treatment, topical treatment was also given in the form of eye drops containing NaCl, KCl, levofloxacin antibiotics and chloramphenicol ointment. This treatment was given by ophthalmologist, and the patient was constantly observed until her conditions improved.

The pathogenesis of orbital cellulitis originating from odontogenic can spread through several routes including infection of the teeth of the maxillary posterior teeth (first molar with the highest incidence), and through the buccal to spread posteriorly through the orbital fissure or through the sinus wall, through the anterior face and vein ophthalmic, pterygopalatine, odontogenic abscess and spread through soft tissue, and through canine fossa.^{7,11} In this patient, the spread of infection to orbital was not from sinusitis, because the orbital CT scan, panoramic photos and history of the patient did not indicate signs of sinusitis. From clinical examinations, signs of extension of infection to the orbit was spread through the canine fossa as characterized by abscesses of the canine fossa which was spread ascending to the orbit. Patients had a history of upper right toothache, and radices were found in the right upper quadrant. Extraction of all gangrenous radices teeth and drainage incisions in the intraoral canine fossa area was carried out. Spontaneous drainage from the tooth socket 13 was extracted, so it was concluded that the canine fossa abscess extending to orbital cellulitis was due to tooth 13.

The location of the right incision can maximize adequate pus drainage. In this case, twenty milliliter of pus production was obtained from intraoral, and maintained using intraoral drainage. Intraoral drainage was placed several days until the

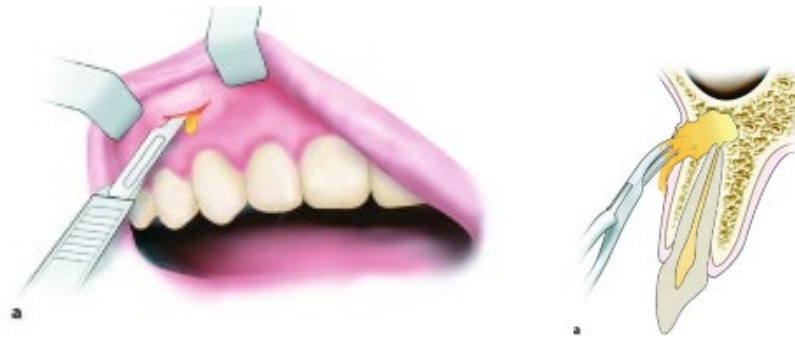

Figure 5. Intraoral incision in the canine fossa⁶

production of pus was minimal. Drain replacement was done every 3 days, massage for maximum evacuation of the pus, and irrigation every day. Irrigation with saline solutions and antibiotics was reported to be effective in eliminating or reducing infection.¹² In addition, patient required supportive therapy to support the healing process. The patient was provided with supportive therapy of education and the provision of high-calorie high-protein diets according to the needs of patients. Furthermore, the patient was advised to make new dentures to maintain the stomatognathic and aesthetic functions.

CONCLUSION

Orbital cellulitis must be recognized and treated quickly and precisely to prevent it from further complications, one of which is blindness. Orbital cellulitis can occur from odontogenic infection. Hence, it is necessary to have adequate knowledge and management. In this case, the patient experienced a decrease in vision due to orbital cellulitis, but the patient experienced a significant improvement due to immediate management in an effort to prevent the spread of infection and further complications.

REFERENCES

1. Mallika OU, Sujatha N, Smitha NMS, Sinumol S. Orbital and preseptal cellulitis. *Kerala Journal of Ophthalmology*. 2011; 23(1): 10-14.
2. Hupp JR, Ferneini EM. *Head, neck and orofacial infections: an interdisciplinary approach*. Missouri: Elsevier; 2016. 496.
3. Yeh CH, Chen WC, Lin MS, Huang HT, Chao SC, Lo YC. Intracranial brain abscess preceded by orbital cellulitis and sinusitis. *J Craniofac Surg*. 2010; 21(3): 934–936. doi: 10.1097/SCS.0b013e3181d84124.
4. Imtiaz AC, Al-Rashed W, Arat YO. The hot orbit: orbital cellulitis. *Middle East African Journal of Ophthalmology*. 2012; 9(1): 34-42. doi: 10.4103/0974-9233.92114
5. Ogle OE. Odontogenic infections. *Dent Clin North Am*. 2017; 61(2): 235–252. doi: 10.1016/j.cden.2016.11.004.
6. Borle RM. *Textbook of Oral and Maxillofacial Surgery*. Jaypee Brothers Medical Publishers. New Delhi; 2014.
7. DeCroos FC, Liao JC, Ramey NA, Li I. Management of odontogenic orbital cellulitis. *Journal of Medicine and Life*. 2011; (4)3: 314-317.
8. Yan W, Chakrabarti R, Choong J, Hardy T. Orbital Cellulitis of Odontogenic Origin. *Orbit*. 2015;34(4):183-185
9. Pushker N, Tejawani LK, Bajaj MS, Khurana S, Velpandian T, Chandra M. Role of Oral Corticosteroid in Orbital Cellulitis. *AM J Ophthalmol*. 2013; 156(1): 178-183.
10. Teweldemedhin M, Saravanan M, Gebreyesus A, Gebreegiabiher D. Ocular bacterial infections at quaha ophthalmic hospital, Northern Ethiopia: an evaluation according to the risk factors and the antimicrobial susceptibility of bacterial isolates. *BMC Infect Dis* 17. 2017; 17(1): 207. doi:10.1186/s12879-017-2304-1

11. Bourlidou E, Kyrgidis A, Venetis G, Panacleridou T, Mangoudi D. Orbital abscess and inflammation of odontogenic origin. *J Pak Med Stud.* 2012; 2(3): 92-97.
12. Nawaz KK. Management of facial space infection in a 9-year old child – a case report. *International Journal of Clinical Oral and Maxillofacial Surgery.* 2016; 2(1): 1-4. doi: 10.11648/j.ijcoms.20160201.11