



Pathogenesis, evaluation, and recent management of diabetic foot ulcer

Lorettha Wijaya^{1,2}, Arief Budiyanto³, Indwiani Astuti⁴, Mustofa⁴

¹Doctorate Program of Medical and Health Science, Faculty of Medicine, Public Health and Nursing, Universitas Gadjah Mada, Yogyakarta, ²Department of Dermatology and Venereology, School of Medicine and Health Sciences, Atma Jaya, Catholic University of Indonesia, Jakarta, ³Department of Dermatology and Venereology, Faculty of Medicine, Public Health and Nursing, Universitas Gadjah Mada, Yogyakarta, ⁴Department of Pharmacology and Therapy, Faculty of Medicine, Public Health and Nursing, Universitas Gadjah Mada, Yogyakarta, Indonesia.

ABSTRACT

Submitted: 2018-06-21

Accepted : 2019-04-23

Diabetic foot ulcers (DFUs) are a major health problem as the number of patients continues to increase, are difficult to heal, require enormous management costs, and deteriorate the quality of life of patients, their families and societies. The pathogenesis of DFUs is complex. Most important factors that increase the risk of DFUs are peripheral neuropathy, foot deformities, frequent minor trauma, and peripheral arterial disease. Neuropeptides derangement, hypoxia, hyperglycemia, and infection act as the cause of chronicity of DFUs. Therefore, during the initial evaluation of DFU, patients need to be checked for their metabolic status, presence or absence of peripheral neuropathy, vascular insufficiency, foot deformities, and infection of the ulcer and its underlying bone. Then, DFUs are classified by the severity of vascular insufficiency, the depth of the wound, and the severity of the infection. This classification system helps clinicians to determine whether the patient needs to be hospitalized or amputated and helps to establish DFU management strategies. In the management of DFUs, adequate blood flow to the wound area should be achieved. Glycemic control and standard wound care should be encouraged. Standard wound care includes debridement, offloading, wound moisture balance with suitable dressing, edema control, and infection control. Education about preventive foot care should be taught to the patients and their families. As the pathogenesis and management of DFUs are complex, a multidisciplinary team consists of expert individuals in their respective fields should be involved.

ABSTRAK

Ulkus kaki diabetik (UKD) masih merupakan masalah dalam bidang kesehatan karena jumlahnya terus meningkat, sulit disembuhkan, membutuhkan biaya penanganan yang besar, dan dapat memperburuk kualitas hidup pasien beserta keluarga dan masyarakat sekitarnya. Patogenesis UKD sangat kompleks. Faktor terpenting yang meningkatkan risiko terjadinya UKD adalah neuropati perifer, deformitas kaki, seringnya terjadi trauma minor pada kaki, dan penyakit arterial perifer. Gangguan neuropeptida, hipoksia, hiperglikemia, dan infeksi berperan sebagai penyebab UKD menjadi kronis. Oleh karena itu, pada evaluasi awal pasien dengan UKD perlu diperiksa mengenai status metabolik pasien, ada tidaknya neuropati perifer, insufisiensi vaskular, deformitas kaki, dan infeksi pada ulkus maupun tulang di bawahnya. Selanjutnya, pasien UKD diklasifikasikan berdasarkan keparahan insufisiensi vaskular, kedalaman luka, dan keparahan infeksinya. Sistem klasifikasi ini membantu menentukan apakah pasien perlu dirawat inap atau diamputasi dan membantu membuat strategi penatalaksanaan UKD. Dalam penatalaksanaan UKD, aliran darah ke daerah luka perlu diusahakan agar adekuat. Kontrol glikemik dan perawatan luka standar juga perlu adekuat. Perawatan luka standar meliputi *debridement*, *offloading*, menjaga kelembapan luka dengan bahan balut yang sesuai, kontrol edema, dan kontrol infeksi. Edukasi tentang perawatan kaki perlu diajarkan pada pasien dan keluarganya. Tim yang terdiri dari individu-individu ahli dalam bidangnya masing-masing diperlukan untuk menangani UKD mengingat kompleksitas faktor yang terlibat dalam patogenesis dan tatalaksananya.

Keywords:

diabetic foot ulcer
classification system
initial evaluation,
management,
risk factors
standard wound care

INTRODUCTION

Diabetic foot ulcer (DFU) is defined as an ulcer affected the foot of a diabetic patient that associated with peripheral neuropathy and/or arterial disease.^{1,2} It is a chronic and devastating complication of diabetes.^{1,3} Only two-thirds of foot ulcers heal, while the rest of them will remain active.⁴ Within 6–18 months after initial evaluation, 5–24% of DFU cases will end in limb amputation.¹

Diabetic foot ulcers are common worldwide, although its frequency and severity vary from region to region.⁴ A previous study has found that the global prevalence of DFU was 6.3%, while in Asia it was 5.5%.³ The incidence of DFU has increased due to the increasing worldwide prevalence of DM in all age-groups.^{3,5} The lifetime risk for developing foot ulcer in a diabetic patient is 15–25%.^{1,6} Based on gender and type of DM, DFUs are more prevalent in male (4.5%) than female (3.5%) and in patients with type 2 DM (6.4%) than in patients with type 1 (5.5%).³ Indonesia ranks fourth in the list of countries with the highest numbers of estimated cases of DM for the year 2000 and 2030.⁵ Ministry of Health, Republic of Indonesia has reported that the proportion of DM in ≥ 15 years age-groups in Indonesia in 2013, based on blood glucose examination, was 6.9%. There were 54.0% foot neuropathy, 10.9% peripheral arterial disease, 8.7% foot ulcer, and 1.3% amputation in RSUP Dr. Cipto Mangunkusumo Jakarta (RSCM), which were reported as the complications of DM in 2011.⁷

Diabetic foot ulcers present as a major burden in economic.⁶ As much as one third of \$176 billion is spent annually for lower-extremity-related diabetes care in the United States.⁸ Aside than that, foot ulcers adversely affect the quality of life of the patients, their families, and society because of the frequent recurrence and limb amputation.⁶ Previous study found that about 40% of

patients had a recurrence within 1 year after the ulcers heal, almost 60% within 3 years, and 65% within 5 years.⁸ Foot ulcers, which subsequently deteriorate to severe infection or gangrene, precede about 85% of all amputations in diabetic patients.² Indonesia, as the fourth countries with the highest numbers of diabetes,⁵ will face the same burden on its healthcare system.

Diabetic foot ulcer is multifactorial in nature.⁹ Multidisciplinary approach is required to give a proper management.^{9,10} Nevertheless, the outcome of management of DFUs still remains a challenge.¹¹ Combination of detrimental effect on patients' health, major economic burden, and unsatisfactory outcome of management encourage us to review DFUs. This review aimed to provide the pathogenesis of DFU, what should be done in the initial evaluation of patients presenting foot ulcer and how to classify DFU, and the recent recommended managements for DFUs.

DISCUSSION

Pathogenesis of DFU

Development of foot ulcer in diabetic patients

There are various risk factors for the development of foot ulcers in diabetic patients. The most important factors are peripheral neuropathy, foot deformity, minor trauma, and peripheral arterial disease.^{2,12}

Up to 66% of diabetic patients experience neuropathy in the lower extremity.¹⁰ It is attributable to chronic hyperglycemia exposure.^{10,13} Sensorimotor polyneuropathy is the most prevalent neuropathy in diabetes.¹³ The sensory neuropathy is associated with lack of sensation of injuries; thus the foot becomes vulnerable to mechanical or pressure or thermal injury.² Repetitive shear stress on an area is the common cause of DFUs.⁸ The motor neuropathy triggers atrophy in intrinsic foot and leg

muscles. The body becomes unable to coordinate movements and the anatomy of the foot gradually altered, initiates the formation of foot deformities.^{2,10} Foot deformities, limited joint mobility and lack of sensation result in abnormal biomechanical loading of some areas of the foot. The skin on that areas thicken (callus formation), undergo subcutaneous hemorrhage, and finally begin to ulcerate.² Over time, diabetic patients may develop autonomic dysfunction in the lower extremity. It affects the sudomotor and results in foot skin dryness. The dry skin is vulnerable to crack and ulcerate.^{13,14} Peripheral arterial disease (PAD) causes inadequate transfer of oxygen and nutrients to the wound area and increases the risk of the wound to become chronic and also infected.^{2,10,12,15}

Chronicity of DFU

Cellular components, extracellular matrix (ECM), cytokines and growth factors coordinate the orderly overlapping 4 phases in normal wound healing process.^{4,16,17} Diabetic foot ulcer fails to progress through those normal phases, hence is susceptible to become chronic.^{10,14,18} Failure of the DFU to heal is connected to neuropeptides derangement, hypoxia, and hyperglycemia. Neuropeptides play a role in controlling inflammation, angiogenesis, cytokines expression, and growth factors release. Neuropeptides derangement is linked to the peripheral neuropathy. Hypoxia is linked to the PAD. Hyperglycemia triggers defective response to hypoxia and dysfunctions in the diabetic cells and tissues.^{10,19-21}

Hypoxia in a wound area normally induces stability of hypoxia-inducible factor (HIF)-1 α , a subunit of an important transcription factor HIF-1, which mediates adaptation response of cells to hypoxia.^{22,23} The stability and transactivation function of HIF-

1 α is compromised by hyperglycemia through several mechanisms, such as methylglyoxal and reactive oxygen species (ROS).²³ As a result, HIF-1 is degraded and leads to impaired hypoxia-induced genes transactivation in many cellular components of wound healing.²³⁻²⁵

Defective response of HIF-1 to hypoxia triggered by hyperglycemia occurs in many cells, including neutrophils and macrophages. Impairment of glycolytic enzymes genes transactivation and expression caused by the degradation of HIF-1 result in depletion of intracellular adenosine triphosphate (ATP) pools in neutrophils and macrophages. ATP depletion produces disturbance of the inflammatory response of the neutrophils and macrophages due to decreased aggregation, motility, bacterial killing, and invasion.²⁵ Macrophages also show inability to phagocytose pathogenic organisms and apoptosed neutrophils (efferocytosis), which increases the number of apoptotic cells in diabetic ulcers and inhibits the switch from M1 macrophages to M2 macrophages phenotype. M1 macrophages generate more pro-inflammatory cytokines, such as tumor necrosis factor (TNF)- α , interleukin (IL)-1, IL-6, as well as inducible nitric oxide synthase (iNOS).²⁶⁻²⁹ These pro-inflammatory cytokines lead to the recruitment of more immune cells, resulting in wounds that remain in the inflammatory phase and fail to progress to the next phase.

Neutrophils in diabetes have an elevated neutrophil extracellular trap (NET) components, such as elastase, histones, neutrophil gelatinase-associated lipocalin, and proteinase-3. The neutrophils are primed to increased spontaneous NETosis, and have an impaired NADPH oxidase (NOX)-independent NETosis.³⁰ Increased NET components degrade important growth factors, such as platelet derived growth factor (PDGF) and transforming growth

factor (TGF)- β . The NET components also degrade and inactivate components of ECM, elevate matrix metalloproteinases (MMPs), and reduce tissue inhibitor of metalloproteinases (TIMPs).²⁶⁻³⁰ The imbalance between MMPs and TIMPs augments degradation of ECM. The ECM breakdown products promote inflammation further and create a self-sustaining process.¹⁹⁻³¹ The DFUs could not progress through the inflammation phase.

Extracellular matrix, including collagen, is mainly produced by fibroblasts. Hyperglycemia alters the diabetic fibroblasts phenotype. The fibroblasts show decreased collagen synthesis ability and low mitogenic capacity,³² migrate less,^{33,34} resistant to growth factors such as insulin-like growth factor (IGF)-1 and epidermal growth factor (EGF),^{35,36} and decreased ability to express VEGF in response to insulin and hypoxia.^{14,37} The decrease in collagen synthesis ability is compounded by prolonged hypoxia. Prolonged hypoxia, is a result of persistent inflammation in diabetic wound.²⁴ Since oxygen is reduced in hypoxia and the oxygen is needed as a substrate in the hydroxylation of proline and lysine residues of procollagen, then the synthesis and deposition of collagen are also reduced.³⁸ Degradation of ECM and TGF- β 1, caused by persistent inflammation in diabetic wound, also impair collagen synthesis.^{19,31,32} As a result, fibroblasts are unable to make progress in depositing ECM because degradation of collagen occurs more rapidly than its synthesis. Diabetic fibroblasts transdifferentiation to myofibroblasts is also impaired. TNF- α , secreted by granulocytes, suppresses expression of α -smooth muscle actin (α -SMA) in diabetic fibroblasts.^{32,39} Failure of diabetic fibroblasts to deposit optimal ECM and to differentiate into myofibroblasts halt the healing of DFUs.

Endothelial cells (ECs) in diabetic ulcers also become dysfunctional

and susceptible to apoptosis.⁴⁰ HIF-1 degradation leads to impaired VEGF and angiopoietins (Ang) genes transactivation in ECs. VEGF and Ang are the main molecular regulators of angiogenesis.^{15,40} VEGF is deficit in diabetic ulcers. Deficit in VEGF affects wound angiogenesis. ECs become less mitogenic and endothelial progenitor cells (EPCs) migrate less from the bone marrow.⁴¹ The EPCs' capacity to produce angiogenic sprouts and tubes is reduced in diabetes and it affects the baseline vascularity, capillary growth, and granulation tissue formation in diabetic wound.⁴⁰ Angiopoietins consist of Ang1 and Ang2. In diabetic wounds the ratio of Ang1 to Ang2 is decreased. The decreased ratio of Ang1 to Ang2 implies that the ability of diabetic wound vasculature to progress to a mature phenotype is disturbed.^{15,40} This disturbance in vascular maturity progression is understandable because Ang1 promotes ECs survival and vascular maturation, stabilizes endothelial interactions with supporting cells and limits the vascular permeability.¹⁵ On the contrary, Ang2 has been reported to induce ECs migration and proliferation and the sprouting of new blood vessels in conjunction with VEGF, whereas in the absence of VEGF, it induces ECs apoptosis and vessel regression.^{15,40} Wound angiogenesis impairment in DFUs is enhanced by M2 macrophages deficit, fibroblasts dysfunction to express VEGF, PDGF degradation, and perturbation of microRNAs (miRNAs) (e.g. miR26-b, miR-200b, and miR27-b).^{37,40} As angiogenesis is impaired, the wound healing process will be delayed and become chronic.

Keratinocytes form the outer layer of the skin. Oxidative stress, induced by high glucose, contributes to elevated epidermal growth factor receptor (EGFR) expression that subsequently resulted in enhanced extracellular signal-regulated kinase (ERK) signaling and increased IL-8 production in epidermal keratinocytes. Higher level of IL-8 is responsible for

recruiting and activating neutrophils. Excessive neutrophil infiltration contributed to the impaired wound healing.⁴² Keratinocytes in DFUs also showed impairment in proliferation, migration, and differentiation, apoptosis, defective expression of receptors for TGF- β , and poor response to growth factors. These changes in keratinocytes phenotype account for hampered re-epithelialization and wound closure.^{32,43}

Pathologic mechanisms in DFU

All of the pathologic response and cellular dysfunctions in diabetic patients stem from overproduction of ROS by the mitochondrial electron-transport chain. Hyperglycemia increases mitochondrial production of ROS through inducing intracellular high glucose and activating nicotinamide adenine dinucleotide phosphate (NAD(P)H) oxidase by interaction of angiotensin II with angiotensin II receptor subtype 1 (AT₁) in target cells.^{22,44,45} The ROS causes breaks in nuclear DNA strand, which then activates poly(ADP-ribose) polymerase (PARP). PARP modifies and reduces glyceraldehyde-3-phosphate dehydrogenase (GAPDH) activity. Decreased GAPDH activity activates the pathologic mechanisms, i.e. increased flux of glucose and other sugars through the polyol pathway, increased intracellular formation of advanced glycation end product (AGE) precursor, increased expression of AGEs receptor and its activating ligands, activation of protein kinase C (PKC) isoforms, and increased hexosamine pathway activity.^{22,44}

Increased polyol pathway flux results in diminished amount of reduced glutathione (GSH), a pivotal intracellular antioxidant. Diminished amount of GSH increases susceptibility of cells to intracellular oxidative stress, which then can damage the cells.^{22,44}

Increased intracellular AGE

precursors causes intracellular proteins modification and alters the function of the proteins, especially proteins involved in the regulation of gene transcription. Intracellular AGE precursors can diffuse out of the cell and modify extracellular matrix molecules. This modification then changes the signaling between the matrix and the matrix receptors (integrins) on the surface of cells and causes cellular dysfunctions. Extracellular AGE precursors can modify plasma proteins (such as albumin) too. Binding of these modified plasma proteins to AGE receptors on cells will activate the cells, causing the production of inflammatory cytokines and growth factors and its subsequent pathological changes, such as inhibition of HIF-1 α stability, endothelial dysfunction, decreased ability of macrophages to phagocytose apoptosed neutrophils, and functional sensory deficits.^{22,29,44}

Increased AGEs receptor (RAGE) and activation by its ligands stimulate a host of proinflammatory events and promotes chronic inflammation. Such chronic inflammation plays a major role in the development of diabetic complications.^{22,46}

Activation of PKC isoforms changes a variety of gene expression. Decreased endothelial nitric oxide synthase (eNOS) and increased of endothelin-1, VEGF, TGF- β , and plasminogen activator inhibitor-1 (PAI-1) cause vascular pathology.^{22,44} Activated PKC δ also inhibits stimulation of angiogenesis and granulation tissue formation by fibroblasts.³⁷ Moreover, activated PKC plays a role in increasing nuclear factor κ B (NF- κ B), a transcription factor that activates many pro-inflammatory genes, and NAD(P)H oxidases, which generates more ROS.^{22,44}

Increased hexosamine pathway activity generates uridine diphosphate (UDP) *N*-acetyl glucosamine. Specific *O*-linked *N*-acetylglucosamine (*O*-GlcNac) transferases use *N*-acetyl glucosamine

for posttranslational modification of specific serine and threonine residues of transcription factors. Overmodification by this glucosamine results in pathologic changes in gene expression. For example, increased modification of the transcription factor Sp1 results in increased expression of TGF- β 1 and PAI-1, which are bad for diabetic blood vessels.^{22,44}

In addition to the pathologic changes above, overproduction of ROS induced by hyperglycemia can drive persistent epigenetic changes, imposing a continued activation of the NF- κ B-p65 and downstream inflammatory promoters. Diabetic individuals will have to afford a continuous deregulation of the inflammatory homeostasis and superoxide metabolism pathways.⁴⁷ This “systemic inflammation” disrupts the insulin receptor-mediated anabolism via NF- κ B and c-Jun N-terminal kinases systems pathways activation. Epigenetic changes contribute to the formation of diabetic complications, including impaired diabetic wound healing.⁴⁸

Formation of biofilms by the bacterial communities is another factor which leads to the chronicity of DFU.¹⁰ The communities of bacteria in the biofilms secrete a matrix or glycocalyx, which is protective against the host immune response and eradication. Continuously present bacteria cause inflammation, which leads to the release of proteases and ROS from the inflammatory cells. These inflammatory cells’ products, together with the exotoxins and proteases secreted by the bacteria degrade proteins that are essential for healing.^{10,14}

After discussing the interconnected factors and the complexity of the pathogenesis of DFUs, it is understandable that the DFU’s management is still a challenge. Ideally, all the factors in the pathogenesis must be well managed to obtain a good result. Hereafter, initial evaluation, classification, and recent management of DFUs will be discussed.

Risk factors for a diabetic patient to develop foot ulcer and for the ulcer to become chronic and the pathologic mechanisms caused by hyperglycemia should be kept in consideration while evaluating and treating the DFUs.

Initial evaluation for DFU patients

A thorough evaluation of ulcer characteristics should be done initially. Plantar surfaces and sites of repetitive trauma and increased pressure should not be overlooked because they are the most common site of DFUs.^{10,14} Clinicians should evaluate the depth, size, and border of the ulcer. The ulcer may be associated with callus, foot deformity, or limited joint mobility; pink, warm, and dry skin; signs of skin fissures and breakdown; and distal anesthesia or paraesthesia.¹⁴ As well as the characteristics of the ulcer, clinicians should remember to evaluate a DFU patient as a whole. The metabolic status, the presence of neuropathy and vascular insufficiency on the affected foot or limb, foot deformities (e.g. claw toes, hammer toes), and the presence of infection in the ulcer should be assessed too because those are the risk factors for chronic nonhealing DFU.¹² Poor clinical outcomes are generally associated with PAD, deepening of the wound, and presence of infection in the ulcer.¹⁰ Early detection of risk factors and appropriate treatments of patients with poor ulcer healing may prevent up to 85% of amputations.⁴⁹

Symptoms of neuropathy, such as tingling or pain in the lower limb, especially at night, should be asked. Sensory foot examination to detect neuropathy should be done. Pressure perception can be assessed by using the 10-g Semmes-Weinstein monofilament; vibration perception by applying tuning fork (128 Hz) on a bony part on the dorsum of distal phalanx of the first toe; discrimination by pin prick test on dorsum of foot, without penetrating the

skin; tactile sensation by applying cotton wisp on dorsum of foot; and reflexes by assessing Achilles tendon reflexes.^{50,51}

Evaluating the presence of vascular insufficiency can be conducted through a range of non-invasive vascular tests. These include ankle-brachial index (ABI), toe-brachial index, toe systolic blood pressure, transcutaneous oxygen pressure (TcPO₂), ankle peak systolic velocity, hyperspectral imaging, microvascular oxygen saturation, and skin perfusion pressure.^{2,14,49} A systematic review and meta-analysis of those tests had found that most of the available evidence evaluated only TcPO₂ and ABI. TcPO₂ was more reliable to predict wound healing and limb amputation than ABI, but further research was needed to provide higher effectiveness evidence.⁴⁹ When non-invasive diagnostic is indicated to decide the needed treatment of the arterial lesions, vascular imaging may be helpful. The vascular imaging tests include duplex ultrasonography, computed tomography angiography (CTA), magnetic resonance angiography (MRA), and digital subtraction angiography (DSA).^{2,14} Choice of imaging method is influenced by the presence of renal insufficiency in the patients, because contrast media are nephrotoxic agents.²

The presence and severity of ulcer's infection and the wound depth (involvement of the bone) should be defined at initial evaluation too.^{10,12} Infection is present if there are at least two local findings of inflammation. The signs of inflammation are redness (erythema or rubor), warmth (color), pain or tenderness (dolor), induration (swelling or tumor) and purulent secretions. When inflammatory signs are diminished because of peripheral neuropathy or ischemia, other features (sometimes called secondary) suggestive of infection may be helpful. Those secondary features include the presence of necrosis, friable or discolored granulation tissue, non-

purulent secretion, foetid odor or the failure of a properly treated wound to heal.¹² Vital signs and appropriate blood tests examinations (i.e. erythrocyte sedimentation rate, blood leukocyte count, C-reactive protein, and procalcitonin), wound debridement, probing and assessing the depth and extent of the ulcer are necessary to evaluate the severity of the infection and to diagnose osteomyelitis.^{12,14} Plain radiography, magnetic resonance imaging (MRI), white blood cell-labelled radionuclide scan, combined single-photon emission computed tomography and computed tomography (SPECT/CT) or fluorine-18-fluorodeoxyglucose positron emission tomography (PET) scans, may be useful to improve the diagnostic accuracy of osteomyelitis.^{2,12} However, the criterion standard for diagnosing osteomyelitis remains a culture of the bone and, when possible, histopathological examination.^{12,52}

Properly obtained deep tissue specimens for Gram stain and culture, to determine the causative microorganisms and their antibiotic sensitivity, are advised in initial evaluation of patients with infected DFU prior to starting empirical antibiotic therapy.^{2,12} Mild (superficial and limited) infection is usually caused by aerobic Gram-positive cocci, especially *Staphylococcus aureus*. Chronic infections and more severe infections are often polymicrobial with aerobic Gram-negative rods and anaerobes.^{2,10,50,52} In the past decade, molecular techniques provide powerful means to define chronic wound microbial communities.¹⁰

Classification systems for DFUs

After the initial evaluation, clinicians should classify the DFU. Proper classification of the DFU is very important in predicting the need for hospitalization or lower extremity amputation and in planning strategies for treatment of diabetic foot lesions.^{10,12}

Various classification systems have been proposed to assess the severity of diabetic foot lesion, including PEDIS (perfusion, extent/size, depth/tissue loss, infection, sensation), UTSA (University of Texas Antonio), Wagner–Meggit, Brodsky Depth–Ischemic, and Saint Elian.^{10,53,54} No system has accepted unequivocal. In line with the risk factors that cause poor clinical outcomes, there are three classification systems that incorporate ischemia, wound depth, and infection into their assessment criteria. The three classification systems will be discussed below.

The PEDIS system was originally developed by the International Working Group on the Diabetic Foot (IWGDF) for research purposes. The aims of the classification system are to facilitate communication and enable the comparison of the results of different research projects.⁵³ However, it can serve

as a clinical classification as well. In PEDIS system, perfusion in the affected foot, extent/size of the ulcer, depth/tissue loss of the ulcer, symptoms and signs of infection, and sensation on the affected foot are graded. The higher grade shows the more severe of the ulcer. This classification has been shown in several prospective studies to predict the need for hospitalization or lower extremity amputation.¹²

The University of Texas Antonio classification system (UTSA) is now widely used in various clinical trials and diabetic centers (Table 1). In this system grading, the basis of depth of the lesion and stages are classified on presence of ischemia, wound bioburden or combination of both. There are grades (0–3) and stages (A–D). Wounds of higher grade or stages are more prone to a lower extremity amputation.¹⁰

TABLE 1. University of Texas classification system to assess the severity of diabetic foot lesion.¹⁰

Stages	Grades			
	0	1	2	3
A	Healed pre or post ulcerative lesion completely epithelialized	Superficial wound not involving bone, tendon or capsule	Wound penetrating tendon and capsule	Wound penetrating to bone or joint
B	With infection	With infection	With infection	With infection
C	With ischemia	With ischemia	With ischemia	With ischemia
D	With infection and with ischemia	With infection and with ischemia	With infection and with ischemia	With infection and with ischemia

In response to the increasing number of diabetic patients with critical limb ischemia, the Society for Vascular Surgery proposed a new classification scheme that combines the classification schemes based on PAD perfusion patterns with foot ulcer schemes. The new classification system is titled WIfI (wound, ischemia, and foot infection). A separate grade is given to the wound (the presence and depth of ulcer), ischemia (based on ABI, toe pressure,

or transcutaneous oxygen pressure (TcPO₂), and infection (local to systemic). The three grades are combined to give a risk of amputation and estimated benefit of revascularization. WIfI is robust to account for several factors in PAD but it has not validated in many research studies.⁵⁴

Management for DFU

Diabetic foot ulcer is a difficult to heal ulcer. The pathogenesis of DFU

and the results of the initial evaluation of the patient should be considered in planning of the management strategies. Peripheral neuropathy, foot deformity, PAD, frequent minor trauma, and infection need to be well managed. Glycemic control must be achieved, and standard wound care must be delivered to the patients. Standard wound care includes local debridement, wound offloading, wound moisture balance with appropriate dressings, control of edema, and control of infection. Education about preventive foot care should be given to the patients and their families.^{1,55}

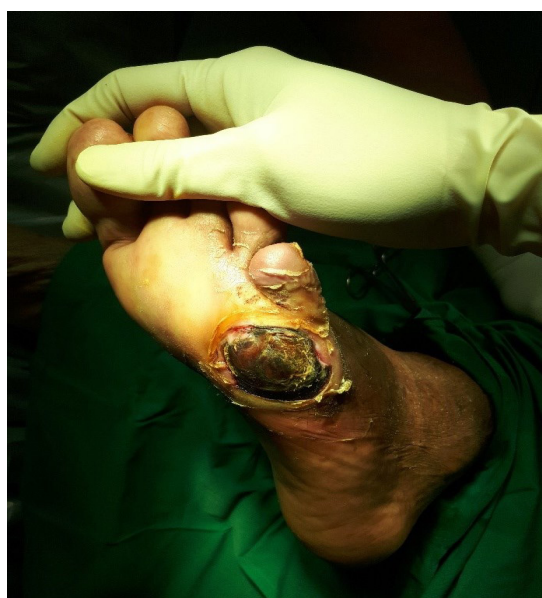
A multidisciplinary team, consist of individuals who have the skills (medical, surgical, podiatric, nursing, and orthotic), should be involved in DFUs management. This multidisciplinary team has been successfully implemented in different centers from various countries, resulting in a substantial decrease in amputation rate.^{2,50}

Glycemic control

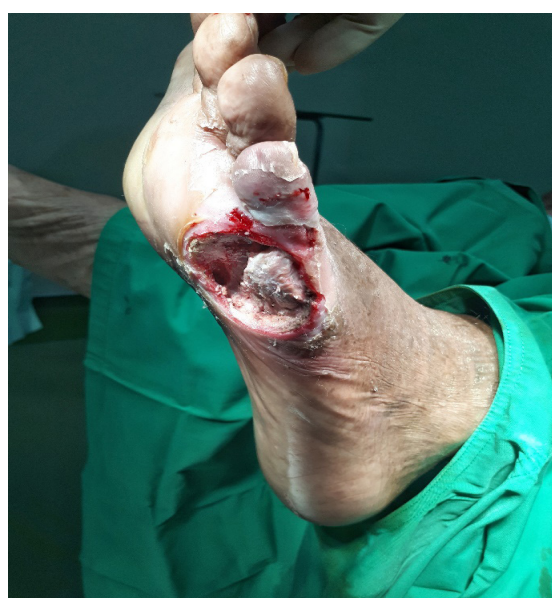Glycemic control, as reflected by hemoglobin A_{1c} (HbA_{1c}) measurement, is a must for DFU patients. HbA_{1c} is inversely related to healing rate, particularly in patients with peripheral neuropathy and PAD.⁵⁶ Early tight control of blood glucose is targeted. The recommended adequate glycemic control is HbA_{1c} < 7%.⁵⁵

Local debridement

Removal of necrotic tissues as well as foreign and infected objects from an ulcer by debridement is the first critical step in the wound care, especially in the control of deep infection.^{2,52} Debridement can decrease bacterial counts, facilitate wound drainage, and reduce pressure on the ulcer. Evaluation of the wound bed and wound closure are facilitated by debridement (FIGURE 1). Adequate debridement decreases the possibility of limb amputation.⁵⁷



A



B

FIGURE 1. Necrotic tissue covers a diabetic foot ulcer on the plantar pedis before debridement (A). A deep ulcer penetrating to the bone and joint is visible after debridement (B) (photographs courtesy of dr. Daniel Ardian Soeselo, Sp.B)

There are several techniques of debridement including surgical or sharp, mechanical, enzymatic, biological, and autolytic.^{2,57} Two systematic reviews and a literature review discussing debridement methods had been published recently.^{11,57,58} They found that available literature supported putative benefits of surgical and biological debridement. However, the quality of comparative effectiveness evidence between the debridement methods was low. Consequently, the need for and choice of technique of debridement are based on the available expertise and supplies, patient tolerance and preference, the clinical context (such as level of perfusion and extent of tissue loss), and cost-effectiveness.^{55,57,58} It should be remembered that the aim of debridement is not only to achieve wound closure, but also to maintain ambulation. In situations without a limb-threatening infection, surgical debridement should be done after the blood supply to the wound/extremity is optimized, to ensure that viable tissue is not removed.² If new necrotic tissue continues to form, repeated surgical debridement should be conducted.⁵⁷

Offloading

Offloading, or pressure modulation, is the cornerstone management for neuropathic DFUs and ulcers with increased biomechanical stress.^{50,57} The aim of offloading is to treat the foot ulcer and to maintain the ability of the patient to walk. A threshold of a peak pressure < 200 KPa has to be achieved by the offloading system to allow the ulcer to heal.²

There are many offloading modalities nowadays, divided into non-surgical and surgical. The non-surgical offloading modalities include soft and shock absorbing materials, custom molding, forefoot or heel offloading shoes, rocker-bottom shoes, casts,

walkers, crutches, and wheelchair. The example of surgical modalities is Achilles Tendon-Lengthening (ATL), which is performed to reduce plantar pressure because of foot deformities.^{2,50} Patient physical characteristics and compliance in conjunction with the location and severity of the ulcer determine the choice of the modalities.⁵⁷ Total contact casting and irremovable cast walkers show benefits in the treatment of DFUs, although based on low-quality evidence.⁵⁹ Another literature review assign grade A recommendation to offloading and grade B recommendation to ATL.⁶⁰ A removable cast walker is suggested as an alternative for patients who need frequent dressing changes.⁵⁵ Specific therapeutic footwear with pressure-relieving insoles is recommended for high-risk patients with healed DFU to reduce relapse.^{55,59}

Wound dressing

Dressing that provides moisture balance of the wound, sequesters protease, stimulates growth factor stimulation, has an antimicrobial activity, permeable for oxygen to pass through the wound, and promotes autolytic debridement is the ideal dressing for DFU. Nowadays there is no single dressing which can fulfill all those requirements.⁵⁷ Dressing that maintains a moist wound bed, controls exudate, and avoids maceration of the intact skin surrounding the wound is recommended for DFU.⁵⁵

Films, hydrogels, hydrocolloids, alginates, foams, and silver-impregnated are novel dressings used over the last decade for DFUs.^{57,61} Cause of the DFU, the location and depth of the wound, the amount of scar or slough, exudates, and condition of the wound boundaries, the presence of infection and pain, requirement for adhesiveness, and conformability of the dressing should determine the selection of the dressing.⁵⁷ However, a significant advantage of a

certain wound dressing in the healing rate of DFUs can not be concluded based on existing data as yet.^{57,61} Simple gauze and saline solution alone still appears to be sufficient for most patients.⁵²

Treatment of peripheral edema

Peripheral edema on the foot/leg of DFU patients should be evaluated. There are several factors that can cause the edema, such as congestive heart failure, nephropathy, infection and hydrostatic/neuropathic edema. External compression therapy, intermittent compression pumps, and diuretics are examples of treatment for peripheral edema. However, the most important thing to note is that peripheral edema in DFU patients should be treated according to the causative factors.^{2,50}

Treatment of infection

Duration, extent and severity of infection and knowledge of the local microbial epidemiology dictate the empirical antibiotic regimen and mode of antibiotic administration.^{2,52} Patients with acute mild-to-moderate infections and have not received antibiotic therapy may be sufficient if treated with antibiotic against aerobic Gram-positive cocci. Broad spectrum empirical therapy is not routinely required for chronic ulcers with polymicrobial flora, but is indicated for moderate to severe infections. Empirical parenteral broad-spectrum antibiotic therapy aimed at Gram-positive and Gram-negative bacteria, including anaerobes, may be given for deep and limb-threatening infection. Definitive therapy should be based on culture results and susceptibility data and clinical response to the empirical regimen. Antibiotic therapy should be continued until the infection has been controlled but not necessarily until the wound has healed.^{2,12,50,52}

Infections accompanied by a

deep abscess, osteomyelitis, crepitus, substantial necrosis or gangrene, or necrotizing fasciitis need immediate surgical consultation. Urgent incision and drainage of an abscess and radical debridement of all infected, non-viable necrotic tissue are the most important steps in controlling deep infection. The debridement should be done first and in the case of ischemia, revascularization thereafter.^{2,12,52}

Surgery

Surgery for DFUs includes nonvascular foot surgery, vascular foot surgery, and amputation. Nonvascular foot surgery aims to correct foot deformities that increase pressure (offload), for example surgical excision of ulcers, arthroplasties, metatarsal head resections and ATL.^{2,57} Vascular foot surgery (revascularization) is indicated to relieve symptoms of limb-threatening ischemia. These symptoms include ischemic pain, ischemic ulcers, and gangrene. Achieving at least one open infrapopliteal artery, preferably the artery that supplies the anatomical region of the ulcer, is the goal of revascularization.² Amputation is the last resort of an urgent or curative surgery to be considered after all other salvage techniques has been attempted, and the patient must give informed consent.⁵⁷

Adjunctive therapies

Adjunctive wound therapy options are recommended for DFUs that fail to show >50% wound area reduction after a 4 weeks of standard wound therapy.⁵⁵ These adjunctive therapies include negative pressure wound therapy (NPWT), biologics (PDGF, living cellular therapy, extracellular matrix products, amniotic membrane products), and hyperbaric oxygen therapy (HBOT). A systematic review to study the effectiveness of interventions to enhance

healing of DFUs found that there is still little published evidence to justify the use of newer therapies, with the possible exception of NPWT in post-operative wounds.¹¹ Choice of adjuvant therapy is based on clinical findings, availability of therapy, and cost-effectiveness. Vascular status, infection control, and offloading is recommended to be optimized before initiation of adjunctive wound therapy.⁵⁵

Education

Educating diabetic patients and families on foot self-management is considered to be the basis of preventing DFUs and reducing the chance of recurrences. Up to 50% of DFUs can be prevented by effective education. Diabetic patients with/without DFUs should be educated about risk factors and the significance of foot care, including self-inspection, examining the temperature of the foot, appropriate daily foot hygiene maintenance, use of suitable footwear, and blood sugar control. Several education sessions over time, using a mixture of methods, should be provided. Whether the diabetic patient has understood the messages, is motivated to act, and has sufficient self-care skills are essential to evaluate.^{50,55,57}

CONCLUSION

The pathogenesis of DFU is very complex. Diabetic patients are vulnerable to develop foot ulcers due to peripheral neuropathy, foot deformity, minor foot trauma, and peripheral arterial disease. Derangements of neuropeptides, hypoxia, hyperglycemia, and infection contribute to the chronicity of DFUs.

The patient as a whole, the characteristics of the ulcer, the presence of neuropathy, the vascular insufficiency, and the presence of infection should be evaluated at initial evaluation of DFU patients. The ulcer then classified according to the classification system to

alert clinicians about the severity of the ulcer and the risk of amputation, so that a suitable management strategies can be set.

In the management of DFUs, blood sugar must be under control and standard wound care must be delivered to each patient. Standard wound care includes local wound debridement, wound offloading, wound moisture balance with appropriate dressings, control of edema, and control of infection. Blood supply to the wound/extremity should be adequate. Education about preventive foot care should be given to the patients and their families. A multidisciplinary team should be involved in DFUs management.

ACKNOWLEDGEMENTS

Authors would like to thank dr. Inneke Jane, Sp.KK. and Dr. dr. Soegianto Ali, M.Med.Sc. for the correction in English as well as dr. Daniel Ardian Soeselo, Sp.B. for providing the photos of DFUs.

REFERENCES

1. Alexiadou K, Doupis J. Management of diabetic foot ulcers. *Diabetes Ther* 2012; 3(1):4. <http://dx.doi.org/10.1007/s13300-012-0004-9>
2. Apelqvist J. Diagnostics and treatment of the diabetic foot. *Endocrine* 2012; 41(3):384-97. <http://dx.doi.org/10.1007/s12020-012-9619-x>
3. Zhang P, Lu J, Jing Y, Tang S, Zhu D, Bi Y. Global epidemiology of diabetic foot ulceration: a systematic review and meta-analysis. *Ann Med* 2017; 49(2):106-16. <http://dx.doi.org/10.1080/07853890.2016.1231932>
4. Bakker K, Apelqvist J, Lipsky BA, Van Netten JJ. The 2015 IWGDF Guidance documents on prevention and management of foot problems in diabetes: development of an evidence-based global consensus.

- Diabetes Metab Res Rev 2016; 32(Suppl 1):2-6.
<http://dx.doi.org/10.1002/dmrr.2694>
5. Wild S, Roglic G, Green A, Sicree R, King H. Global prevalence of diabetes: estimates for the year 2000 and projections for 2030. *Diabetes Care* 2004; 27(5):1047-53.
<http://dx.doi.org/10.2337/diacare.27.5.1047>
 6. Boulton AJ, Vileikyte L, Ragnarson-Tennvall G, Apelqvist J. The global burden of diabetic foot disease. *Lancet* 2005; 366(9498):1719-24.
[http://dx.doi.org/10.1016/S0140-6736\(05\)67698-2](http://dx.doi.org/10.1016/S0140-6736(05)67698-2)
 7. Kementerian Kesehatan RI. Situasi dan Analisis Diabetes. 2014. [Cited 2015 August 6]. <http://www.depkes.go.id/download.php?file=download/pusdatin / infodatin / infodatin-diabetes.pdf>.
 8. Armstrong DG, Boulton AJM, Bus SA. Diabetic foot ulcers and their recurrence. *N Engl J Med* 2017; 376(24):2367-75.
<http://dx.doi.org/10.1056/NEJMra1615439>
 9. Shin JY, Roh SG, Sharaf B, Lee NH. Risk of major limb amputation in diabetic foot ulcer and accompanying disease: a meta-analysis. *J Plast Reconstr Aesthet Surg* 2017; 70(12):1681-8.
<http://dx.doi.org/10.1016/j.bjps.2017.07.015>
 10. Noor S, Zubair M, Ahmad J. Diabetic foot ulcer--A review on pathophysiology, classification and microbial etiology. *Diabetes Metab Syndr* 2015; 9(3):192-9.
<http://dx.doi.org/10.1016/j.dsx.2015.04.007>
 11. Game FL, Apelqvist J, Attinger C, et al. Effectiveness of interventions to enhance healing of chronic ulcers of the foot in diabetes: a systematic review. *Diabetes Metab Res Rev* 2016;32(Suppl. 1):154-68.
<http://dx.doi.org/10.1002/dmrr.2707>
 12. Lipsky BA, Aragón-Sánchez J, Diggle M, Embil J, Kono S, Lavery L, et al. IWGDF guidance on the diagnosis and management of foot infections in persons with diabetes. *Diabetes Metab Res Rev* 2016; 32(Suppl. 1):45-74.
<http://dx.doi.org/10.1002/dmrr.2699>
 13. Tesfaye S, Boulton AJ, Dyck PJ, Freeman R, Horowitz M, Kempner P, et al. Diabetic neuropathies: update on definitions, diagnostic criteria, estimation of severity, and treatments. *Diabetes Care* 2010; 33(10):2285-93.
<http://dx.doi.org/10.2337/dc10-1303>
 14. Morton LM, Phillips TJ. Wound healing and treating wounds Differential diagnosis and evaluation of chronic wounds. *J Am Acad Dermatol* 2016; 74(4):589-605.
<http://dx.doi.org/10.1016/j.jaad.2015.08.068>
 15. Isidori AM, Venneri MA, Fiore D. Angiopoietin-1 and Angiopoietin-2 in metabolic disorders: therapeutic strategies to restore the highs and lows of angiogenesis in diabetes. *J Endocrinol Invest* 2016; 39(11):1235-46.
<http://dx.doi.org/10.1007/s40618-016-0502-0>
 16. Sen CK, Roy S. Wound Healing. In: Neligan PC, ed. *Plastic surgery*, 3rd ed. Elsevier Inc. 2013:240-66.e5.
 17. Mirastschijski U, Jokuszies A, Vogt PM. Skin wound healing: repair biology, wound, and scar treatment. In: Neligan PC, ed. *Plastic surgery*, 3rd ed. Elsevier Inc. 2013:267-96.e8.
 18. Brem H, Tomic-Canic M. Cellular and molecular basis of wound healing in diabetes. *J Clin Invest* 2007; 117(5):1219-22.
<http://dx.doi.org/10.1172/JCI32169>
 19. Zhao R, Liang H, Clarke E, Jackson C, Xue M. Inflammation in chronic wounds. *Int J Mol Sci* 2016; 17(12):2085.
<http://dx.doi.org/10.3390/ijms17122085>
 20. Catrina SB, Okamoto K, Pereira T, Brismar K, Poellinger L. Hyperglycemia regulates hypoxia-inducible factor-1 α protein stability and function. *Diabetes* 2004; 53(12):3226-32.
<http://dx.doi.org/10.2337/diabetes.53.12.3226>
 21. Pradhan L, Nabzdyk C, Andersen ND, LoGerfo FW, Veves A. Inflammation and neuropeptides: the connection in diabetic wound healing. *Expert*

- Rev Mol Med 2009; 11:e2.
<http://dx.doi.org/10.1017/S1462399409000945>
22. Giacco F, Brownlee M. Oxidative stress and diabetic complications. *Circ Res* 2010; 107(9):1058-70.
<http://dx.doi.org/10.1161/CIRCRESAHA.110.223545>.
 23. Xiao H, Gu Z, Wang G, Zhao T. The possible mechanisms underlying the impairment of HIF-1 α pathway signaling in hyperglycemia and the beneficial effects of certain therapies. *Int J Med Sci* 2013; 10(10):1412-21.
<http://dx.doi.org/10.7150/ijms.5630>
 24. Strehl C, Fangradt M, Fearon U, Gaber T, Buttgerleit F, Veale DJ. Hypoxia: how does the monocyte-macrophage system respond to changes in oxygen availability? *J Leukoc Biol* 2014; 95(2):233-41.
<http://dx.doi.org/10.1189/jlb.1212627>
 25. Egners A, Erdem M, Cramer T. The response of macrophages and neutrophils to hypoxia in the context of cancer and other inflammatory diseases. *Mediators Inflamm* 2016; 2016:2053646.
<http://dx.doi.org/10.1155/2016/2053646>
 26. Novak ML, Koh TJ. Phenotypic transitions of macrophages orchestrate tissue repair. *Am J Pathol* 2013; 183(5):1352-63.
<http://dx.doi.org/10.1016/j.ajpath.2013.06.034>
 27. Khanna S, Biswas S, Shang Y, Collard E, Azad A, Kauh C, et al. Macrophage dysfunction impairs resolution of inflammation in the wounds of diabetic mice. *PLoS One* 2010; 5(3):e9539.
<http://dx.doi.org/10.1371/journal.pone.0009539>
 28. Wicks K, Torbica T, Mace KA. Myeloid cell dysfunction and the pathogenesis of the diabetic chronic wound. *Semin Immunol* 2014; 26(4):341-53.
<http://dx.doi.org/10.1016/j.smim.2014.04.006>
 29. Sahin KB, Hesketh M, West ZE, Murray RZ. Altered macrophage phenotypes impair wound healing. *Wound Pract Res* 2017; 25(4):166-71.
 30. Fadini GP, Menegazzo L, Rigato M, Scattolini V, Poncina N, Bruttocao A, et al. NETosis delays diabetic wound healing in mice and humans. *Diabetes* 2016; 65(4):1061-71.
<http://dx.doi.org/10.2337/db15-0863>
 31. Menke NB, Ward KR, Witten TM, Bonchev DG, Diegelmann RF. Impaired wound healing. *Clin Dermatol* 2007; 25(1):19-25.
<http://dx.doi.org/10.1016/j.clindermatol.2006.12.005>
 32. Berlanga-Acosta J, Schultz GS, López-Mola E, Guillen-Nieto G, García-Siverio M, Herrera-Martínez L. Glucose toxic effects on granulation tissue productive cells: the diabetics' impaired healing. *Biomed Res Int* 2013; 2013:256043.
<http://dx.doi.org/10.1155/2013/256043>
 33. Lamers ML, Almeida ME, Vicente-Manzanares M, Horwitz AF, Santos MF. High glucose-mediated oxidative stress impairs cell migration. *PLoS One* 2011; 6(8):e22865.
<http://dx.doi.org/10.1371/journal.pone.0022865>
 34. Xuan YH, Huang BB, Tian HS, Chi LS, Duan YM, Wang, et al. High-glucose inhibits human fibroblast cell migration in wound healing via repression of bFGF-regulating JNK phosphorylation. *PLoS One* 2014; 9(9):e108182.
<http://dx.doi.org/10.1371/journal.pone.0108182>
 35. Hehenberger K, Hansson A. High glucose-induced growth factor resistance in human fibroblasts can be reversed by antioxidants and protein kinase C-inhibitors. *Cell Biochem Funct* 1997; 15(3):197-201.
[http://dx.doi.org/10.1002/\(SICI\)1099-0844\(199709\)15:3<197::AID-CBF740>3.0.CO;2-7](http://dx.doi.org/10.1002/(SICI)1099-0844(199709)15:3<197::AID-CBF740>3.0.CO;2-7)
 36. Bitar MS, Al-Mulla F. ROS constitute a convergence nexus in the development of IGF1 resistance and impaired wound healing in a rat model of type 2 diabetes. *Dis Model Mech* 2012; 5(3):375-88.
<http://dx.doi.org/10.1242/dmm.007872>
 37. Khamaisi M, Katagiri S, Keenan H,

- Park K, Maeda Y, Li Q, et al. PKC δ inhibition normalizes the wound-healing capacity of diabetic human fibroblasts. *J Clin Invest* 2016; 126(3):837-53.
<http://dx.doi.org/10.1172/JCI82788>
38. Harper D, Young A, McNaught C-E. The physiology of wound healing. *Surgery* 2014; 32(9):445-50.
 39. Goldberg MT, Han YP, Yan C, Shaw MC, Garner WL. TNF- α suppresses α -smooth muscle actin expression in human dermal fibroblasts: an implication for abnormal wound healing. *J Invest Dermatol* 2007; 127(11):2645-55.
<http://dx.doi.org/10.1038/sj.jid.5700890>
 40. Okonkwo UA, Dipietro LA. Diabetes and wound angiogenesis. *Int J Mol Sci* 2017; 18(7):1419.
<http://dx.doi.org/10.3390/ijms18071419>
 41. Kota SK, Meher LK, Jammula S, Kota SK, Krishna SV, Modi KD. Aberrant angiogenesis: the gateway to diabetic complications. *Indian J Endocrinol Metab* 2012; 16(6):918-30.
<http://dx.doi.org/10.4103/2230-8210.102992>
 42. Lan CC, Wu CS, Huang SM, Wu IH, Chen GS. High-glucose environment enhanced oxidative stress and increased Interleukin-8 secretion from keratinocytes: new insights into impaired diabetic wound healing. *Diabetes* 2013; 62(7):2530-8.
<http://dx.doi.org/10.2337/db12-1714>
 43. Kruse CR, Singh M, Sørensen JA, Eriksson E, Nuutila K. The effect of local hyperglycemia on skin cells in vitro and on wound healing in euglycemic rats. *J Surg Res* 2016; 206(2):418-26.
<http://dx.doi.org/10.1016/j.jss.2016.08.060>
 44. Brownlee M. The pathobiology of diabetic complications: a unifying mechanism. *Diabetes* 2005; 54(6):1615-25.
<http://dx.doi.org/10.2337/diabetes.54.6.1615>
 45. Skov J, Persson F, Frøkiær J, Christiansen JS. Tissue renin-angiotensin systems: a unifying hypothesis of metabolic disease. *Front Endocrinol (Lausanne)* 2014; 5:23.
<http://dx.doi.org/10.3389/fendo.2014.00023>
 46. Yao D, Brownlee M. Hyperglycemia-induced reactive oxygen species increase expression of the receptor for advanced glycation end products (RAGE) and RAGE ligands. *Diabetes* 2010; 59(1):249-55.
<http://dx.doi.org/10.2337/db09-0801>
 47. Berlanga-Acosta J, Fernández-Montequín J, Valdés-Pérez C, Savigne-Gutiérrez W, Mendoza-Marí Y, García-Ojalvo A, et al. Diabetic foot ulcers and epidermal growth factor: revisiting the local delivery route for a successful outcome. *Biomed Res Int* 2017; 2017:2923759.
<http://dx.doi.org/10.1155/2017/2923759>
 48. Rafehi H, El-osta A, Karagiannis TC. Epigenetic mechanisms in the pathogenesis of diabetic foot ulcers. *J Diabetes Complications* 2012; 26(6):554-61.
<http://dx.doi.org/10.1016/j.jdiacomp.2012.05.015>
 49. Wang Z, Hasan R, Firwana B, Elraiyah T, Tsapas A, Prokop L. A systematic review and meta-analysis of tests to predict wound healing in diabetic foot. *J Vasc Surg* 2016; 63(2 Suppl):29S-36S.
<http://dx.doi.org/10.1016/j.jvs.2015.10.004>
 50. Bakker K, Apelqvist J, Schaper NC. Practical guidelines on the management and prevention of the diabetic foot 2011. *Diabetes Metab Res Rev* 2012; 28(Suppl 1):225-31.
<http://dx.doi.org/10.1002/dmrr.2253>
 51. Bus SA, van Netten JJ, Lavery LA, Monteiro-Soares M, Rasmussen A, Jubiz Y, et al. IWGDF guidance on the prevention of foot ulcers in at-risk patients with diabetes. *Diabetes Metab Res Rev* 2016; 32(Suppl 1):16-24.
<http://dx.doi.org/10.1002/dmrr.2696>
 52. Uçkay I, Aragón-Sánchez J, Lew D, Lipsky BA. Diabetic foot infections: what have we learned in the last 30 years? *Int J Infect Dis* 2015; 40:81-91.

- <http://dx.doi.org/10.1016/j.ijid.2015.09.023>
53. Schaper NC. Diabetic foot ulcer classification system for research purposes: a progress report on criteria for including patients in research studies. *Diabetes Metab Res Rev* 2004; 20(Suppl 1):S90-5.
<http://dx.doi.org/10.1002/dmrr.464>
54. Hardman RL, Jazaeri O, Yi J, Smith M, Gupta R. Overview of classification systems in peripheral artery disease. *Semin Intervent Radiol* 2014; 31(4):378-88.
<http://dx.doi.org/10.1055/s-0034-1393976>
55. Hingorani A, LaMuraglia GM, Henke P, Meissner MH, Loretz L, Zinszer KM, et al. The management of diabetic foot: a clinical practice guideline by the Society for Vascular Surgery in collaboration with the American Podiatric Medical Association and the Society for Vascular Medicine. *J Vasc Surg* 2016; 63(2 Suppl):3S-21S.
<http://dx.doi.org/10.1016/j.jvs.2015.10.003>
56. Christman AL, Selvin E, Margolis DJ, Lazarus GS, Garza LA. Hemoglobin A1c predicts healing rate in diabetic wounds. *J Invest Dermatol* 2011; 131(10):2121-7.
<http://dx.doi.org/10.1038/jid.2011.176>
57. Yazdanpanah L, Nasiri M, Adarvishi S. Literature review on the management of diabetic foot ulcer. *World J Diabetes* 2015; 6(1):37-53.
<http://dx.doi.org/10.4239/wjd.v6.i1.37>
58. Elraiyah T, Domecq JP, Prutsky G, Tsapas A, Nabhan M, Frykberg RG, et al. A systematic review and meta-analysis of débridement methods for chronic diabetic foot ulcers. *J Vasc Surg* 2016; 63(2 Suppl):37S-45S.e2.
<http://dx.doi.org/10.1016/j.jvs.2015.10.002>
59. Elraiyah T, Prutsky G, Domecq JP, Tsapas A, Nabhan M, Frykberg RG, et al. A systematic review and meta-analysis of off-loading methods for diabetic foot ulcers. *J Vasc Surg* 2016; 63(2 Suppl):59S-68S.e2.
<http://dx.doi.org/10.1016/j.jvs.2015.10.006>
60. Lefrancois T, Mehta K, Sullivan V, Lin S, Glazebrook M. Evidence based review of literature on detriments to healing of diabetic foot ulcers. *Foot Ankle Surg* 2017; 23(4):215-24.
<http://dx.doi.org/10.1016/j.fas.2016.04.002>
61. Klein S, Schreml S, Dolderer J, Gehmert S, Niederbichler A, Landthaler M, et al. Evidence-based topical management of chronic wounds according to the T.I.M.E. principle. *J Ger Soc Dermatology* 2013; 11(9):819-29.
<http://dx.doi.org/10.1111/ddg.12138>