



The effect of L-arginine therapy on hepatocyte cells damage in mice (*Mus musculus*) model of preeclampsia

Soetrisno*, Bambang Arinekso, Sri Sulistyowati

Department of Obstetrics and Gynecology, Faculty of Medicine, Sebelas Maret University/Dr. Moewardi General Hospital, Surakarta, Indonesia

ABSTRACT

Submitted: 2017-08-23

Accepted : 2019-09-22

Preeclampsia is one of the main contributors on morbidity and mortality of mother and fetus. Imbalance of body antioxidants and oxidants has a role on endothelial destruction causing endothelial dysfunction which leads to preeclampsia. L-arginine administration is indicated to be able to fix the remodelling process of hepatocytes which was damaged on preeclampsia. The aim of this study was to investigate the effect of L-arginine on hepatocyte cells damage on mouse (*Mus musculus*) model of preeclampsia. Experimental study was conducted in the Experimental Animal Warehouse and Biomedical Laboratory, Faculty of Veterinary Medicine, Airlangga University, Surabaya. A total of 30 pregnant mice were divided into three groups with 10 mice in each group i.e. normal, preeclampsia model and preeclampsia model with L-arginine therapy pregnant mice. Preparates were taken from dissected mice liver, with prior paraffin block and were then stained with hematoxylin-eosin. Results were analyzed semi quantitatively with Manja Roenigk hepar histology scoring method. Data were analyzed using Kruskal-Wallis and Man-Whitney test. Mean of hepar histopathology score of preeclampsia model with L-arginine therapy ($40.80 \pm 1.17/\mu\text{m}^2$) was significantly lower compared with preeclampsia model pregnant mice ($58.80 \pm 4.23/\mu\text{m}^2$) ($p < 0.05$), however it was significantly higher compared with normal pregnant mice ($18.40 \pm 2.41/\mu\text{m}^2$) ($p < 0.05$). It was indicated that the L-arginine therapy on preeclampsia mouse model can reduce the score of hepar histopathology. In conclusion, L-arginine administration can reduce the hepatocyte cells damage of mouse due to preeclampsia.

ABSTRAK

Preeklamsia merupakan salah satu contributor utama morbiditas dan mortalitas pada ibu dan janin. Ketidakseimbangan antioksidan dan oksidan tubuh berperan terjadinya kerusakan endotel yang menyebabkan disfungsi endotel dan terjadinya preeklamsia. Pemberian L-arginine diduga memperbaiki proses remodeling sel hepatosit hepar yang rusak pada preeklamsia. Penelitian ini bertujuan untuk mengkaji pengaruh pemberian L-arginine terhadap perbaikan kerusakan sel hepatosit hepar yang dinilai dari skor histopatologi hepar model mencit (*Mus musculus*) preeklamsia. Penelitian dilakukan di Kandang Hewan Percobaan dan Laboratorium Biomedik, Fakultas Kedokteran Hewan, Universitas Airlangga, Surabaya. Sebanyak 30 ekor mencit bunting dibagi dalam 3 kelompok dengan masing-masing kelompok 10 ekor yaitu kelompok mencit bunting normal, model preeklamsia dan model preeklamsia dengan terapi L-arginin. Pengambilan preparat dilakukan pada hepar mencit yang sebelumnya telah dibedah dan dilakukan blok parafin untuk kemudian diberi pewarna hematoxylin-eosin. Hasil dianalisis secara semi kuantitatif menurut metode skor histopatologi hepar Manja Roenigk. Analisa data menggunakan uji Kruskal-Wallis dan Man-Whitney. Rerata skor histopatologi hepar model mencit preeklamsia yang diterapi L-arginin ($40,80 \pm 1,17/\mu\text{m}^2$) lebih rendah secara nyata dibandingkan dengan model mencit preeklamsia ($58,80 \pm 4,23/\mu\text{m}^2$) ($p < 0,05$), namun demikian lebih tinggi secara nyata dibandingkan dengan tikus bunting normal ($18,40 \pm 2,41/\mu\text{m}^2$) ($p < 0,05$). Hal ini menunjukkan terapi L-arginin dapat menurunkan skor histopatologi hepar pada model mencit preeklamsia. Dapat disimpulkan, pemberian L-arginin dapat menurunkan kerusakan hepatosit mencit akibat preeklamsia.

Keywords:

L-arginine
hepatocyte cells
preeclampsia
mouse model
animal model

INTRODUCTION

Preeclampsia is a serious complication in pregnancy characterized by elevated blood pressure and proteinuria on the 20th week of pregnancy. Preeclampsia prevalence ranges from 5-8% from pregnancy population, but it increases to 10-15% in pregnancy with high risk.¹ Preeclampsia complication causes approximately 50.000 maternal death each year.² In Indonesia, 30-40% preeclampsia becomes the cause of maternal death and 30-50% becomes the cause of perinatal death. In Dr. Moewari Generah Hospital, Surakarta, Central Java maternal death caused by preeclampsia was 67.6% from 37 preeclampsia case from 1956 births in 2008.³

Endothelial dysfunction in preeclampsia increases blood vessels resistance, platelet aggregation, and coagulation system activation. These factors are related to abnormal placentation marked by cytotrophoblast dysfunction and inadequate spiral artery invasion on myometrium. This initiates vasoconstriction and hypoperfusion causing ischaemia and hypoxia on placenta.⁴

Preeclampsia is also linked to elevation of oxidative stress. Reactive oxygen type also known as reactive oxygen species (ROS) plays important role in this process. Reactive oxygen works as placenta cellular growth, differentiation, apoptosis, and also the out put of the pregnancy itself. Relative hypoxia on placenta is linked to inadequate uteroplacenta circulation. These factors will cause maternal endotel damage.⁵

Nowadays, experts propose a hypothesis of primer dysfunction of preeclampsia is caused by relative deficiency of available nitric oxide (NO), and oversaturation of peroxynitrite (ONOO). The combination of NO deficiency and elevated ONOO directly and indirectly initiate physiologic change and serologic change related

to preeclampsia, platelet dysfunction, thromboxane (TXA) elevation and endothelin also reduction of prostacyclin (PGI₂). NO is an endogen vasodilator synthesized from non essential amino acid L-arginine with mediation of nitric oxide synthase (NOS). Oxydative stress is opposed to be the key factor of the occurrence of preeclampsia, so that the administration of antioxidant on pregnant woman during pregnancy is expected to delay or prevent the onset of preeclampsia.⁶

Endothel dysfunction causing reduction of vasodilator molecule formation like NO is one of the vasoactive mediator of endothel. During pregnancy with preeclampsia, there is an increase on assymetric dimethyl arginine (ADMA) synthesis. ADMA is an endogen inhibitor of NOS, reducing NO synthesis. L-arginine is a NO precursor amino acid. Enzymatic pathway of L-arginine affects the formation of NOS. In patients with elevated ADMA, L-arginine compete with ADMA for NOS, so that the number of NO elevated.⁷

Mice were used (*Mus musculus*) as animal model of preeclampsia due to mice are the most common animal to be used in bimoedic experiments, have a genetical similarities with human and have an ability to adapt in laboratory environment.³ Hepatal damage in relation with preeclampsia varies from light elevation of hepatal enzyme to broad bleeding under liver capsule (hematoma subcapsular) and hepatic rupture. The last two conditions are linked to HELLP syndrome. Hepatal lesion seen on biopsy and autopsy includes periportal bleeding, ischaemic lesion, and fibrin deposit.⁸ On severe preeclampsia, changes may be found in hepar function and integrity test. Periportal bleeding necrosis in the edge of hepatal lobules seem to be the reason of elevated serum hepatal enzyme.⁹ If bleeding occurs on periportal cells of the perifer lobule, hepatocyte cell necrosis

will happen. The bleeding will broaden into the under hepar capsule called subcapsular hematoma.¹⁰

L-arginine have an important role in L-arginine-nitric oxide pathway on preeclampsia. Several studies reported that the NO production elevates in normal pregnancy. On mice, cyclic guanosine monophosphate (cGMP, a NO second messenger) level on plasma and urine also nitrite/nitrate urine level, NO metabolite, and indicator of NO production in the body, will elevate during pregnancy.¹¹ This study was aimed to investigate the effect of L-arginine administration on hepatocyte cells damage on preeclampsia mice model.

MATERIALS AND METHODS

Animals

The study was conducted after an Ethical Clearance (number 648-KE) from Reseach Ethics Committee in Faculty of Veterinary Medicine, Airlangga University, Surabaya Indonesia was obtained. A total of 30 female Swiss mice aged 12 week with body weight 20-25 g obtained from Veterina Farma, Surabaya were used in this study.

Impregnate mice were conducted by synchronizing female mice lust with injecting 5 IU of pregnant more serum gonadotropin (PMSG) hormone followed by injecting 5 IU of human chorionic gonadotropin (hCG) after 48 h later. The female mice were then mated monomatedly by place each synchronized mouse into a cage with one male mouse aged 28 week with body weigh \pm 60 g. Furthermore, 17 h after mated pregnant mice were diagnosed if copulatory plug (a plug on mice's vagina from cervix to vulva) was observed. The 30 pregnant Swiss mice were then divided into three groups with 10 mice in each group i.e. normal pregnancy (G1), preeclampsia

model (G2) and preeclampsia model with L-arginine therapy (G3) mice.¹²

Protocol of study

On the 1st until 4th day of pregnancy, mice of G2 and G3 were injected anti Qa-2 10 ng IV (Mouse Qa-2® - Qa Lymphocyte Antigen 2 Region - MyBioSource TM).³ Following on 7 to 15th day, mice of G3 were given L-arginine at dose of 200 mg/kg body weigh/oral/day (# 400145/L-Arginine Free Base® 50 gr, Dyets Inc. TM). On the 16th day of pregnancy termination was conducted in all three groups of mice, being an analog of a 2nd trimester of human pregnancy where preeclampsia manifestation emerges in human. The mice were eutanated with ketamine and continued with necropsy. After all abdominal cavity were dissected and visible, liver was taken and moved into a pot of netral buffer formalin 10% for fixation. The indicator used to measure the successful rate of modeling preeclampsia was by looking at the level of hepatocyte cell repair to normal.

Preparates were made for histological examination, where fixated hepar was cuted and moved into a specimen plastic pot. Preparates were then colored with hematoxylin-eosin (HE). The preparates were observed under the microscope of Nikon Eclipse Ci with a magnification of 400x. Hepar histopathological change was scored with a Manja Roenigk scoring model as presented on TABLE 1.

TABLE 1. Manja Roenigk hepar histopathological score

Changing Level	Score
Normal	1
Parenkimatose degeneration	2
Hydropic degeneration	3
Necrosis	4

The number of cell damage was calculated on 5 field of view in each preparates paraffin block. The parameter for determining hepatic cell damage was conducted by comparing the structure change of the mice hepar-hostpathology in 3 groups, by finding signs of histopathological changes including degeneration and necrosis. Numbers of cells changing on each preparates were noted, then calculated to discover the scoring.^{14,15} In this experiment, one slide was prepared in each mouse, so that there were 30 slides in maximum. All experimental process were performed in Experimental Animal Warehouse and Biomedical Laboratory, Faculty of Veterinary, Airlangga University, Surabaya, Indonesia.

Statistical analysis

Data were presented as mean \pm standard deviation (SD) and analyzed using SPSS (Software Package for Social Science) 21. Results were calculated semiquantitatively with Manja Roenigk hepar histology scoring method. Data were tested nonparametrically using Kruskal-Wallis test. If there was any

significant differences, a Mann-Whitney test was performed. A p value <0.05 with confident interval 95% was considered significant.

RESULTS

FIGURE 1 presents hepar histopathology of all groups. Normal pregnant mice (G1) showed clear margin of sinusoid, hepatocyte cells structured radially, and degeneration and necrosis of cells not found, and cells clearly visible. On mice model preeclampsia (G2) showed and hepatocyte cells with hidropic degeneration (yellow arrow 1), accumulation of inflammation cell (blue arrow 2), hepar sinusoid not clearly visible, cells overlapping and accumulated, necrosis hepatocyte cells not found indicating hepatocyte cells damage. On mice model preeclampsia after L-arginine administration (G3) showed hepatocyte cells with parenchymal degeneration (arrow 3), space between sinusoid clearly bordered and hepatocyte cells looks normal and clearly visible indicating hepatocyte cells repair observed.

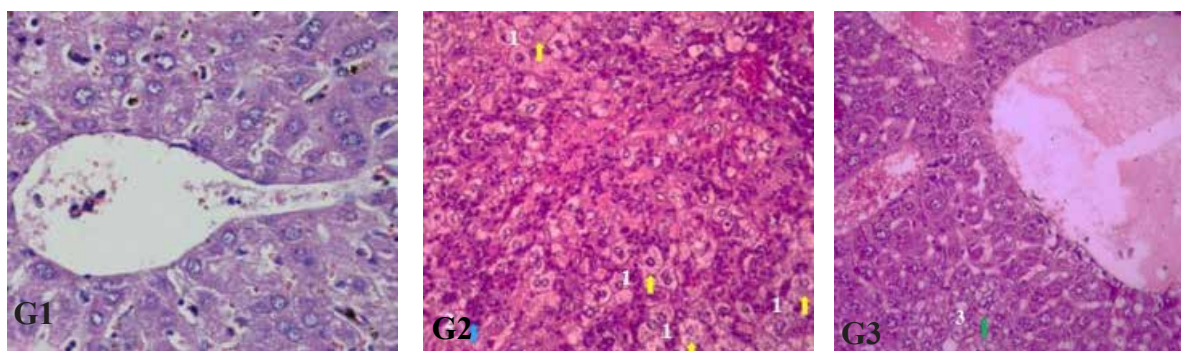


FIGURE 1. Comparison of hepar histopathology between musmusculus mice normal pregnancy (G1), model preeclampsia (G2), and model preeclampsia with L-arginine therapy (G3).

Mean of hepar histopathology score of preeclampsia model with L-arginine therapy ($40.80 \pm 1.17/\mu\text{m}^2$)

was significantly lower compared with preeclampsia model pregnant mice ($58.80 \pm 4.23/\mu\text{m}^2$) ($p < 0.05$). However, it

was significantly higher compared with normal pregnant mice ($18.40 \pm 2.41/\mu\text{m}^2$) ($p < 0.05$) (FIGURE 2). It was indicated that the L-arginine administration on

preeclampsia mouse model can reduce the score of hepatic histopathology score. However, the reduction did not achieved the normal condition.

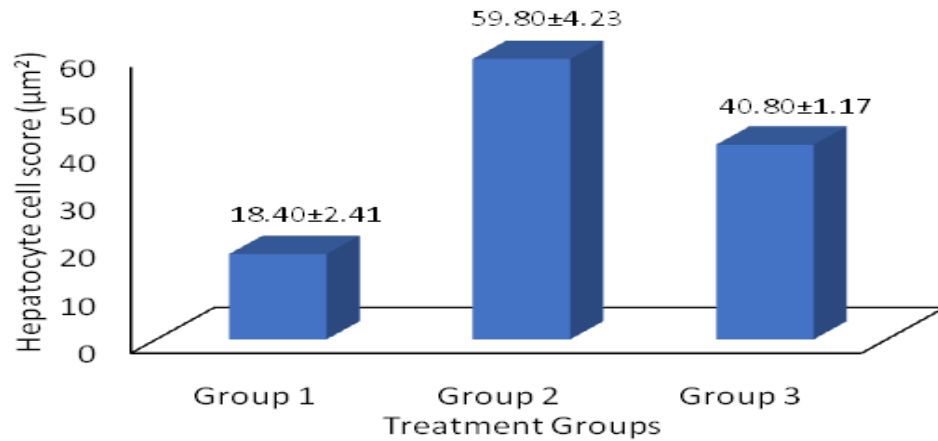


FIGURE 2. Mean of hepatic immunochemical score. G1 vs G2 ($p < 0.05$); G1 vs G3 ($p < 0.05$) and G2 vs G3 ($p < 0.05$)

DISCUSSION

During pregnancy under circumstances of increased NO production, endogenous synthesis of L-arginine is insufficient. L-arginine concentrations is significantly reduced in women with preeclampsia compared with healthy women. However, it appears that the ratio ADMA to L-arginine, rather than the concentration of L-arginine, is more critical in determining NOS activity and the subsequent production of oxygen free radicals, thus creating a perpetuating of NOS dysfunction.¹⁶

Endothelial dysfunction related to NO synthesis dysfunction is considered to be one of the causes of hypertension on pregnancy. L-arginine administration for pregnant woman will elevate NO production on peripheral vessels and lowered blood pressure. Moreover, it has been reported that administration of L-arginine can ameliorate artery hypertension, hypertension related to

pregnancy pathology, ischaemic disease, circulatory failure, atherosclerosis and cerebral stroke.¹⁷

Nitric oxide is a free radical role in human physiology in many ways. Its role on obstetric is to help smooth muscles relaxation. Nitric oxide production main site is NOS inside endothelial cells, used in L-arginine circulation as a substrate. Therefore, the local ability of these amino acids is important to regulate the endothelial adaptive mechanisms that are opposed to the occurrence of vasoconstrictors in preeclampsia. L-arginine is a semi essential amino acid because under an increased demand, and inadequate endogenous synthesis to fulfill the requirement. Vasodilation failure obtained in patients with preeclampsia. Circulated L-arginine substrate on NO synthesis happens during pregnancy. Preliminary data shows L-arginine supplement on diet reduced preeclampsia risk during pregnancy with increase vasodilation

through elevation of NO.¹⁸

Oxidative stress marked with an imbalanced production of ROS and endogen antioxidant. This change may cause cell structure damage from any tissues and organs, with changing vital function and determining cell death. Latest study shows oxidative stress as one of the main factor in preeclampsia pathophysiology and may interfere all reproductive period on woman. Other study support the hypothesis of oxidative stress could contribute on preeclampsia syndrome etiology.¹⁹

L-arginine acts as NO precursor and turned into NO and L-citrulline by NOS. L-arginine administration on pregnant woman with preeclampsia shows significant decrease of blood pressure. A controlled random trial shows diet supplementation with L-arginine combination and antioxidant vitamin such as vitamin C and E linked with significant decrease on preeclampsia cases, compared to antioxidant vitamin alone and placebo.²⁰

L-arginine decreases the number of preeclampsia cases and preeclampsia frequency 14.5%. Decreased risk on L-arginine group is estimated 26% with efficacy of 74%. L-arginine decreases incidence rate of severe preeclampsia significantly.²⁰ Latest study shows that L-arginine decreases systolic blood pressure, diastolic, and mean arterial pressure (MAP). Even on patients with chronic hypertension could reduce antihypertension medication doses. Decrease of preeclampsia incidence rate shows pregnancy with more gestational age and better perinatal outcome. Premature births are lower in L-arginine group and child given birth in this group has higher birth weight than placebo group.⁷

L-arginine works through NOS pathway with inhibit NO synthesis by inhibit NOS inhibitor so the production of NO will increase and able to give an impact on vascular vasodilatation and

improve hypoxia, therefore L-arginine might be a new therapeutic option for hypertension in pregnancy to prevent the incidence of preeclampsia in high-risk women.¹⁶

The mechanism of hepatic lesions with different etiologies begins with bleeding into the liver cell column due to arteriolar vasodilation, resulting in dislocation and deformation of hepatocytes in the stromal arm. Then in the advanced stage the state of persistent vasospasm causes gradual liver infarction starting from the area near the sinusoid and extending to the area near the portal vessels. Hemorrhagic changes occur in about 66% and necrotic changes in about 40% in women with eclampsia, which is one and a half more than in cases of preeclampsia. Hyalineinization and thrombosis of the liver have been obtained as evidence of DIC, but possibly as a result of the bleeding process.²¹

Cell necrosis is one of irreversible lesions (fibrosis, serosis) which can occur directly or can follow cell degeneration (reversible lesions; swelling and fatty liver). Microscopic features of necrosis can be picnosis, karyorrhesis, and karyolysis. Based on its location necrosis is divided into three which are focal necrosis, zone necrosis and submassive necrosis. Focal hepatic cell necrosis is necrosis that occurs randomly in one cell or a small group of cells in all regions of the liver lobules. This necrosis is recognized on biopsy through acidophilic bodies (councilman bodies) which are necrotic liver cells with a picnotic nucleus or lysis and pink coagulated cytoplasm. It can also be recognized in the liver cell lysis area surrounded by a collection of kupffer cells and inflammatory cells. Liver cell zone necrosis is liver cell necrosis that occurs in identical regions in all liver lobules, while submassive necrosis is liver cell necrosis that extends beyond the lobular border, often bridging portal areas with central veins (bridging necrosis).²²

L-arginine administration seems promising on lowering blood pressure and sustain pregnancy. A few studies showed positive result in hypertension effect after L-arginine administration. L-arginine administration is also reported to have a therapeutic effect on other pregnancy complication. However, other studies reported that there is no significant effect on L-arginine administration.²³

In pregnancy, l-arginine insufficiency may occur. The ADMA concentrations, a competitive inhibitor of NOS, are increased in women with preeclampsia. L-arginine supplementation in diet can provide a source of substrate for the synthesis of NO during pregnancy, which can play a role in the process of vasodilation. In preeclampsia, in long term of L-arginine administration in low doses significantly decreases in maternal blood pressure and increases the bioavailability of endothelial NO.²⁴

Other studies showed that L-arginine can reduce both systolic and diastolic blood pressure. Even patients with chronic hypertension significantly decrease the dose on antihypertensive medication. In subsequent studies, there was a decrease in the incidence of severe preeclampsia so as to obtain a pregnancy with a higher gestational age and better perinatal outcomes. Preterm birth was lower in the L-arginine group with higher birth weight compared to the placebo group.⁷ Therefore L-arginine can be a new therapeutic option for hypertension in pregnancy, to prevent the occurrence of preeclampsia especially in high-risk women.

CONCLUSION

L-arginine administration can reduce the hepatocyte cells damage of preeclampsia mice model.

ACKNOWLEDGEMENTS

Authors would like to thank technicians from the Experimental Animal Warehouse and Biomedical Laboratory, Faculty of Veterinary, Airlangga University, Surabaya for their valuable assistances during the study.

REFERENCES

1. Bilano VL, Ota E, Ganchimeg T, Mori R, Souza JP. Risk factors of preeclampsia/eclampsia and its adverse outcomes in low- and middle-income countries: a who secondary analysis. PLoS One 2014; 9(3):e91198. <https://doi.org/10.1371/journal.pone.0091198>
2. Staff AC, Benton SJ, von Dadelszen P, Roberts JM, Taylor RN, Powers RW, *et al.* Redefining preeclampsia using placenta-derived biomarkers. Hypertension 2013; 61(5):932-42. <https://doi.org/10.1161/hypertensionaha.111.00250>
3. Sulistyowati S, Abadi A, Wijati. Low class Ib (HLA-G/Qa2) MHC protein expression against HSP-70 and VCAM-1 profile on preeclampsia: an observation on experimental animal musmusculus with endothelial dysfunction model. Indonesian J Obstet Gynecol 2010; 34(3):103-6.
4. Jankowski M. Angiogenesis inhibition and preeclampsia. J Hypertens 2009; 27(4):707-8. <https://doi.org/10.1097/HJH.0b013e3283293dc5>
5. Ekambaram P. HSP70 Expression and its role in preeclamptic stress. Indian J Biochem Biophys 2011; 48(4):243-55.
6. Villar J, Purwar M, Merialdi M, Zavaleta N, thi Nhu Ngoc N, Anthony J, *et al.* World Health Organization

- multicentre randomized trial of supplementation with vitamin C and E among pregnant women at high risk for preeclampsia in populations of low nutritional status from developing countries. *BJOG* 2009; 116(6):780-8.
<https://doi.org/10.1111/j.1471-0528.2009.02158.x>
7. Camarena Pulido EE, García Benavides L, Panduro Barón JG, Pascoe Gonzalez S, Madrigal Saray AJ, García Padilla FE, *et al.* Efficacy of L arginine for preventing preeclampsia in high-risk pregnancies: a double-blind, randomized clinical trial. *Hypertens Pregnancy* 2016. 35(2):217-25.
<https://doi.org/10.3109/10641955.2015.1137586>
 8. Pramatiarta AP. Penatalaksanaan hipertensi dalam kehamilan dengan berbagai komplikasinya dalam penatalaksanaan intensif obstetri. Bandung: Sagung Seto. 2015.
 9. Leveno KJ. Hipertensi gestasional dan preeklamsia dalam manual Williams komplikasi kehamilan, Edisi 23. Jakarta: EGC. 2016; I,23;210-20.
 10. Angsar MD. Hipertensi dalam kehamilan. Dalam Ilmu Kebidanan Sarwono Prawirohardjo, Edisi V. Jakarta: PT Bina Pustaka Sarwono Prawirohardjo. 2014.
 11. Israel A, Elsa C, Matos MG, Garrido MDR. Rat kidney antioxidant enzyme activities in experimental preeclampsia. laboratory of neuropeptides, school of pharmacy, universidad central de Venezuela, Caracas, Venezuela. *IJCMPR* 2015; 1(7):104-9.
 12. Supranto J. Teknik sampling untuk survei dan eksperimen. Jakarta: Rineka Cipta, 2007.
 13. Nursheha A, Febrianti N. Pengaruh ekstrak daun cincau hijau (*Cyclea barbata* miers). terhadap gambaran histopatologik hepar mencit (*Mus musculus*) yang diinduksi MSG. *JUPEMASI-PBIO* 2015; 1(2):198-203.
<https://doi.org/10.26555/bioedukatika.v2i1.4105>
 14. Mescher AL. Junqueira's basic histology text and atlas, 13th Ed. New York: McGraw-Hill Education, 2013.
 15. Chan AWH, Quaglia A, Haugk B, Burt A. Atlas of Liver Pathology. New York: Springer. 2014.
<https://doi.org/10.1007/978-1-4614-9114-9>
 16. Wall TD, Grivell RM, Dekker GA, Hague W, Dodd JM. The role of L-arginine in the prevention and treatment of pre-eclampsia: a systematic review of randomised trials. *J Hum Hypertens* 2014; 28(4):230-5.
<https://doi.org/10.1038/jhh.2013.100>.
 17. Grafka A, Lopucki M, Kajszczyk KK. Study of the role L-arginine in the diagnosis of pregnancy-induced hypertension. *Arterial Hypertens*, 2016; 20(3):113-8.
<https://doi.org/10.5603/AH.2016.0017>
 18. Hegde CV. The use of L-Arginine in the management of pre-eclampsia and intrauterine growth restriction. *J Obstet Gynecol India* 2012; 62(1):1-2.
<https://doi.org/10.1007/s13224-012-0146-8>.
 19. De Lucca L, Gallareta FMP, Goncalves TDL. Oxidative stress markers in pregnant woman with preeclampsia. *Am J Med Biol Res* 2015; 3(3):68-73.
<https://doi.org/10.12691/ajmbr-3-3-1>
 20. Vellido-Ortega F, Perichart-Perera O, Espino S, Avila-Vergara MA, Ibarra I, Ahued R, *et al.* Effect of supplementation during pregnancy with L-arginine and antioxidant vitamins in medical food on pre-eclampsia in high risk population: randomised controlled trial. *BMJ* 2011; 342: d2901.
<https://doi.org/10.1136/bmj.d2901>
 21. Creasy RK, Resnik R, Iams JD, Lockwood CJ, Moore TR, Greene MF. Pregnancy-related hypertension in creasy & resnik's maternal-fetal medicine principle and practice,

- 7th ed. Philadelphia USA: Saunders Elseviers, 2014; Part 4, 48;756-81.
22. Kumar V, Abbas AK, Aster JC. Robbins and cotran pathologic basic of disease, 9th Ed. Philadelphia USA: Saunders Elsevier. 2015.
23. Shunping G, Jin J, Xiaoyu N, Yi B, Heng Z, Juelin D, *et al.* Arginine supplementation for improving maternal and neonatal outcomes in hypertensive disorder of pregnancy: a systematic review. JRAAS 2014; 15(1):88-96. <https://doi.org/10.1177/1470320313475910>
24. Hegde CV. The use of L-arginine in the management of preeclampsia and intrauterine growth restriction. J Obstet Gynecol India 2012; 62(1):1-2. <http://doi.org/10.1007/s13224-012-0146-8>.