

J Med Sci, Volume 47, No. 2, June: 96-114

Basic principles and diagnostic of colposcopy

Heru Pradjatmo

Gynecologic Oncology Division, Department of Obstetric and Gynecology,
Faculty of Medicine/Dr. Sardjito General Hospital, Universitas Gadjah Mada, Yogyakarta

DOI: <http://dx.doi.org/10.19106/JMedSci004702201506>

ABSTRACT

The colposcope is an optical system that offers illumination and magnifications between 10 and 16 times. Colposcopy is the diagnostic test to evaluate patients with an abnormal cervical cytological smear, abnormal VIA (visual inspection with acetic acid application) or VILI (visual inspection with Lugo's Iodine application), abnormal appearing cervix and directing biopsies. The colposcopic examination of the cervix starts with "General Assessment" to immediately recognize the level of examination reliability. Examination should be assessed for three variables: 1) adequate or inadequate, with the reason given; 2) squamocolumnar junction visibility; and 3) transformation zone type. Colposcopic features and patterns will correspond with underlying specific histological features. The greater the expertise and experience of the colposcopist, the greater the confidence in the assessment of the atypical transformation zone (TZ). For practical purposes, the most important aspect is always the recognition or exclusion of underlying actual invasive disease. The presence or absence of precancerous lesions can be confirmed with colposcopy.

ABSTRAK

Kolposkop adalah sistem optik yang memberikan iluminasi cahaya dan perbesaran antara 10 dan 16 kali. Kolposkopi adalah tes diagnostik untuk mengevaluasi pasien dengan sitologi Pap's smear abnormal, abnormal VIA (visual inspection with acetic acid application) atau abnormal VILI (visual inspection with Lugo's Iodine application), atau serviks yang tampaknya abnormal dan membantu biopsi terarah. Pemeriksaan kolposkopi serviks dimulai dengan "Penilaian Umum" yaitu segera mengenali tingkat keandalan pemeriksaan. Pemeriksaan harus menilai tiga variabel: 1) pemeriksaan adekuat atau tidak adekuat, dengan diberikan alasan 2) visibilitas batas skuamokolumnar dan 3) jenis zona transformasi. Pola gambaran kolposkopi akan sesuai dengan gambaran spesifik histopatologi yang mendasarinya. Semakin besar keahlian dan pengalaman ahli kolposkopi, semakin besar kesesuaian dalam penilaian zona transformasi atipi. Untuk tujuan praktis, aspek yang paling penting adalah selalu mengenali atau dapat menyingkirkan adanya penyakit invasif. Jadi ada atau tidak adanya lesi prakanker dapat dikonfirmasi dengan kolposkopi.

Keywords: Colposcopy - transformation zone - precancer lesion - cervical cancer - diagnosis

Corresponding author: : pradjatmo@yahoo.com

INTRODUCTION

The Papanicolaou smear (Pap smear) is a commonly used screening test for uterine cervix to detect potentially pre-cancerous and cancerous processes in the cervix. However, lately Naked-eye visual inspection of the uterine cervix, after application of 5% acetic acid (VIA) or visual inspection of Lugol's iodine (VILI), provides simple tests for early detection of precancerous cervical lesions and early invasive cancer.¹⁻⁴ The VILI is similar to the Schiller's iodine test, which used for early detection of cervical neoplasia in the third and fourth decades of the 20th century, but it discontinued after the advent of cervical cytology testing. The potential difficulties in implementing cervical cytology-based screening in low resource settings have prompted the investigation of the accuracy of alternative low-technology tests such as VIA and VILI in the early detection of cervical neoplasia.

Colposcopy is the diagnostic test to evaluate patients with an abnormal cervical cytological smear, abnormal VIA or VILI and abnormal appearing cervix. It entails the use of a field microscope to examine the cervix for acetic acid, and Lugol's iodine are applied to stain the cervix temporarily. The colposcope is an optical system that offers illumination and magnifications between 10 and 16 times. The cervix and vagina examined under magnification, and all abnormal areas identified. The characteristics of acetowhite changes, if any, on the cervix and vagina following the application of dilute acetic acid are useful in colposcopic interpretation and in directing biopsies. It is important to document the findings of colposcopic examination carefully, immediately after the procedure, in a colposcopic record.

BASIC PRINCIPLES OF COLPOSCOPY

The method of the investigation a speculum should be placed without previous vaginal exploration. It should not be completely open until the cervix has been visualized in order not to damage the unseen cervix. The speculum that used should have a dull-coated inner surface to prevent the reflection of the colposcope light that will interfere with the examination. The first procedure should be a naked eye examination of the cervix to evaluate its shape and size, the existence of any laceration, and the presence of leukoplakia or erythroplakia.

The direct colposcopic examination can then performed after one has cleaned the mucus that usually coats the surface of the cervix. Diagnosis of a lesion by colposcopy at this time can be taken as meaningful. Flooding the cervix with an aqueous solution of 3–5 % acetic acid followed in 15 to 20 seconds by the disappearance of the cervical mucus and improvement in the clarity of the colposcopic image. Differences in cellular density, thickness, and keratinization of the mucosa, breaks in the epithelium, and even the columnar papillae may clearly visible after the acetic acid has applied. However, the vascular bed becomes less evident, perhaps due to arteriolar spasm. The effect of acetic acid disappears after 2 minutes, and reapplication becomes necessary. Various techniques have been proposed to obtain better visualization of the cervical lesion and blood vessels appearances, as follow:⁵⁻¹⁰

- 1) Ethyl chloride to differentiate typical vessels, which contract on application of that chemical and the atypical ones of carcinoma, do not contract;
- 2) Epinephrine solution on 1: 1000 in 30 seconds vascular network especially capillary will be more evident;

- 3) Using fluorescent lamp;
- 4) Using green filter provide the visualization of the vascular bed;
- 5) If any doubt regarding the integrity of the epithelium using 1-2 percent silver nitrate solution is useful to visualize it, the reagent will produce whitish color of the denuded subdermis and permitting to differentiate erosion and a red congested area;
- 6) *In vivo* staining method to apply the acetic acid solution. It consists of hematoxylin solution for 1 to 2 minutes and then 0.5 % hydrochloric acid for one minute; a deep blue stain is as positive test implying malignancy, and a light blue color is as negative;
- 7) Schiller's test use Lugol solution, it is useful as an adjunct in the differentiation of some different image which looks alike superficially, such as ground structure found with vaginitis, also makes it possible to define the exact limits of a lesion and

to study its degree of maturation. The fundamental principle of Schiller's test is that only mature tissue containing of glycogen take up iodine, the atypical or carcinomatous epithelium is iodine-negative also young epithelium, columnar epithelium and involuted epithelium.

In the colposcopic examination report, there are several simple abbreviations and symbols (TABLE 1 and FIGURE 1). It would be just useful when the examiner and the gynecologist in charge of the patient are not the same people. The final report of the colposcopist should include a description of the colposcopic image using the symbols or a simple set of abbreviations or initial.¹¹ Then a diagnosis taking into account the peculiarities of the cervix being examined, recommendations as to follow-up and treatment of symptoms should be added as well.

TABLE 1. Several simple abbreviations in colposcopic examination^{12, 13}

Typical appearances	Abbreviation	Atypical appearances	Abbreviation
Original Mucosa	O.M.	Leukoplakia	L.
Papillary elevation	p.e.	Ground structure	G.
Ectopy	E.	Mosaic	M.
Vaginitis	V.	True erosion	T.E.
Red punctate vaginitis	r.p.v.	Ulceration	U.
White punctate vaginitis	w.p.v.	Vascular irregularities	V.I.
Focal vaginitis	f.v.	Atypical re-epithelialization zone	A.R.Z.
Petechial vaginitis	p.v.	Stable atypical scar	S.A.S.
Atropic Mukosa	A.M.	Atypical transformation zone	A.T.Z.
Typical re-epithelialization Zone	T.R.Z.	Carcinomatous proliferation	CA
Regular re-epithelialization	T.R.Z.r.		
Irregular re-epithelialization	T.R.Z.i.		
Glandular cyst	g.c.		

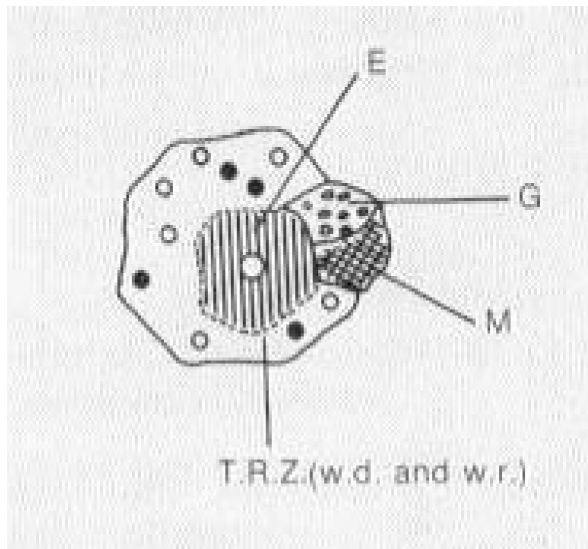


FIGURE 1. The schema of colposcopic examination report

INDICATION FOR COLPOSCOPY

Indications for colposcopy as follow: ¹⁴⁻¹⁶

- 1) Papanicolaou smear consistent with CIN 2 or CIN 3, persistent CIN I or cancer;
- 2) Papanicolaou smear with evidence of HPV infection (don't assume it is only HPV);
- 3) Papanicolaou smears with ASCUS or repeated ASCUS;
- 4) Abnormal-appearing cervix or suspicious-looking cervix;
- 5) Acetopositivity on visual inspection with acetic acid (VIA);
- 6) Acetopositivity on visual inspection with acetic acid using magnification (VIAM);
- 7) Positive on visual inspection with Lugol's iodine (VILI);

- 8) Persistent unsatisfactory quality on cytology;
- 9) Lesions that are more likely missed or under-read by colposcopic examination include endocervical lesions, extensive lesions that are difficult to sample, and necrotic lesions.

It should emphasize that women with low-grade lesions (CIN 1) on their cytology smears have a higher probability of having a high-grade lesion that would found at colposcopy; perhaps 15% for those with atypia and 20% with CIN 1 on cytology may harbour higher-grade lesions.¹⁷ It is advisable that women with any grade of CIN on cytology referred for colposcopy in developing countries, given the possibility of reporting misclassification associated with cytology and poor compliance with follow-up. The roles of 3-5% acetic acid application for VIA and subsequent visual inspection of the cervix with magnification (VIAM) and visual inspection with Lugol's iodine (VILI) accepted as alternative low-technology tests. However, a clear understanding of the anatomy, physiology, and pathology of the cervix is essential to understand the basis and to interpret the outcome of screening using VIA and VILI. Women who are positive for these tests may be referred for colposcopy to rule out underlying high-grade CIN and invasive cancer. However, if we have facility for HPV examination either, according to the recommendation for colposcopy of American Society for Colposcopy and Cervical Pathology described as presented in TABLE 2.¹⁸

TABLE 2. Recommendation for colposcopy, American Society for Colposcopy and Cervical Pathology

Cytology result	Recommendation for colposcopy	Strength of recommendation
ASC-US	• Preferred for positive high-risk HPV DNA	A
	• Acceptable for any patients with ASC-US	A
	• Also acceptable intensive cytology follow-up alone	A
ASC-H	• Preferred for immunosuppressed patients	B
AGC or AIS	• Preferred for all patients	A
	• Preferred for all patients (include endocervical curettage)	A
	• Preferred for all those older than 35 years, or having atypical endocervical cells, or unexplained vaginal bleeding (include endometrial biopsy)	A
LSIL	• Preferred for all patients	A
HSIL	• Preferred for patients (include endometrial curettage)	A

CLASSIFICATION

The current nomenclature committee established at 2008. International Federation of Cervical Pathology and Colposcopy World Congress in Auckland were replaced by new colposcopy terminology of the International Federation of Cervical Pathology and Colpos-

copy after a critical review of previous terminologies (TABLE 3). Classification of the colposcopic finding according to 2011 International Federation of Cervical Pathology and Colposcopy, the Colposcopic terminology of the Cervix.¹⁹

TABLE 3. 2011 International Federation of Cervical Pathology and Colposcopy Clinical and Colposcopic Terminology of the Vagina

Section	Pattern
General assessment	<ul style="list-style-type: none"> • Adequate or inadequate for the reason (e.g., cervix obscured by inflammation, bleeding, scar) • Squamocolumnar junction visibility: completely visible, partially visible, not visible • Transformation zone types 1, 2, 3
Normal colposcopic findings	<ul style="list-style-type: none"> • Original squamous epithelium: mature, atrophic • Columnar epithelium; ectopy/ectropion • Metaplastic squamous epithelium; nabothian cysts; crypt (gland) openings • Deciduous in pregnancy
Abnormal colposcopic findings	<ul style="list-style-type: none"> • General principles • Location of the lesion: Inside or outside the transformation zone; location of the lesion by clock position • Size of the lesion: number of cervical quadrants the lesion covers • Size of the lesion as percentage of cervix • Grade 1 (minor): <ul style="list-style-type: none"> • Fine mosaic; fine punctation; thin acetowhite epithelium; irregular, geographic border • Grade 2 (major): <ul style="list-style-type: none"> • Sharp border; inner border sign; ridge sign; dense acetowhite epithelium; coarse mosaic; coarse punctuation; rapid appearance of acetowhitening; cuffed crypt (gland) openings • Nonspecific: <ul style="list-style-type: none"> • Leukoplakia (keratosis, hyperkeratosis), erosion • Lugol's staining (Schiller's test): stained or nonstained
Suspicious for invasion	<ul style="list-style-type: none"> • Atypical vessels • Additional signs: fragile vessels, irregular surface, exophytic lesion, necrosis, ulceration (necrotic), tumor or gross neoplasm
Miscellaneous findings	<ul style="list-style-type: none"> • Congenital transformation zone, condyloma, polyp (ectocervical or endocervical), inflammation, stenosis, congenital anomaly, posttreatment consequence, endometriosis

COLPOSCOPIC APPEARANCES

The 2011 colposcopic terminology of the cervix starts with "General Assessment." of the cervix to immediately recognize the level of reliability of the examination. The popular terms "satisfactory colposcopy" and "unsatisfactory colposcopy" abandoned because they have the connotation of an inadequate examination that needs to repeat. The colposcopic examination should be assessed for three variables: 1) adequate or inadequate, with the reason given; 2)

squamocolumnar junction visibility; and 3) transformation zone type.^{16,19}

"Adequate or inadequate with the reason": this should be the opening statement of every colposcopic examination. The examination may be inadequate because the cervix obscured by inflammation, bleeding, or scarring. Squamocolumnar junction visibility: the squamocolumnar junction may be completely visible when 360° of the squamocolumnar junction is seen and partially visible when most of the squamocolumnar junction are visible but a section of it is

inside the endocervical canal or when a lesion covers the squamocolumnar junction with its inner border in the endocervical canal. The squamocolumnar junction may be not visible when all or most of the squamocolumnar junction cannot be seen because it is in the endocervical canal, then mentioned as transformation zone types 1, 2, 3. The reason that the visibility and site of the squamocolumnar junction are so important is that it dictates both the ability to do a satisfactory examination and when treatment is

indicated, what the extent and type of excision. In the “abnormal colposcopic findings,” we added the localization of the lesion to either inside or outside the transformation zone.²⁰

Normal cervix (normal colposcopic finding)

Three epithelial types cover the normal cervix i.e. 1) original squamous epithelium: mature or atrophic; 2) columnar epithelium: ectopy/ectropion; 3) transformation zone (TZ): metaplastic squamous epithelium, nabothian cyst, crypt opening (FIGURE 2-4).

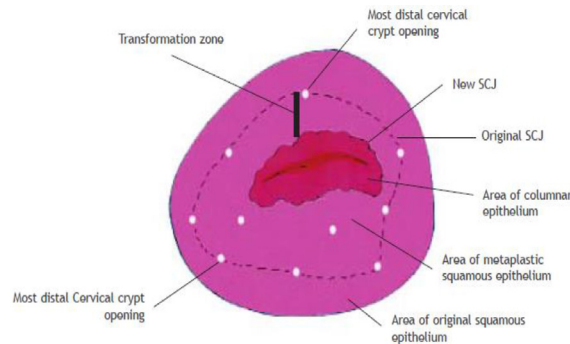


FIGURE 2. A method of identifying outer and inner borders of the transformation zone (SCJ: squamocolumnar junction) 16

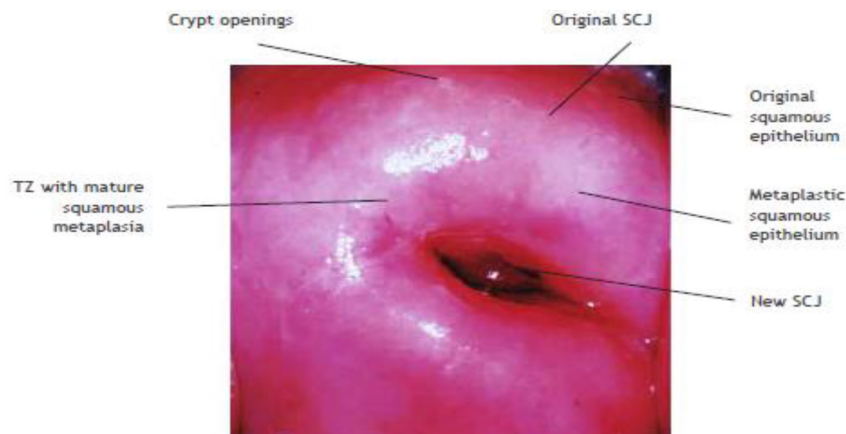


FIGURE 3. Normal colposcopic finding, entire new SCJ is visible, the TZ is fully visualized. The metaplastic squamous epithelium is pinkish-white compared to the pink original squamous epithelium. 16

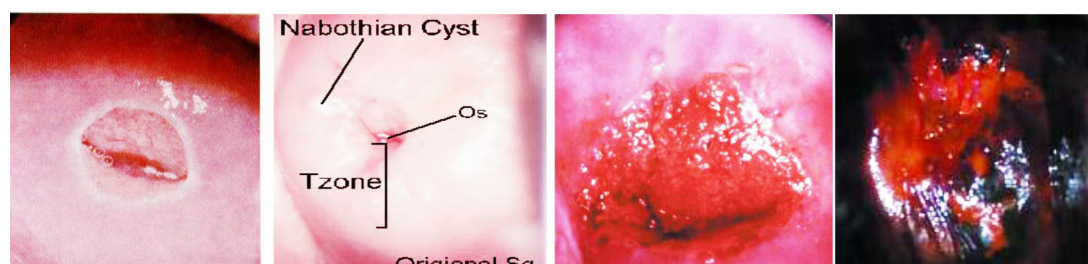


FIGURE 4. Normal colposcopic finding of the cervix^{12,14,16}

The original squamous epithelium is a featureless, smooth, pink epithelium. No features are suggesting columnar epithelium such as gland openings or Nabothian cysts. The epithelium is considered “always” squamous and not transformed from columnar to squamous. The epithelium will not stain white after application of acetic acid; it will stain brown after application of Lugol’s iodine. The columnar epithelium is a single-cell layer, mucous producing, tall epithelium that extends between the endometrium and the squamous epithelium. Columnar epithelium appears red and irregular with stromal papillae and clefts. With acetic acid application and magnification, columnar epithelium has a grape-like or “sea-anemone” appearance. It is found in the endocervix, surrounding the cervical os, or (rarely) extending into the vagina. Squamocolumnar junction a clinically visible line was seen on the ectocervix or within the distal canal (e.g., post-cryotherapy), which demarcates endocervical tissue from squamous (or squamous metaplastic tissue). The SJ represents the cranial extension of the TZ and, therefore, most CIN but not necessarily the metaplastic process. Congenital or acquired factors determine the substantial extent of exposed columnar epithelium; such a finding is pathologic and is known to colposcopist as ectopy. The physiologic process of the changes in the columnar

epithelium to form squamous epithelium as metaplastic squamous epithelium, this part of the metaplastic squamous epithelium also mentioned as TZ.

Transformation zone is the geographic area between the original squamous epithelium (before puberty) and the current SJ. It may contain gland openings, Nabothian cysts, and islands of columnar epithelium surrounded by varying degrees of maturity the metaplastic squamous epithelium. The proportion of each type of epithelium and its relationship to the ectocervix, cervical canal and each other will determine by several factors such as age, parity, pregnancy and previous surgery. It may stain slightly white after the application of acetic acid and partial brown after the application of Lugol’s iodine. There are three types of the transformation zone. A type 1 TZ is completely outside endocervical and fully visible. A type 2 TZ has an endocervical component, is fully visible, and may have an ectocervical component that may be small or large. A type 3 TZ has an endocervical component that is not entirely visible and may have an ectocervical component that may be small or large. Colposcopically without preparation the original mucosa has a uniform pink color and its surface is smooth, moist and subepithelial vascularization is barely visible. Terminal capillary vessels are seen through the colposcope. After flooding with acetic acid, the

usual pink color of the original mucosa pales a bit, even though it remains homogeneous. After a few minutes, it is possible to see the terminal capillaries in a manner suggesting a head of delicate hair. With Iodine staining (Schiller's test) the cervix takes an intense, homogenous chestnut color. The colorization is less remarkable at the level of the vaginal vault. At the intraepithelial junction the color disappears because the columnar epithelium does not fix iodine. Colposcopic features suggestive of metaplastic change: a smooth surface with subtle, uniform-calibre vessels, mild acetowhite change, negative or partial positivity with Lugol's iodine.

Abnormal colposcopic finding

Cervical intraepithelial neoplasia (CIN) is an asymptomatic condition suspected following cytological screening, usually no obvious characteristic signs with naked eye. CIN originates as a result of atypical metaplasia (dysplasia) mostly in the transformation zone. It is associated with alteration in cell contacts, decreased deposition of glycogen and increase cell turnover rates, which are important in the recognition. Cytology recognizes the possibility of CIN being present and histology allows diagnostic confirmation. However, colposcopy provides the important information which includes confirmation of the presence of a lesion, its topography; location of the lesion inside or outside the transformation zone, size, number of cervical quadrants and grade; suggest biopsy technique and appropriate treatment, and even the possibility of unsuspected cancer as well. Colposcopy has a reported sensitivity ranging from 87% to 99% to diagnose cervical neoplasia, but its specificity is lower, between 23% and 87%.^{2,21} Atypical TZ is area of transformation zone, which can be recognized with the colposcope as having undergone morphologic change

into squamous metaplasia, different to the normal pattern of physiologic transformation of columnar epithelium. Histology sampling from this area may reveal a spectrum of change varying from immature metaplasia to dysplasia or definitive precancerous change, culminating in preclinical invasive cancer. Location of the lesion is relative to the original squamocolumnar junction. "Inside" location means medial to the original squamocolumnar junction and 'Outside' is vice versa.

Pattern of atypical transformation zone

Color and opacity

Acetowhite epithelium

After application of a dilute solution of acetic acid areas of high nuclear density appear white (FIGURE 5). Dilute of 3 – 5 % acetic acid has a differential effect on the cervical epithelium. After dissolving mucous and demonstrating the SJ, it has a peculiar reversible effect on metabolically active squamous and columnar epithelium as white, or oyster grayish color in the transformation zone referred to as acetowhitening. The acetowhitening is thought related to the presence of increased nucleoprotein. The acetowhite common with CIN and the degree of change usually reflects the lesion grade. By logistic regression analysis the risk for a higher histologic grade when assessed by colposcopy was greatest in women with variation of the acetowhite color (odds ratio/OR =16.0; 95% CI: 10.0-26.0).²²

Not all active epithelium is CIN affected. Immature metaplasia and HPV disease can cause confusion and with both also often coexisting with CIN. The original transformation zone also has a predilection for acetic acid transformation. Dense acetowhite change within columnar epithelium may indicate glandular disease.

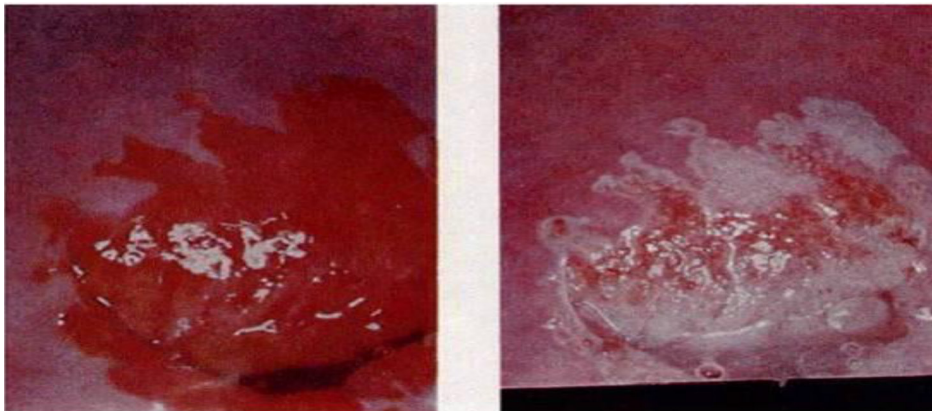


FIGURE 5. Uterine cervix with CIN before (left) and after (right) application of acetic acid 12

Angioarchitecture

The blood supply of squamous epithelium arises from stromal vessels and usually arranged in a regular pattern. When there is increasing metabolic activity, such as in CIN, the vessels become more prominent and can be readily visible colposcopically. Variation in intraepithelial capillary pattern and caliber of vessels occurs to produce characteristic patterns in the acetowhite epithelium. The grosser pattern more likely associated with the more severe grades of histology changes. By logistic regression analysis the risk for a higher histologic grade when assessed by colposcopy was greatest in women with coarse vessels (OR = 10.0; 95% CI: 3.2-34.0).²²

Punctuation

Single loop capillaries lying within the stromal papillae are seen end on, as dots or punctuation coursing obliquely or perpendicularly toward the surface of the epithelium (FIGURE 6). The pattern may vary from regular one of extremely fine, closely spaced, loop capillaries of narrow caliber with increased and irregular intercapillary spacing. A focal colposcopic pattern in which capillaries appear in a tipped pattern. The finer the punctuation appearance, the more likely the lesion is to be low grade or metaplasia. The coarser the punctuation the more likely the lesion is to be of major grade.

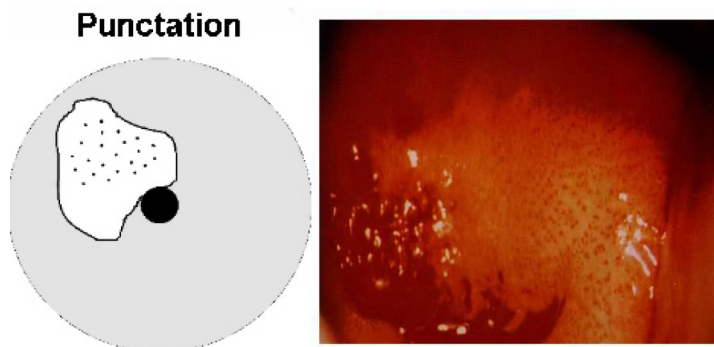


FIGURE 6. Punctuation pattern of blood vessel¹⁴

Mosaic pattern

A terminal vessel running in thin fibrous septa may cut the epithelium into abnormal pattern described as a mosaic (FIGURE 7). This mosaic pattern will vary from the minimal form showing fine caliber vessels delineating a small area of regular size and shape, through varying stages to that of coarse, prominent surface vessels surrounding blocks which may be grossly irregular in size and shape with obvious increased intercapillary

distance. A focal colposcopic appearance in which the new vessel formation appears as a rectangular pattern like a mosaic. The smaller the mosaic, the more likely the lesion is to be a low grade. The coarser, wider, and more irregular the mosaic, the more likely the lesion to be a major grade. The combination of both punctuation and mosaic structure will frequently intermingle and represent underlying abnormal vascular growth and activity.

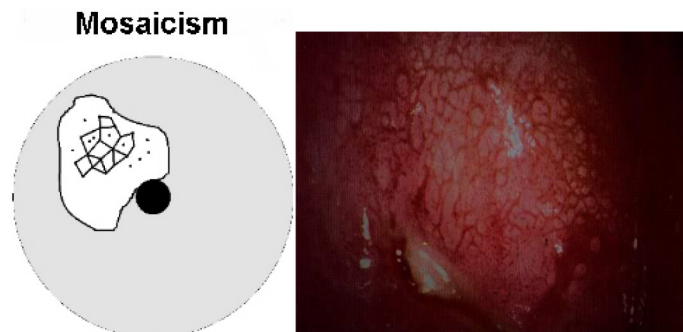


FIGURE 7. Punctuation and mosaic pattern of blood vessel¹⁴

Atypical vessels

Non-specific changes showing bizarre, irregular branching with considerable variation in caliber and coarse more frequently associated with the feature of invasive carcinoma. These are the result of new vessel formation and are usually seen only in high-grade lesion where invasion may have already taken place (FIGURE 8). A focal abnormal colposcopic pattern in which the blood vessel pattern appeared not as punctuation or mosaic or as the finely branching capillaries of normal epithelium, but rather as irregular vessels with an abrupt and interrupted coarse-appearing as commas, corkscrew capillaries, or spaghetti-like forms.

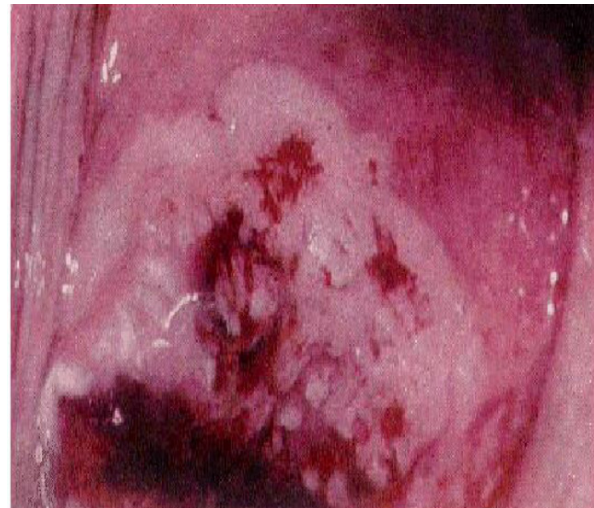

FIGURE 8. Atypical pattern of blood vessel¹⁴

Surface contour or configuration changes

Irregular surface contour with excrescences, particularly with abnormal vascular changes is more likely associated with a feature of high-grade CIN or early invasive lesions (FIGURE 9).²² However, its can be seen in lesser grades, especially when HPV involvement is prominent. Other causes of an irregular surface may be cystic inclusions and even persistence of the villous-like columnar structure still undergoing metaplastic change. Location of the lesion inside or outside the TZ. Location of the lesion is relative to the original squamocolumnar junction. “Inside” location means medial to the original squamocolumnar junction (toward the cervical os) and vice versa. The border of a lesion is a sharp border that is a straight edge of an acetowhite cervical lesion.

Other edge definitions are feathered or geographical margin, usually associated with a low-grade lesion, and rolled peeling edges that associated with a high-grade lesion.⁷ The inner border sign is a sharp demarcation between a thin and a dense acetowhite area within the same.²³ The Ridge sign is an opaque protuberance at the field of a white epithelium within the TZ.²⁴

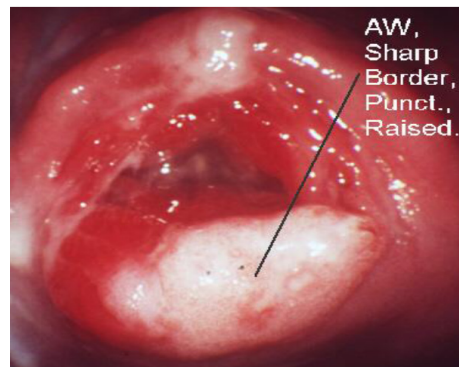


FIGURE 9. Show the surface contour or configuration changes¹⁴

TABLE 4. Colposcopic features suggestive abnormal changes²⁵

<p>Low-grade disease (minor change). A smooth surface with an irrugular outer border. Slight acetowhite change, slow to appear and quick to disappear. Fine punctation and fine regular mosaic. Mild, often speckled iodine partial positivity.</p> <p>High-grade disease (major change). A generally smooth surface with a sharp outer border. Dense acetowhite change, which appears early and is slow to resolve; it may be oyster white. Coarse punctation and wide irregular mosaics of differing size. Dense acetowhite change within columnar epithelium may indicate glandular disease. Iodine negativity, a yellow appearance in a previously densely white epithelium</p> <p>Suggestive of invasive cancer Irregular surface, erosion, or ulceration. Dense acetowhite change. Wide irregular punctation and mosaic, atypical vessels irregular mosaics of differing size. Dense acetowhite change within columnar epithelium may indicate glandular disease. Iodine negativity, a yellow appearance in a previously densely white epithelium.</p>
--

Other colposcopic findings

Vaginitis

Cervicitis may cause abnormal Pap smears and make colposcopic assessment

more difficult. Many authorities recommend treatment before biopsy when a STD is strongly suspected.

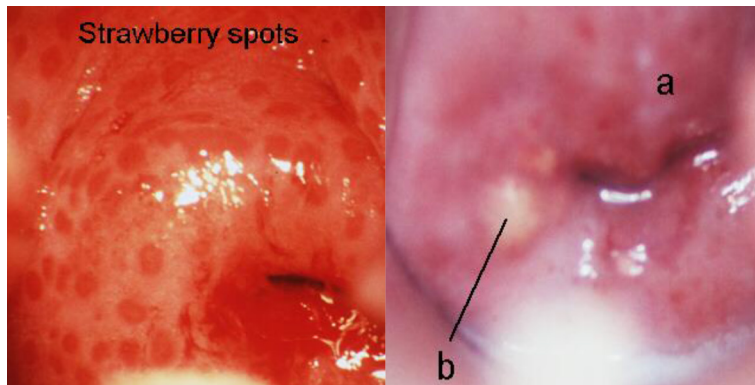


FIGURE 10. The appearance of Strawberry spot in Trichomoniasis infection (left), and purulent discharge and Nabothian cyst (b) in cervicitis (a) (right)¹⁴

Traumatic erosion

Traumatic erosions are most commonly caused by speculum insertion and over vigorous Pap smears but can also result from such irritants as tampons, diaphragms, and intercourse (FIGURE 11).¹²

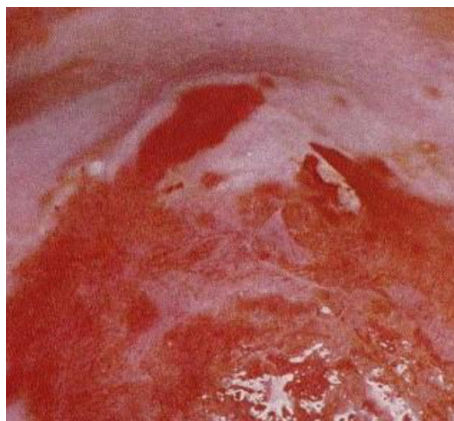

FIGURE 11. Traumatic erosion of the cervix¹²

Atrophic epithelium

Atrophic vaginal or cervical epithelium may also cause abnormal Papanicolaou smears (FIGURE 12). Colposcopists will often prescribe estrogen for 2 to 4 weeks before a colposcopy in order to “normalize” the epithelium before the examination. This is generally felt to be safe even if dysplasia or cancer is present because the duration of therapy is short and these lesions do not express any more estrogen receptors than a normal cervix.

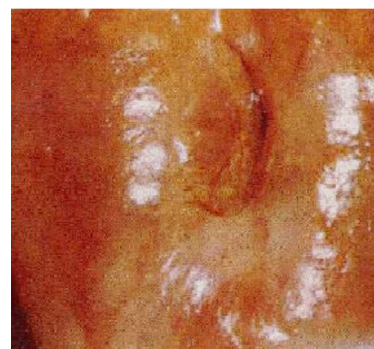

FIGURE 12. Atrophic epithelium of the cervix¹²

Nabothian cysts

Nabothian cysts are normal. They are areas of mucus producing epithelium that is “roofed over” with squamous epithelium. They do not require any treatment. They provide markers for the transformation zone since they are in squamous areas but are remnants of columnar epithelium.

Congestion (erythroplakia)

This reflects epithelial thickness and blood supply (FIGURE 13). Full thickness mature squamous epithelium will not be as red as columnar epithelium. CIN, particularly of an advanced grade, will appear more congested than normal inactive metaplasia.

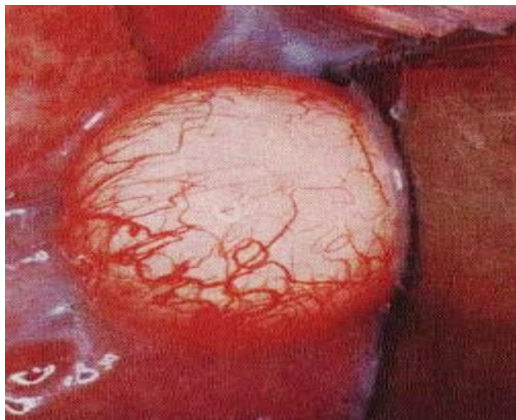


FIGURE 13. Nabothian cyst and congestion (erythroplakia) of blood vessel¹²

Leukoplakia (keratosis)

These are the areas of white elevation visible before the application of acetic acid. Leukoplakia is a sign of disordered keratin production and the possibility of underlying abnormal epithelium. It is a particular feature of HPV affected tissue and condylomata.

Colposcopic Assessment of topography

The management of suspected CIN would depend on the site of the lesion.

The transformation zone must be assessed completely as successful treatment will depend on removal of the area within which precursors of cancer develop. Focal lesion-entirely visible, this should not pose any therapeutic problems. Lesion extend into the cervical canal, it is often possible to see the upper extremity with manipulation of the cervix, where this is not possible, the colposcopic findings are “TZ type 2 or 3” and other management techniques will be necessary. Lesion not visible, caution is required to avoid missing disease high in the cervical canal. False positive Pap smear is possible but unusual. Colposcopic assessment not possible, there may be technical difficulties in exposing the cervix. The co-existence of significant inflammation or atrophy can interfere with the examination. Specific treatment should allow later adequate assessment. Lesion extends onto vagina, although this is uncommon, it is well recognized as a reason for recurrent abnormal Pap smears. HPV affected epithelium not uncommonly involves the vagina.

Colposcopic grading

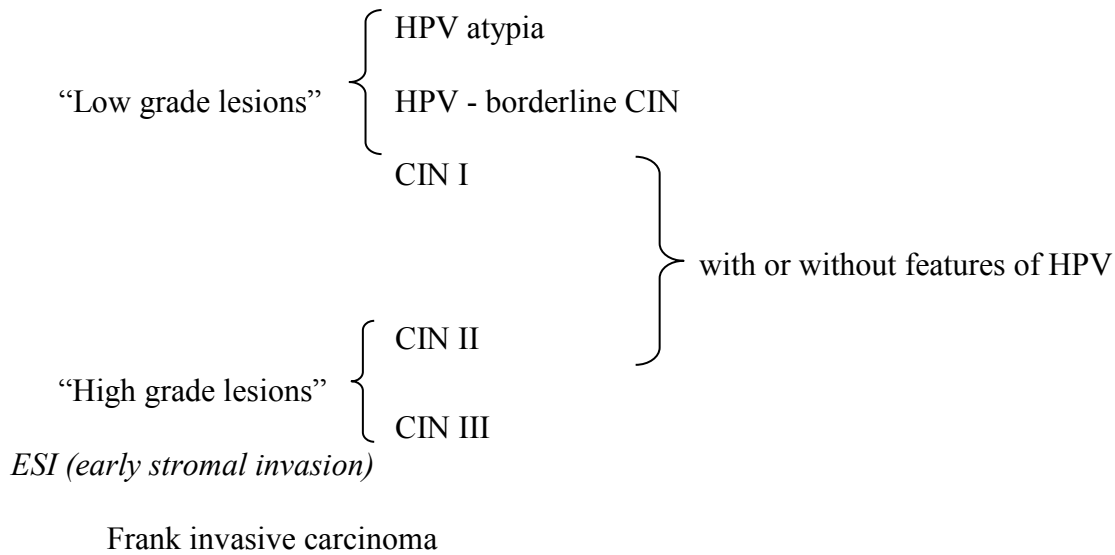
Cytology has alerted the possibility of CIN being present. Colposcopy has confirmed the presence of a lesion and its topography. It is important to assess the lesion’s significance and colposcopic grading. Such factors as color, vascularity, margins and contour need to be assessed. The grade will depend on interpretation of: a). degree of acetowhitening, b). caliber, shape, and pattern of punctuation and mosaic, c). intercapillary distance, d). presence of atypical vessels, e). surface contour, f). margin of abnormal epithelium.

Major grade III lesions are usually highly significant with maximum histology required to exclude invasion. Lesser grade is more common and represents one or other level of

CIN. Richard Reid has introduced his concept of the combined Colposcopic Index, which is a widely accepted technique used in the assessment of the degree of concurrent HPV involvement.¹⁷

Interpretation of Atypical Features of TZ

Interpretation of atypical features of transformation zone can be assessed in the following ways:¹⁷



Subjective assessment of the overall morphology and pattern

The fundamental practical principles involved are to decide: a). Is there normal or abnormal TZ? b). Is the lesion in or out of range? c). Can confident exclusion of invasive disease be made?. Colposcopic features can then be expressed in the term “consistent with an underlying histologic diagnosis” of:

Grading (Coppleson)

Grade I (insignificant not suspicious) HPV up to CIN I

Flat, acetowhite epithelium, borders not so sharp; semi-translucent with or without fine caliber, regular shaped vessels, patterns are ill defined with short intercapillary distance.

Grade II (significant, suspicious) CIN II - III

Flat, whiter epithelium sharply bordered, increased opacity; regular shaped vessels,

varying caliber, absence of atypical vessels; defined patterns, increased intercapillary distance.

Grade III (highly significant, highly suspicious) CIN III or ‘microinvasive’

Very white or gray opaque epithelium; sharply bordered vessels of dilated caliber, irregularly shaped, often coiled and atypical; increased but variable intercapillary distance; sometimes irregular surface contour.

TABLE 3. The modified Reid colposcopic index (RCI)^{16,26}

Colposcopic Sign	Zero point	One point	Two points
Colour	Low-intensity acetowhitening (not completely opaque); indistinct acetowhitening; transparent or translucent acetowhitening. Acetowhitening beyond the margin of the transformation zone. Pure snow-white color with intense surface shine (rare)	Intermediate shade - grey/white color and shiny surface (most lesions should be scored in this category)	Dull, opaque, oyster white; grey
Lesion margin and Surface configuration	Microcondylomatous or micropapillary. Contour Flat lesions with indistinct margins. Feathered or finely scalloped margins. Angular, jagged lesions. Satellite lesions beyond the margin of the transformation zone	Regular-shaped, symmetrical lesions with smooth, straight outlines	Rolled, peeling edges. Internal demarcations between areas of differing colposcopic appearance—a central area of high-grade change and peripheral area of low-grade change
Vessels	Fine/uniform-calibre vessels- closely and uniformly placed Poorly formed patterns of fine punctation and/or mosaic Vessels beyond the margin of the transformation zone Fine vessels within microcondylomatous or micropapillary lesions	Absent vessels	Well defined coarse punctation or mosaic, sharply demarcated – and randomly and widely placed
Iodine staining	Positive iodine uptake giving mahogany brown color Negative uptake of insignificant lesion, i.e., yellow staining by a lesion scoring three points or less on the first three criteria	Partial iodine uptake - variegated, speckled appearance	Negative iodine uptake of significant lesion, i.e., yellow staining by a lesion already scoring four points or more on the first three criteria
	Areas beyond the margin of the transformation zone, conspicuous on colposcopy, evident as iodine-negative areas (such areas are frequently due to parakeratosis)		

“Colposcopic Score”

0-2 = Likely to be CIN 1

3-4 = Overlapping lesion: likely to be CIN 1 or CIN 2

5-8 = Likely to be CIN 2-3

Colposcopy has a role in the prevention of cervical cancer by identifying preinvasive or invasive lesions. Very strongly that the heart of colposcopic practice is the identification of the most abnormal area for biopsy.²⁷ However, colposcopy is subjective and is responsible for 52% of screening failures.²⁸ Technology is constantly evolving, which is a subjective examination method continue to pursue to more objective.^{28,29} Pretorius et al. studied for determining the relative importance of colposcopically directed biopsy, random biopsy, and endocervical curettage (ECC) in diagnosing cervical intraepithelial neoplasia (CIN) II or worse. They concluded that random biopsies of the cervix may be helpful in the detection of CIN II or worse in patients with HGSIL or cancer cytology and negative colposcopy. Endocervical curettage increases detection of CIN II or worse regardless of referral cytology and should be included in routine colposcopic evaluation of patients with abnormal cytology.³⁰ Soutter et al. performed research with dynamic spectral imaging based on objectivity, quantitative determination and acetowhitening effect. Showed that the method of dynamic spectral imaging more sensitive than colposcopy in detecting high-grade lesions and can provide improved guidance for biopsy.²⁸

CONCLUSION

In summary, colposcopy is the diagnostic test to evaluate patients with an abnormal cervical cytological smear or abnormal-appearing cervix. Colposcopic features and patterns will correspond with underlying specific histological features. The greater the expertise and experience of the colposcopist, the greater the confidence in the assessment

of the atypical TZ. For practical purposes, the most important aspect is always the recognition or exclusion of underlying actual invasive disease. The presence or absence of precancerous lesions can confirm with colposcopy.

ACKNOWLEDGEMENTS

This paper was presented on The Training of Management of Pre-cancerous Lesion, *Indonesian Society of Obstetrics & Gynecology Yogyakarta at December 12-14, 2014 in Yogyakarta.*

REFERENCES

1. Denny L, Kuhn L, Pollack A, Wainwright H, Wright TC Jr. Evaluation of alternative methods of cervical cancer screening for resource-poor settings. *Cancer* 2000; 89(4):826-33. [http://dx.doi.org/10.1002/1097-0142\(20000815\)89:4<826::AID-CNCR15>3.0.CO;2-5](http://dx.doi.org/10.1002/1097-0142(20000815)89:4<826::AID-CNCR15>3.0.CO;2-5)
2. Belinson JL, Pretorius RG, Zhang WH, Wu LY, Qiao YL, Elson P. Cervical cancer 111 screening by simple visual inspection after acetic acid. *Obstet Gynecol* 2001; 98(3):441-4. <http://dx.doi.org/10.1097/00006250-200109000-00014> [http://dx.doi.org/10.1016/S0029-7844\(01\)01454-5](http://dx.doi.org/10.1016/S0029-7844(01)01454-5)
3. Sankaranarayanan R, Budukh AM, Rajkumar R. Effective screening programmes for cervical cancer in low-and middle-income developing countries. *Bull World Health Organ* 2001; 79(10):954-62.
4. Shastri SS, Dinshaw K, Amin G, Goswami S, Patil S, Chinoy R, *et al.* Concurrent evaluation of visual, cytological and HPV testing as screening methods for the early detection of cervical neoplasia in Mumbai, India. *Bull World Health Organ* 2005; 83(3):186-94.

5. Burke L, Antonioli DA, Ducatman BS. Colposcopy text and atlas. Connecticut: Appleton & Lange, 1990.
6. Soutter, P. Practical colposcopy. Oxford: Oxford University Press, 1993.
7. Wright VC, Lickrish GM, Michael Shier R. Basic and advanced colposcopy. Part 1: a practical handbook for treatment, 2nd ed. Texas: Houston, 1995.
8. Anderson M, Jordan J, Morse A, Sharp F. Integrated colposcopy. 2nd ed. London: Chapman Hall Medical, 1996.
9. Burghardt E, Pickel H, Girardi F. Colposcopy cervical pathology. Textbook and Atlas. New York: Thieme, 1998.
10. Singer A, Monaghan J. Lower genital tract precancer colposcopy, pathology and treatment. 2nd ed. Oxford: Blackwell Science, 2000. <http://dx.doi.org/10.1002/9780470760093>
11. Cartier R, Cartier I. Practical colposcopy. 3rd ed. Paris: Laboratoire Cartier, 1993.
12. Dexeus S, Carrera JM, Coupeze F. Colposcopy. 10th ed. Toronto: W.B. Saunders Co. 1977.
13. Staffl A, Wilbanks GD. An international terminology of colposcopy: Report of the nomenclature committee of the international federation of cervical pathology and colposcopy. *Obstet Gynecol* 1991; 77(2):313-4. <http://dx.doi.org/10.1097/00006250-199102000-00032>
14. Mayeaux EJ Jr, Newkirk G. Introduction to colposcopy. [cited 2015, December 5] Available from: URL: <http://lib-sh.lsumc.edu/fammed/atlas/colpoat.html>, 2000
15. Champion M, Ferris D, di Paola F, Reid R. Modern colposcopy : a practical approach. Augusta: Educational System Inc., 1991.
16. Sellors W, Sankaranarayanan R. Colposcopy and treatment of cervical intraepithelial neoplasia: a beginners manual. IARC, 2003.
17. Shafi MI, Luesley DM, Jordan JA, Dunn JA, Rollason TP, Yates M. Randomised trial of immediate versus deferred treatment strategies for the management of minor cervical cytological abnormalities. *Br J Obstet Gynaecol* 1997; 104(5):590-4. <http://dx.doi.org/10.1111/j.1471-0528.1997.tb11538.x>
18. Wright TC Jr, Cox JT, Massad LS, Twiggs LB, Wilkinson EJ. 2001 Consensus guidelines for the management of women with cervical cytological abnormalities. *JAMA* 2002; 287(16):2120-9. <http://dx.doi.org/10.1001/jama.287.16.2120>
19. Bornstein J, Bentley J, Bösze P, Girardi F, Haefner H, Menton M, *et al.* 2011 Colposcopic terminology of the international federation for cervical pathology and colposcopy. *Obstet Gynecol* 2012; 120(1):166-72. <http://dx.doi.org/10.1097/AOG.0b013e318254f90c>
20. Walker P, Dexeus S, De Palo G, Barrasso R, Champion M, Girardi F, *et al.* International terminology of colposcopy: an updated report from the international federation for cervical pathology and colposcopy. *Obstet Gynecol* 2003; 101(1):175-7. [http://dx.doi.org/10.1016/S0029-7844\(02\)02581-4](http://dx.doi.org/10.1016/S0029-7844(02)02581-4) <http://dx.doi.org/10.1097/00006250-200301000-00032>
21. Mitchell MF, Schottenfeld D, Tortolero-Luna G, Cantor SB, Richards-Kortum R. Colposcopy for the diagnosis of squamous intraepithelial lesions: a meta-analysis. *Obstet Gynecol* 1998; 91(4):626-31.
22. Kierkegaard O, Byralsen C, Hansen KC, Frandsen KH, Frydenberg M. Association between colposcopic findings and histology in cervical lesions: the significance of the size of the lesion. *Gynecol Oncol* 1995; 57(1):66-7. <http://dx.doi.org/10.1006/gyno.1995.1100>
23. Scheungraber C, Glutig K, Fechtel B, Kuehne-Heid R, Duerst M, Schneider A. Inner border:

- a specific and significant colposcopic sign for moderate or severe dysplasia (cervical intraepithelial neoplasia 2 or 3). *J Low Genit Tract Dis* 2009; 13(1):1-4. Doi: 10.1097/LGT.0b013e31817ff92a.
24. Scheungraber C, Koenig U, Fechtel B, Kuehne-Heid R, Duerst M, Schneider A. The colposcopic feature ridge sign is associated with the presence of cervical intraepithelial neoplasia 2/3 and human papillomavirus 16 in young women. *J Low Genit Tract Dis* 2009; 13(1):13-6. <http://dx.doi.org/10.1097/LGT.0b013e318180438a>.
 25. Nazeer S, Shafi MI. Objective perspective in colposcopy. *Best Pract Res Clin Obstet Gynaecol* 2011; 25(5):631-40. <http://dx.doi.org/10.1016/j.bpobgyn.2011.04.008>.
 26. Reid R, Scalzi P. Genital warts and cervical cancer. VII. An improved colposcopic index for differentiating benign papillomaviral infections from high-grade cervical intraepithelial neoplasia. *Am J Obstet Gynecol* 1985; 153(6):611-8. [http://dx.doi.org/10.1016/S0002-9378\(85\)80244-1](http://dx.doi.org/10.1016/S0002-9378(85)80244-1)
 27. Jeronimo J, Schiffman M. Colposcopy at a crossroads. *Am J Obstet Gynecol* 2006; 195(2):349-53. <http://dx.doi.org/10.1016/j.ajog.2006.01.091>
 28. Soutter WP, Diakomanolis E, Lyons D, Ghaem-Maghani S, Ajala T, Haidopoulos D, *et al*. Dynamic Spectral imaging: improving colposcopy. *Clin Cancer Res* 2009; 15(5): 1814-20. Doi: 10.1158/1078-0432.CCR-08-1636.
 29. Li W, Gu J, Ferris D, Poirson A. Automated image analysis of uterine cervical images. *Medical Imaging* 2007; 651465142:P-2.
 30. Pretorius RG, Zhang WH, Belinson JL, Huang MN, Wu LY, Zhang X, *et al*. Colposcopically directed biopsy, random cervical biopsy, and endocervical curettage in the diagnosis of cervical intraepithelial neoplasia II or worse. *Am J Obstet Gynecol* 2004; 191(2):430-4.