

*J Med Sci*  
Volume 43, No. 1, March 2011: 8-11

# Agreement between ultrasonography and histopathologic findings in diagnosing retinoblastoma

Fitria Natliani\*, Siti Sundari, Retno Ekantini

Department of Ophthalmology, Faculty of Medicine, Gadjah Mada University/  
Dr. Sardjito General Hospital, Yogyakarta, Indonesia

## ABSTRACT

Retinoblastoma is a rare eye tumor of childhood that represents the most common intraocular malignancy of infancy and childhood. Diagnosis of retinoblastoma are based on ophthalmological examination and imaging, including ultrasonography (USG). In a typical case of retinoblastoma, it will provide a nearly pathognomonic picture with cottage-cheese calcification, with density higher than the sclera and high internal reflectivity in USG findings. Histopathologic examination is a gold standard for malignancy cases and Flexner-Wintersteiner cells is a pathognomonic sign. The aim of this study is to determine the value of an agreement test comparing USG as a preoperative diagnostic tool with histopathologic examination in diagnosing retinoblastoma. This study was an observational agreement test. All of the patients with clinically suspected intraocular lesion were examined with USG followed by surgery and histopathologic examination in Eye Clinic of Dr. Sardjito Hospital, Yogyakarta. The result of USG examinations was interpreted by one eye oncologist and the histopathologic reading was performed by one anatomical pathologist. Data were analyzed to determine the agreement value. Thirty three eyes, 21 eyes were retinoblastoma suspected and 12 eyes were non-retinoblastoma suspected based on USG examination), were observed in this study. One eye (3.03%) was false positive case and 1 was false negative case. The Kappa value of agreement test was 0.87. In conclusion, ultrasonography of the eye as a pre-operative diagnostic tool had an excellent agreement compared with histopathological examination as a gold standard in retinoblastoma.

*Key words:* eye-retina-intraocular malignancy-diagnosis-Kappa value

## INTRODUCTION

Retinoblastoma is a rare eye tumor of childhood that arises in the retina, and represents the most common intraocular malignancy of infancy and childhood with an incidence of 1/15.000-20.000 live births.<sup>1</sup> There are no difference in incidence by sex or race or right versus left eye. In 60% of cases, the disease is unilateral and the median age at diagnosis is two years.<sup>1,2</sup>

The diagnosis of retinoblastoma is based on ophthalmologist examination and imaging, including ultrasonography. Biopsy is not indicated because theoretically the procedure can make the tumor extent into extraocular, that can change the intraocular tumor with good prognosis become an extraocular tumor, metastatic with poor prognosis.

Therefore, it is needed a save, noninvasive, cost effective diagnostic tools, such as ultrasonography.<sup>2,3,4</sup>

Ultrasonic imaging of ocular structures has unique acoustical advantages of the cyst like globe and the dimensions of the important ocular tissues. Routine ocular scanning is performed with B-scan using 7.5 MHz-10 MHz transducer and examinations can be performed at frequencies of up to 100 MHz, permitting the visualization of structures of the anterior segment in near microscopic detail. This modality is of great value to eye surgeon for a preoperative assessment of the posterior segment when funduscopy is not possible due to opaque ocular media from various causes.<sup>5</sup>

Retinoblastoma is seen as an irregular mass with a broad base in the posterior segment of the eye.

---

\* corresponding author: [fnch2212@yahoo.com](mailto:fnch2212@yahoo.com)

Calcification can be seen. There may be an associated retinal detachment in 5% of patients. Tumor extension into the optic nerve is associated with 65% mortality. In a typical case of retinoblastoma, it will provide a nearly pathognomonic picture with cottage-cheese calcification, a yellowish mass like cheese.<sup>5,6</sup> Calcification in retinoblastoma can be seen as high as 97%,<sup>7</sup> as reported by Wirasmita *et al.*<sup>8</sup> in 95% of retinoblastoma cases, calcification can be found. A single or multiple irregular mass in the vitreous cavity arising from the retina with calcification and irregular high internal reflectivity with a high echo spike (>80%) are typical for retinoblastoma.<sup>6,9-11</sup>

Histopathologic examination which is a routine standard procedure is also a gold standard for malignancies, including retinoblastoma. A typical and well-differentiated microscopic cell tumor for retinoblastoma is rosette Flexner-Wintersteiner cell.<sup>12</sup>

The aim of this study was to determine the value of an agreement test between ultrasonography as a preoperative diagnostic tool with histopatologic examination in diagnosing retinoblastoma.

## MATERIALS AND METHODS

This was an observational agreement test. All of the patients with clinically suspected intraocular lesion (retinoblastoma and non-retinoblastoma) and performed ultrasonography examination followed by surgery and histopathologic examination in eye clinic of Dr. Sardjito General Hospital Yogyakarta were eligible into this study. We exclude cases with failed in histopathologic reading.

The ultrasonography examination was performed with Quantel Medical Compact II and a

10 MHz transducer by some operator with supine position of the patient and axial oriented probe (Gain: 90 dB, TGC: 20 dB). The result of ultrasonographic examinations was interpreted by one eye oncologist and the histopathologic reading was performed by one anatomical pathologist (with intraobserver reliability >0.75). The histopathological criteria for retinoblastoma is the presence of a Flexner-Wintersteiner cell. Data were analyzed to determine the agreement value. The protocol of the study has been approved by the Medical and Health Research Committee, Faculty of Medicine, Gadjah Mada University, Yogyakarta.

## RESULTS

There were 33 eyes included in this study. Based on ultrasonography examination, 21 eyes were retinoblastoma suspects and 12 eyes were non-retinoblastoma suspects (4 eyes were endophthalmitis, 2 eyes were panophthalmitis, 2 eyes were hemophthalmus post blunt trauma and 3 eyes were malignancy choroidal melanoma suspects). The mean age of retinoblastoma group was 36.86±39.83 months whereas the non-retinoblastoma group was 36.75±23.58 years. The differences of age between groups could happen because retinoblastoma is the most common intraocular malignancy in infant and childhood, while the intraocular lesion other than retinoblastoma might occur in all age, and majority of cases were adults. Subject characteristics is shown in TABLE 1. The youngest age of retinoblastoma cases was 2 months, whereas calcification started at 41 days of age as studied by Gallenga *et al.*<sup>13</sup>

TABLE 1. Subject characteristics

Characteristics	Retinoblastoma group	Non-retinoblastoma group
Total case	21 eyes	12 eyes
Age	36.86±39.83 months	36.75±23.58 years
Sex		
- Male	10 (47.62%)	8 (58.33%)
- Female	11 (52.38%)	4 (41.67%)
Pre-operative diagnosis	retinoblastoma (21 eyes)	Endophthalmitis (4 eyes) Panophthalmitis (2 eyes) Hemophthalmus post trauma (2 eyes) PHPV (1 eye) Choroidal melanoma (3 eyes)

All cases were divided into 4 groups, true positive, false positive, false negative and true negative (TABLE 2). Based on TABLE 2, the Kappa value for the agreement test was 0.87.

TABLE 2. Results of USG and histopathologic examination

USG	Histopathology		Total
	Rb (+)	Rb (-)	
Rb (+)	20	1	21
Rb (-)	1	11	12
Total	21	12	33

Rb: retinoblastoma

## DISCUSSION

Agreement test for ultrasonography as a pre-operative diagnostic tool compare with histopathological examination in diagnosing retinoblastoma showed a high value (> 0.80). Retinoblastoma is a rare case and its management in developing countries is usually surgical option that associated with physical, financial and emotional as well as medicolegal factors. An excellent agreement is needed in such case.

An excellent agreement value can be achieved because retinoblastoma has a unique and pathognomonic sign by the presence of calcification which was shown as a mass with high internal reflectivity with echo spike more than 80% and has higher density than the sclera and a high internal reflectivity (FIGURE 1), as those that were found in this study. A non-retinoblastoma case did not show calcification with higher density than sclera (FIGURE 2).

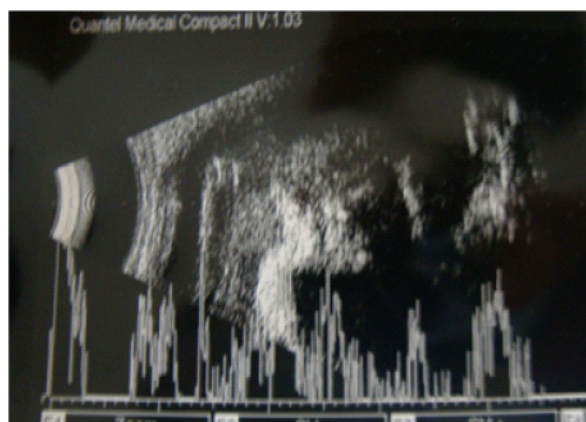


FIGURE 1. Ultrasonography result of retinoblastoma case, there is a density higher than the sclera with high echo spike

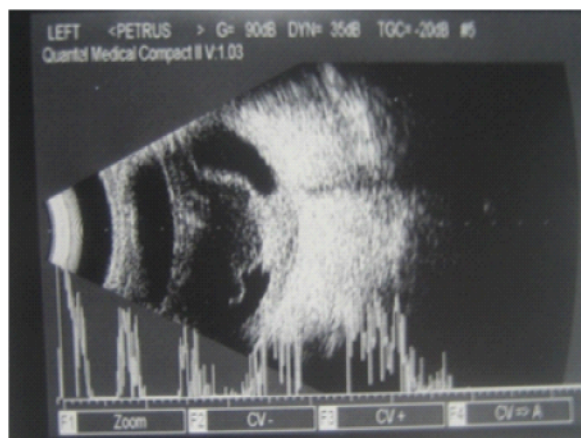


FIGURE 2. Ultrasonography result of non-retinoblastoma case, there is no density higher than the sclera and high internal reflectivity

An ideal agreement for a diagnostic tool compared with the gold standard will give positive result for all of the unhealthy subjects and give negative result for all of the healthy subjects, with Kappa value 1.0. An ideal Kappa value is extremely rare, the false positive and false negative can be found in almost all of the agreement test.<sup>14</sup> In this study, there was 1 eye (3.03%) with false positive and 1 eye (3.03%) also with false negative. The false positive result was similar with the study by Zilelio and Gündüz<sup>15</sup> with 3.79%, but the false negative in their study was higher (9.09%).

The false positive or the false negative in ultrasonography of the eye might be caused by unclear calcification appearance as in diffuse retinoblastoma, a diffused retinal infiltration without distinct lesion. This condition caused difficulties in retinoblastoma diagnosis. Diffuse retinoblastoma is often seen as hemorrhage of the globe, hyphema and or hemophthalmus, inflammation, known as masquerade syndrome.<sup>16,17</sup>

Bhatnagar and Vine<sup>18</sup> reported that only 14% calcification was found in diffuse retinoblastoma based on histopathologic examination, compared with typical retinoblastoma in which >9% calcification was found. Prevalence of diffuse retinoblastoma is about 1.4% from all retinoblastoma cases.<sup>16,17</sup>

Atypical appearance in ultrasonography of diffuse retinoblastoma sometimes might cause false positive case. The ultrasonography examination in retinoblastoma revealed varying degrees of internal

reflectivity according to the amount of calcification in the lesions. The same condition might happened in other cases but it was infrequent. Moskowitz *et al.*<sup>19</sup> reported a case of rhabdomyosarcoma with necrotic tissue and calcification was found in histopathological examination. Calcification in rhabdomyosarcoma is rare, while the intraocular hemorrhage that mimicking a diffuse retinoblastoma is more frequent.

Other conditions that might cause false positive were other intraocular calcifications, such as sclerochoroidal calcification, but this lesion is on the choroid and not extent into intraocular cavity. An advance Coat's disease can be accompanied with calcification in 1%-2% of cases, but there is no mass can be found.<sup>10,20</sup>

## CONCLUSION

The Kappa value of agreement test in this study was 0.87, which means that ultrasonography of the eye as a pre-operative diagnostic tool had a high agreement with histopathological examination as a gold standard.

## ACKNOWLEDGMENT

The authors would like to thank Head Eye Clinic, Department of Ophthalmology, Faculty of Medicine, Gadjah Mada University/Dr. Sardjito Hospital for providing facilities to conduct this study. We are also thank to our colleagues from Department of Anatomy Pathology, Faculty of Medicine, Gadjah Mada University for their valuable assistance in histopathologic examination.

## REFERENCES

1. Aerts I, Rouic LL, Gauthier-Villars M, Brisse H, Doz F, Desjardins L. Retinoblastoma. *Orphanet J Rare Dis* 2006;1(31): 1-11.
2. Abramson DH, Scheffler AC. Update on retinoblastoma. *Retina* 2004; 24(6): 828-48.
3. Chintagumpala M, Chevez-Barrios P, Paysee EA, Plon SE, Hurwitz R. Retinoblastoma: review of current management. *Oncologist* 2007;12:1237-46.
4. Shields JA. Diagnosis and management of orbital tumors. Philadelphia:WB Saunders Company, 1989.

5. Sen KK, Parihar JKS, Saini MM, Moorthy SS. Conventional B-mode ultrasonography for evaluation of retinal disorders. *MJAFI* 2003;59(4):310-2.
6. Guthoff R, Thijssen JM. 1991, History of ultrasound diagnosis. In: Guthoff R editor. *Ultrasound in ophthalmic diagnosis*. New York:Thieme Medical Publishers, Inc., 1991.
7. Poujol J, Varene B. Contribution of echography to the diagnosis of retinoblastoma: A homogeneous B-scan study. *Ultrasound Med Biol* 1985;11(1):171-5.
8. Wirasasmita DA, Sitorus RS, Gumay S. Retinoblastoma:unusual imaging findings. *EuroRad*. Published Nov 3, 1999. Available from: [http://www.euroRad.org//tmp/cache/pdfs/case\\_6516\\_en.pdf](http://www.euroRad.org//tmp/cache/pdfs/case_6516_en.pdf)
9. Evelyn X, Hayden BC, Singh AD. Intraocular tumors. In: Singh AD, Hayden BC, Pavlin CJ editors. *Ultrasound clinics*, 3<sup>rd</sup> vol. Philadelphia:Elsevier Inc., 2008:229-44.
10. Bhende M, Gopal S, Gogi A, Sharma T, Gopal L, Sen P *et al.* The shankara nethralaya: atlas of ophthalmic ultrasound. New Delhi: Jaypee Brothers Medical Publishers Ltd., 2006.
11. Atta HR. Special examination techniques: globe. In: Atta HR editor. *Ophthalmic ultrasound, a practical guide*. Philadelphia:Elsevier Science, 1996.
12. Isidro MA, Roque MR, Aaberg TM, Roque BL. *Emedicine Specialties-Ophthalmology-Retina: Retinoblastoma*. Updated Jan 21, 2009. Available from: <http://emedicine.medscape.com/article/1222849-overvie>
13. Gallenga PE, Mancini A, Di Bastiano W, Colangelo L, Carpineto P, Lobefalo L. Congenital retinoblastoma: appearance of calcification during short-term follow-up. *Ophthalmologica* 1998;212(suppl 1):61-4.
14. Sastroasmoro A, Ismael S. *Dasar-dasar metodologi penelitian klinis*. Jakarta:Sagung Seto, 2002.
15. Zilelio G, Gündüz K. Ultrasonic findings in intraocular retinoblastoma and correlation with histopathologic diagnosis. *Int Ophthalmol* 1995;19(2):71-5.
16. Català-Mora J, Parareda-Salles A, Vicuò-a-muòoz CG, Medina-Zurinaga M, Prat-Bartomeu J. Uveitis masquerade syndrome presenting as a diffuse retinoblastoma. *Arch Sos Esp Oftalmol* 2009;84(9):477-80.
17. Brisse HJ, Lumbroso L, Frneaux PC, Validire P, Doz FP, Quintana EJ *et al.* Sonographic, CT, and MRI imaging findings in diffuse infiltrative retinoblastoma: report of two cases with histologic comparison. *Am J Neuroradiol* 2001;22(5):499-504.
18. Bhatnagar R, Vine AK. Diffuse infiltrating retinoblastoma. *Ophthalmology* 1991; 98(11):1657-61.
19. Moskowitz M, Rosenbaum HT, Sweet R, McLeod C. Calcified embryonal rhabdomyosarcoma with local bone invasion. An unusal case. *Radiology* 1968;91(1):121-2.
20. Hayden BC, Kelley L, Singh AD. Ophthalmic ultrasonography: theoretic and practical consideration. In: Singh AD, Hayden BC, Pavlin CJ editors. *Ultrasound clinics*, 3<sup>rd</sup> vol. Philadelphia:Elsevier Inc., 2008:179-83.