

# Non-ST elevation of acute myocardial infarction caused by probable acute stent thrombosis after drug eluting stent implantation: a case report

Budi Yuli Setianto\*, Bagus Andi Pramono

Department of Cardiology and Vascular, Dr. Sardjito General Hospital/  
Faculty of Medicine, Universitas Gadjah Mada, Yogyakarta, Indonesia

## ABSTRACT

Nowadays, one of the modalities in performing reperfusion in coronary artery disease is percutaneous coronary intervention. Before drug eluting stent era, the problem that occurs the most among interventional cardiologists is restenosis. After drug eluting stent era, restenosis can be reduced significantly. Unfortunately, it further develops another problem, that is called stent thrombosis. Mechanism of stent thrombosis is related to vascular response, thrombosis, coagulation, and clinical factors. Based on our experience, non-ST elevation acute myocardial infarction is caused by probable acute stent thrombosis after drug eluting stent implantation. Therefore, the prevention and therapeutic approaches should be put first in our priority because it can provide a serious complication.

## ABSTRAK

Saat ini, satu modalitas untuk melakukan reperfusi penyakit jantung koroner adalah intervensi koroner perkutan. Sebelum zaman sten berlumur obat, masalah yang paling sering dihadapi dokter jantung intervensi adalah kejadian restenosis. Setelah zaman sten berlumur obat, restenosis dapat diturunkan secara signifikan. Sayangnya, kemudian timbul masalah lain yang disebut dengan trombosis sten. Mekanisme trombosis sten berkaitan dengan respon pembuluh darah, trombosis, koagulasi, dan faktor klinis. Kami laporkan pengalaman kami dengan non-ST elevasi infark miokard akut yang disebabkan oleh trombosis sten akut (*probable*) setelah implantasi sten berlumur obat. Maka dari itu, pencegahan dan pendekatan terapi terhadap masalah ini harus menyadarkan kita, karena dapat menimbulkan komplikasi yang serius.

**Keywords :** coronary artery disease - percutaneous coronary intervention – drug eluting stent - stent thrombosis - acute coronary syndrome

## INTRODUCTION

Restenosis is a weakness of coronary artery stent implantation. The discovery of drug eluting stents (DES) has been able to reduce the incidence of restenosis dramatically. Recently, studies have shown that a decrease in the

incidence of restenosis is often followed by a higher incidence of stent thrombosis, especially late stent thrombosis.<sup>1</sup>

The incidence of stent thrombosis has been reported in several studies, ranging between 0.5 - 2%. Although the incidence is not high, stent

---

\* corresponding author: budyuls@yahoo.com

thrombosis has major clinical effects due to its high risk of myocardial infarction and death. The mortality rate caused by stent thrombosis is relatively high—approximately 45%.<sup>2</sup>

The standard definition of stent thrombosis according to the Academic Research Consortium (ARC) based on the level of documentation are: 1) definite or confirmed (symptoms suggestive of acute coronary syndrome and angiography or pathological confirmation of stent thrombosis), 2) probable (deaths that cannot be explained in 30 days or myocardial infarction without confirmation of stent thrombosis in the target blood vessel angiographically), 3) possible (any unexplained death after 30 days). Meanwhile, based on the time since stent implantation, stent thrombosis can be classified as: 1) early (0 - 30 days after stent implantation), 2) late (> 30 days), 3) very late (> 12 months). Early stent thrombosis is often divided into acute (<24 hours) and sub-acute (> 24 hours-30 days).<sup>3</sup>

Based on our experience, it is reported that non-ST elevation acute myocardial infarction (NSTEMI) is caused by probable acute stent thrombosis after implantation DES in patients with stable angina pectoris.

## CASE REPORT

A 48-year-old male came with stable angina pectoris Canadian Classifications Cardiology Society (CCS) class 2-3 to be performed PCI. Blood tests showed normal limits. The result of the electrocardiographic (ECG) resting showed sinus rhythm and no ST-T changes (FIGURE 1). Chest x-ray showed that the heart and lungs were in the normal range. Transthoracic echocardiography found normal cardiac chamber dimensions, global left ventricular systolic function within the normal range with an ejection fraction of 55%, mild hypokinetic apical, diastolic dysfunction type of relaxation, normal right ventricular systolic function, and normal valves.

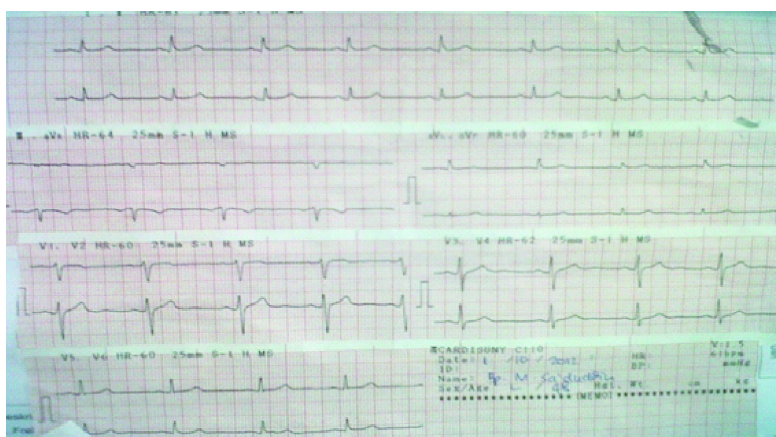


FIGURE 1. ECG recordings at the time of admission showed sinus rhythm and no ST-T changes

Coronary angiography showed normal left main, stenosis of 80% of the length from the proximal to mid left anterior descending (LAD), a big left circumflex (LCX) despite that there

was a 60% stenosis in the mid after obtuse marginal 1 (FIGURE 2). Right Coronary Artery (RCA) stenosis 70-75% in the mid and 60% in the distal before the bifurcation (FIGURE 3).

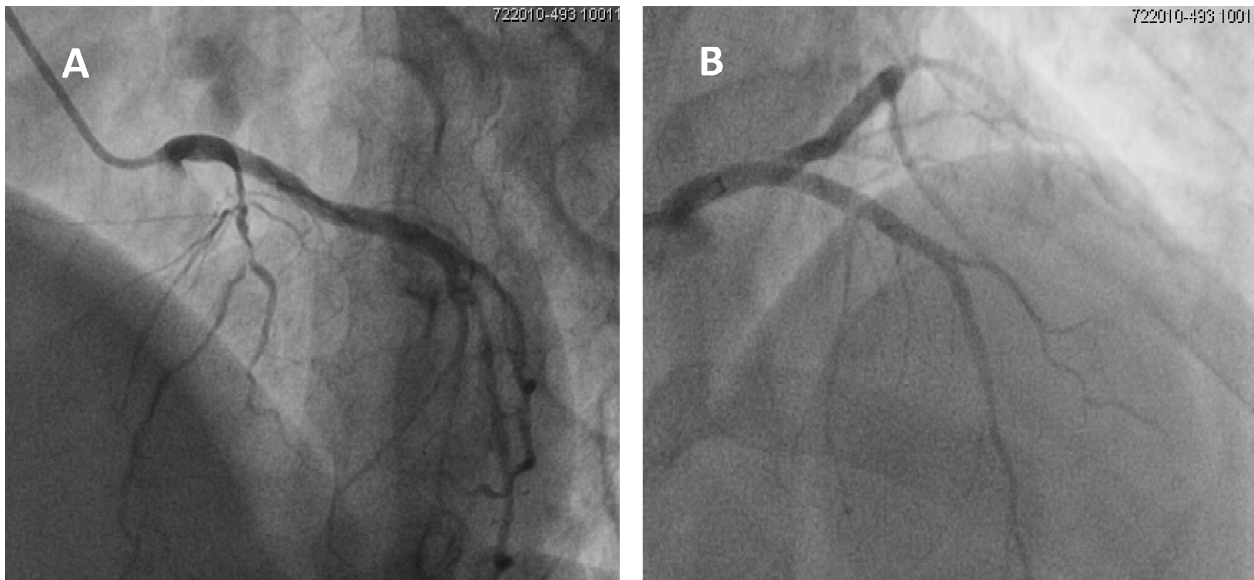


FIGURE 2. A. stenosis of 80% of the length from the proximal to mid LAD, LCX was big but there was a 60% stenosis in the mid after obtuse marginal 1, B. LAD after stent was implanted

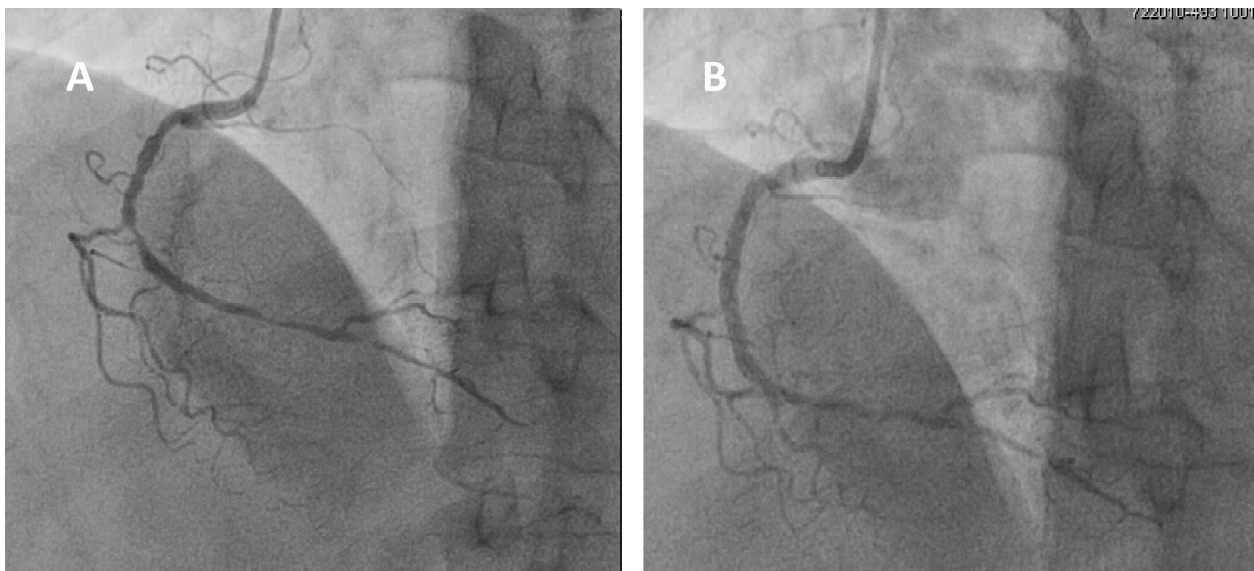


FIGURE 3. A. RCA stenosis 70-75% in the mid and 60% in the distal before the bifurcation, B. RCA after stent implantation

Stent implantation was performed with the target LAD and RCA lesions using drug eluting stents (DES). Shortly after being treated in the Intermediate Cardiovascular Care (IMCC), the patient complained of chest pain, spreading to the left arm, which was not accompanied by a

cold sweat. His vital sign was within normal limits. The patient was given tablets isosorbide dinitrate (ISDN) at dose of 5 mg sublingual. Five minutes later the patient still complained of chest pain, and it was then decided to give him intravenous injection of 2 mg morphine.

Electrocardiograph recordings showed sinus rhythm with slight ST elevation and T wave inversion in leads V2-V3, different with the ECG prior to the procedure (FIGURE 4). Creatin kinase isoenzym MB (CKMB) and

Troponin I levels increased respectively 30 and 0.9. Patient was diagnosed as probable acute stent thrombosis and moved to ICCU for more intensive care. FIGURE 5 shows the ECG when the patient was discharged.

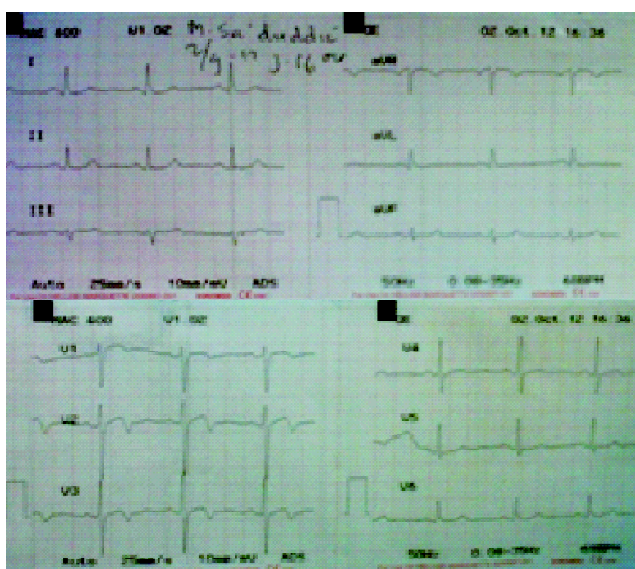

FIGURE 4. Electrocardiograph recordings showed sinus rhythm with slight ST elevation and T wave inversion in leads V2-V3

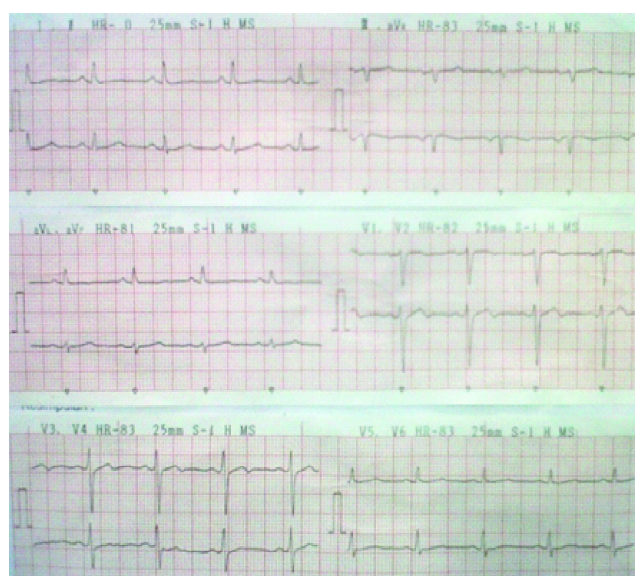


FIGURE 5. Figure 5 shows the ECG when the patient was discharged. No more ST-T changes in leads V2-V3

## DISCUSSION

In two decades, coronary artery stent has been introduced to clinical practice with 2 goals, namely to prevent the incidence of restenosis in one hand and treat the sudden blockage of blood vessels on the other hand. Stent implantation has increased dramatically until a new problem appears, namely stent thrombosis. Aggressive antithrombotic regimens were then introduced. Aspirin is administered with dipyridamole, sulfapyrazone, and oral anticoagulants (acenocoumarin) up to 6 months.

However, the incidence of stent thrombosis is still quite high, ranging from 6% -12%.<sup>4</sup>

Pathophysiology of stent thrombosis includes factors related to the stent, the procedure and the patient (TABLE 1). Stent thrombosis can occur either with a bare metal stent (BMS) or DES. Incidence of immediate (early) thrombosis may be associated with thrombus or dissection at the target lesion, stasis, less stent expansion or a combination of all.<sup>5</sup>

TABLE 1. Factors which cause stent thrombosis<sup>6</sup>

Factors	Precipitant Stent Thrombosis
Stent factors	Hypersensitivity to the drug or polymer Endothelialization incomplete Stent design Stents covered
Patient factors	PCI for acute coronary syndrome / STEMI Diabetes mellitus Renal failure Impaired left ventricular function Premature discontinuation of dual antiplatelet therapy Not responsive to aspirin Not responsive to clopidogrel Previous brachytherapy Malignancies Saphenous vein graft disease
Characteristic lesions	The length of the lesion / stent The diameter of blood vessels / stents Complex lesions (bifurcation lesions, chronic total occlusion) Saphenous vein graft lesion targets Stasis
Procedural factors	Inadequate stent expansion Incomplete stent apposition Stent placement in the necrotic core Residual dissection

Analogous to the BMS era, early stent thrombosis with DES shows an increased risk based on clinical settings, from low risk patients with stable coronary artery disease,

intermediate patients with non-ST acute coronary syndrome to high risk patients with ST elevation myocardial infarction STEMI (TABLE 2).

TABLE 2. Early stent thrombosis risk based on clinical presentation<sup>4</sup>

Stent thrombosis type	Angina stable	UAP/NSTEMI	STEMI
Bare-metal stents, %	0–0.5	1.4–1.6	0–2.9
Drug-eluting stents, %	0.3–0.4	1.2–1.9	0–3.1

The most important risk factor for acute and sub-acute stent thrombosis is the primary stent in STEMI and acute coronary syndrome. Additional risk factor is the length of the stent, congestive heart failure and prothrombogenic status, such as metastatic cancer.<sup>7</sup>

BMS and DES induce platelet adhesion, activation and thrombus formation. Stent gradually covered by endothelial cells does not induce thrombus formation. Cytotoxic drugs are used in the DES to reduce the growth of smooth muscle cells after coronary intervention endothelialization to inhibit this process. Sirolimus and paclitaxel induce the expression of tissue factor on the mounted stent lesions that cause activation of the coagulation system. Polymers are used to release these drugs to cause inflammation of the coronary artery shown by the infiltration of eosinophilia cells in the blood vessel wall which is suggestive to a hypersensitivity reaction, and this also contributes to the prothrombotic environment.<sup>7</sup>

Ten to thirty percents patients with definite stent thrombosis will die in the hospital. In addition, non-fatal acute myocardial infarction is the most common clinical presentation of stent thrombosis (70-80% of cases).<sup>8</sup>

The main objective of the management of stent thrombosis is to achieve effective reperfusion immediately. Type of thrombus in patients with stent thrombosis is different to that of the ordinary acute myocardial infarction patients. Thrombus on stent thrombosis is almost entirely composed of very few platelets and fibrin. As this can lead to an ineffective

thrombolysis for reperfusion, most authors advised emergency PCI for treatment of stent thrombosis.<sup>9</sup>

The introduction of dual antiplatelet therapy with aspirin and a thienopyridine ticlopidine, and shift indication of stent implantation forms bailout to elective case procedures, resulting in a significant reduction of stent thrombosis to <2%, as well as fewer bleeding complications. Attention to the importance of stent implantation technique, proper medication before the procedure and loading with thienopyridine, and the use of antagonists glycoprotein IIb/ IIIa in the setting of acute coronary syndrome results in more decreased stent thrombosis cases.<sup>10</sup>

Several studies have demonstrated the advantages of dual antiplatelet therapy of aspirin plus ticlopidine on early and clopidogrel plus aspirin in the first 4 weeks after BMS implantation. The combination of aspirin and clopidogrel is more widely used because it has fewer side effects. Since the introduction of DES, the result shows that this therapy should be continued for 3-6 months. Recent guidelines recommend dual antiplatelet therapy 12 months after implantation of DES. Some authors suggest that this therapy should be continued until more than 12 months but there is no data available to support the safety and benefits of this combination.<sup>9</sup>

The basis of the prevention of stent thrombosis is doing the best PCI procedures, including good stent expansion and apposition. In this context, the role of intravascular ultrasound should be considered. The role of

antiplatelet therapy in the prevention of early stent thrombosis is already well known.<sup>11</sup>

Several studies have shown the benefits of clopidogrel loading dose. In the setting of acute coronary syndrome, it should be given 600 mg loading dose. Even Montalescot *et al.*<sup>12</sup> recommends that 900 mg loading dose of clopidogrel can improve platelet inhibition. TRITON TIMI-38 study showed inhibition of platelet aggregation with prasugrel better than standard therapy with clopidogrel and lowering the incidence of stent thrombosis significantly. However, a higher incidence of major bleeding still shows a lack of systematic prescribing prasugrel, so it is not recommended for routine practice.<sup>9</sup>

Several risk factors for the occurrence of stent thrombosis were found in these patients, namely kidney failure and malignancy. Patients' creatinine level was 2.13 and these patients had a history of lung carcinoma. Both of these factors lead to a higher prothrombotic status. The results of coronary angiography showed a long lesion in LAD which increases the risk of stent thrombosis. ECG recording after the procedure showed ST segment changes in leads V2-V4, according to the LAD vascularization. The presence of these risk factors may explain why patients had a stable clinical setting at first and then suffered stent thrombosis after DES implantation. The clinical presentation of stent thrombosis in these patients was non-fatal acute myocardial infarction, which is most often the case.

Working diagnosis of these patients was probable acute stent thrombosis, with the clinical presentation of acute myocardial infarction as evidenced by typical chest pain, ST segment changes on ECG dynamic and rising levels of cardiac enzymes. Management of these patients is similar as NSTEMI management in general: being given aspirin and clopidogrel

loading dose, continuing with dual antiplatelet therapy, beta receptor blockers and heparin. In these patients percutaneous coronary intervention had not been done, because there was no ST elevation. After being treated for 3 days in ICCU, the patients were allowed to go home.

## CONCLUSION

A case of NSTEMI caused by probable acute stent thrombosis after percutaneous coronary intervention has been reported. There are some risk factors found associated with the stent thrombosis, i.e. elevated levels of creatinine, prothrombotic status because of a history of lung malignancy and the presence of long lesions in LAD. Although the incidence of stent thrombosis was low, it should be paid attention quickly because mortality and the incidence of acute myocardial infarction are high. Handling thrombosis at the beginning is very important, as to prevent the incidence of stent thrombosis in patients with stent implantation, although the clinical presentation shows a low risk for thrombosis.

## ACKNOWLEDGEMENTS

Authors would like to thank the Head and Staff of ICCU Dr. Sardjito General Hospital, for permission and assistance to conduct this case report. We would also like to thank the reviews for reviewers.

## REFERENCES

1. Grove ECL, Kristensen SD. Stent thrombosis: definitions, mechanisms and prevention. *Hemodinamiadelsur* [serial online] 2009. Available from: [http://www.hemodinamiadelsur.com.ar/journals/journal\\_140.asp](http://www.hemodinamiadelsur.com.ar/journals/journal_140.asp)
2. Lakovou I, Schmidt T, Bonizzoni E, Ge L, Sangiorgi GM, Stankovic G, *et al.* Incidence, predictors, and outcome of thrombosis after



- successful implantation of drug-eluting stents. *JAMA* 2005; 293(17):2126-30.
3. Food and Drug Administration. Circulatory System Devices Panel Meeting. 2006 December 7-8, Washington DC.
  4. Cook S, Windecker S. Early stent thrombosis: past, present, and future. *Circulation*. 2009;119:657-9.
  5. Fujii K, Carlier SG, Mintz GS. Stent under expansion and residual reference segment stenosis are related to stent thrombosis after sirolimus-eluting stent implantation: an intravascular ultrasound study. *J Am Coll Cardiol* 2005;45:995- 8.
  6. Holmes DRJ, Kereiakes DJ, Garg S, Serruys PW, Dehmer GJ, Ellis SG, *et al*. Stent thrombosis. *J Am Coll Cardiol* 2010; 56(17):1357-65.
  7. Luscher TF, Steffel J, Eberli FR, Joner M, Nakazawa G, Tanner FC, *et al*. Drug-eluting stent and coronary thrombosis: biological mechanisms and clinical implications. *Circulation* 2007; 115(8):1051-8.
  8. Mauri L, Hsieh WH, Massaro JM. Stent thrombosis in randomized clinical trials of drug-eluting stents. *N Engl J Med* 2007;356:1020-9.
  9. Lemesle G, Delhayea C, Bonello L, Labriolle A, Waksman R, Pichard A. Stent thrombosis in 2008: Definition, predictors, prognosis and treatment. *Archives of Cardiovascular Disease*. 2008; 101:769-77.
  10. Leon MB, Baim DS, Popma JJ, Gordon PC, Cutlip DE, Ho KK, *et al*. A clinical trial comparing three antithrombotic-drug regimens after coronary-artery stenting. *N Engl J Med*. 1998; 339:1665-71.
  11. Silber S, Albertsson P, Aviles FF. Guidelines for percutaneous coronary interventions. The Task Force for Percutaneous Coronary Interventions of the European Society of Cardiology. *Eur Heart J* 2005; 26:804-47.
  12. Montalescot G, Sideris G, Meuleman C. A randomized comparison of high clopidogrel loading doses in patients with non-ST-segment elevation acute coronary syndromes: the ALBION (Assessment of the Best Loading Dose of Clopidogrel to Blunt Platelet Activation, Inflammation and Ongoing Necrosis) trial. *J Am Coll Cardiol* 2006; 48:931-8.