



Research article

A Landmark Approach to Aphrodisiac Property of *Abelmoschus manihot* (L.)

K.K. Rewatkar^{1,2}, Naiyer Shahzad², Ayaz Ahmed², Mohd. Irfan Khan², N. Ganesh^{1*}

*Corresponding author:

N. Ganesh

1. Head of Research,
Department of Research
Jawaharlal Nehru Cancer
Hospital and Research Center
Bhopal (M.P.)

Contact no: +919826321616

E-mail:-

[nganesh_research2\(at\)yahoo.co.in](mailto:nganesh_research2(at)yahoo.co.in)

2. School of Pharmacy and
Medical Sciences, Singhania
University, Pachari Bari,
Jhunjhunu (Raj.)

Abstract

The *Abelmoschus manihot* (L.) commonly referred to as “Junglee bhindi” is widely used to control fertility, depression and anxiety in traditional Chinese medicine and has potential therapeutic benefit for cardiovascular diseases associated with diabetes mellitus. The present study is aimed to investigate the effect of 95% ethanolic extract of *Abelmoschus manihot* on general mounting frequency, intromission frequency, penile erection index along with body weight/organ weight and sperm count on sexually normal male mice. Two doses i.e. 100 and 200 mg/kg b.w. of ethanolic extract administered to Swiss albino mice, showed pronounced anabolic and spermatogenic effect in animals of respective groups. There was a remarkable increase in sperm count and penile erection index and also improved sexual behavior of male mice by increased mount and intromission frequency.

The result of the present study signified for sexual enhancing capacity of the drug *Abelmoschus manihot* is an individual and also holds good aphrodisiac property when compared with standard drug. It was noticed that a 200 mg/kg b.w. dose of *Abelmoschus manihot*, the performance rate enhances without any side effect. Therefore, the conclusion suggests that the *Abelmoschus manihot* will be a drug of choice or alternative therapy for a marketed product. Which may help the population to lead their sexual life perfectly with full of pleasure to interact body, mind and soul.

Keywords: *Abelmoschus manihot*, Aphrodisiac, Mounting frequency, Intromission frequency, Penile erection index.

Introduction

Sexual function is an important component of human quality of life and subjective well being. Sexual problems are wide spread and adversely affect mood, well being, and interpersonal functioning. Mainly, sexual problems are related to desire and male erectile dysfunction [1].

An aphrodisiac is a substance which is used in the belief that it increases sexual desire. The name

comes from Aphrodite, the Greek goddess of sensuality and love. Many herbs are renowned for its medicinal and ornamental properties. Since immemorial medicinal herbs are practiced as a traditional system to treat various ailments [2]. Aphrodisiac drugs extracted from medicinal plants possess the vital regulation of sexual enhancement. Ayurvedic literature also refers a common medical term “Vajikarana” (literally,

[doi:10.5138/ijpm.2010.0975.0185.02044](https://doi.org/10.5138/ijpm.2010.0975.0185.02044)

©arjournals.org, All rights reserved.

horse making), the medicine that confers upon a man sexual power similar to that of a stallion [3].

Many clinical studies on medicinal plants have proven aphrodisiac activity. They possess anabolic activity and stimulate the growth hormones. Similarly a number of plants, *Microstylis wallichii*, *Roscoea procera*, *Mucuna pruriens*, *Curculigo orchoides*, *Datura stramonium*, *Anacyclus pyrethrum*, [4,5].

Abelmoschus manihot is found as wasteland and crop weed in Chhattisgarh. Its Hindi name is Janglee Bhindi but in Chhattisgarh it is popularly known as Phuttu Bhaji.

A. manihot (L) medik is a native to the Old World tropics and has been naturalized in some wild New World tropical areas. It is an edible hibiscus of the Malvaceae (Mallow) family, and is also used as a staple in folk medicine in Papua New Guinea, Vanuatu, Fiji, New Caledonia, or china for variety of purpose. It has been also used for the control of fertility, to ease childbirth, to stimulate lactation, to help against menorrhagia to induce abortion and to prevent osteoporosis [6,-

,11]. Phytoconstituents mainly reported the total flavanoids in the flower of *A. manihot*. Hyperoside, isoquercetin, and quercetin, 3'-glucosides are important ingredient in total flavanoids [12].

The present investigation were undertaken with a view to explain the effect of 95% ethanolic extract of *A. manihot* as an aphrodisiac.

Material and method

Animal stock: The experimental protocol was approved by the Institutional Animals Ethics Committee (IAEC) of Jawaharlal Nehru Cancer Hospital and Research Centre Bhopal, (M.P.) India. and care of laboratory animals was taken as per CPCSEA guidelines (Reg. No. 500/1A/2002/CPCSEA). The male Swiss albino mice of (25-30 gm.) were used for the study. The animals were housed in polypropylene cages, under standard laboratory conditions of temperature (25±2°C) and fed with standard rodent pellet (Brooke Bond-Lipton, India) diet and water ad libitum at 24±2 °C and day-night cycle 06:00 h to 18:00 h. and relative humidity (60±5%).

Plant material and extraction: The dried seeds of *Abelmoschus manihot* Linn (Family-Malvaceae) were procured at the month of September to October 2009, from the herbal garden of Jawaharlal Nehru Cancer Hospital & Research Centre, Bhopal (M.P.) India. The seeds were shade dried at room temperature, crushed to moderately fine power and Powered seeds were weighed and subjected to extraction with petroleum ether in a separating funnel. The extraction was continued till the defatting of the material had taken place [13]. The defatted marc of the drugs was subjected to extraction with 95% ethanol in a Separating funnel. The extraction was continued for a period of 4-5 days. Complete extraction was ensured by clear or transparent the solution in separating funnel. The extracted material was removed from the separating funnel and the extract was concentrated and finally dried using vaccum evaporator to remove last traces of ethanol [5].

Preparation of test samples

Ethanolic extract of *Abelmoschus manihot* were prepared by triturating 2 gm extract with small quantity of 2% Tween 80 in a glass pestle mortar and then volume was made up to 10 ml with distilled water which gives a concentration of 200 mg/ml. Similarly sildenafil citrate was prepared using arachis oil separately giving a suspension of 0.5 mg/kg b.w. for oral use [2].

Treatment: The animals were divided in 4 groups of 4 Swiss albino mice in each. Group I animals served as control and received only vehicle i.e. 2% Tween 80 suspension. Group III and Group IV was administered orally with 100 and 200 mg/kg/b.w per day of the ethanolic extract of *Abelmoschus manihot* suspended in 2% Tween 80. Group II was given orally 0.5 mg/kg b.w of testosterone suspended in arachis oil twice weekly and served as positive control for anabolic studies. The doses used in the study were selected as per the previous study by (Linlin WU 2007) [12].

Studies Performed:

Effect on sexual organ weight: After 7 days treatment the body weight of animals was recorded. The animals were sacrificed by cervical dislocation and testis, seminal vesicle, were carefully removed and weight of each organ was determined [14, 15].

Histological study: Histological studies were carried out to determine the effect of drug administration on the spermatids and other testicular cells. The testes, epididymis and seminal vesicle of animals of all respective groups were dissected out and cut into small pieces and fixed using Bovine's fixative for 6 hours. Then dehydrates with varying percentage of ethanol and embedded in paraffin wax for histological studies. Sections were cut (5µm) thickness using rotary microtome (MATCHLESS) blade and sections were stained by haematoxylin stain (CDH, Mumbai). Photomicrographs were taken by image analyzer (Motic 2.8) [14, 15].

Sexual behavior analysis: The Healthy and sexually experienced male swiss albino mice (25-35gm) were selected for the study. They were divided into 6 groups of 4 animals each and kept singly in separate cages during the experiment. Group I represented the control group which received 10 ml /kg of distilled water orally. Group III and IV received suspension of the ethanolic extract of plant material orally at the doses of 100 and 200mg/kg body weight, respectively, daily at evening for 7 days. Group II served as standard and was given suspension of sildenafil citrate orally at the dose of 5mg/kg body weight, one hour prior to the commencement of the experiment. Since the male animals should not be tested in unfamiliar circumstances, the animals were bring to the laboratory and exposed to deem light (in 1 watts fluorescent tube) at the stipulated time of testing daily for six days before the experiment. The experiment was carried out on the 7th day after commencement of the treatment of the male animals. The experiment was conducted at 20:00 hrs, in the same laboratory and under the light of

same intensity. The receptive female animals were introduced in to the cages of male animals with one female to one male. The observation for mating behavior was immediately commenced and continued for first two mating series. The test was terminated if the female failed to evince sexual interest. If female do not show receptivity it is replaced by another artificially warmed female. The occurrence of events and phase of mating are called out to be recorded. Later, the frequencies and phases are determined in terms of mounting frequency (MF), intromission frequency (IF), and post ejaculatory interval (PEI). The values for the observed parameters were statistically analyzed by using (ANOVA) method [16-18].

Penile Erection Index: Penile erection was determined when the rats bent down to lick their erect penis during the observation period. Penile erection index was determined by multiplying the percentage of mice exhibiting at least one episode of penile erection during observation period with the mean number of penile erection [3].

$\text{PEI} = \% \text{ of mice exhibiting penile erection} \times \text{Mean number of erections}$

Sperm count: The epididymides from each mice were removed. Epididymal spermatozoa were quickly obtained by punctures of both caput and cauda epididymis with a disposable hypodermic needle (gauge 21). Samples of approximately 1:2 of fluid from the epididymal lumens of caput and cauda were collected using microcapillary pipettes and transferred into sample vials containing 1 ml phosphate-buffered saline [19]. Motility of cauda epididymal spermatozoa was determined in a haemocytometer chamber after 5-min incubation at room temperature [20]. The epididymal fluid from both caput and cauda segments was then subjected to a 20-fold dilution with a spermicidal solution containing 5 gm. of NaHCO₃ and 1 ml of 35% formaldehyde in 100 ml physiological saline. The sperms were counted using a Neubauer haemocytometer [21, 22].

Statistical Analysis

Data were expressed as mean± SEM. (standard error of mean) and statistical analysis was carried out using Tukey Kramer test. The values were calculated and analysed using Graph Pad InStat 3.06 software run on Windows XP (Microsoft Corp.).

Results

Anabolic effect: The effect of the ethanolic extract of *Abelmoschus manihot* on sexual organ and body weight is summarized in Table 1. Treatment with ethanolic extract of *Abelmoschus manihot* (200 mg/kg b.w.) p.o., (45.02±1.035) increase in body weight, (0.30±0.0064) increase in testis and (0.3±0.0091) increase weight in seminal vesicle significantly, while (100 mg/kg b.w.) p.o., showed an moderately increment of (39.62±1.173) in body weight, (0.27±0.0047) increase in testis and (0.28±0.0094) increase weight in case of seminal vesicle, after 7th days treatment. Testosterone administration produced (38.07±0.5138) increase in body weight, (0.28±0.0047) increase in testis and (0.28±0.021) in case of seminal vesicle as compare to control (31.9±0.5951, 0.22±0.012, 0.20±0.019) Table 1.

was revealed that sperm count of male mice fed with *Abelmoschus manihot* 200 mg/kg b.w. was significant equal to the standard, i.e. (13.41±0.20) and (13.16±0.30) respectively. Table.1.

Sexual behavior:

Sexual behavior of the animals was also improved, when non oestrus female mice were paired with males upon treated with repeated doses of the plant drugs (water suspension or extract). The control mice received the vehicle in an identical manner. The effect of repeated oral administration (daily for 7th days) of relatively identical doses of water suspension as a vehicle and 100 mg/kg body weight & 200 mg/kg body weight of the *Abelmoschus manihot* plant seed extract is given (Table 2) treated male mice, 1 hr after the final treatment displayed excessive sexual performance, as compared to control during the period of different parameters studies. The observation for mount frequency revealed an significantly increase in mounting frequency 67±1.826 in *Abelmoschus manihot* seed extract (200 mg/kg b.w.), 65.25±2.592 in *A. manihot* (100 mg/kg b.w.) and 69±1.581 in standard. as

Table: 1 Effect of ethanolic extract of *Abelmoschus manihot* on body/organ weight/sperm counts of Swiss albino mice.

S. No	Group	Body Weight (gm)		Weight of Testis (gm)	Weight of Seminal Vesicle (gm)	Sperm count (10 ⁶ /ml)
		0 day	7 days	7 days	7 days	7 days
1.	Control	31.01±0.55	31.9±0.59	0.22±0.01	0.20±0.02	06.65±1.43
2.	STD.	28.67±1.85	38.07±0.51**	0.28±0.01***	0.28±0.02**	13.41±0.20***
3.	AM100	30.68±0.43	39.62±1.17***	0.27±0.00**	0.28±0.01**	10.13±0.55*
4.	AM200	33.18±1.24	45.02±1.03***	0.30±0.01***	0.3±0.01***	13.16±0.30***

All values are expressed as mean ± S.E.M., P* < 0.05 and P** < 0.01, P*** < 0.001, Considered significant as compared to control;

Control: No drug; AM 100: *Abelmoschus manihot* extract (100 mg/kg b.w) p.o., AM 200: *Abelmoschus manihot* extract (200 mg/kg b.w) p.o., standard group sildenafil citrate (0.5 mg/kg b.w.).

Sperm count:

Sperm count is the major parameter to signature the fertility in-situ according to Table No.1, It

compared to 36.75±11.265 in control. The intromission frequency was also significantly increased and was found to be 5.75±0.478 in *A.*

manihot (200 mg/kg), 4.75 ± 0.478 in *A. manihot* (100 mg/kg), and 6 ± 0.408 in standard treated group compared to 2.5 ± 0.500 in control group animals. Penile erection index an indicator of enhanced vascular function in penile tissue, was also significantly increased 12.75 ± 0.4787 in treated group *A. manihot* (200 mg/kg) b.w., 10.25 ± 0.6292 moderately significant increased in *A. manihot* (100 mg/kg) b.w., and 13.5 ± 0.6455 significantly increased in standard, as compared to 7.75 ± 0.6292 in control group animals. Table 2.

Table: 2 Effect of ethanolic extract of *Abelmoschus manihot* on sexual activity in Swiss albino mice

S. No.	Group	Mounting Frequency (MF)	Intromission Frequency (IF)	Penile Erection (PEI)
1.	Control	36.75 ± 11.265	2.5 ± 0.0500	7.75 ± 0.6292
2.	STD	69. $\pm 1.581^{**}$	$6 \pm 0.408^{**}$	$13.5 \pm 0.6455^{***}$
3.	AM 100	65.25 $\pm 2.594^{**}$	4.75 ± 0.478	$10.25 \pm 0.6292^*$
4.	AM 200	67. $\pm 1.826^{**}$	$5.75 \pm 0.478^{**}$	$12.75 \pm 0.4787^{***}$

All values are expressed as mean \pm S.E.M., $P < 0.05$ and $P^{**} < 0.01$, $P^{***} < 0.001$, ns = $P > 0.05$ Considered significant as compared to control; Control: No drug; AM 100: *Abelmoschus manihot* extract (100 mg/kg b.w) p.o., AM 200: *Abelmoschus manihot* extract (200 mg/kg b.w) p.o., HE 100: *Hibiscus esculentus* extract (100 mg/kg b.w.) p.o, STD: standard group sildenafil citrate (0.5 mg/kg b.w.).

Histological studies:

The sections of the testis of the control group when compared with treated group animals showed observable differences in various stages of spermatogenesis observed in different treated groups. In control group animals, all stages of spermatogenesis were clearly observed (Fig.1.), viz. spermatids, seminiferous tubules, primary spermatocytes, secondary spermatocytes and spermatozoa, beside connective tissue, blood vessels, lymph ducts, Sertoli cells and Leydig’s cells were observable and distinct. The proliferation was evidently more perceptible in case of treated group animals as compared to control.

Ethanolic extract of *Abelmoschus manihot* 100 and 200 mg/kg treated groups showed increase in the diameter of seminiferous tubules varied within a range. The tubules having maximum diameter, were not abundant and well within range. Sertoli cells had many cytoplasmic processes which were normal in size. Spermatozoa were embedded in the sertoli cells and showed normal cytoplasmic granulation. Leydig cells had

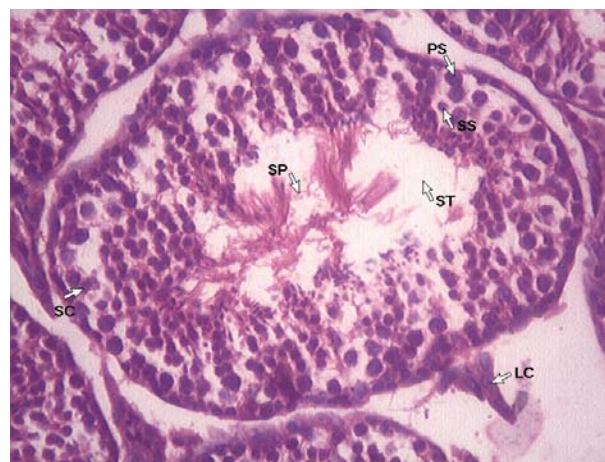

Fig.1. Histoarchitecture of testis of control group

normal nuclear size. Luminal part of the tubule were normal in number with bundles of spermatozoa. Spermatozoa with long tail with small distinct head were more visible (Fig. 3 and 4). The extract treated group animals showed pronounced effects in terms of testis weight and histological alterations. Since the weight and size of the testis was greater in extract treated groups almost all seminiferous tubules showed greater diameter. Lumen of every seminiferous tubules had enormous number of spermatozoa. Sertoli cells were enlarged highly processed and rich in nutrients as evidenced by highly granulated cytoplasm. This was the normal response of the sertoli cells when they were in readiness for providing nutritional supplementation to large number of spermatozoa [23]. Almost all leydig cells showed hypertrophy with enlarged nucleus and darkly stained cytoplasm. Increment in the volume of cells and nucleus was strongly suggestive of steroid synthesis under the direct or indirect influence of the drug. Almost all tubules were overcrowded with sperm bundles. In some

tubules, spermatids were found scattered amidst spermatozoa. The blood vessels of testis were slightly dilated. Histoarchitecture of testosterone treated group also exhibited similar profile. Increased spermatogenesis was evident by high number of spermatozoa in seminiferous tubules and which is evident by increase in spermatogenic elements as compared to control (Fig. 2).

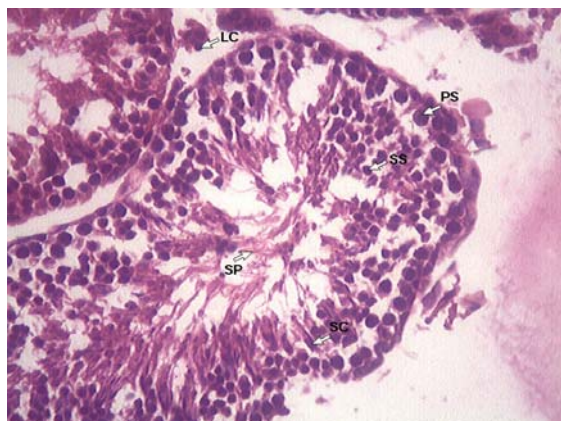


Fig. 2 Histoarchitecture of testis of standard group

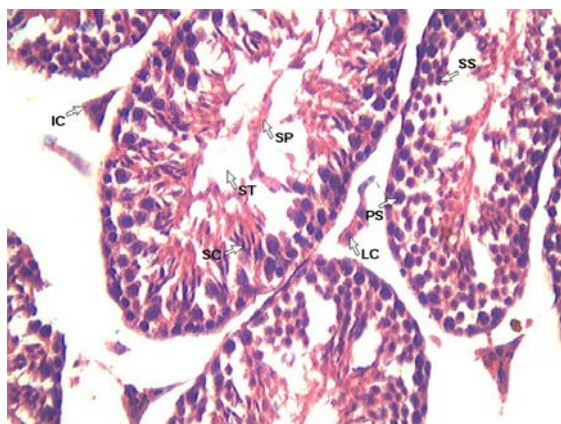


Fig. 3. Histoarchitecture of testis of A.M. extract 100 mg/kg treated group

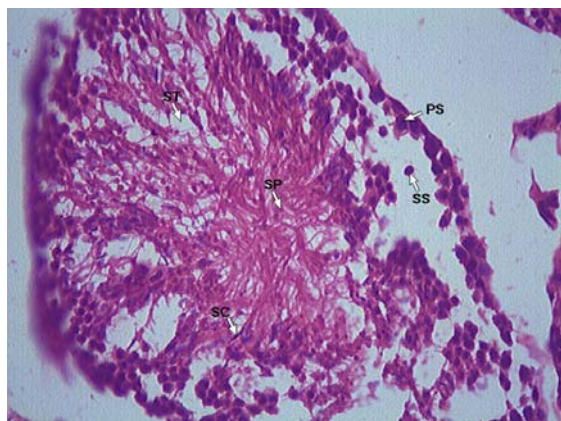


Fig. 4. Histoarchitecture of testis of A.M. extract 200 mg/kg treated group

Discussion

The present study of *Abelmoschus manihot* were tested in animal experimentation for its effect on body/organ weight and sexual behavior and Sildenafil citrate were used as the standard referent.

The study showed that 95% ethanolic extract of *Abelmoschus manihot* possesses significant body/organ weight and sexual function enhancing activity as observed in body/organ and sexual behavior tests. Sexual behavior test revealed that the test drug *Abelmoschus manihot* significantly increased the mounting frequency (MF), intromission frequency (IF) and penile reflex (PEI), as compared to control and the body/organ weight, weight of testis, weight of seminal vesicle and sperm count is also increased as compared to control.

Therefore, the present study suggest that the short term use of *Abelmoschus manihot* extract have shown good aphrodisiac property and have not shown any tissue level toxicity. However, continue dosing to be required to know the acute toxicity and drug validation can be performed accurately.

As *Abelmoschus manihot* hold increased sexual performance rate without any side effect. Therefore, the conclusion suggestive of the *Abelmoschus manihot* will be a drug of choice or alternative therapy for a marketed product. Which may help the population to lead their sexual life perfectly with full of pleasure to interact body, mind and sole.

References

1. Adimoelija A, Adaikan PG., Protodioscin from herbal plant *Tribulus terrestris L.* improves male sexual functions possibly via DHEA. International Journal of Impotence Research, (1997), 9, 1, S 64.
2. Suresh Kumar P.K, Subramoniam A, Pushpangadan P. Aphrodisiac activity of *Vanda Tessellata (Roxb.)* Hook. Ex don extract in Male Mice. Indian Journal of pharmacology, (2000), 32, 300-304.

3. Chauhan NS and Dixit VK., Spermatogenic activity of Rhizomes of *Curculigo orchiodies* Garten in male rats. International Journal of Applied Research in Natural Products (2008), 1 (2): 26-33.
4. Singh G. and Mukharjee T., Herbal aphrodisiac, A review Indian Drugs., (1998), 34, 175-182.
5. Sharma Vikas, Thakur Mayank, Chauhan Nagendra Singh, Dixit Vinod Kumar. Evaluation of the Anabolic, aphrodisiac and reproductive activity of *Anacyclus Pyrethrum* DC in male mices. Sci. Pharm. (2009), 77, 97-110.
6. Ritchie HE., The safety of herbal medicine use during pregnancy. Frontiers in fetal health, (2001), 3, 259–266.
7. Buck Louis GM, Lynch CD, Cooney MA. Environmental influences on female fecundity and fertility. Semin Reproductive Medicine, (2006), 24, 147–55.
8. Liu IM, Liou SS, Cheng JT: Mediation of beta-endorphin by myricetin to lower plasma glucose in streptozocin-induced diabetic rats. *Journal of Ethnopharmacology* (2006), 104, 199-206.
9. Bourdy G, Walter A. Maternity and medicinal plants in Vanuatu. In The cycle of reproduction, *Journal of Ethnopharmacology*, (1992), 37, 179–96.
10. Preston SR. Aibika/Bele-*Abelmoschus manihot* (L.) Medik. In: CAB ABSTRACTS. CAB International, (1998), 97.
11. Puel C, Mathey J, Kati-Coulibaly S, Davicco M J, Lebecque P, Chanteranne B, Preventive effect of *Abelmoschus manihot* (L.) Medik on bone loss in the ovariectomised rats. *Journal of Ethnopharmacology*, (2005), 99, 55–60.
12. Lin-lin WU, Xin-bo YANG, Zheng-ming HUANG, He-zhi LIU, Guang-xia WU. In vivo and in vitro activity of hyperoside extracted from *Abelmoschus manihot* (L) medic. *Acta Pharmacologica Sinica* (2007), 28 (3), 404-409.
13. Pandey Milind, Pathak Anupam. Investigation of Aphrodisiac potential Of *Blepharis edulis* Linn.(*Utangan*) claimed by Tribals Of Malwa Region of Madhya Pradesh. International Journal of Chem Tech Research (2009), 1 (3), 769-776.
14. Saxena S, Dixit VK., Role of total alkaloids of *Mucuna pruriens* Baker in spermatogenesis in male rats. Indian Journal of Natural Product, (1987), 3, 3–7.
15. Thakur M, Dixit VK., Effect of *Chlorophytum borivilianum* on androgenic & sexual behavior of male rats. Indian Drugs, (2006), 43, 300–306.
16. Ratansooriya W. D, Fernanda T.S.P. Effect of black tea brew of *Camellia sinensis* on sexual competence of male rats. *Journal of Ethnopharmacology* (2008), 118, 373-377.
17. Dewsbury DA & Davis HN Jr. “Effect of reserpine on Copulatory behavior of male rats”, *Physiological Behavior.*, (1970), 5, 1331- 1333.
18. Szechtman H., Moshe H., Rabi S., “Sexual behavior pain sensitivity and stimulates endogenous opioids in male rats”, *European Journal of Pharmacology*, (1981), 70, 279-285
19. Hinton, B.T., Doll, H.M. and Setchell, B.P. Measurement of the motility of rat spermatozoa collected by micropuncture from the testes and from different regions along the epididymis. *Journal of Reproduction and Fertility*, (1979) 55, 167-172.
20. Pholpramool, C. and Chaturapanich, G. Effect of sodium and potassium concentrations and pH on the maintenance of motility of rabbit and rat epididymal spermatozoa. *Journal of Reproduction and Fertility*, (1979), 57, 245-251.
21. Biggers, J.D., Whittam, W.K. and Whittingham, O.G., The culture of mouse embryos in vitro. In: J.D. Daniel (Ed.), *Methods in Mammalian Embryology*. Freeman, San Francisco, (1971), 86-117.
22. Seema Parveen, Suwagmani Das, Chandra Prakash Kundra, B.M.J. Pereira, A

- comprehensive evaluation of the reproductive toxicity of *Quassia amara* in male rats *Reproductive Toxicology*, (2003), 17, 45–50.
23. Majumdar SS, Tsuruta J, Griswold MD, Bartke A..Isolation and Culture of Sertoli Cells from the Testes of Adult Siberian Hamsters: Analysis of Proteins Synthesized and Secreted by Sertoli Cells Cultured from Hamsters Raised in a Long or a Short Photoperiod. *Biol Reprod* (1995), 52, 658-666. 291-296.