



**UNIVERSIDADE ESTADUAL DE CAMPINAS
SISTEMA DE BIBLIOTECAS DA UNICAMP
REPOSITÓRIO DA PRODUÇÃO CIENTÍFICA E INTELLECTUAL DA UNICAMP**

Versão do arquivo anexado / Version of attached file:

Versão do Editor / Published Version

Mais informações no site da editora / Further information on publisher's website:

http://www.scielo.br/scielo.php?script=sci_abstract&pid=S0004-27492019000500381

DOI: 10.5935/0004-2749.20190076

Direitos autorais / Publisher's copyright statement:

©2019 by Conselho Brasileiro de Oftalmologia. All rights reserved.

DIRETORIA DE TRATAMENTO DA INFORMAÇÃO

Cidade Universitária Zeferino Vaz Barão Geraldo

CEP 13083-970 – Campinas SP

Fone: (19) 3521-6493

<http://www.repositorio.unicamp.br>

Prospective evaluation of micropulse transscleral diode cyclophotocoagulation in refractory glaucoma: 1 year results

Avaliação prospectiva do laser de diodo micropulsado em pacientes com glaucoma refratário: resultados de um ano de seguimento

Alessandro Adad Jammal¹, Danilo Campos Costa¹, José Paulo Cabral Vasconcellos¹, Vital Paulino Costa¹

1. Department of Ophthalmology, Universidade Estadual de Campinas, Campinas, SP, Brazil.

ABSTRACT | Purpose: To evaluate the effectiveness in intraocular pressure reduction and safety of micropulse transscleral diode cyclophotocoagulation in refractory glaucoma. **Methods:** We prospectively evaluated a case series of 21 eyes of 21 consecutive patients with refractory glaucoma treated with micropulse transscleral diode cyclophotocoagulation at 12-month follow-up. The total treatment time was at the discretion of the surgeon, considering baseline and target intraocular pressure and glaucoma diagnosis. Intraocular pressure, inflammation, visual acuity, and number of medications were monitored. Success was defined as intraocular pressure between 6 and 21 mmHg and/or 30% reduction from baseline intraocular pressure with or without the use of antiglaucoma medications. Visual acuity loss was defined as a loss of ≥ 2 lines of vision on the Snellen chart or a ≥ 2 -level decrease in visual function in patients with nonmeasurable chart acuity. **Results:** The mean age was 61.04 ± 12.99 years, and 11 (52.4%) patients were male, with most (95%) patients showing low visual acuity at baseline (count fingers or worse). The mean intraocular pressure was 33.38 ± 15.95 mmHg, and the mean number of medications was 3.5 ± 1.1 at baseline. After 1, 3, 6, and 12 months, 76.19%, 57.14%, 55.56%, and 66.67%, respectively, of the patients were classified as treatment successes. Seven (33.3%) patients required new laser treatment and were considered treatment failures. The mean intraocular pressure reduction was $44.72\% \pm 29.72\%$ in the first week and $41.59\% \pm 18.93\%$ at the end of follow-up

($p=0.006$). The mean number of medications significantly dropped to 2.00 ± 1.7 at the 12-month visit ($p=0.044$). Complications included hypotony (4.8%), intraocular inflammation after 1 month (19%), and visual acuity loss (4.8%). **Conclusions:** Micropulse transscleral diode cyclophotocoagulation was safe and effective for reducing intraocular pressure in eyes with refractory and advanced glaucoma, with reduced need for ocular antihypertensive medication.

Keywords: Glaucoma; Laser therapy; Micropulse transscleral diode cyclophotocoagulation; Intraocular pressure; Laser, semiconductor

RESUMO | Objetivo: Avaliar a eficácia na redução da pressão intraocular e na segurança da ciclofotocoagulação com laser de diodo transescleral em glaucoma refratário. **Métodos:** Avaliamos prospectivamente uma série de casos de 21 olhos de 21 pacientes com glaucoma refratário tratados com ciclofotocoagulação com laser de diodo transescleral com acompanhamento por 12 meses. O tempo total de tratamento ficou a critério do cirurgião, considerando a pressão intraocular inicial e alvo e o tipo de glaucoma. Pressão intraocular, inflamação, acuidade visual e número de medicamentos foram monitorados. O sucesso foi definido como pressão intraocular entre 6 e 21 mmHg e/ou redução de 30% da pressão intraocular basal com ou sem o uso de medicamentos glaucomatosos. Perda da acuidade visual foi definida como perda de ≥ 2 linhas de visão na tabela de Snellen ou uma diminuição de ≥ 2 níveis na função visual em pacientes com acuidade do gráfico não mensurável. **Resultados:** A idade média foi de $61,04 \pm 12,99$ anos e 11 (52,4%) pacientes eram do sexo masculino, com a maioria (95%) dos pacientes apresentando baixa acuidade visual inicialmente (conta dedos ou pior). A pressão intraocular média foi de $33,38 \pm 15,95$ mmHg, e o número médio de medicamentos foi de $3,5 \pm 1,1$, no início do estudo. Após 1, 3, 6 e 12 meses, 76,19%, 57,14%, 55,56% e 66,67%, respectivamente, dos pacientes foram classificados como sucesso do tratamento. Sete (33,3%) pacientes necessitaram de novo tratamento com laser e foram considerados falhas no tratamento. A redução média da

Submitted for publication: August 6, 2018
Accepted for publication: December 11, 2018

Funding: This study was supported by Conselho Nacional de Desenvolvimento Científico e Tecnológico (AAJ).

Disclosure of potential conflicts of interest: None of the authors have any potential conflicts of interest to disclose.

Corresponding author: Vital Paulino Costa.

Departamento de Oftalmologia - Faculdade de Ciências Médicas - UNICAMP
Rua Tessália Vieira de Camargo, 126 - Campinas - SP - 13083-887 - Brazil
E-mail: vp.costa@uol.com.br

Approved by the following research ethics committee: Universidade Estadual de Campinas (#2.660.773).

pressão intraocular foi de $44,72\% \pm 29,72\%$ na primeira semana e $41,59\% \pm 18,93\%$ no final do seguimento ($p=0,006$). O número médio de medicamentos diminuiu significativamente para $2,00 \pm 1,7$ na visita de 12 meses ($p=0,044$). As complicações incluíram hipotonia (4,8%), inflamação intraocular após 1 mês (19%) e perda de acuidade visual (4,8%). **Conclusões:** A ciclofotocoagulação com laser de diodo transescleral foi segura e eficaz para reduzir a pressão intraocular em olhos com glaucoma refratário e avançado, com necessidade reduzida de hipotensores oculares.

Descritores: Glaucoma; Terapia a laser; Ciclofotocoagulação transescleral com laser de diodo micropulsado; Pressão intraocular; Laser semicondutores

INTRODUCTION

Glaucoma is the leading cause of irreversible blindness in the world, with approximately 8.4 million people blind from glaucoma^(1,2). Evidence from long-term clinical trials shows that lowering intraocular pressure (IOP) prevents progression at the early and late stages of the disease⁽³⁻⁶⁾. Even in the final stages, when visual acuity is very low or absent, high IOP is a frequent cause of pain and discomfort. Topical medical therapy remains the most common initial intervention to lower IOP, but some patients do not respond to medical therapy and require laser or surgical procedures⁽⁷⁾. Several laser or surgical procedures are used to treat glaucoma, and each has a different safety profile and success rate.

During the past 3 decades, continuous transscleral laser diode cyclophotocoagulation (TSCPC) has been an alternative to incisional surgery⁽⁸⁾. This procedure uses an 810-nm wavelength laser that produces a thermal effect when absorbed by melanin in the pigmented epithelial cells of the ciliary body, which reduces aqueous humor production⁽⁹⁾. Given the potential risk of sight-threatening complications (e.g., *phthisis bulbi*, sympathetic ophthalmia, postoperative inflammation, hypotony, and cystoid macular edema) coupled with the unpredictability of the IOP-lowering effect, TSCPC has been used after clinical treatment or invasive procedures have failed⁽¹⁰⁻¹³⁾.

As an alternative to the conventional continuous high-intensity energy laser delivery of the TSCPC system, micropulse diode laser has been proposed as a safer cyclodestructive procedure^(14,15). By delivering a series of repetitive short pulses of energy separated by rest periods, micropulse transscleral cyclophotocoagulation (MP-TSCPC) is believed to minimize collateral thermal damage to adjacent tissues by allowing nonpigmented tissue to remain below the coagulation threshold during the off-cycle⁽¹⁵⁾. In the present study, we prospectively

evaluated the efficacy and safety of MP-TSCPC in patients with refractory glaucoma who were followed for 12 months.

METHODS

This prospective interventional study conducted at the University of Campinas (UNICAMP), Campinas, São Paulo, Brazil, was approved by the Ethics Committee of the University of Campinas. The protocol was in compliance with Good Clinical Practices and the tenets of the Declaration of Helsinki (1996).

Patients

Twenty-one eyes of 21 consecutive patients with refractory glaucoma, defined as medically uncontrolled glaucoma despite previous glaucoma surgery, who were seen at the outpatient clinic of UNICAMP were enrolled and followed for 12 months. The eyes had no previous ciliary ablative surgery, and the patients were either poor candidates for additional filtering surgery or had declined an additional incisional procedure. Patients with no light perception but who presented with ocular pain associated with high IOPs were also enrolled. Patients with ongoing ocular inflammation or infection were excluded.

Examination

Before the intervention, all participants underwent a comprehensive ophthalmological examination, which included review of medical history, best-corrected visual acuity (BCVA), slit-lamp biomicroscopy, IOP measurement using Goldmann applanation tonometry, dilated funduscopy examination, and standard automated perimetry using the Humphrey Field Analyzer (Carl Zeiss Meditec, Dublin, CA) whenever the visual acuity allowed. Spectral-domain optical coherence tomography (OCT) imaging of the macula with Cirrus HD-OCT (Carl Zeiss Meditec, Inc., Dublin, CA, USA) was performed in eyes without media opacities.

Intervention

MP-TSCPC was performed by using the Cyclo G6 Glaucoma Laser System and a MicroPulse P3 probe (Iridex, Mountain View, CA, USA) by 1 of 2 surgeons (V.P.C. and J.P.C.V.). Following peribulbar anesthesia, the probe was applied firmly to the conjunctiva and moved in a continuous sliding arc motion ("painting") avoiding the 3 and 9 o'clock positions. In contrast to the G-probe used for TSCPC, the MicroPulse P3 probe targets the *pars*

plana instead of the *pars plicata* and places the quartz optical fiber 3 mm posterior to the limbus. The device was set on micropulse mode with 2000 mW of 810 nm infrared diode laser radiation, with a 0.5 ms on-time and a 1.1 ms off-time and an equivalent duty factor of 31.3% (Figure 1). The total treatment time was at the discretion of the surgeon who considered baseline and target IOPs and glaucoma diagnosis, i.e., higher baseline IOPs and lower target IOPs received longer treatment. We prescribed postoperative steroid eye drops (prednisolone acetate, 1% q.i.d.) for 3 weeks after the procedure.

Follow-up

Patients were seen on days 1, 7, and 30 and months 3, 6, and 12 after the procedure. The follow-up examination included determining BCVA, slit-lamp biomicroscopy, dilated funduscopy, and OCT imaging. IOP was measured twice by using a Goldmann applanation tonometer, and the mean was calculated. Additional visits were scheduled as needed. The number of antiglaucoma medications and clinical complications was annotated. Hypotony was defined as an IOP <6 mmHg at 2 consecutive visits, and prolonged intraocular inflammation was defined as an anterior chamber inflammation⁽¹⁶⁾ (1+ cells or more) presented for at least 1 month after treatment. Visual acuity loss was defined as a loss of

≥2 lines of vision on the Snellen chart or a ≥1-level decrease in visual function (e.g., from count fingers to hand movements).

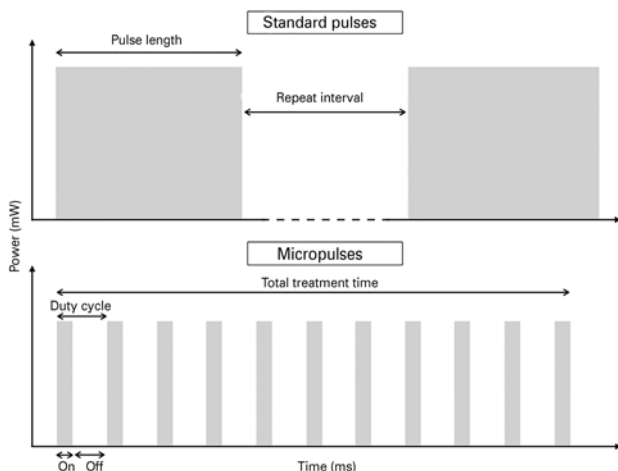
Outcome measures

Success was defined as an IOP between 6 and 21 mmHg and/or a minimum of 30% IOP reduction from baseline, with or without glaucoma medication, after a single MP-TSCPC application. For patients with an IOP <21 mmHg at enrollment, an IOP reduction >30% from the baseline was required for treatment success. The need for a new surgical intervention (including a new MP-TSCPC) for IOP control at any time during follow-up was also considered to be a failure. We also evaluated the number of antiglaucoma medications and the frequency of postoperative complications.

Statistical analysis

The values were characterized by the mean and standard deviation, median, and minimum and maximum values. For the purposes of the Kaplan-Meier plots, the date of treatment failure was defined as the first post-laser visit when a success-defining IOP level was not achieved.

All analyses were performed in the open-source environment R (R Foundation, Vienna, Austria) and by using the commercially available software, Stata version 15 (StataCorp LP, College Station, Texas, USA). The alpha level (type I error) was set at 0.05.



mW= milliwatts; ms= milliseconds.

Figure 1. Standard versus micropulse energy delivery configuration. In continuous TSCPC, the pulse length indicates the amount of time (ms) the laser delivers the indicated power (mW), either in single-shot or repeat mode. For MP-TSCPC, the treatment time corresponds to the total time length in which ≥1 smaller pulses may be fired. In this study, the device was set to 2000 mW of 810 nm infrared diode laser radiation, with a 0.5 ms on-time and a 1.1 ms off-time (duty factor of 31.3%). The total time was at the discretion of the surgeon.

RESULTS

Twenty-one eyes of 21 consecutive patients underwent MP-TSCPC application. Two (9.5%) patients did not participate in the 1-year follow-up visit. One of the patients died between the 6th and 12th month after surgery from causes unrelated to the procedure. The mean age was 61.04 ± 12.99 years, and 11 (52.4%) patients were male. The vast majority (95%) of patients had BCVA below measurable values in the Snellen visual acuity chart (count fingers or worse), and 7 (33%) had no light perception at baseline. Among the 21 patients, 4.8% had traumatic, 9.5% had silicone oil-induced, 33.3% had primary open-angle, and 52% had neovascular glaucoma. Demographics and clinical characteristics are summarized in table 1.

The mean IOP was 33.38 ± 15.95 mmHg at baseline. Success rates were 71.43%, 76.19%, 57.14%, 55.56%, and 66.67% at day 7 and 1, 3, 6, and 12 months, respectively, after 1 single MP-TSCPC treatment (mean

treatment time of 183.3 ± 72.1 s). The 2 subjects with refractory glaucoma enrolled with a baseline IOP <21 mmHg (16 and 19 mmHg) achieved the required IOP reduction of >30% to be considered a treatment success by month 3. The average IOP reduction was $44.72\% \pm 29.72\%$ in the first week and $41.59\% \pm 18.93\%$ at the end of follow-up (Figure 2).

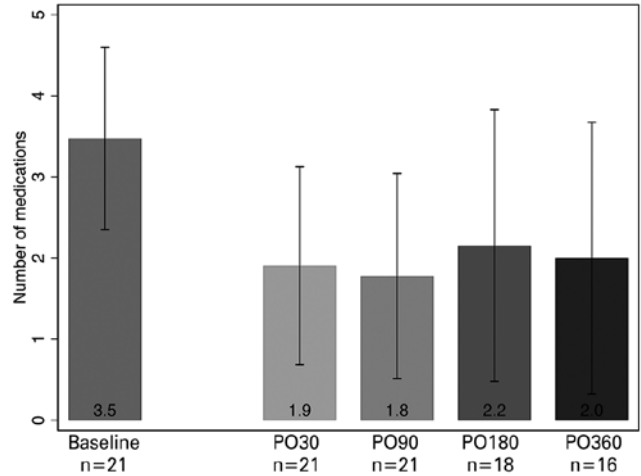
Table 1. Demographics and clinical characteristics of the study patients

Age (years)*	61.04 ± 12.99
Sex, male	11 (52.4%)
Phakic	10 (47.6%)
BCVA	
>20/200	1 (4.8%)
CF or HM	12 (57.1%)
LP	1 (4.8%)
NLP	7 (33.3%)
Glaucoma diagnosis	
Traumatic	1 (4.8%)
Silicon oil-induced	2 (9.52%)
POAG	7 (33.3%)
Neovascular	11 (52.4%)

*Mean and standard deviation.

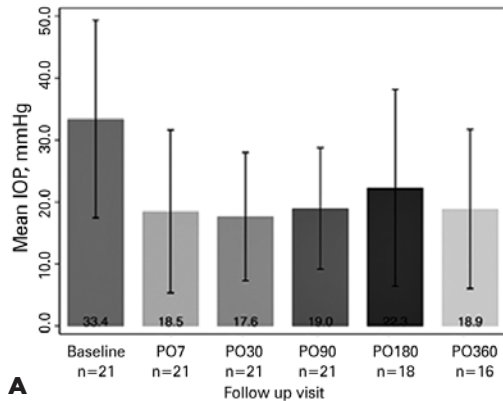
BCVA= best-corrected visual acuity; CF= count fingers; HM= hand movement; LP= light perception; NLP= no light perception; POAG= primary open-angle glaucoma.

Seven (33.3%) patients required a new laser treatment and were considered to be treatment failures: 3 patients underwent continuous TSCPC 2 months after MP-TSCPC and 1 after 3 months, all of them because of uncontrolled IOP under maximum medical therapy. The other 3 pa-

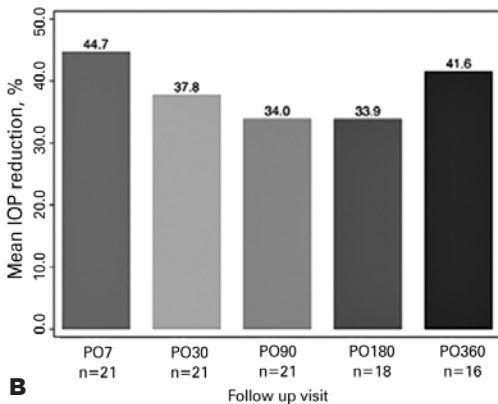


PO= postoperative day.

Figure 3. Mean number of antiglaucoma medications over time.



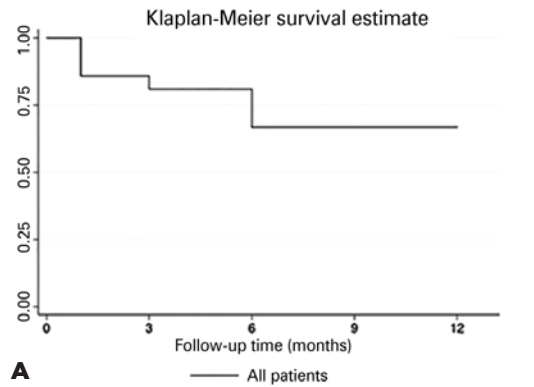
A



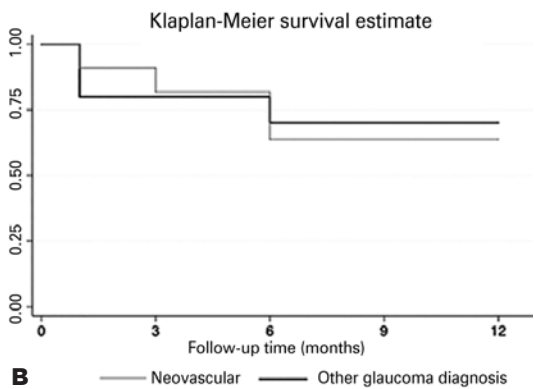
B

PO= postoperative day.

Figure 2. (A) Mean intraocular pressure (IOP) and (B) mean IOP reduction over time.



A



B

Figure 4. Kaplan-Meier cumulative survival analysis curve for (A) all diagnosis and (B) comparative curves between neovascular glaucoma and other glaucoma diagnosis. (Log-rank test for equality of survivor functions: $p=0.821$)

tients, who were NLP and had a painful eye at baseline, presented with high IOPs and no ocular pain after 6 months but refused any further laser treatment.

Figure 3 shows the mean number of antiglaucoma medications over time. At enrollment, the patients used an average of 3.48 drugs. This number significantly decreased to 1.90 in the first month and slightly increased toward the end of follow-up (2.00 ocular medications at the 12-month visit; $p=0.044$).

Figure 4 illustrates the Kaplan-Meier survival curve after MP-TSCPC treatment. At 12 months, the success rate was 66.67%. Survival rates between neovascular glaucoma patients and other glaucoma diagnosis were not significantly different ($p=0.821$).

One patient with neovascular glaucoma (NVG) showed 0 mmHg IOP on postoperative day 30 and was treated with atropine 1% and prednisolone 1% eye drops for 1 month, later presenting with IOPs between 9 and

Table 2. Review of the current literature

Authors	Study type	Sample	Laser settings	Follow-up*	Baseline IOP*	Final IOP*	Number of medications*	Outcome/success	Complications
Tan et al, 2010 ⁽¹⁵⁾	Prospective	40 eyes of 38 patients	2000 mW for 100 s	17.3 ± 2.0 months	40.1 ± 11.6	24.6 ± 9.6 mmHg	2.1 ± 1.1 to 1.3 ± 1.0	IOP < 21 mmHg or > 30% reduction with or without medications Success rate: 80% (32 out of 40 eyes) at 18 months	4 eyes (10%): persistent inflammation for 4 weeks 7 eyes (17.5%): hyphema post laser (neovascular glaucoma) No cases of hypotony, scleral perforation, phthisis bulbi, endophthalmitis, or sympathetic ophthalmia
Aquino et al, 2015 ⁽¹⁴⁾	Prospective, randomized	14 eyes (MP-TSCPC group) 14 eyes (TSCPC group)	2000 mW for 100 s	17.5 ± 1.6 months	36.5 mmHg (29.5, 56.5) median (IQR)	20.0 mmHg (16.0, 23.5) median (25th, 75th percentile)	2 (1.75, 3.00) to 1 (1, 2) median (25th, 75th percentile)	IOP 6-21 mmHg and > 30% reduction with or without medications/retreatment Success rate: 52% at 12 months; 75% at 18 months	1 eye (4%): vision loss from hands motion to no light perception 1 eye (4%): persistent inflammation 1 retreatment: 30% 2 retreatments: 17% No cases of hypotony
Kuchar et al, 2016 ⁽²⁵⁾	Retrospective	19 patients	2000 mW for 100-240 s.	60.3 days	37.9 mmHg	22.7 mmHg	2.6 to 1.9	IOP < 21 mmHg or > 20% reduction with or without medications Success rate: 73.7% (14 eyes); 89.5% (17 eyes) with retreatment	1 eye (5%): hypotony 4 eyes (20%): lost one line of vision 4 eyes (20%): gained one line of vision No cases of prolonged inflammation or phthisis bulbi
Lee et al, 2017 ⁽²⁴⁾	Retrospective	27 eyes (25 adult patients) 9 eyes (9 pediatric patients)	2000 mW for 320 s	12 months	28.41 ± 8.32 mmHg (adult patients) 34.28 ± 9.92 mmHg (pediatric patients)	18.98 ± 6.45 mmHg (adult patients), 27.20 ± 15.68 mmHg (pediatric patients)	Not disclosed	IOP < 21 mmHg or > 20% reduction with or without medications Success rate: 72.22% (adults); 22.22% (pediatric patients)	65% patients had mild postoperative inflammation for 2-4 weeks No shallow chamber, choroidal effusion, macular edema, and hyphema
Emanuel et al, 2017 ⁽¹⁸⁾	Retrospective	84 eyes	2000 - 1900 mW for 319 s (mean)	4.3 ± 3.0 months	27.7 ± 10.3 mmHg	14.6 ± 8.8 mmHg at 3 months 11.1 ± 4.4 at 12 months	3.3 ± 1.0 to 2.3 ± 1.5	Not set	8 and 3 eyes: persistent hypotony at 3 and 6 months, respectively 46%: persistent inflammation 41%: vision loss of at least 1 line No cases of <i>phthisis bulbi</i> or sympathetic ophthalmia
Williams et al, 2018 ⁽²⁶⁾	Retrospective	79 eyes of 79 patients	2000 mW for 300 s (mean)	7.8 ± 4.5 months	31.9 ± 10.2 mmHg	15.6 mmHg	2.3 ± 1.2 to 1.5	IOP 6-21 mmHg and >20% reduction with or without medications/retreatment Success rate: 75% at 3 months, 66% at 6 months, and 67% at last follow-up	7 eyes (8.8%): hypotony 21 eyes (26%): prolonged inflammation for >3months 13 eyes (17%): visual loss of ≥2 lines 4 eyes (5%): macular edema 2 eyes (2.5%): <i>phthisis bulbi</i> 1 retreatment: 12.6% 2 retreatments: 1.2%

*Mean ± standard deviation, unless otherwise noted; mW= milliwatts; s= seconds; mmHg= millimeters of mercury; IOP= intraocular pressure; MP-TSCPC= micropulse transscleral cyclophotocoagulation; TSCPC= transscleral cyclophotocoagulation.

10 mmHg until the end of follow-up. This patient had the highest IOP at baseline (78 mmHg) and received the longest exposure to MP-TSCPC (160 s per 180°).

Four (19%) patients presented with intraocular inflammation at the 1-month visit after MP-TSCPC, and 1 (4.7%) patient presented at the 3-month visit. Although characterizing visual loss in patients with very low vision is unreliable, this complication was observed in 1 patient at the 3-month visit (from hand movement to light perception). Patients considered as failures completed scheduled visits up to 1 year to assess possible late complications. No patient showed signs of *phthisis bulbi*, or macular edema in OCT.

DISCUSSION

In this study, MP-TSCPC effectively lowered IOP in patients with refractory glaucoma, with relatively few complications. The mean IOP was significantly reduced from the first week of treatment (44.7% reduction) and consistently maintained its effectiveness up to 1 year (41.6% reduction).

TSCPC has been used for decades as a noninvasive treatment for patients who are not good surgical candidates or with poor visual potential, with reported success rates in the range of 34% to 94%⁽¹⁰⁾, but with a number of known complications. The severity of these complications is secondary to the collateral damage to surrounding tissues, including the nonpigmented epithelium, ciliary body stroma, and ciliary muscles⁽¹⁷⁾. By delivering energy in an intermittent fashion, MP-TSCPC is believed to spare those structures from significant damage by gradually building up a photocoagulative state mainly in the pigmented epithelium⁽¹⁸⁾.

Micropulse diode laser has been successfully used in the management of retinal disorders, including macular edema secondary to diabetic retinopathy and branch retinal vein occlusion⁽¹⁹⁻²¹⁾. In retinal pigment epithelium models, Li and colleagues demonstrated that the micropulse-delivered energy partially suppressed anti-inflammatory mediators, which slowed normal cellular stress response and compensatory healing mechanisms and allowed faster protein denaturation⁽²²⁾. This offers a possible reason as to why micropulse can cause biological stress or even induce apoptosis without evident necrosis in the ciliary body⁽²³⁾.

Data on clinical studies with micropulse diode laser in glaucoma, however, are limited (Table 2). To the best of our knowledge, only 2 other studies, which were pu-

blished by the same group of investigators, have evaluated MP-TSCPC outcomes prospectively. In the first study of its kind, Tan et al.⁽¹⁵⁾ followed 40 eyes of 38 patients for an average of 17.3 ± 2.0 months and observed a mean IOP reduction from 40.1 ± 11.6 mmHg to 24.6 ± 9.9 mmHg, which resulted in an 80% success rate (IOP between 6 and 21 mmHg and/or 30% reduction from baseline with or without medication) after MP-TSCPC. Aquino et al.⁽¹⁴⁾ observed a similar success rate in the MP-TSCPC group (75% at 18 months by the same criteria) in a prospective randomized study that compared micropulse and standard TSCPC, with higher success rates for MP-TSCPC. It should be noted, however, that in both studies, the need for a repeat laser procedure was not considered to be a failure, with 30% of eyes requiring a second treatment and 17% requiring a third treatment with MP-TSCPC⁽¹⁴⁾. Our series shows a success rate of 66.67% at 1 year when applying the same success criteria after a single laser procedure. Unlike the previously cited studies, our methodology allowed the surgeon to deliver different treatment times (i.e., longer treatments for worse cases) with a mean treatment time of 183.3 ± 72.1 s, which is higher than the fixed time of 100 s in these studies. We believe that an individualized treatment plan provides better IOP outcomes, although no standard algorithm has been proposed, and we relied on the surgeon's expertise and gestalt.

Retrospective studies have also reported IOP lowering with variable success rates ranging from 22.2% in pediatric patients to 72.2% in adults at the end of the first postoperative year⁽²⁴⁾ or 73.7%⁽²⁵⁾ to 75%⁽²⁶⁾ after shorter follow-ups of 60.3 and 90 days, respectively. Nonetheless, these studies are diverse in methodology and limited in follow-up time.

The reduction in the number of required antiglaucoma medications after MP-TSCPC is remarkable. Previous studies have reported a significant decrease in this number, ranging from 2.1-3.3 at baseline to 1.3-2.3 medications at the last follow-up on average^(14,15,18,25). Similarly, we observed a notable drop in the number of ocular glaucoma medications from the first month onwards (Figure 2), although the number oscillated over time as treatment was adjusted after each visit according to drug tolerability and target IOP.

Complications

When new technologies are introduced, thorough follow-up and careful enrollment are necessary to inves-

tigate potential complications. Concerning the nature of this procedure and the complications of continuous TSCPC, we elected to include eyes with low visual acuities and refractory glaucomas in this initial study. Hence, 95% of our patients showed visual acuities of $<20/400$ at baseline. However, in 1 patient with neovascular glaucoma, we observed consistent visual acuity loss (from hand movements to light perception). Nonetheless, it is questionable if the visual acuity loss in this case was secondary to the laser procedure or a consequence of the natural history of the disease. Emanuel et al.⁽¹⁸⁾ published the largest cohort of patients to date who had undergone MP-TSCPC and observed that a substantial proportion (41%) of patients experienced loss of ≥ 1 line of vision after MP-TSCPC, including 3 patients who lost light perception. However, the mean follow-up was short (4.3 ± 3.0 months), with most patients monitored for ≤ 1 month. This same group later reported high rates of visual loss in a longer follow-up of 7.8 ± 4.5 months in which 13 (17%) eyes from a different series of patients lost ≥ 2 lines of vision⁽²⁶⁾. A lower incidence of visual loss was observed by Aquino et al.⁽¹⁴⁾ (1 patient in the MP-TSCPC group, from hand motion to no light perception), although improvement of 1 line of vision was observed by Tan et al.⁽¹⁵⁾ in 4 (10%) patients. Kuchar et al.⁽²⁵⁾ reported that 20% of patients lost ≥ 1 line of vision, whereas another 20% gained 1 line of vision after a short mean follow-up of 60.3 days. It is important to note that all previous studies also enrolled mostly patients with low vision (no light perception to 20/200).

Only 1 patient showed hypotony in our study, but it was transitory and successfully treated with topical steroids and atropine. Hypotony was the most common complication observed by Emanuel et al.⁽¹⁸⁾, with 8 and 3 eyes showing persistent hypotony at 3 and 6 months, respectively. In their study, laser settings and time of treatment were determined by the treating physician. In fact, the mean treatment time reported by these authors was 319 s, which was notably higher than ours. Similarly, Williams et al.⁽²⁶⁾ described a broader range of complications than that previously reported for MP-TSCPC, which is possibly related to longer treatment times (mean treatment time of 300 s). Conversely, our patient with persistent hypotony was also treated for a longer time (320 s) because of very high baseline IOP (78 mmHg) caused by neovascular glaucoma. No cases of hypotony were observed by Tan et al.⁽¹⁵⁾ and Aquino et al.⁽¹⁴⁾ at a fixed total treatment time of 100 s. Although no data is available for MP-TSCPC, an increased risk of complica-

tions is associated with higher energies in continuous TSCPC⁽²⁷⁾.

Postoperative intraocular inflammation was common following MP-TSCPC. Four (19%) patients in our study required extended treatment with prednisolone 1%, which resolved after 1 month. All of them had neovascular glaucoma and were treated for an average of 205 s (range, 160-240 s). Emanuel et al.⁽¹⁸⁾ observed that 74% (45/61 eyes) were on topical steroids at postoperative month 3 because of some degree of anterior chamber cell and/or flare. Lee et al.⁽²⁴⁾ reported a 65% prevalence of mild postoperative inflammation for 2 to 4 weeks postoperatively in 27 eyes in a sample that included 9 pediatric patients. Williams and colleagues⁽²⁶⁾ found an association of non-white race with prolonged inflammation after MP-TSCPC (OR, 3.61; 95% CI, 1.27-10.23; $p=0.02$). In prospective studies, the prevalence of prolonged intraocular inflammation has been found to be lower (4%-10%)^(14,15). This apparent discrepancy is because of a lack of standardization both in the definition and treatment of persistent inflammation.

We followed a small subgroup (14%) of patients without media opacities with macular OCT scans, and none of those eyes presented with macular edema. Four (5%) patients were clinically diagnosed as having macular edema by Williams et al.⁽²⁶⁾. Other studies did not report this complication. Similar to the present study, no cases of sympathetic ophthalmia, scleral perforation, or endophthalmitis were observed by previous authors.

However, 2 cases of *phthisis bulbi* were recently described⁽²⁶⁾ in patients with complex ocular histories (1 with nanophthalmos and 1 with neovascular glaucoma and uncontrolled diabetes). Yet, most evidence to date suggests that MP-TSCPC is an effective and safe alternative to traditional continuous TSCPC, with possible decreased rates of complications^(14,15,18,24-26).

Limitations

This study had several limitations. The low baseline visual acuity of our patients precluded the investigation of the safety of this procedure in eyes with good visual function. In TSCPC, the risk of complications is affected by the type of glaucoma, with NVG patients having a significantly increased risk of complications and failure^(27,28). Tan et al.⁽¹⁵⁾ also reported a higher failure rate in patients with NVG (6/12 eyes). There was no significant statistical difference in the cumulative survival rates between NVG and the other types of glaucoma ($p=0.825$). New studies, including logistic regression analysis, to

accurately identify predictors of failure with larger sample sizes should be conducted to allow better comparisons. Although no patient spontaneously reported ocular pain during laser treatment or during follow-up visits, we did not use a scale of pain or discomfort in our series. It has been previously observed that 94.7%-95.0% of the patients who underwent MP-TSCPC reported mild to no pain according to a verbal analog pain scale^(14,15). Finally, longer follow-up is desirable to establish efficacy and long-term complications.

We demonstrated that MP-TSCPC is a safe surgical option for eyes with refractory and advanced glaucoma, with a reduced need for antiglaucoma medications after 1 year. Further studies with longer follow-up, including in eyes with early to moderate disease and better baseline visual acuities, are needed to better determine the indications and safety of this procedure.

REFERENCES

1. Quigley HA, Broman AT. The number of people with glaucoma worldwide in 2010 and 2020. *Br J Ophthalmol.* 2006;90(3):262-7.
2. Tham YC, Li X, Wong TY, Quigley HA, Aung T, Cheng CY. Global prevalence of glaucoma and projections of glaucoma burden through 2040: a systematic review and meta-analysis. *Ophthalmology.* 2014; 121(11):2081-90.
3. The AGIS Investigators. The Advanced Glaucoma Intervention Study (AGIS): 7. The relationship between control of intraocular pressure and visual field deterioration. *Am J Ophthalmol.* 2000; 130(4):429-40.
4. Collaborative Normal-Tension Glaucoma Study Group. Comparison of glaucomatous progression between untreated patients with normal-tension glaucoma and patients with therapeutically reduced intraocular pressures. *Am J Ophthalmol.* 1998;126(4):487-97.
5. Heijl A, Leske MC, Bengtsson B, Hyman L, Bengtsson B, Hussein M. Reduction of intraocular pressure and glaucoma progression: results from the Early Manifest Glaucoma Trial. *Arch Ophthalmol (Chicago, Ill : 1960).* 2002;120(10):1268-79.
6. Lichter PR, Musch DC, Gillespie BW, Guire KE, Janz NK, Wren PA, et al. CIGTS Study Group. Interim clinical outcomes in the Collaborative Initial Glaucoma Treatment Study comparing initial treatment randomized to medications or surgery. *Ophthalmology.* 2001;108(11):1943-53.
7. Prum BE Jr, Rosenberg LF, Gedde SJ, Mansberger SL, Stein JD, Moroi SE, et al. Primary open-angle glaucoma preferred practice pattern(r) guidelines. *Ophthalmology.* 2016;123(1):41-P111.
8. Gaasterland DE, Pollack IP. Initial experience with a new method of laser transscleral cyclophotocoagulation for ciliary ablation in severe glaucoma. *Trans Am Ophthalmol Soc.* 1992;90:225-43.
9. Peyman GA, Naguib KS, Gaasterland D. Trans-scleral application of a semiconductor diode laser. *Lasers Surg Med.* 1990;10(6):569-75.
10. Lin SC. Endoscopic and transscleral cyclophotocoagulation for the treatment of refractory glaucoma. *J Glaucoma.* 2008;17(3):238-47.
11. Kosoko O, Gaasterland DE, Pollack IP, Enger CL, Wise JB, Shields MB, et al.; The Diode Laser Ciliary Ablation Study Group. Long-term outcome of initial ciliary ablation with contact diode laser transscleral cyclophotocoagulation for severe glaucoma. *Ophthalmology.* 1996;103(8):1294-302.
12. Youn J, Cox TA, Allingham RR, Shields MB. Factors associated with visual acuity loss after noncontact transscleral Nd:YAG cyclophotocoagulation. *J Glaucoma.* 1996;5(6):390-4.
13. Bechrakis NE, Müller-Stolzenburg NW, Helbig H, Foerster MH. Sympathetic ophthalmia following laser cyclocoagulation. *Arch Ophthalmol.* 1994;112(1):80-4.
14. Aquino MC, Barton K, Tan AM, Sng C, Li X, Loon SC, et al. Micropulse versus continuous wave transscleral diode cyclophotocoagulation in refractory glaucoma: a randomized exploratory study. *Clin Exp Ophthalmol.* 2015;43(1):40-6.
15. Tan AM, Chockalingam M, Aquino MC, Lim ZI, See JL, Chew PT. Micropulse transscleral diode laser cyclophotocoagulation in the treatment of refractory glaucoma. *Clin Exp Ophthalmol.* 2010; 38(3):266-72.
16. Jabs DA, Nussenblatt RB, Rosenbaum JT; Standardization of Uveitis Nomenclature (SUN) Working Group. Standardization of uveitis nomenclature for reporting clinical data. Results of the First International Workshop. *Am J Ophthalmol.* 2005;140(3):509-16.
17. Pantcheva MB, Kahook MY, Schuman JS, Rubin MW, Noecker RJ. Comparison of acute structural and histopathological changes of the porcine ciliary processes after endoscopic cyclophotocoagulation and transscleral cyclophotocoagulation. *Clin Exp Ophthalmol.* 2007;35(3):270-4.
18. Emanuel ME, Grover DS, Fellman RL, Godfrey DG, Smith O, Butler MR, et al. Micropulse cyclophotocoagulation: initial results in refractory glaucoma. *J Glaucoma.* 2017;26(8):726-9.
19. Moorman CM, Hamilton AM. Clinical applications of the Micropulse diode laser. *Eye (Lond).* 1999;13(Pt 2):145-50.
20. Parodi MB, Spasse S, Iacono P, Stefano GD, Canziani T. Subthreshold grid laser treatment of macular edema secondary to branch retinal vein occlusion with micropulse infrared (810 Nm) diode laser. *Invest Ophthalmol Vis Sci.* 2005;46(13):4045.
21. Luttrull JK, Musch DC, Mainster MA. Subthreshold diode micropulse photocoagulation for the treatment of clinically significant diabetic macular oedema. *Br J Ophthalmol.* 2005;89(1):74-80.
22. Li Z, Song Y, Chen X, Chen Z, Ding Q. Biological modulation of mouse RPE cells in response to subthreshold diode micropulse laser treatment. *Cell Biochem Biophys.* 2015;73(2):545-52.
23. Amoozgar B, Phan EN, Lin SC, Han Y. Update on ciliary body laser procedures. *Curr Opin Ophthalmol.* 2017;28(2):181-6.
24. Lee JH, Shi Y, Amoozgar B, Aderman C, De Alba Campomanes A, Lin S, et al. Outcome of micropulse laser transscleral cyclophotocoagulation on pediatric versus adult glaucoma patients. *J Glaucoma.* 2017;26(10):936-9.
25. Kuchar S, Moster MR, Reamer CB, Waisbourd M. Treatment outcomes of micropulse transscleral cyclophotocoagulation in advanced glaucoma. *Lasers Med Sci.* 2016;31(2):393-6.
26. Williams AL, Moster MR, Rahmatnejad K, Resende AF, Horan T, Reynolds M, et al. Clinical Efficacy and safety profile of micropulse transscleral cyclophotocoagulation in refractory glaucoma. *J Glaucoma.* 2018;27(5):445-9.
27. Vernon SA, Koppens JM, Menon GJ, Negi AK. Diode laser cycloablation in adult glaucoma: long-term results of a standard protocol and review of current literature. *Clin Exp Ophthalmol.* 2006;34(5):411-20.
28. Ramli N, Htoon HM, Ho CL, Aung T, Perera S. Risk factors for hypotony after transscleral diode cyclophotocoagulation. *J Glaucoma.* 2012;21(3):169-73.