



KATYA PULIDO DIAZ

*"ESTUDO IMUNOISTOQUÍMICO DA ANGIOGÊNESE, PROLIFERAÇÃO
CELULAR E DA ENZIMA ÁCIDO GRAXO SINTASE (FASN) EM TUMORES
MALIGNOS PRIMÁRIOS DE GLÂNDULAS SALIVARES MAIORES E
MENORES"*

*"IMMUNOHISTOCHEMICAL STUDY OF ANGIOGENESIS, CELLULAR
PROLIFERATION AND FATTY ACID SYNTHASE (FASN) IN MINOR AND
MAJOR PRIMARY MALIGNANT SALIVARY GLAND TUMORS."*

PIRACICABA

2014



UNIVERSIDADE ESTADUAL DE CAMPINAS

FACULDADE DE ODONTOLOGIA E PIRACICABA

KATYA PULIDO DIAZ

***"ESTUDO IMUNOISTOQUÍMICO DA ANGIOGÊNESE, PROLIFERAÇÃO
CELULAR E DA ENZIMA ÁCIDO GRAXO SINTASE (FASN) EM TUMORES
MALIGNOS PRIMÁRIOS DE GLÂNDULAS SALIVARES MAIORES E
MENORES"***

***"IMMUNOHISTOCHEMICAL STUDY OF ANGIOGENESIS, CELLULAR
PROLIFERATION AND FATTY ACID SYNTHASE (FASN) IN MINOR AND
MAJOR PRIMARY MALIGNANT SALIVARY GLAND TUMORS."***

Thesis presented to the Piracicaba Dental School of the State
University of Campinas to obtain the Ph.D. grade in
Stomatopathology, in the Pathology Area.

Tese apresentada à Faculdade de Odontologia de Piracicaba da
Universidade Estadual de Campinas, para obtenção do título de
Doutora em Estomatopatologia, na área de Patologia.

Orientador: Professor Dr. Pablo Agustin Vargas.
Este exemplar corresponde à versão final da tese
defendida pela aluna Katya Pulido Diaz e
orientada pelo Prof. Dr. Pablo Agustin Vargas.

Assinatura do Orientador

PIRACICABA

2014

Ficha catalográfica
Universidade Estadual de Campinas
Biblioteca da Faculdade de Odontologia de Piracicaba
Marilene Girello - CRB 8/6159

D543e Diaz, Katya Pulido, 1978-
Estudo imunoistoquímico da angiogênese, proliferação celular e da enzima ácido graxo sintase (FASN) em tumores malignos primários de glândulas salivares maiores e menores / Katya Pulido Diaz. – Piracicaba, SP : [s.n.], 2014.

Orientador: Pablo Agustin Vargas.
Tese (doutorado) – Universidade Estadual de Campinas, Faculdade de Odontologia de Piracicaba.

1. Glândulas salivares. 2. Proliferação celular. I. Vargas, Pablo Agustin, 1973-
II. Universidade Estadual de Campinas. Faculdade de Odontologia de Piracicaba.
III. Título.

Informações para Biblioteca Digital

Título em outro idioma: Immunohistochemical study of angiogenesis, cellular proliferation and fatty acid synthase (FASN) in minor and major primary malignant salivary gland tumors

Palavras-chave em inglês:

Salivary glands

Cell proliferation

Área de concentração: Patologia

Titulação: Doutora em Estomatopatologia

Banca examinadora:

Pablo Agustin Vargas [Orientador]

Mário José Romãach Gonzalez Sobrinho

Jorge Esquiche León

Marcio Ajudarte Lopes

Albina Messias de Almeida Milani Altemani

Data de defesa: 25-02-2014

Programa de Pós-Graduação: Estomatopatologia



UNIVERSIDADE ESTADUAL DE CAMPINAS
Faculdade de Odontologia de Piracicaba



A Comissão Julgadora dos trabalhos de Defesa de Tese de Doutorado, em sessão pública realizada em 25 de Fevereiro de 2014, considerou a candidata KATYA PULIDO DIAZ aprovada.

Prof. Dr. PABLO AGUSTIN VARGAS

Prof. Dr. MÁRIO JOSÉ ROMANACH GONZALEZ SOBRINHO

Prof. Dr. JORGE ESQUICHE LEÓN

Prof. Dr. MARCIO AJUDARTE LOPES

Profa. Dra. ALBINA MESSIAS DE ALMEIDA MILANI ALTEMANI

RESUMO

Introdução: Os tumores das glândulas salivares (TGS) são lesões incomuns e correspondem a aproximadamente 3 a 10% das neoplasias que acometem a região de cabeça e pescoço. A angiogênese, proliferação celular e a expressão da enzima ácido graxo sintase (FASN) podem interferir nos mecanismos de progressão tumoral e comportamento clínico dos tumores malignos de glândulas salivares. **Objetivos:** Avaliar imunohistoquimicamente a angiogênese, índice de proliferação celular e expressão de FASN em tumores malignos de glândulas salivares maiores e menores e correlacionar a expressão destes biomarcadores com os dados clínicos e agressividade histopatológica além de comparar a expressão de FASN e Ki67 entre 12 casos de adenoma pleomorfo e 6 de carcinoma ex-adenoma pleomorfos. **Pacientes e Métodos:** Foram utilizadas 52 peças cirúrgicas de pacientes portadores de tumores malignos de glândulas salivares maiores e menores e 12 de adenomas pleomorfos como controle do marcador FASN e Ki67. As amostras de tecidos dos TGS malignos foram submetidas a reações imunohistoquímicas para os anticorpos CD31, CD34, CD105, e para ambos tipos de tumores Ki-67 e FASN. Para a quantificação microvascular e determinação da proliferação celular utilizamos os métodos quantitativos *Microvessel Analysis Algorithm* e *Nuclear Image Analysis Algorithm* com o *software* ImageScope (Aperio Scanscope® CS System). Foi utilizado o método semi-quantitativo convencional para a análise do marcador FASN. **Resultados:** O local anatômico mais acometido foi a parótida (67,3%), os pacientes apresentaram idade média de 50,2±21,9 anos e 17,6% tiveram metástases à distância. A densidade microvascular nas áreas intra e peritumorais com marcadores CD31, CD34 e CD105 não mostrou significância estatística em relação aos índices de proliferação celular ou expressão de FASN ($P>0,05$). Os TGS malignos de alto grau apresentaram altos índices de proliferação celular ($P<0,006$) maior expressão de FASN do que os TGS de baixo grau de malignidade ($P<0,003$) e de igual forma em 6 casos de carcinoma ex-adenoma pleomorfo do que em adenomas pleomorfos ($P<0,001$). **Conclusões:** Esses dados sugerem que os tumores malignos de glândulas salivares com altos índices de Ki-67 e FASN podem estar relacionados a maior proliferação celular em tumores de alto grau de malignidade e podem contribuir na identificação do componente maligno do carcinoma ex-adenoma pleomorfo.

Palavras-chave: glândulas salivares; imunohistoquímica; angiogênese; proliferação celular.

ABSTRACT

Introduction: Salivary gland tumors (SGT) are uncommon and account for approximately 3-10% of cancers affecting the head and neck region. Angiogenesis, cell proliferation, expression of the enzyme fatty acid synthase (FASN) may interfere with the mechanisms of tumor progression and clinical behavior of malignant SGT.

Objectives: To assess the expression of biomarkers related to angiogenesis and cell proliferation, as well FASN protein in major and minor malignant SGT, correlating the results with clinical findings and histopathological aggressivity. Also, to compare the expression of FASN and Ki67 between 12 pleomorphic adenomas and 6 carcinomas ex-pleomorphic adenomas.

Patients and Methods: 51 surgical specimens from patients with malignant SGT were assessed. We performed immunohistochemical study for CD31, CD34, CD105, Ki67 and FASN antibodies. For quantification and determination of the microvascular density (MVD) of tumors, quantitative method was used with *Microvessel Analysis Algorithm* (software Aperio Scanscope® CS System) and for nuclear analysis was used *Nuclear Image Analysis Algorithm*, but for FASN only conventional semi-quantitative method was used.

Results: The most affected anatomical site was the parotid gland (67.3 %), average age $50.2 \pm 21,9$ years and 17.6% of patients had distant metastases. Microvascular analysis in intra and peritumoral areas with markers CD31, CD34 and CD105 showed no statistical significance in relation to rates of cell proliferation and expression of FASN ($P > 0.05$). However, patients with high-grade malignant SGT showed higher rates of cell proliferation ($P < 0.006$) and increased expression of FASN ($P < 0.003$) at the same time to 6 cases of carcinoma ex-pleomorphic adenoma compared with 6 of pleomorphic adenoma ($P < 0.001$).

Conclusions: These data suggest that malignant salivary gland tumors with high levels of Ki-67 and FASN may be associated with high index of cellular proliferation in high-grade malignant SGT and its overexpression may be a useful marker for carcinoma ex-pleomorphic adenoma.

Keywords: salivary gland, immunohistochemistry, angiogenesis, cellular proliferation.

SUMÁRIO

DEDICATÓRIA	xii
AGRADECIMENTOS	xv
EPÍGRAFE	xix
INTRODUÇÃO	1
CAPITULO 1: EXPRESSION OF BIOMARKERS RELATED TO ANGIOGENESIS AND CELLULAR PROLIFERATION IN PRIMARY MALIGNANT SALIVARY GLAND TUMORS	7
CAPITULO 2: FATTY ACID SYNTHASE (FASN) AND KI-67 IMMUNOEXPRESSION CAN BE USEFUL TO IDENTIFY THE MALIGNANT COMPONENT IN CARCINOMA EX-PLEOMORPHIC ADENOMA	27
CONCLUSÃO	43
REFERÊNCIAS	44
ANEXO	49

DEDICATÓRIA

*Dedico este trabalho à minha mãe, **Maria Rufina**, meu melhor exemplo. Obrigada pelo ensino, apoio incondicional e liberdade nas escolhas para realizar meus sonhos, por ter mantido unida nossa família sempre, por sua infinita bondade, sabedoria e alegria, e por me acompanhar agora em cada amanhecer, cada por do sol, cada flor, cada brilho das estrelas...*

*Ao meu pai **Rosalio Pulido** e as minhas irmãs **Rosalia e Guadalupe Pulido** que contribuíram para me manter firme mesmo longe, obrigada por todo o amor e apoio desde sempre.*

*Ao meu orientador Professor Doutor **Pablo Agustin Vargas**, que considero um exemplo de ser humano com vasta bondade, aberto, sempre compreensivo comigo nos momentos mais difíceis para mim durante esses 5 anos. Pessoa que admiro profissionalmente e que me concedeu a oportunidade de aprender sem limites, com ele e seus mestres, o qual acho extremamente inestimável. Não é coincidência ter mantido contato com o senhor há mais de 12 anos, muito obrigada pela oportunidade de conseguir meu objetivo, pela confiança e por acreditar em mim. Os maiores logros de meu desenvolvimento profissional que consegui são graças ao senhor, que me considerou para entrar e estudar nesta universidade durante a aplicação da prova PEC-PG.*

AGRADECIMENTOS

AGRADECIMENTOS ESPECIAIS:

Ao Dr. Leandro Liporoni Martins, que considero amigo e mestre. Obrigada por compartilhar sem limites sua sabedoria, pela agradável e alegre companhia de sempre no 9º e 10º andar do HC-FMSUP, por depositar toda confiança e acreditar em mim.

À Dra. Sheila Siqueira Medeiros, exemplo de força, trabalho e profissionalismo, obrigada por me receber com alegria sempre no HC-FMUSP e dar liberdade para participar das atividades com os professores e residentes, além de conceder seu valioso tempo toda vez que precisei de sua ajuda.

À Prof. Dra. Albina Messias Altemani, modelo exemplar de profissionalismo, serenidade, humildade e paciência, obrigada por conceder os valiosos momentos de estudo e aprendizado com a senhora no Departamento de Patologia do HC-UNICAMP.

Ao Prof. Dr. Román Carlos Bregni, que considero exemplo de força e profissionalismo, meu eterno agradecimento por receber-me em sua casa, pela confiança e por compartilhar sua sabedoria e vasta experiência.

Ao Prof. Dr. Oslei Paes de Almeida, meu eterno agradecimento por acolher-me desde a minha chegada no Brasil. Considero exemplo de profissionalismo, humildade e sabedoria. Obrigada por me atender prontamente, toda vez que pedi para estudar junto e aprender com o senhor.

Ao Prof. Dr. Jorge Esquiche León, meu primeiro amigo e irmão aqui no Brasil, obrigada pelos valiosos conselhos e pela dedicação que demonstrou-me ensinando, além dos momentos de descontração e alegria. Considero você modelo exemplar de profissional, humildade, força e honestidade.

Ao Prof. Msc. Adalberto Mosqueda Taylor, meus agradecimentos por fazer parte de minha formação profissional desde o México. Obrigada pelos conselhos e lembranças em toda vinda ao Brasil, além de compartilhar as nossas saudades.

Ao Prof. Dr. Rogério Gondak, amigo e irmão, o qual participou neste trabalho. Considero você um verdadeiro exemplo de coleguismo, amizade e profissionalismo. Sou muito grata por ter compartilhado e aprendido de você experiências profissionais e nos momentos de descontração. Muito obrigada por estar presente desde o início da nossa turma e me transmitir paz e serenidade durante esses cinco anos.

AGRADECIMENTOS

À Faculdade de Odontologia de Piracicaba da Universidade Estadual de Campinas, na pessoa de seu diretor, Prof. Dr. **Jacks Jorge Júnior**.

Ao Prof. Dr. **Alan Roger dos Santos Silva** coordenador do Programa de Pós-Graduação em Estomatopatologia e aos Professores Drs. **Edgard Graner, Jacks Jorge Júnior, Marcio Ajudarte Lopes, Pablo Agustin Vargas, Ricardo Della Coletta e Oslei Paes de Almeida** das áreas de Patologia e Semiologia da Faculdade de Odontologia de Piracicaba – UNICAMP, pelos ensinamentos transmitidos.

Ao Prof. Dr. **Ricardo Della Coletta**, pelo apoio sempre que precisei, além da agradável gentileza de me receber na minha chegada em 2009.

À **Raquel Quintana Marcondes** e **Ana Carone**, assessoras da coordenação da Pós-Graduação pela paciência e amabilidade.

À CAPES pelo financiamento deste estudo por meio do Programa de Estudantes-Convênio de Pós-graduação (PEC-PG, Processo nº 5881102) e ao Ilmo. **Alejandro Reyes Silvestre** coordenador da Cultura na embaixada do Brasil no México, por toda a orientação e ajuda.

Aos amigos residentes e doutores assistentes da Anatomia Patológica do HC-FMUSP 10º andar, em especial à **Dra. Patricia Picciarelli**, e ao querido **Dr. Daniel Hiedo Kato** pela disponibilidade, alegria e valiosos ensinamentos compartilhados.

Aos funcionários da Anatomia Patológica do HC-FMUSP 10º andar, **Simone Viera Martins, Elisabete da Silva, Douglas Moreira e Rafael de Oliveira** pela

disponibilidade de sempre, paciência, carinho e dedicação a seu trabalho, sou muito grata à vocês.

Aos funcionários da FOP-UNICAMP **Geovania Almeida, João Carlos Gomes, Adriano Luis Martins e Luana Ganhor Delafiori** pela amabilidade e paciência, e a **Fabiana Facco Cassarotti** pelo apoio, amizade e valiosa ajuda no departamento de imunoistoquímica para a realização deste trabalho.

Aos meus amigos-irmãos **Fabio Gutiérrez e Bisharú Bernal** pelos valiosos conselhos, apoio e amor incondicional de sempre. Ainda estando longe, fisicamente vocês sempre estiveram presentes no meu pensamento e coração.

Aos meus amigos queridos **Adriano Lima e Caroline Camargo** pelos momentos de diversão, pela torcida e companhia tão alegre, positiva e sincera.

A minha amiga irmãzinha **Marisol Martínez Martínez**, sou muito grata pela valiosa amizade, carinho, conselhos, tristezas e alegrias. Obrigada pela sua alegria e ensinamentos transmitidos, além de compartilhar as nossas saudades mexicanas.

Aos meus amigos queridos Professores, **Ana Cláudia Rossi e Alexandre Rodrigues Freire** do Departamento de Anatomia da FOP-UNICAMP, pela bondade, amizade e pelo apoio desde minha chegada ao Brasil.

A minha segunda família aqui no Brasil, **Sra. Leny, Sr. Valdir e Felipe Valdir Brito**, pelo carinho e modelo exemplar de força, trabalho e amor. Serei eternamente grata por me acolher desde minha chegada em Piracicaba.

Aos meus amigos queridos Professores Drs. **Andreia Bufalino, Jorge Esquiche León, Michelle Agostini, Ana Terezinha Mesquita, Patricia Feio, Mario Romañach, Daniel Berretta, e Bruno Augusto Benevenuto** pela valiosa amizade e aprendizado adquirido, além de alegrias e lembranças.

Ao meu amigo **Wilfredo González Arriagada**, pelo companherismo, amizade e alegrias. Obrigada pelos ensinamentos compartilhados desde que chegamos ao Brasil e pela sua ajuda incondicional de sempre.

Às minhas amigas do laboratório **Luciana Yamamoto de Almeida, Rose Mara Ortega, Débora Bastos, e Andreinha Silva** pela amizade, conselhos e ensinamentos transmitidos.

Aos meus amigos **Karina Morais Faria, Lara Ramos Inocentini, Rodrigo Neves Silva, Wilfredo González Arriagada, Renato Assis Machado, Camila Borges e Renata Lucena Markman** pelos momentos de estudo, risadas e alegre convivência de sempre na sala da semiologia, em especial a Karis, por sua extrema bondade e alegria.

Aos amigos **Ana Lúcia Noronha e Juscelino Freitas** pela amizade e apoio, quando nos encontramos em São Paulo.

Aos amigos **Alicia Rumayor Piña, Harim Tavares e Fernanda Moreira** pelos momentos de descontração e estudo, e a todos os demais colegas da Pós-graduação em Estomatopatologia, pelas experiências compartilhadas na Área de Patologia da FOP-UNICAMP.

EPIGRAFE

"Todo mundo é meu professor. Alguns eu procuro. Alguns eu inconscientemente atraio.

Muitas vezes eu aprendo simplesmente observando outros. Alguns podem ser completamente inconscientes de que eu estou aprendendo com eles, mas eu me curvo profundamente em sinal de gratidão."

Eric Allen.

INTRODUÇÃO

Os tumores das glândulas salivares (TGS) são lesões incomuns e correspondem a aproximadamente 3% a 10% das neoplasias que acometem a região de cabeça e pescoço (Speight & Barret, 2002; Ito *et al.*, 2005). Cerca de 60% a 80% dos tumores de glândulas salivares acometem a glândula parótida, 7% a 11% acometem a glândula submandibular, 9% a 23% ocorrem em glândulas salivares menores e apenas 1% afetam a glândula sublingual. Os tumores benignos correspondem de 54% a 79% dos casos e os malignos podem representar de 21% a 46% (Speight & Barret, 2002; Eveson *et al.*, 2005). Com relação aos tumores malignos de glândulas salivares, o carcinoma mucoepidermóide (CME) é o mais frequente correspondendo a 10% de todos os tumores, sendo que 60% dos casos acometem a glândula parótida (Speight & Barret, 2002; Luna, 2006). O segundo tipo mais comum é o carcinoma adenóide cístico (CAC) com uma incidência de 24,2% entre os tumores salivares malignos, sendo as glândulas salivares menores acometidas mais frequentemente (Ito *et al.*, 2005).

Os TGS proporcionam uma grande oportunidade para se conhecer os mecanismos de progressão tumoral, devido à alta complexidade genética e variabilidade citoarquitetural (Cheuk & Chan, 2007). O estudo imunoistoquímico pode auxiliar no entendimento do diagnóstico e comportamento biológico destes tumores malignos.

Classificação de tumores de glândulas salivares malignos

Em 2005 a Organização Mundial de Saúde (OMS) atualizou a classificação das neoplasias de glândulas salivares e incluiu novas entidades (Barnes *et al.*, 2005). A tabela 1 abaixo ilustra os 24 tipos histopatológicos destas neoplasias.

Tumores epiteliais malignos

- *Carcinoma de células acinares
 - *Cacinoma mucoepidermóide
 - *Carcinoma adenóide cístico
 - *Adenocarcinoma polimorfo de baixo-grau
 - *Carcinoma epitelial-mioepitelial
 - *Carcinoma de células claras sem outra especificação
 - *Adenocarcinoma de células basais
 - *Carcinoma sebáceo
 - *Linfadenocarcinoma sebáceo
 - *Cistadenocarcinoma
 - *Cistadenocarcinoma cribriforme de baixo-grau
 - *Adenocarcinoma mucinoso
 - *Carcinoma oncocítico
 - *Carcinoma salivar ductal
 - *Adenocarcinoma sem outra especificação
 - *Carcinoma mioepitelial
 - *Carcinoma ex-adenoma pleomorfo
 - *Carcinossarcoma
 - *Adenoma pleomorfo metastatizante
 - *Carcinoma de células escamosas
 - *Carcinoma de células pequenas
 - *Carcinoma de células grandes
 - *Carcinoma linfoepitelial
 - *Sialoblastoma
-

ANGIOGÊNESE E MARCADORES IMUNOISTOQUÍMICOS

Angiogênese e CD105

A angiogênese tem um papel importante no crescimento de tumores malignos primários e desenvolvimento de metástases. Em casos de vascularização insuficiente, os tecidos esgotam o oxigênio e nutrientes que conduzem a secreção de fatores angiogênicos (Ferrara *et al.*, 2003). O anticorpo CD105 (endoglina) é expresso na superfície celular como uma glicoproteína de 180kDa homodimérica de transmembrana. Modula a sinalização TGF-B interagindo com receptores TGF-B I e III. TGF-B atua como um regulador negativo para angiogênese tumoral via inibição, proliferação e

migração de células endoteliais (Duff *et al.*, 2003) interrompendo a formação de microvasos, enquanto CD105 contrabalança estas ações. Uma possível explicação para este paradoxo é a apresentação da sinalização TGF- β como uma forma não funcional para este receptor. A endoglina é fortemente expressa em vasos sanguíneos de tumores enquanto está ausente em vasos sanguíneos de tecidos normais. Também é induzida por hipóxia e associada com incremento da proliferação celular endotelial e provável relação com a linfangiogênese tumoral (Kizas, *et al.*, 2006). A densidade intratumoral microvascular determinada pelo anticorpo CD105 foi correlacionada com aumento da agressividade tumoral em câncer de mama, melanoma cutâneo, câncer de pulmão, câncer de colón, malignidades ginecológicas e câncer renal. Além disso, o anticorpo CD105 tem sido usado como fator prognóstico em tumores angiogênicos de cabeça e pescoço (Kizas, 2006; Martone *et al.*, 2005).

CD31

CD31 é também conhecido como PECAM-1 (em inglês *Platelet Endothelial Cell Adhesion Molecule-1*) membro da superfamília das imunoglobulinas e funciona como mediador de adesão celular (El Gehani *et al.*, 2011). CD31 também é expresso na superfície das células endoteliais embrionárias e em alguns leucócitos e plaquetas periféricas. CD31 é considerado um marcador membranal angiogênico mais eficiente do que fator VIII, em câncer de bexiga (El Gehani *et al.*, 2011) e também é expresso em células neoplásicas de tumores de glândulas salivares e está envolvido na adesão de células tumorais ao endotélio facilitando metástase por via linfática e vascular (Perschbacher *et al.*, 2004) mas não diferencia entre células neoplásicas e não neoplásicas (Dubinski *et al.*, 2011).

CD34

O CD34 é uma proteína transmembrânica de cadeia simples, com aproximadamente 116 kDa, sendo expressa em células imaturas hematopoiéticas, células endoteliais progenitoras e de capilares, fibroblastos embrionários e mais raramente em células da glia em tecido nervoso (Krause *et al.*, 1996). Participa na adesão celular e na inibição da hematopoiese (Fina *et al.*, 1990), além disso é um marcador pan-endotelial robusto, de fácil uso na quantificação de angiogênese tumoral (Ding *et al.*, 2006).

Ki-67

Ki-67 é uma proteína considerada como antígeno nuclear de 395 kDa, que está presente apenas no ciclo celular nas fases S e G1 após a mitose e ausente na fase G0 (Gerdes *et al.*, 1991; Vargas *et al.*, 2008). Este anticorpo é considerado um marcador de nucléolo e a sua expressão em tumores malignos de glândulas salivares tem sido associada a um prognóstico desfavorável para o paciente (Gerdes *et al.*, 1991; Vacchi-Suzzi *et al.*, 2010). do Prado *et al.* (2011) realizaram um estudo em 66 casos de tumores benignos e malignos de glândulas salivares, encontrando maior expressão deste anticorpo em carcinoma mucoepidermóide, carcinoma adenoide cístico e adenocarcinoma polimorfo de baixo grau. Vargas *et al.* (2008) encontraram maior expressão deste marcador de proliferação celular em carcinoma adenoide cístico de padrão sólido do que no padrão cribiforme.

Ácido graxo sintase (FASN)

Ácido graxo sintase (FASN) é uma enzima anabólica funcional responsável pela síntese endógena de ácidos graxos saturados de cadeia longa, a partir dos substratos

acetil-CoA e malonil-CoA (Agostini *et al.*, 2004; Baron *et al.*, 2004; Kuhajda, 2000). Estruturalmente, FASN é um homodímero formado por duas cadeias polipeptídicas longas com massa molecular de aproximadamente 270 kDa e meia-vida de 12,2 h (Graner *et al.*, 2004).

O FASN tem uma importância significativa no rol dos seres humanos, funcionando como reservatório de energia, na lactação e reprodução. Além disso, tem sido relacionada com lesões cancerizáveis ou pré-cancerígenas (Kuhajda *et al.*, 2000). A expressão de FASN é ausente em tecidos normais, exceto no fígado, tecido adiposo, mama durante a lactação, endométrio na fase proliferativa e pulmões de recém-nascidos (Kuhajda *et al.*, 2000; Chirala *et al.*, 2003; Kusakabe *et al.*, 2002). A atividade desta enzima também é baixa na maioria dos tecidos normais, exceto os lipogênicos, uma vez que a maior parte dos ácidos graxos usados pelas células provém da dieta (Weiss *et al.*, 1986; Baron *et al.*, 2004; Menendez *et al.*, 2005).

O aumento da atividade desta enzima tem sido encontrado em vários tipos de carcinoma em mama, ovário, próstata, endométrio, cólon, esôfago, estômago, bexiga, carcinoma espinocelular bucal e melanoma e da mesma forma em sarcomas (Alo' *et al.*, 2001; Kusakabe *et al.*, 2002; Innocenzi *et al.*, 2003; Takahiro *et al.*, 2003; Visca *et al.*, 2003; Baron *et al.*, 2004; Graner *et al.*, 2004; Kapur *et al.*, 2005; Migita *et al.*, 2009; de Andrade *et al.*, 2011; Agostini *et al.*, 2004; Agostini *et al.*, 2013). Em melanomas, a alta expressão de FASN está associada a uma maior taxa de recorrência, maior risco de desenvolvimento de metástase e, conseqüentemente, pior prognóstico (Innocenzi *et al.*, 2003). FASN participa na formação de membranas celulares produzindo componentes como ácidos graxos e seus derivados (Chirala *et al.*, 2003), os quais agem como mensageiros intracelulares e também como armazenador de energia. Desse modo, sua

alta atividade proporciona vantagens para o rápido crescimento celular em neoplasias (Baron *et al.*, 2004; de Andrade *et al.*, 2011) demonstraram a expressão de FASN em melanomas orais e ausência nos nevos melanocíticos, o qual é um achado importante para diferenciar estas duas lesões.

Existem somente dois estudos sobre expressão imunohistoquímica de FASN em tumores de glândulas salivares que mostraram resultados distintos (Ito *et al.*, 2009; do Prado *et al.*, 2011). Ito *et al.*, (2009), encontraram maior expressão de FASN em carcinomas mucoepidermóides de alto grau. No entanto, Prado *et al.*, (2011), observaram maior expressão dessa enzima em tumores benignos sugerindo que FASN mantém a diferenciação celular. Além disso, não existe nenhum estudo que correlacione angiogênese e FASN em TGS.

CAPÍTULO 1.

Artigo submetido para possível publicação no periódico científico em Oral Surgery, Oral Medicine, Oral Pathology, Oral Radiology.

EXPRESSION OF BIOMARKERS RELATED TO ANGIOGENESIS AND CELLULAR PROLIFERATION IN MALIGNANT SALIVARY GLAND TUMORS.

Katya Pulido Díaz, DDS, MSc¹; Leandro Liporoni Martins, MD²; Sheila Siqueira Medeiros, DDS, PhD²; Oslei Paes de Almeida, DDS, PhD¹; Graner E, DDS, PhD¹; Rogério Gondak, DDS, PhD³; Pablo Agustin Vargas, DDS, PhD, FRCPath^{1*}

¹ Department of Oral Diagnosis, Oral Pathology, Piracicaba Dental School, University of Campinas (FOP-UNICAMP), Piracicaba, São Paulo State, Brazil.

² Division of Anatomic Pathology, Hospital das Clinicas, Faculty of Medicine, University of São Paulo (HC-FMUSP), São Paulo State, Brazil.

³Department of Pathology, Federal University of Santa Catarina, Florianópolis, Brazil.

***Corresponding author:** Prof. Pablo Agustin Vargas, FRCPath, Oral Diagnosis Department, Piracicaba Dental School, University of Campinas, Avenida Limeira 901, Piracicaba-São Paulo State, Caixa Postal 52, CEP: 13414-903, Brazil. E-mail: pavargas@fop.unicamp.br; Phone: + 55 19 2106-5319; Fax: + 55 19 2106-5218

ABSTRACT

Aims: To assess the expression of biomarkers related to angiogenesis, cell proliferation and FASN protein in malignant tumors of major and minor salivary glands, correlating the results with clinical findings such as aggressiveness, tumor size and metastasis.

Methods and results: We performed immunohistochemical study for CD31, CD34, CD105, Ki67, and FASN (Fatty acid synthase) antibodies in 52 surgical specimens from patients with malignant tumors of major and minor salivary glands. For quantification and determination of the microvascular density (MVD) of tumors, quantitative method was used with digital algorithms (Aperio ScanScope CS® System). The conventional semi-quantitative method for FASN was used. MVD analysis in intra and peritumoral areas with CD31 , CD34 and CD105 showed no statistical significance in relation to rates of cell proliferation and immunohistochemical expression of FASN ($P >0.05$). However, patients with larger tumors had higher rates of cell proliferation ($P <0.043$) and showed increased expression of FASN ($P <0.002$). **Conclusions:** These data suggest high grade malignant salivary gland tumors with high levels of Ki-67 and FASN may be associated with increased aggressiveness.

Keywords: salivary gland, immunohistochemistry, angiogenesis, cell proliferation, FASN.

INTRODUCTION

Malignant salivary gland tumors (SGT) correspond to approximately 5% of all head and neck malignancies.¹ Many studies have been focused in understanding their biological behaviour to determine appropriate prognostic parameters and new therapeutic targets.^{1,2} Angiogenesis is a process related to tumor progression and regulated at the molecular and genetic levels.^{3,4} CD105 is an accepted marker of neoangiogenesis and has been associated to a worse prognosis in different human malignant tumors.⁵⁻¹⁴ Ki67 is a nuclear proliferation antigen that is recognized as an independent prognostic factor on SGT^{15,16}. Fatty acid synthase (FASN) is a multifunctional enzyme involved in anabolic conversion of dietary carbohydrates to fatty acids^{17,9} and has been expressed in many types of carcinomas¹⁸⁻²¹ and might be a potential target in tongue squamous cell carcinoma.¹⁴

Despite the heterogeneity of histological subtypes, other factors may be correlated with the aggressiveness of malignant SGT. Thus, the aim of this study is to assess microvessel density (MVD) in malignant SGT and correlate it with FASN and Ki67 immunomarkers.

MATERIALS AND METHODS

This study was approved by the Ethics Committee for Research Project Analysis, Clinics Hospital of Medical School, University of São Paulo (Protocol #164.151). 52 surgical specimens of malignant SGTs were obtained from Department of Pathology of Medical School of University of São Paulo.

HISTOLOGICAL ANALYSIS AND CLASSIFICATION

All original hematoxylin and eosin stained slides of malignant SGT were reviewed by two experts pathologists (PAV and LAM) and classified according to WHO guidelines.²² Tumors were divided into 2 groups: high grade malignant tumors (carcinoma ex-pleomorphic adenoma, salivary duct carcinoma, oncocytic carcinoma, carcinosarcoma, high-grade of adenocarcinoma not otherwise specified, solid type of adenoid cystic carcinoma and lymphoepithelial carcinoma) and low to intermediate-grade malignant SGT (acinic cell carcinoma, low and intermediate grade mucoepidermoid carcinoma, polymorphous low-grade adenocarcinoma, adenoid cystic carcinoma cribriform-tubular pattern, epithelial-myoepithelial carcinoma, myoepithelial carcinoma and basal cell adenocarcinoma).²³

TISSUE PROCESSING

The samples were fixed in 10% formalin for 24 hours, embedded in paraffin and 3- μ m-thick histological sections were submitted for haematoxylin and eosin (H&E) staining and immunohistochemistry. Some samples were stained with Periodic acid-Schiff (PAS) and mucicarmine to contribute with the diagnosis.

IMMUNOHISTOCHEMISTRY

For MVD evaluation CD31 and CD34 (panendothelial markers) and CD105 endoglin (neoangiogenic marker) antibodies were used.

Antigen retrieval with citrate (pH 6.0) was performed for CD34, CD105 and Ki67 antibodies whereas EDTA/Tris (pH 9.0) retrieval was used for CD31 and FASN

antibodies. The slides were incubated with secondary antibodies conjugated with horseradish peroxidase [labelled streptavidin biotin (LSAB)] and system-horseradish peroxidase (HRP), mouse/rabbit; Dako) for 30 min at 37°C. After this, the slides were incubated with streptavidin-HRP (Dako) for another 30 min and developed with a chromogenic substrate [3,3 diaminobenzidine (DAB); Sigma, St Louis, MO, USA]. The slides were counterstained with Harris haematoxylin. Negative controls were obtained by omitting primary antibodies. Dilution and additional information about primary antibodies used in the study are shown in **Table 1**.

NUCLEAR IMAGE ANALYSIS FOR KI-67

Labeling index for ki-67 was performed using the Nuclear V9 Algorithm (Aperio Technologies, Inc., Vista, CA, USA).²⁴ This digital method detects the nuclear staining classified as 0 (blue), 1+ (yellow), 2+ (orange) and 3+ (red) based on nuclear staining intensity. A nucleus is classified 0 when it has no nuclear staining, 1+ as weak nuclear staining, 2+ as moderate nuclear staining and 3+ as intense nuclear staining. For the correct quantization of the staining and avoid background staining, it was considered just the nuclei classified as 2+ and 3+. A minimum area of 1mm² of tumor tissue was considered and the microscopic analysis was performed at full x200 magnification. The results were provided in percentage of positive nuclei (**Figures 1A and 1B**).

MICROVESSEL DENSITY DIGITAL ANALYSIS

Glass slides were scanned with the ScanScope CS® scanner (Aperio Technologies, Inc., Vista, CA, USA), which automatically created the high-quality resolution digital image. Digital analysis of the microvascular density was performed

using Microvessel Analysis V1 Algorithm (Aperio Technologies, Inc., Vista, CA, USA).²⁵ Three intratumoral and 3 peritumoral “hot-spot” areas were selected to determine vascular density (number of vessels/mm²) in each case (**Figure 1C and 1D**).

SEMI-QUANTITATIVE ANALYSIS FOR FASN ANTIBODIE

FASN staining were evaluated using conventional semi-quantitative analysis in accordance with Innocenzi et al., 2003.¹⁸ SGTs were classified as follows: 0 (negative), 1+ (low intensity); 2+ (moderate) and 3+ (strong). The fraction of positive cells was estimated as follows: <10%=1, 11-50%=2, 51-80%=3, >80%=4. (original magnification 200X).

STATISTICAL ANALYSIS

Statistical analyses were performed with SPSS software version 17.0 (Chicago, IL, USA). Statistical differences between groups were estimated using a standart non parametric test (Mann-Whitney U-test) and the clinical correlations were tested with contingency tables using Fisher’s exact test (two variables) or χ^2 (three or more variables). The significance level was 5% for all statistical tests.

RESULTS

CLINICAL FINDINGS

The group with malignant SGT classified as low-grade consisted of 12 males and 21 females. The mean age was 50.2 ± 21.9 years (ranging from 13 to 87 years). Acinic cell carcinoma and polymorphous low-grade adenocarcinoma occurred in 57.5%

of the patients and 60.6% of the tumours involved parotid glands. In addition, 17.6% of the patients developed distant metastasis.

The group with high-grade malignant SGT consisted of 8 males and 10 females. The mean age was 56.9 ± 9.1 years (ranging from 42 to 79 years). Salivary duct carcinoma and carcinoma ex-pleomorphic adenoma affected 55.5% of the patients and 77.7% of the tumours involved parotid glands. Regarding the clinical behavior, 27.8% of the patients developed distant metastasis.

The malignant SGT included in this study presented different histologic types: 13 (25%) acinic cell carcinomas, 7 (13.4%) adenoid cystic carcinomas, 6 (11.5%) polymorphous low-grade adenocarcinomas, 6 (11.5%) carcinoma ex-pleomorphic adenomas, 4 (7.6%) salivary duct carcinomas, 4 (7.6%) mucoepidermoid carcinomas, 1 (5.7%) basal cell adenocarcinomas, 2 (3.8%) epithelial-myoepithelial carcinomas, 2 (3.8%) oncocytic carcinomas, 2 (3.8%) high-grade adenocarcinomas not otherwise specified, 1 (2%) lymphoepithelial carcinoma, 1 (2%) papillary cystadenocarcinoma, 1 (2%) carcinosarcoma and 1 (2%) myoepithelial carcinoma.

The main clinical features of the current series of 52 patients with malignant SGT are summarized in **Table 2**.

CELL PROLIFERATION

The percentage of Ki-67 immunostaining of high-grade malignant salivary gland tumours varied between 0.56% and 58.0% whereas low to intermediate-grade tumours varied between 0.3% and 21.3%. Ki-67 levels were significantly higher in patients with high-grade malignant salivary gland tumors compared to patients with low-grade ($P = 0.006$) (**Figure 2B and 2C**).

Tumours diagnosed as carcinoma ex-pleomorphic adenoma presented higher levels of cell proliferation than other tumors and patients with malignant SGT classified as T3 showed statistical significance in relation to patients with tumours classified as T1 ($P = 0.043$).

SEMI-QUANTITATIVE ANALYSIS OF FASN EXPRESSION

High-grade malignant SGT revealed higher FASN expression than low-grade neoplasias ($P = 0.003$). Although there was no statistically significant difference between FASN expression and microvessel density, the tumours that had higher levels of cell proliferation had stronger expression of FASN (**Table 4, Figure 2A and 2B**).

The immunopattern expression of FASN was cytoplasmic in all samples. The cases of high grade SGT as a salivary ductal carcinoma, carcinoma ex-pleomorphic adenoma, solid type of adenoid cystic carcinoma, carcinosarcoma, basal cell adenocarcinoma and oncocytic carcinoma were positive in all tumor cells. We also found focal intense expression in papilliferous areas for FASN in a few cases of intermediate to low-grade SGT as polymorphous low-grade adenocarcinoma (n= 3), acinic cell carcinoma (n= 2), epithelial-myopithelial carcinoma (n= 1), and cystadenocarcinoma (n= 1). Adenoid cystic adenocarcinoma (n= 5), polymorphous low-grade adenocarcinoma (n= 1) and solid type acinic cell carcinoma (n= 3) showed weak to moderate expression for FASN. The others low-grade SGTs like mucoepidermoid carcinoma (n= 4), polymorphous low-grade adenocarcinoma (n= 1), epithelial-myoeipithelial carcinoma (n= 1) and acinic cell carcinoma (n= 3) presented no immunoreactivity for FASN.

EVALUATION OF INTRA AND PERITUMORAL MICROVESSEL DENSITY

The median of microvessel density (MVD) determined by antibodies against CD31, CD34 and CD105 was higher in the intratumoral regions of the tumors than peritumoral regions but not significant ($P > 0.05$) (**Figure 2E and 2F**).

Oncocytic carcinoma had higher MVD ($63.75/\text{mm}^2$) than the other malignant SGTs, and epithelial-myoeplithelial carcinoma had the lower MVD ($40.6/\text{mm}^2$) when using panendothelial markers (CD31, CD34). Angiogenic antibody (CD105) also had higher MVD in oncocytic carcinoma ($115.5/\text{mm}^2$), and lower MVD in epithelial-myoeplithelial carcinoma ($10/\text{mm}^2$).

It was not possible to identify any significant correlation between intra and peritumoral vascular densities with Ki67 proliferative index in any of the groups studied (**Table 3**).

DISCUSSION

Microvessel density analysis (MVD) was first introduced in 1991 by Weidner *et al.*,²⁶ with the aim of measuring tumor angiogenesis. CD31 also known as PECAM-1 (Platelet Endothelial Cell Adhesion Molecule 1) and CD34 have been used in malignant SGT and its expression in mature and immature endothelial cells, which may be involved into the process of vascular metastasis.^{15,27,28} We tested panendothelial markers (CD31, CD34) as complementary tools of MVD, however CD105 (endoglin) is considered the best neoangiogenic marker and might be used as a prognostic factor in SGT.^{29,30} The role of angiogenesis on various histopathological types of SGT has been reported in some papers.²⁹⁻³³ We did not observe correlation between high grade malignant SGT and panendothelial or angiogenic markers, in contrast with the findings

reported by Dhanuthai *et al.*,³² in a series of 43 SGTs, where they observed higher expression of MVD using CD105 antibody by immunohistochemistry on malignant SGTs. The current findings showed that a higher MVD was present in intratumoral areas.

Ki-67 antibody is the most widely used marker for cell proliferating in SGTs.^{34,35} In the current study, this protein was mainly expressed in high grade malignant SGT ($P= 0.006$), similarly to previous studies.^{35,36} The present findings also showed higher cellular proliferation in carcinoma ex-pleomorphic adenoma than in the other malignancies, probably because of its highly invasive malignant component.

There are several studies that evaluated Ki-67 expression in many different subtypes of salivary gland carcinomas. The present work demonstrated that cellular proliferation is higher in high grade malignant SGTs than low-grade ones, despite the diversity of histopathological subtypes included in our sample. Larsten *et al.*,¹² reported that ki67 antibody is an important independent prognostic factor in a series of 13 subtypes of malignant SGTs. It is important to mention that T3 classification in our series presented higher cell proliferation than T1 ($P= 0.043$) as reported in similar studies.^{1,2,37}

FASN is a molecule with complex functions and has an important role in the activation of lipogenesis in many types of malignant tumors.^{5,8,14,20,21,38} There are only two reports in the English-language literature using FASN in SGTs.^{39,40} do Prado *et al.*,⁴⁰ evaluated the expression of FASN on adenoid cystic carcinoma, polymorphous low grade adenocarcinoma and pleomorphic adenoma, describing an increased expression in the benign entity. In contrast, Ito *et al.*,³⁹ showed higher expression of FASN on mucoepidermoid carcinomas than pleomorphic adenomas. In the current

series, FASN had different patterns of expression. In salivary duct carcinomas and carcinosarcoma the expression was intense, whereas in acinic cell carcinoma the expression was higher in papillary component than in the solid cystic area. At the same time, polymorphous low grade adenocarcinoma presented more immunoreactivity in cases with papillary pattern and all carcinoma ex-pleomorphic adenomas had strong expression only on malignant component. In adenoid cystic carcinoma, FASN was homogeneously expressed in the myoepithelial component and solid areas had intense immunoreactivity.

In summary, FASN associated to Ki67 were indicators of aggressiveness in high grade malignant SGTs having no correlation with angiogenic proliferation. Further studies with larger samples might be needed to confirm our findings.

ACKNOWLEDGEMENTS

This study was supported by Brazilian Programme for Post Graduate Students (PEC-PG/process:5881102) and the Coordination for the Improvement of Higher Education Personnel (CAPES). There were no conflicts to interest. We also thank Douglas Moreira and Rafael de Oliveira for their assistance with material collection.

REFERENCES

1. Bell RB, Dierks EJ, Homer L, Potter BE. Management and outcome of patients with malignant salivary gland tumors. *J Oral Maxillofac Surg.* 2005;63:917-28.
2. Speight PM, Barrett AW. Prognostic factors in malignant tumours of the salivary glands. *Br J Oral Maxillofac Surg.* 2009;47:587-93.
3. Folkman J. Tumor angiogenesis: therapeutic implications. *N Engl J Med.* 1971;285:1182-6.
4. Folkman. Fundamental concepts of the angiogenic process. *Curr Mol Med* 2003; 3:643-51.
5. Alo' PL, Visca P, Marci A, Mangoni A, Botti C, Di Tondo U. Expression of fatty acid synthase (FAS) as a predictor of recurrence in stage I breast carcinoma patients. *Cancer.* 1996;77:474-82.
6. Schoell WM, Pieber D, Reich O, Lahousen M, Janicek M, Guecer F, Winter R. Tumor angiogenesis as a prognostic factor in ovarian carcinoma: quantification of endothelial immunoreactivity by image analysis. *Cancer.* 1997;80:2257-62.
7. Kumar S, Ghellal A, Li C, Byrne G, Haboubi N, Wang JM, Bundred N. Breast carcinoma: vascular density determined using CD105 antibody correlates with tumor prognosis. *Cancer Res.* 1999;59:856-61.
8. Alo' PL, Visca P, Framarino ML, Botti C, Monaco S, Sebastiani V *et al.* Immunohistochemical study of fatty acid synthase in ovarian neoplasms. *Oncol Rep.* 2000;7:1383-8.
9. Kuhajda FP, Pizer ES, Li JN, Mani NS, Frehywot GL, Townsend CA. Synthesis and antitumor activity of an inhibitor of fatty acid synthase. *Proc Natl Acad Sci*

- U S A. 2000;97:3450-4.
10. Chien CY, Su CY, Hwang CF, Chuang HC, Chen CM, Huang CC. High expressions of CD105 and VEGF in early oral cancer predict potential cervical metastasis. *J Surg Oncol.* 2006;94:413-7.
 11. Chuang HC, Su CY, Huang HY, Chien CY, Chen CM, Huang CC. High expression of CD105 as a prognostic predictor of early tongue cancer. *Laryngoscope.* 2006;116:1175-9.
 12. Kyzas PA, Agnantis NJ, Stefanou D. Endoglin (CD105) as a prognostic factor in head and neck squamous cell carcinoma. *Virchows Arch.* 2006;448:768-75.
 13. Zijlmans HJ, Fleuren GJ, Hazelbag S, Sier CF, Dreef EJ, Kenter GG, Gorter A. Expression of endoglin (CD105) in cervical cancer. *Br J Cancer.* 2009;100:1617-26.882-9.
 14. Agostini M, Almeida LY, Bastos DC, Ortega RM, Moreira FS, Seguin F, Zecchin KG, Raposo HF, Oliveira HC, Amoêdo ND, Salo T, Coletta RD, Graner E. The fatty acid synthase inhibitor orlistat reduces the growth and metastasis of orthotopic tongue oral squamous cell carcinomas. *Mol Cancer Ther.* 2013 Dec 20. [Epub ahead of print].
 15. Luukkaa H, Klemi P, Leivo I, Vahlberg T, Grénman R. Prognostic significance of Ki-67 and p53 as tumor markers in salivary gland malignancies in Finland: an evaluation of 212 cases. *Acta Oncol.* 2006;45:669-75.
 16. Larsen SR, Bjørndal K, Godballe C, Krogdahl A. Prognostic significance of Ki-67 in salivary gland carcinomas. *J Oral Pathol Med.* 2012;41:598-602.
 17. Jayakumar A, Tai MH, Huang WY, al-Feel W, Hsu M, Abu-Elheiga L, Chirala SS, Wakil SJ. Human fatty acid synthase: properties and molecular cloning.

- Proc Natl Acad Sci U S A. 1995;92:8695-9.
18. Innocenzi D, Alò PL, Balzani A, Sebastiani B, Silipo V, La Torre G, Riccirardi G, et al. Fatty acid synthase expression in melanoma. *J Cutan Pathol.* 2003;30:23-8.
 19. Baron A, Migita T, Tang D, Loda M. Fatty acid synthase: a metabolic oncogene in prostate cancer? *J Cell Biochem.* 2004;91:47-53.
 20. Kusakabe T, Nashimoto A, Honma K, Suzuki T. Fatty acid synthase is highly expressed in carcinoma, adenoma and in regenerative epithelium and intestinal metaplasia of the stomach. *Histopathology.* 2002;40:71-9.
 21. de Andrade BA, León JE, Carlos R, Delgado-Azañero W, Mosqueda-Taylor A, Graner E, de Almeida OP. Expression of fatty acid synthase (FASN) in oral nevi and melanoma. *Oral Dis.* 2011;17:808-12.
 22. Barnes L, Eveson JW, Relchart P, Sidransky D. eds. Tumors of the salivary glands. In: *World Health Organization Classification of Tumours: Pathology and Genetics of Head and Neck Tumours.* Lyon, France: IARC Press; 2005:209-281.
 23. Stenner M, Klussman JP. Current update on established and novel biomarkers in salivary gland carcinoma pathology and molecular pathways involved. *Eur Arch Otorhinolaryngol.* 2009; 266:333-41.
 24. Aperio technologies. *Microvessel analysis algorithm user's guide.* Vista, CA: Aperio Technologies 2009;9-27.
 25. Aperio technologies. *Algorithm user guide: nuclear quantification.* Vista, CA: Aperio Technologies 2011;1-7.
 26. Weidner N, Semple JP, Welch WR, Folkman J. Tumor angiogenesis and metastasis--correlation in invasive breast carcinoma. *N Engl J Med.* 1991;

- 3;324:1-8.
27. Pershbacher K, Jackson-Boeters L, Daley T. The adhesion molecules NCAM, HCAM, PECAM-1 and ICAM-1 in normal salivary gland tissues and salivary gland malignancies. *J Oral Pathol Med.* 2004;33:230-6.
 28. Luukkaa H, Laitakari J, Vahlberg T, Klemi P, Stenbäck F, Grénman R. Morphometric analysis of CD34-positive vessels in salivary gland adenoid cystic and mucoepidermoid carcinomas. *J Oral Pathol Med.* 2009;38:695-700.
 29. Soares AB, Ponchio L, Juliano PB, de Araújo VC, Altemani A. Lymphatic vascular density and lymphangiogenesis during tumour progression of carcinoma ex-pleomorphic adenoma. *J Clin Pathol.* 2007;60:995-1000.
 30. Costa AF, Demasi AP, Bonfitto VL, Bonfitto JF, Furuse C, Araújo VC, Metze K, Altemani A. Angiogenesis in salivary carcinomas with and without myoepithelial differentiation. *Virchows Arch.* 2008;453:359-67.
 31. Cardoso SV, Souza KC, Faria PR, Eisenberg AL, Dias FL, Loyola AM. Assessment of angiogenesis by CD105 antigen in epithelial salivary gland neoplasms with diverse metastatic behavior. *BMC Cancer.* 2009 Nov 4;9:391.
 32. Dhanuthai K, Sappayatosok K, Yodsanga S, Rojanawatsirivej S, Pausch NC, Pitak-Arnop P. An analysis of microvessel density in salivary gland tumours: a single centre study. *Surgeon.* 2013;11:147-52.
 33. Mărgăritescu C, Munteanu MC, Nițulescu NC, Cionca L, Cotoi OS, Paskova G. Acinic cell carcinoma of the salivary glands: an immunohistochemical study of angiogenesis in 12 cases. *Rom J Morphol Embryol.* 2013;54:275-84.
 34. Cheuk W, Chan JK. Advances in salivary gland pathology. *Histopathology.* 2007;51:1-20.

35. Vargas PA, Cheng Y, Barrett AW, Craig GT, Speight PM. Expression of Mcm-2, Ki-67 and geminin in benign and malignant salivary gland tumours. *J Oral Pathol Med.* 2008;37:309-18.
36. Alves FA, Pires FR, De Almeida OP, Lopes MA, Kowalski LP. PCNA, Ki-67 and p53 expressions in submandibular salivary gland tumours. *Int J Oral Maxillofac Surg.* 2004;33:593-7.
37. Lima RA, Tavares MR, Dias FL, Kligerman J, Nascimento MF, Barbosa MM, Cernea CR, Soares JR, Santos IC, Salviano S. Clinical prognostic factors in malignant parotid gland tumors. *Otolaryngol Head Neck Surg.* 2005;133:702-8.
38. Silva SD, Agostini M, Nishimoto IN, Coletta RD, Alves FA, Lopes MA *et al.* Expression of fatty acid synthase, ErbB2 and Ki-67 in head and neck squamous cell carcinoma. A clinicopathological study. *Oral Oncol.* 2004;40:688-96.
39. Ito FA, Ito K, Coletta RD, Graner E, de Almeida OP, Lopes MA. Salivary gland tumors: immunohistochemical study of EGF, EGFR, ErbB-2, FAS and Ki-67. *Anal Quant Cytol Histol.* 2009;31:280-7.
40. do Prado RF, da Silva Machado AL, Colombo CE, Carvalho YR. Immunohistochemical study of the expression of fatty acid synthase and Ki-67 in salivary gland tumors. *J Oral Pathol Med.* 2011;40:467-75.

1. TABLES

Table 1. Primary antibodies used for immunohistochemical analysis.

Primary antibody	Clone	Dilution	Source
CD105	SNGH	1:30	Dako®
CD34	QBEnd 10	1:50	Dako®
CD31	IC70A	1:200	Dako®
FASN	Polyclonal	1:200	Dako®
KI67	QBEnd 10	1:100	Dako®

Table 2. Clinical data of patients with low and high-grade malignant salivary gland tumors.

Variable	Total	No. of patients (%)		P-value
		Low-grade	High-grade	
Sex				
Male	20	12 (60.0)	8 (40.0)	0,313 ^a
Female	31	21 (67.8)	10 (32.2)	
Age				
> 50 years	33	20 (57.6)	14 (42.4)	0,382 ^a
≤ 50 years	18	14 (77.8)	4 (22.2)	
Salivary glands				
Major glands	38	22 (57.9)	16 (42.1)	0,177 ^a
Minor glands	13	11 (84.6)	2 (15.4)	
Tumor stage				
T1	15	13 (86.7)	2 (13.3)	0,874 ^b
T2	19	10 (58.9)	9 (47.4)	
T3	17	11 (64.7)	7 (41.1)	

^aFischer exact test. ^b χ^2 Test

Table 3. Intra and peritumoral microvessel density (vessels/mm²) for CD31, CD34, CD105 and cell proliferation level for Ki-67 (%).

	Low-grade (n=34)	High-grade (n=18)	P-value
CD31-IMVD	40.8±22.1	49.8±25.2	0.431
CD31-PMVD	31.4±20.7	35.0±22.3	0.564
CD34-IMVD	73.8±30.6	66.5±21.1	0.370
CD34-PMVD	55.1±25.8	53.2±26.4	0.891
CD105-IMVD	40.3±25.7	45.3±21.7	0.488
CD105-PMVD	30.8±20.8	35.0±27.3	0.303
Ki-67	5.6±8.4	15.2±16.8	0.006*

IMD, Intratumoral microvessel density. PMD, Peritumoral microvessel density.

Table 4. FASN expression in the low and high-grade malignant salivary gland tumors.

	Low-grade (n=34)				High-grade (n=18)				P-value
FASN **	0	1+	2+	3+	0	1+	2+	3+	
Patients(%)	8 (23.5)	8 (23.5)	10 (29.5)	8 (23.5)	0 (0.0)	2 (11.1)	2 (11.1)	14 (77.8)	0.003*

**FASN intensity

FIGURES AND LEGENDS

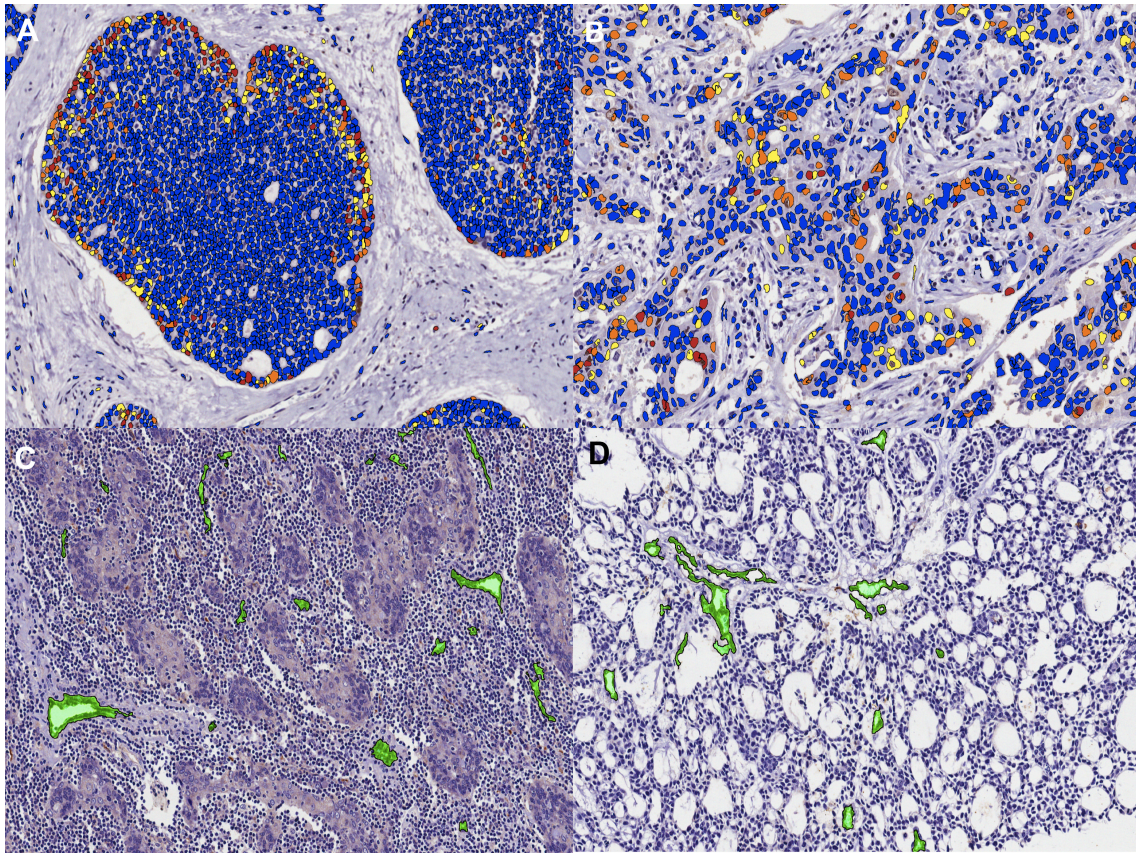


FIGURE 1. Digital microvessel density and nuclear proliferation assessed by Image Scope software. **A.** Nuclear Image Analysis algorithm method measuring nuclear proliferation (Ki-67, original magnification 200X) in solid type of adenoid cystic carcinoma according to specific color (blue = negative, yellow = weakly positive, orange = medium positive, red = strongly positive); **B.** Salivary duct carcinoma measuring nuclear proliferation (original magnification 400X); **C.** Selected vessels stained in green in lymphoepithelial carcinoma (CD34, original magnification 200X); **D.** Cribriform type of adenoid cystic carcinoma (CD105, original magnification 200X).

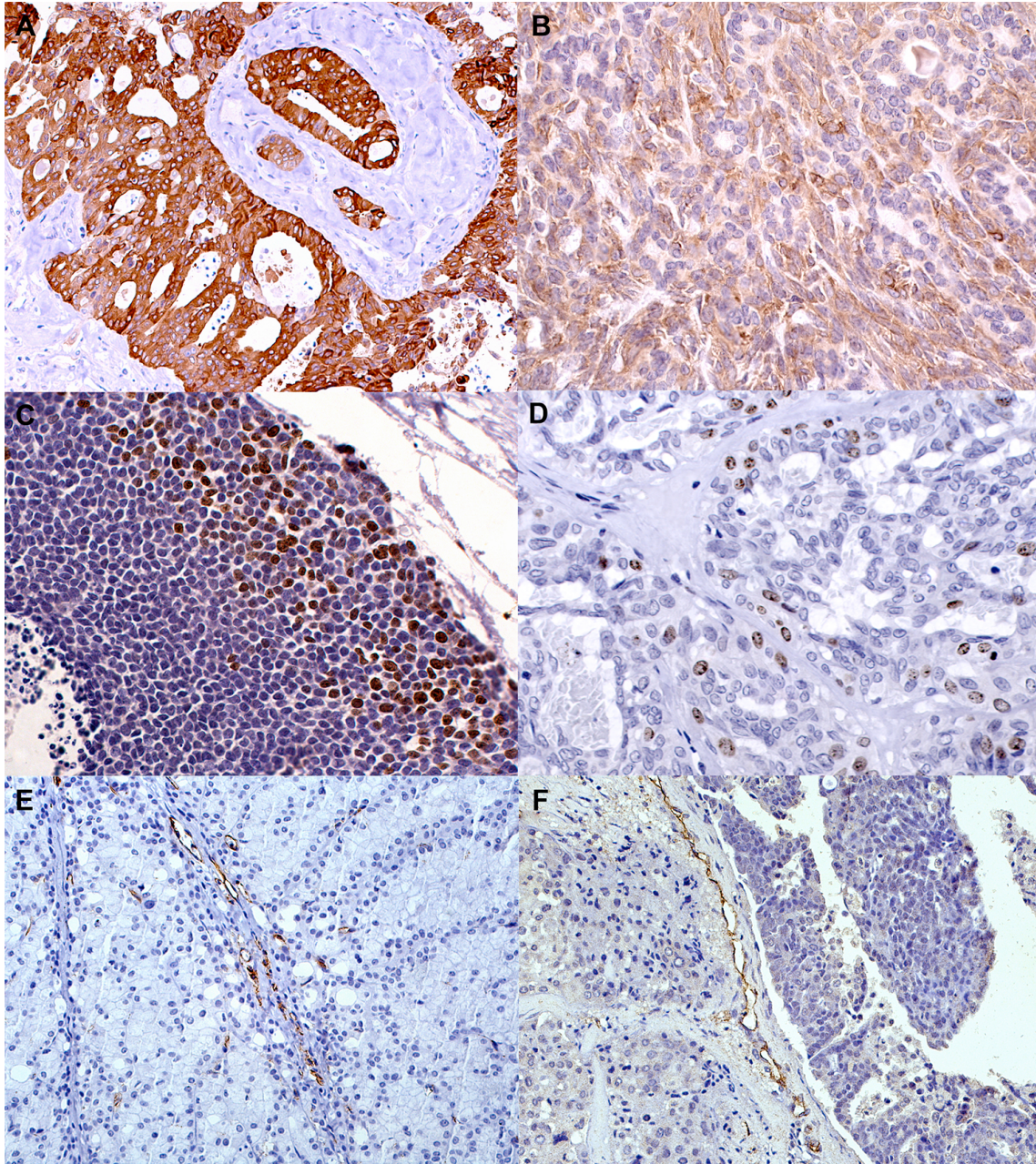


Figure 2. **A.** Intense FASN expression in salivary duct carcinoma (original magnification 200X); **B.** Low intensity expression of FASN in epithelial-myoepithelial carcinoma (original magnification 200X); **C.** High immunoreactivity of Ki67 in adenoid cystic carcinoma (original magnification 200X); **D.** Lower immunoreactivity of Ki67 in polymorphous low-grade adenocarcinoma (original magnification 200X); **E.** CD34 positive intratumoral vessels in acinic cell carcinoma; **F.** CD105 positive intratumoral vessels in salivary ductal carcinoma (original magnification 200X).

CAPÍTULO 2.

Artigo submetido para possível publicação no periódico científico Head and Neck Pathology.

FATTY ACID SYNTHASE (FASN) AND Ki67 IMMUNOEXPRESSION CAN BE USEFUL-FOR THE IDENTIFICATION OF MALIGNANT COMPONENT IN CARCINOMA EX-PLEOMORPHIC ADENOMA.

Katya Pulido Díaz, DDS, MSc¹, Leandro Liporoni Martins, DDS², Rogério Gondak, DDS, PhD³, Oslei Paes de Almeida, DDS, PhD¹, Jorge Esquiche León, DDS, PhD⁴, Pablo Agustin Vargas, DDS, PhD, FRCPath*¹

¹ Department of Oral Diagnosis, Oral Pathology, Piracicaba Dental School, University of Campinas (FOP-UNICAMP), Piracicaba, Brazil.

² Department of Pathology, Clinics Hospital University of São Paulo School of Medicine (HC-FMUSP), São Paulo, Brazil.

³ Department of Pathology, Federal University of Santa Catarina, Florianópolis, Brazil

⁴ Oral Pathology Section, Department of Stomatology, Public Oral Health, and Forensic Dentistry. Dental School of Ribeirão Preto, University of São Paulo, Ribeirão Preto, Brazil

***Corresponding author:** Prof. Pablo Agustin Vargas, FRCPath, Oral Diagnosis Department, Piracicaba Dental School, University of Campinas, Avenida Limeira 901, Piracicaba-São Paulo State, Caixa Postal 52, CEP: 13414-903, Brazil. E-mail: pavargas@fop.unicamp.br; Phone: + 55 19 2106-5319; Fax: + 55 19 2106-5218

ABSTRACT

AIMS: FASN is overexpressed in a variety of human cancers, then we evaluated the FASN expression in benign and malignant components of Carcinoma Ex-Pleomorphic Adenoma (CXPA) and correlated with tumor cell proliferation assessed by Ki67 immunostaining. **METHODS AND RESULTS:** FASN and Ki67 antibodies were carried out on 6 CXPA and 12 pleomorphic adenomas (PA). Labeling index for ki-67 was performed by using the Nuclear V9 algorithm method. Ki-67 levels were significantly higher in patients with CXPA who had a mean percentage of 7.7% ranging between 0.5% and 13.2% ($P < 0.001$). We found intense immunoreactivity for FASN in the malignant component of CXPA and these malignant areas also presented intense nuclear immunoreactivity for Ki67. **CONCLUSION:** The present results suggest that overexpression of FASN in CXPA might be associated with malignant transformation of ductal epithelial cells and/or myoepithelial cells from PA. FASN associated to Ki67 may be an useful diagnostic markers for CXPA.

Keywords: FASN, carcinoma ex-pleomorphic adenoma, salivary gland tumors.

INTRODUCTION

Fatty Acid Synthase (FASN) is a key enzyme for the endogenous synthesis of saturated long-chain fatty acids from the carbon substrates acetyl-CoA and malonyl-CoA.^{1,2} In most normal human tissues FASN is downregulated, because cells preferentially use circulating dietary fatty acids for the synthesis of new structural lipids.^{1,2} It has been reported that tumor cells express high levels of FASN, for endogenous fatty acid production. The abnormal FASN production may indicate a high proliferative rate of tumor cells, suggesting the need of fatty acids for the synthesis of cell membranes in dividing cells. In fact, FASN is overexpressed in a variety of human cancers affecting the skin, breast, ovaries, prostate, bladder, lung, gastric, oral cavity, colon, endometrium, and thyroid.³⁻¹² However, its expression in salivary gland tumors (SGTs) is poorly understood. There are only 2 investigations evaluating FASN immunoexpression in SGTs.^{13,14} These studies have showed a variable FASN expression pattern in both benign and malignant tumors, but none of them focused on the FASN immunoexpression patterns in benign and malignant component of carcinoma ex-pleomorphic adenoma (CXPA). Therefore, further studies are needed to clarify the role of FASN in the pathogenesis of this entity.

CXPA is typically considered as a high-grade malignant SGT, accounting for approximately 3.6% of all SGTs.^{15,16} The identification of early carcinomatous transformation of pleomorphic adenoma (PA) may be problematic. In these cases, an infiltrative and destructive growth pattern is necessary to substantiate the diagnosis of carcinoma.¹⁶

Earlier studies have reported that HER2/neu, p53, androgen receptor (AR), bcl-2, and Ki-67 expression are overexpressed in CXPA compared with PAs, suggesting that these molecules may play a role in the malignant transformation of PA, and may serve as specific markers to distinguish CXPA from PA.¹⁷ However, it has also been reported that approximately 5% to 10% of PAs express HER2/neu, AR, and p53.¹⁸

FASN is overexpressed in a variety of human cancers, and then we decided to evaluate FASN expression in benign and malignant components of Carcinoma Ex-Pleomorphic Adenoma (CXPA) and correlate it with Ki67 expression.

MATERIAL AND METHODS

The Ethics Committee of the Medical School of São Paulo University approved this study (Protocol #164.151). Medical records and paraffin-embedded tissues of 12 patients with PA and 6 patients with CXPA were collected from the archives of the Hospital das Clinicas at the University of São Paulo, School of Medicine between 2000 to 2012. CXPA cases were classified according to the extension of invasion of malignant component: 2 cases classified as intracapsular, 1 minimally invasive and 3 frankly invasive.¹⁶

IMMUNOHISTOCHEMISTRY

Polyclonal FASN antibody (Dako® polyclonal 1:200) was carried out for the identification of malignant component of CXPA. Monoclonal antibodies against Ki67 (Dako®, clone MIB1, dilution 1:50).

Immunohistochemistry staining was performed in 3 μm thick tissue sections cut from paraffin-embedded previously fixed in 10% formalin. After deparaffinization and rehydration in ethanol solutions, antigen retrieval was performed. Afterward endogenous peroxidase activity was blocked with 20% H_2O_2 for 5 cycles of 5 minutes each. The slides were incubated with primary antibodies after washing in PBS buffer (pH 7.4) and subsequently exposed to secondary antibodies (LSAB Kit-Dako Cytomation) and developed with chromogenic substrate (diaminobenzidine-hydrochloride DAB Sigma-Aldrich, St Louis, MO, USA). The slides were counterstained with Harris hematoxylin. Negative controls were obtained by omitting primary antibodies.

NUCLEAR IMAGE ANALYSIS FOR KI-67

Labeling index for ki-67 was performed by using the Nuclear V9 algorithm (Aperio Technologies, Inc., Vista, CA, USA) (Aperio technologies, 2011). This virtual method detects the nuclear staining classified as 0 (blue), 1+ (yellow), 2+ (orange) and 3+ (red) based on nuclear staining intensity. A nucleus is classified 0 when it has no nuclear staining, 1+ as weak nuclear staining, 2+ as moderate nuclear staining and 3+ as intense nuclear staining. For the correct quantization of the staining and avoid background staining, it was considered just the nuclei classified as 2+ and 3+. A minimum area of 1mm^2 of tumor tissue was considered and the microscopic analysis was performed at full x200 magnification. The results were provided in percentage of positive nuclei.

SEMI-QUANTITATIVE ANALYSIS FOR FASN

Immunoexpression of FASN in CXPA were classified as follows: 0 (negative), 1+ (low intensity); 2+ (moderate) and 3+ (strong). The fraction of positive cells was estimated as follows: <10%=1, 11-50%=2, 51-80%=3, >80%=4. (original magnification 200X).²

STATISTICAL ANALYSIS

Statistical differences between groups were estimated using a standard non-parametric test (Mann-Whitney U-test). Differences at $P < 0.05$ were considered as statistically significant. The statistical software SPSS version 17.0 (Chicago, IL, USA) was used for the analyses.

RESULTS

CLINICAL FINDINGS

The group PA consisted of 3 males and 9 females. The mean age was 47.6 ± 20.3 years (ranging from 13 to 84 years). Parotid gland was affected by PA in 66.6% of the patients and submandibular gland in 33.4%. The average tumor size was 1.6 cm, ranging from 0.8 to 2.4 cm.

The group with CXPA consisted of 2 males and 4 females. The mean age was 55.0 ± 6.57 years (ranging from 42 to 60 years). CXPA involved parotid gland in 66.6% of the patients, submandibular gland in 16.7% and minor salivary glands (palate) in

16.7%. The average tumor size was 3.8 cm, ranging from 1.6 to 5.0 cm. Regarding clinical behavior, no patients developed distant metastasis.

CELL PROLIFERATION

The mean percentage of Ki-67 immunostaining of PA was 0.09% ranging between 0 and 0.21%. Ki-67 levels were significantly higher in patients with CXPA who had a mean percentage of 7.7% ranging between 0.5% and 13.2% ($P < 0.001$).

Patients with CXPA classified as T3 had higher levels of Ki-67 immunostaining than patients classified as T2 or T1 and tumors that affected parotid gland had higher percentage of Ki-67 than tumors that involved submandibular gland ($P = 0.052$). There was no statistical correlation between levels of cell proliferation and the age or gender of the patients.

MICROSCOPICAL FINDINGS

All the PAs showed ductal structures surrounded by myoepithelial and epithelial cells, in hyaline or myxoid stroma (**Figures 1A-C**) and only 3 cases of PA were predominantly myxoid. Histologically, CXPAs showed the transition of benign pleomorphic adenoma into carcinoma (**Figure 1D**). The carcinomatous component of the current cases corresponded to 2 salivary ductal adenocarcinomas, 1 adenocarcinoma not otherwise specified, 1 polymorphous low-grade adenocarcinoma and 2 myoepithelial carcinomas and all of them showed markedly expression of FASN on this malignant component (**Figure 1E**).

SEMIQUANTITATIVE FASN EXPRESSION

High FASN expression (3+) was observed in all patients with CXPA. Patients with PA revealed significantly lower FASN expression than patients with CXPA ($P < 0.001$). PA showed no FASN expression in 58.3% of the cases, weak expression (1+) in 8.3% and moderate expression (2+) in 33.4%. None patient with PA had high FASN expression (3+). There was no statistically significant difference between FASN expression and anatomic region or tumor size (**Table 1**).

We found intense immunoreactivity for FASN in the malignant component of CXPAs and these malignant areas also presented intense nuclear immunoreactivity for Ki67 (**Figures 2 A-D**). The current results showed a strikingly sharp immunoexpression of FASN in the malignant component in all CXPAs.

DISCUSSION

Pleomorphic adenoma is the most common salivary gland tumor and mainly affects the parotid gland.²⁰⁻²³ In the current series females were more affected than males, which are in accordance with other epidemiological studies of SGTs.^{21,23,24,25} CXPA arising from pleomorphic adenoma and the carcinomatous component is variable, although salivary duct carcinoma is one of the most observed histopathological malignant component of CXPA²⁶ as seen in our two cases.

It is well known that CXPA can present aggressive biological behaviour, and Ki67 and p53 proteins have been used to investigate the proliferative activity of tumor cells in CXPA.^{26,27} We found that the high expression of Ki-67 in the malignant cells associated to FASN immunoreactivity can be a helpful diagnostic tool in the

identification of the malignant component of CXPA. However, do Prado *et al.*,¹⁴ reported FASN immunoreactivity in ductal and/or myoepithelial cells of PAs, and found FASN positivity in a single case of CXPA. We disagree that the expression of FASN on SGTs means that maintains cell differentiation and do Prado *et al.*, did not perform antigenic retrieval for FASN. The present results demonstrated that Ki-67 had a low (0.09%) expression in PAs and there was no expression of FASN in the myoepithelial cells or stromal component. However, 9 PAs showed focal FASN positivity preferentially on ductal cells (**Figure 1B**), but no positivity for Ki-67 was detected in these areas. These findings probably indicate the complex biological profile observed in some PA cases, highlighting the heterogeneous proliferative potential of different cellular components of PAs. Altemani *et al.*,¹⁶ showed that the malignant component of CXPA is composed by epithelial cells that arise in duct-cell structures. Based in the current results, FASN immunoexpression seems to be valuable for identifying the malignant component of CXPA. Thus, we suggested that the malignant component of CXPA can be identified using Ki-67 and FASN antibodies.

In conclusion, the present results suggest that the overexpression of FASN is associated with the malignant transformation of ductal epithelial cells and/or myoepithelial cells of PA. FASN may be a useful diagnostic marker for CXPA, in combination with Ki-67. Further studies assessing larger series of CXPA are needed to validate the present findings.

This study was supported by Brazilian Programme for Post Graduate Students (PEC-PG/process: 5881102) and the Brazilian Coordination of Higher Education (CAPES). There were no conflicts to interest.

REFERENCES

1. Kuhajda FP. Fatty-acid synthase and human cancer: new perspectives on its role in tumor biology. *Nutrition*. 2000;16:202-8.
2. de Andrade BA, León JE, Carlos R, Delgado-Azañero W, Mosqueda-Taylor A, Graner E, de Almeida OP. Expression of fatty acid synthase (FASN) in oral nevi and melanoma. *Oral Dis*. 2011;17:808-12.
3. Milgraum LZ, Witters LA, Pasternack GR, Kuhajda FP. Enzymes of the fatty acid synthesis pathway are highly expressed in in situ breast carcinoma. *Clin Cancer Res*. 1997;3:2115-20.
4. Visca P, Alò PL, Del Nonno F, Botti C, Trombetta G, Marandino F *et al*. Immunohistochemical expression of fatty acid synthase, apoptotic-regulating genes, proliferating factors, and ras protein product in colorectal adenomas, carcinomas, and adjacent nonneoplastic mucosa. *Clin Cancer Res*. 1999;12:4111-8.
5. Pizer ES, Chrest FJ, DiGiuseppe JA, Han WF. Pharmacological inhibitors of mammalian fatty acid synthase suppress DNA replication and induce apoptosis in tumor cell lines. *Cancer Res*. 1998;58:4611-5.

6. Alo PL, Visca P, Framarino ML, Botti C, Monaco S, Sebastiani V *et al.* Immunohistochemical study of fatty acid synthase in ovarian neoplasms. *Oncol Rep.* 2000;7:1383-8.
7. Piyathilake CJ, Frost AR, Manne U, Bell WC, Weiss H, Heimbürger DC *et al.* The expression of fatty acid synthase (FAS) is an early event in the development and progression of squamous cell carcinoma of the lung. *Hum Pathol.* 2000;31:1068-73.
8. Kusakabe T, Nashimoto A, Honma K, Suzuki T. Fatty acid synthase is highly expressed in carcinoma, adenoma and in regenerative epithelium and intestinal metaplasia of the stomach. *Histopathology.* 2002;40:71-9.
9. Visca P, Sebastiani V, Pizer ES, Botti C, De Carli P, Filippi S *et al.* Immunohistochemical expression and prognostic significance of FAS and GLUT1 in bladder carcinoma. *Anticancer Res.* 2003;23:335-9.
10. Agostini M, Silva SD, Zecchin KG, Coletta RD, Jorge J, Loda M *et al.* Fatty acid synthase is required for the proliferation of human oral squamous carcinoma cells. *Oral Oncol.* 2004;40:728-35.
11. Silva SD, Agostini M, Nishimoto IN, Coletta RD, Alves FA, Lopes MA *et al.* Expression of fatty acid synthase, ErbB2 and Ki-67 in head and neck squamous cell carcinoma. A clinicopathological study. *Oral Oncol.* 2004;40:688-96.
12. Dhanasekaran SM, Barrette TR, Ghosh D, Shah R, Varambally S, Kurachi K, *et al.* Delineation of prognostic biomarkers in prostate cancer. *Nature.* 2001;412:822-6.
13. Ito FA, Ito K, Coletta RD, Graner E, Almeida OP, Lopes AM. Salivary gland tumors: immunohistochemical study of EGF, EGFR, ErbB-2, FAS and Ki-67. *Anal Quant Cytol Histol.* 2009;31:280-7.

14. do Prado RF, da Silva Machado AL, Colombo CE, Carvalho YR. Immunohistochemical study of the expression of fatty acid synthase and Ki-67 in salivary gland tumors. *J Oral Pathol Med.* 2011;40:467-75.
15. Gneep DR, Wenig B. in: *Malignant Mixed Tumors. Surgical Pathology of Salivary gland tumors.* W.B Saunders Company. 1991. p. 350-368.
16. Altemani A, Martins MT, Freitas L, Soares F, Araújo NS, Araújo VC. Carcinoma ex pleomorphic adenoma (CXPA): immunoprofile of the cells involved in carcinomatous progression. *Histopathology.* 2005;46:635-41.
17. Freitas LL, Araújo VC, Martins MT, Chone C, Crespo A, Altemani A. Biomarker analysis in carcinoma ex pleomorphic adenoma at an early phase of carcinomatous transformation. *Int J Surg Pathol.* 2005;13:337-42.
18. DeRoche TC, Hoschar AP, Hunt JL. Immunohistochemical evaluation of androgen receptor, HER-2/neu, and p53 in benign pleomorphic adenomas. *Arch Pathol Lab Med.* 2008;132:1907–1911.
19. Aperio technologies. Algorithm user guide: nuclear quantification. Vista, CA: Aperio Techonologies 2011;1-7.
20. Eveson JW. Salivary tumours. *Periodontol.* 2000;57:150-9.
21. de Oliveira FA, Duarte EC, Taveira CT, Máximo AA, de Aquino EC, Alencar Rde C, Vencio EF. Salivary gland tumor: a review of 599 cases in a Brazilian population. *Head Neck Pathol.* 2009;3:271-5.
22. Tian Z, Li L, Wang L, Hu Y, Li J. Salivary gland neoplasms in oral and maxillofacial regions: a 23-year retrospective study of 6982 cases in an eastern Chinese population. *Int J Oral Maxillofac Surg.* 2010;39:235-42.

23. Fonseca FP, Carvalho M de V, de Almeida OP, Rangel AL, Takisawa MC, Bueno AG, *et al.* Clinicopathologic analysis of 493 cases of salivary gland tumors in a Southern Brazilian population. *Oral Sur Oral Med Oral Pathol Oral Radiol.* 2012;114:230-9.
24. Vargas PA, Gerhard R, Vergilius JF, Araújo Filho VJF, Vieira de Castro I. Salivary gland tumors in a Brazilian population: a retrospective study of 124 cases. *Rev Hosp Clín Fac Med Sao Paulo.* 2002;57:271-6.
25. Ansari MH. Salivary gland tumors in an Iranian population: a retrospective study of 130 cases. *J Oral Maxillofac Surg.* 2007;65:2187-94.
26. Lewis JE, Olsen KD, Sebo TJ. Carcinoma ex pleomorphic adenoma: pathologic analysis of 73 cases. *Hum Pathol.* 2001;32:596-604.
27. Matsubayashi S, Yoshihara T. Carcinoma ex pleomorphic adenoma of the salivary gland: an immunohistochemical study. *Eur Arch Otorhinolaryngol.* 2007;264:789-95.

TABLE

Table 1. FASN expression in patients with pleomorphic adenoma and carcinoma ex pleomorphic adenoma.

	Pleomorphic adenoma (n=12)				Carcinoma ex pleomorphic adenoma (n=6)				P-value
FASN**	0	1+	2+	3+	0	1+	2+	3+	
Patients (%)	7 (58.3)	1 (8.3)	4 (33.4)	0 (0.0)	0 (0.0)	0 (0.0)	0 (0.0)	6 (100.0)	<0.001*

**FASN intensity.

FIGURES AND LEGENDS.

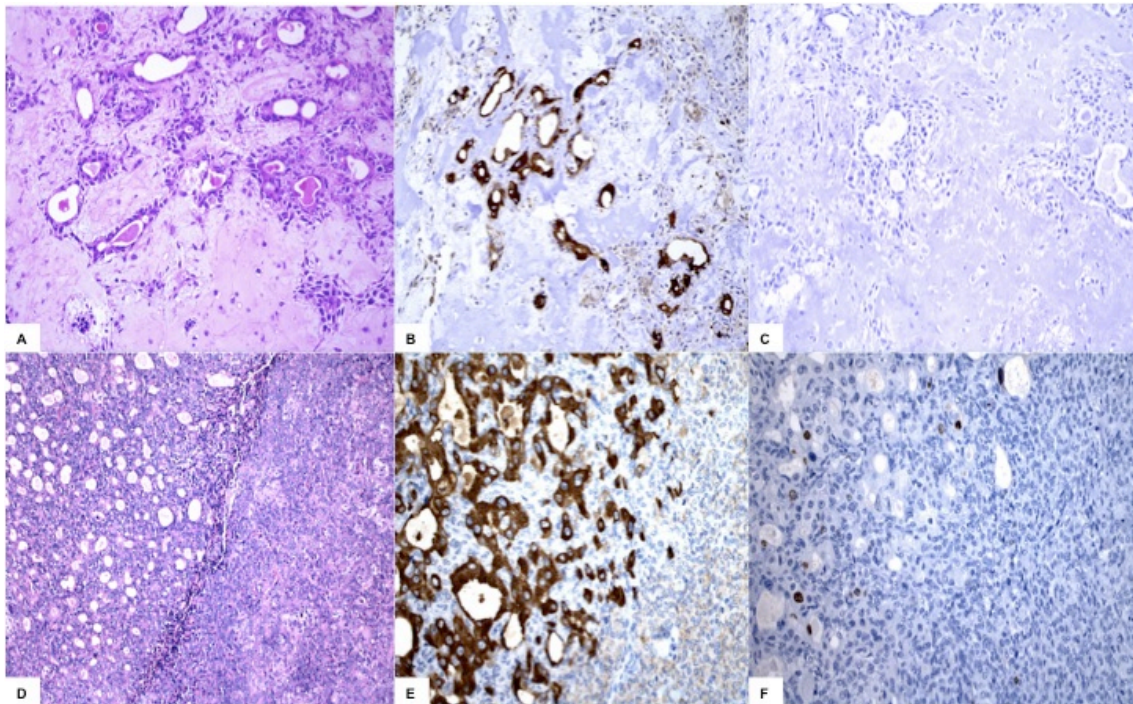


Figure 1. **A**, Pleomorphic adenoma showing ductal structures and chondromyxoid stroma (H&E, original magnification x200); **B**, Focal FASN immunoreactivity in ductal cells of pleomorphic adenoma (original magnification x200); **C**, Observe the absence of Ki67 immunoreactivity in pleomorphic adenoma (original magnification x200); **D**, Malignant component in non-invasive CXPA, adjacent to the benign component of myoepithelial proliferation (H&E original magnification x200); **E**, Atypical ductal proliferation of non-invasive CXPA in the transitional malignant component, showing intense immunoreactivity for FASN (original magnification x200); **F**, Nuclear staining of Ki67 in non-invasive CXPA (H&E original magnification x200).

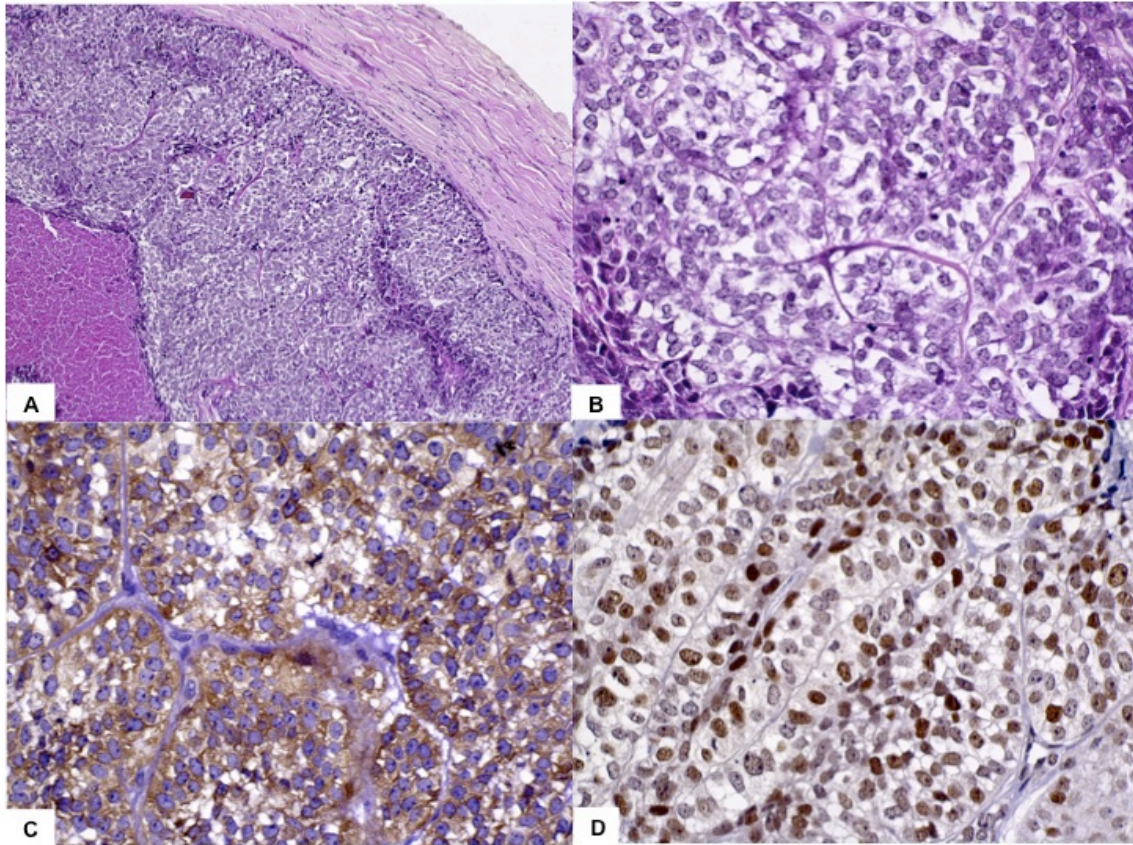


Figure 2. **A**, Malignant cells in invasive CXPA demonstrating myoepithelial carcinoma component and necrosis (H&E original magnification x200); **B**, Clear malignant cells in the malignant component of CXPA (H&E original magnification x400); **C**. Evident FASN immunoexpression on CXPA (original magnification x200). **D**. Ki67 expression on myoepithelial carcinoma of CXPA (original magnification x400).

CONCLUSÃO

- As expressões imunoistoquímicas dos marcadores angiogênicos CD31, CD34, e CD105 não foram úteis na diferenciação entre tumores malignos de glândulas salivares de baixo/intermediário e alto grau de malignidade.
- Tumores malignos de glândulas salivares de alto grau de malignidade apresentaram maiores índices de proliferação celular para o anticorpo Ki-67 quando comparados com tumores de baixo grau de malignidade.
- A intensa imunomarcção de tumores de glândulas salivares de alto grau de malignidade para o anticorpo FASN pode estar relacionada a uma maior agressividade tumoral.
- Adenoma Pleomorfo apresentou menor índice de proliferação celular quando comparado com Carcinoma Ex-Adenoma Pleomorfo.
- FASN associado a Ki67 contribuiu na identificação do componente maligno do Carcinoma Ex-Adenoma Pleomorfo.

REFERÊNCIAS*

1. Agostini M, Silva SD, Zecchin KG, Coletta RD, Jorge J, Loda M *et al.* Fatty acid synthase is required for the proliferation of human oral squamous carcinoma cells. *Oral Oncol.* 2004;40:728-35.
2. Alo' PL, Visca P, Framarino ML, Botti C, Monaco S, Sebastiani V *et al.* Immunohistochemical study of fatty acid synthase in ovarian neoplasms. *Oncol Rep.* 2000;7: 1383-8.
3. Altemani A, Martins MT, Freitas L, Soares F, Araújo NS, Araújo VC. Carcinoma ex pleomorphic adenoma (CXPA): immunoprofile of the cells involved in carcinomatous progression. *Histopathology.* 2005;46:635-41.
4. Baron A, Migita T, Tang D, Loda M. Fatty acid synthase: a metabolic oncogene in cancer? *J Cell Biochem.* 2004;91;47-53.
5. Cheuk W, Chan JK. Advances in salivary gland pathology. *Histopathology.* 2007;51:1-20.
6. Chirala SS, Chang H, Matzuk M, Abu-Elheiga L, Mao J, Mahon K, *et al.* Fatty acid synthesis is essential in embryonic development: fatty acid synthase null mutants and most of the heterozygotes die in utero. *Proc Natl Acad Sci U S A.* 2003;100:6358-63.

*De acordo com as normas da UNICAMP/FOP, baseadas na norma do Internacional Committee of Medical Journals Editors - Grupo de Vancouver. Abreviatura dos periódicos em conformidade com Medline.

7. de Andrade BA, León JE, Carlos R, Delgado-Azañero W, Mosqueda-Taylor A, Graner E, de Almeida OP. Expression of fatty acid synthase (FASN) in oral nevi and melanoma. *Oral Dis.* 2011;17:808-12.
8. do Prado RF, da Silva Machado AL, Colombo CE, Carvalho YR. Immunohistochemical study of the expression of fatty acid synthase and Ki-67 in salivary gland tumors. *J Oral Pathol Med.* 2011;40:467-75.
9. Dubinski W, Gabriel M, Iakovlev VV, Scorilas A, Youssef YM, Faragalla H, Kovacs K, Rotondo F, Metias S, Arsanious A, Plotkin A, Girgis AH, Streutker CJ, Yousef GM. Assessment of the prognostic significance of endoglin (CD105) in clear cell renal cell carcinoma using automated image analysis. *Hum Pathol.* 2012;43:1037-43.
10. Ding S, Li C, Lin S, Yang Y, Liu D, Han Y, Zhang Y, Li L, Zhou L, Kumar S. Comparative evaluation of microvessel density determined by CD34 or CD105 in benign and malignant gastric lesions. *Hum Pathol.* 2006;37:861-6
11. Duff SE, Li C, Garland JM, Kumar S. CD105 is important for angiogenesis: evidence and potential applications. *FASEB J.* 2003;17:984-92.
12. Eveson JW, Auclair P, Gnepp DR, El-Naggar AK. Tumours of the salivary glands: introduction. In: Barnes L, Eveson JW, Reichart P, Sidransky D, editores. *World health organization classification of tumours. Pathology & genetic - head and neck tumors.* Lyon: IARC Press; 2005. p.212.
13. El Gehani K, Al-Kikhia L, Mansuri N, Syrjänen K, Al-Fituri O, Elzagheid A. Angiogenesis in urinary bladder carcinoma as defined by microvessel density (MVD)

- after immunohistochemical staining for Factor VIII and CD31. *Libyan J Med.* 2011;31:6.
14. Ferrara N, Gerber HP, LeCouter J. The biology of VEGF and its receptors. *Nat Med.* 2003;9:669-76.
15. Fina L, Molgaard HV, Robertson D, Bradley NJ, Monaghan P, Delia D, Sutherland DR, Baker MA, Greaves MF. Expression of the CD34 gene in vascular endothelial cells. *Blood.* 1990;75:2417-26.
16. Folkman J. Angiogenesis and apoptosis. *Semin Cancer Biol.* 2003;13:159-67.
17. Gerdes J, Li L, Schlueter C, Duchrow M, Wohlenberg C, Gerlach C, Stahmer I, Kloth S, Brandt E, Flad HD. Immunobiochemical and molecular biologic characterization of the cell proliferation-associated nuclear antigen that is defined by monoclonal antibody Ki-67. *Am J Pathol.* 1991;138:867-73.
18. Graner E, Tang D, Rossi S, Baron A, Migita T, Weinstein LJ *et al.* The isopeptidase USP2a regulates the stability of fatty acid synthase in prostate cancer. *Cancer Cell.* 2004;5:253-61.
19. Ito F, Vargas PA, de Almeida OP, Lopes MA. Salivary gland tumors in a Brazilian population, a retrospective study of 496 cases. *Int J Oral Maxillofac Surg.* 2005;34:533-6.
20. Ito FA, Ito K, Coletta RD, Graner E, de Almeida OP, Lopes MA. Salivary gland tumors: immunohistochemical study of EGF, EGFR, ErbB-2, FAS and Ki-67. *Anal Quant Cytol Histol.* 2009;31:280-7.
21. Innocenzi D, Alo PL, Balzani A, Sebastiane V, Silipo V, La Torre G *et al.* Fatty acid synthase expression in melanoma. *J Cutan Pathol.* 2003;30:23-8. 30.
22. Krause DS, Fackler MJ, Civin CI, May WS. CD34: structure, biology, and

clinical utility. *Blood*. 1996;1:87:1-13.

23. Kyzas PA, Agnantis NJ, Stefanou D. Endoglin (CD105) as a prognostic factor in head and neck squamous cell carcinoma. *Virchows Arch*. 2006; 448:768-75.

24. Kuhajda FP, Pizer ES, Li JN, Mani NS, Frehywot GL, Townsend CA. Synthesis and antitumor activity of an inhibitor of fatty acid synthase. *Proc Natl Acad Sci U S A*. 2000;97:3450-4.

25. Kusakabe T, Nashimoto A, Honma K, Suzuki T. Fatty acid synthase is highly expressed in carcinoma, adenoma and in regenerative epithelium and intestinal metaplasia of the stomach. *Histopathology*. 2002;40:71-9.

26. Luna MA. Salivary Mucoepidermoid Carcinoma. *Adv Anat Pathol*. 2006;13:293-307.

27. Martone T, Rosso P, Albera R, Migliaretti G, Fraire F, Pignataro L, Pruneri G, Bellone G, Cortesina G. Prognostic relevance of CD105+ microvessel density in HNSCC patient outcome. *Oral Oncol*. 2005; 41:147-55.

28. Menendez JA, Vellon L, Lupu R. Orlistat: from antiobesity drug to anticancer agent in Her-2/neu (erbB-2)-overexpressing gastrointestinal tumors? *Exp Biol Med (Maywood)*. 2005;230:151-4.

29. Perschbacher K, Jackson-Boeters L, Daley T. The adhesion molecules NCAM, HCAM, PECAM-1 and ICAM-1 in normal salivary gland tissues and salivary gland malignancies. *J Oral Pathol Med*. 2004;33:230-6.

30. Rossi S, Graner E, Febbo P, Weinstein L, Bhattacharya N, Onody T *et al*. Fatty acid synthase expression defines distinct molecular signatures in prostate cancer. *Mol Cancer Res*. 2003;1:707-15.

31. Vacchi-Suzzi M, Bocciolini C, Bertarelli C, Dall'Olio D. Ki-67 proliferation rate as a prognostic marker in major salivary gland carcinomas. *Ann Otol Rhinol Laryngol.* 2010;119:677-83.
32. Vargas PA, Cheng Y, Barrett AW, Craig GT, Speight PM. Expression of Mcm-2, Ki-67 and geminin in benign and malignant salivary gland tumours. *J Oral Pathol Med.* 2008;37:309-18.
33. Visca P, Alò PL, Del Nonno F, Botti C, Trombetta G, Marandino F *et al.* Immunohistochemical expression of fatty acid synthase, apoptotic-regulating genes, proliferating factors, and ras protein product in colorectal adenomas, carcinomas, and adjacent nonneoplastic mucosa. *Clin Cancer Res.* 1999;5:4111-8.
34. Visca P, Sebastiani V, Pizer ES, Botti C, De Carli P, Filippi S *et al.* Immunohistochemical expression and prognostic significance of FAS and GLUT1 in bladder carcinoma. *Anticancer Res.* 2003;23:335-9.
35. Weiss L, Hoffmann GE, Schreiber R, Andres H, Fuchs E, Korber E *et al.* Fatty-acid biosynthesis in man, a pathway of minor importance. Purification, optimal assay conditions, and organ distribution of fatty-acid synthase. *Biol Chem Hoppe Seyler.* 1986;367:905-12.



Hospital das Clínicas da FMUSP
Comissão de Ética para Análise de Projetos de Pesquisa - CAPPesq

PROJETO DE PESQUISA

Título: ESTUDO HISTOPATOLÓGICO E IMUNOISTOQUÍMICO DE TUMORES MALIGNOS DE GLÂNDULAS SALIVARES

Pesquisador Responsável: SHEILA APARECIDA COELHO SIQUEIRA **Versão:** 1

Pesquisador Executante: KATYA PULIDO DÍAZ **CAAE:** 05899212.6.0000.0068

Co-autores: LEANDRO AURÉLIO LIPORONI MARTINS, PABLO AGUSTIN VARGAS.

Finalidade Acadêmica: Doutorado

Instituição: HCFMUSP

Departamento: PATOLOGIA

PARECER CONSUBSTANCIADO DO CEP

Registro on-line: 9734

Número do Parecer: 164.151

Data da Relatoria: 05/12/2012

Apresentação do Projeto: O estudo busca analisar diversos marcadores imunoistoquímicos em pacientes com neoplasia maligna de glândulas salivares

Objetivo da Pesquisa: Estabelecer a relação entre diversos marcadores imunoistoquímicos e outros indicadores de agressividade em neoplasia maligna de glândulas salivares

Avaliação dos Riscos e Benefícios: Não há riscos aos pacientes e os pesquisadores e técnicos envolvidos seguem as normas de segurança habituais na manipulação de material biológico

Comentários e Considerações sobre a Pesquisa: A pesquisa poderá agregar conhecimento quanto a indicadores prognósticos em neoplasia maligna de glândulas salivares

Considerações sobre os Termos de apresentação obrigatória: Adequados

Recomendações: Não há recomendações.


Conclusões ou Pendências e Lista de Inadequações: Aprovado

Situação do Parecer: Aprovado

Necessita Apreciação da CONEP: Não

Considerações Finais a critério do CEP: Aprovado

São Paulo, 12 de Dezembro de 2012


PROF. DR. ALFREDO JOSÉ MANSUR
Vice-Coordenador
Comissão de Ética para Análise de
Projetos de Pesquisa - CAPPesq

Rua Dr. Ovídio Pires de Campos, 225 - Prédio da Administração - 5º andar
CEP 05403-010 - São Paulo - SP.
55 11 2661-7585 - 55 11 2661-6442 ramais: 16, 17, 18 | marcia.carvalho@hc.fm.usp.br