



**ROGÉRIO DE OLIVEIRA GONDAK**

**“ANALYSIS OF DENDRITIC CELLS IN TONGUE, CERVICAL  
LYMPH NODES AND PALATINE TONSILS OF AUTOPSIED  
PATIENTS WITH ACQUIRED IMMUNODEFICIENCY SYNDROME”**

***“ANÁLISE DAS CÉLULAS DENDRÍTICAS NA LÍNGUA, LINFONODOS  
CERVICAIS E TONSILAS PALATINAS DE PACIENTES AUTOPSIADOS COM  
SÍNDROME DA IMUNODEFICIÊNCIA ADQUIRIDA”***

**PIRACICABA**

**2013**





**UNIVERSIDADE ESTADUAL DE CAMPINAS  
FACULDADE DE ODONTOLOGIA DE PIRACICABA**

**ROGÉRIO DE OLIVEIRA GONDAK**

**“ANALYSIS OF DENDRITIC CELLS IN TONGUE, CERVICAL  
LYMPH NODES AND PALATINE TONSILS OF AUTOPSIED  
PATIENTS WITH ACQUIRED IMMUNODEFICIENCY SYNDROME”**

**Orientador: Prof. Dr. Pablo Agustin Vargas**

**Co-orientador: Prof. Dr. Luiz Paulo Kowalski**

**“ANÁLISE DAS CÉLULAS DENDRÍTICAS NA LÍNGUA, LINFONODOS  
CERVICAIS E TONSILAS PALATINAS DE PACIENTES AUTOPSIADOS COM  
SÍNDROME DA IMUNODEFICIÊNCIA ADQUIRIDA”**

Tese de Doutorado apresentada ao Programa de Pós-Graduação em Estomatopatologia da Faculdade de Odontologia da Universidade Estadual de Campinas para obtenção do título de Doutor em Estomatopatologia na Área de Patologia.

Doctorate thesis presented to the Postgraduation Programme in Stomatopathology of the Dental School of the University of Campinas to obtain the Ph.D. grade in Stomatopathology in Pathology Area.

ESTE EXEMPLAR CORRESPONDE À VERSÃO FINAL DA TESE  
DEFENDIDA PELO ALUNO ROGÉRIO DE OLIVEIRA GONDAK  
E ORIENTADO PELO PROF. DR. PABLO AGUSTIN VARGAS

Assinatura do Orientador

---

**PIRACICABA**

**2013**

FICHA CATALOGRÁFICA ELABORADA POR  
JOSIDELMA F COSTA DE SOUZA – CRB8/5894 - BIBLIOTECA DA  
FACULDADE DE ODONTOLOGIA DE PIRACICABA DA UNICAMP

G586a Gondak, Rogério de Oliveira, 1978-  
Análise das células dendríticas na língua, linfonodos cervicais e tonsilas palatinas de pacientes autopsiados com Síndrome da Imunodeficiência Adquirida / Rogério de Oliveira Gondak. -- Piracicaba, SP : [s.n.], 2013.

Orientador: Pablo Agustin Vargas.  
Coorientador: Luiz Paulo Kowalski.  
Tese (Doutorado) - Universidade Estadual de Campinas, Faculdade de Odontologia de Piracicaba.

1. HIV-1. 2. Autópsia. 3. Imunoistoquímica. I. Vargas, Pablo Agustin, 1973- II. Kowalski, Luiz Paulo. III. Universidade Estadual de Campinas. Faculdade de Odontologia de Piracicaba. IV. Título.

Informações para a Biblioteca Digital

**Título em Inglês:** Analysis of dendritic cells in tongue, cervical lymph nodes and palatine tonsils of autopsied patients with acquired immunodeficiency syndrome

**Palavras-chave em Inglês:**

HIV-1

Autopsy

Immunohistochemistry

**Área de concentração:** Patologia

**Titulação:** Doutor em Estomatopatologia

**Banca examinadora:**

Pablo Agustin Vargas [Orientador]

Fábio Daumas Nunes

Halbert Villalba

Marcio Ajudarte Lopes

Edgard Graner

**Data da defesa:** 23-04-2013

**Programa de Pós-Graduação:** Estomatopatologia



UNIVERSIDADE ESTADUAL DE CAMPINAS  
Faculdade de Odontologia de Piracicaba



A Comissão Julgadora dos trabalhos de Defesa de Tese de Doutorado, em sessão pública realizada em 23 de Abril de 2013, considerou o candidato ROGÉRIO DE OLIVEIRA GONDAK aprovado.

Prof. Dr. PABLO AGUSTIN VARGAS

Prof. Dr. FÁBIO DAUMAS NUNES

Prof. Dr. HALBERT VILLALBA

Prof. Dr. MARCIO AJUDARTE LOPES

Prof. Dr. EDGARD GRANER

## DEDICATÓRIA

Dedico este estudo principalmente à minha querida esposa **CINTIA** pela dedicação, integridade e constante incentivo.

## AGRADECIMENTOS

À Faculdade de Odontologia de Piracicaba da Universidade Estadual de Campinas (FOP/UNICAMP), na pessoa do seu diretor Prof. Dr. **Jacks Jorge Junior**.

Ao coordenador do curso de pós-graduação de Estomatopatologia da FOP-UNICAMP, Prof. Dr. **Alan Roger dos Santos Silva**, pela sabedoria, polidez de atitude e plenos aconselhamentos.

Ao meu orientador Prof. Dr. **Pablo Agustin Vargas**, pela orientação e confiança depositada no meu trabalho. Muito lhe agradeço especialmente pela oportunidade de desenvolver este trabalho no Departamento de Patologia da Faculdade de Medicina da Universidade de São Paulo (FMUSP) e no Departamento de Cirurgia de Cabeça e Pescoço do Hospital AC Camargo (São Paulo – SP).

Ao meu co-orientador Prof. Dr. **Luiz Paulo Kowalski**, pelo aprimoramento intelectual e, sobretudo, pela sabedoria sustentada pelo equilíbrio.

À Prof<sup>a</sup>. Dr<sup>a</sup>. **Thais Mauad**, pela postura crítica pautada no amplo conhecimento científico e por ter me acolhido com tanto carinho e motivação.

Ao Prof. Dr. **Márcio Ajudarte Lopes**, pela prática clínica consciente, seriedade e dedicação. Diante de sua postura profissional, pude vivenciar o grande exemplo de docente e pesquisador, revestido pelos mais nobres sentimentos humanos.

Ao Prof. Dr. **Oslei Paes de Almeida**, pela capacitação técnica e doação ao serviço.

Aos Profs. Dr. **Ricardo Della Coletta** e Dr. **Edgard Graner**, pelos exemplos de competência e seriedade.

Ao Prof. Dr. **Rogério Jorge**, coordenador do Curso de Estomatologia da Associação dos Cirurgiões-dentistas de Campinas, pela amizade e preciosos ensinamentos clínicos prestados.

Aos grandes amigos **Fernanda Viviane Mariano** e **Marcelo Brum Correa**, pelo carinho, amizade e momentos compartilhados.

À técnica do Laboratório de Imunoistoquímica do Departamento de Patologia do Hospital AC Camargo **Suely Nonogaki** pelo fundamental apoio técnico.

Aos colegas da pós-graduação do Programa de Estomatopatologia da Faculdade de Odontologia de Piracicaba: **Alicia Rumayor Piña, Ana Camila Pereira Messetti, Ana Lucia Noronha Francisco, Andreia Bufalino, Bruno Augusto Benevenuto de Andrade, Daniel Berretta Moreira Alves, Elizabete Bagordakis Pinto, Felipe Paiva Fonseca, Isadora Luana Flores, Katya Pulido Díaz, Lara Maria Alencar Ramos Innocentini, Marcondes Sena Filho, Marisol Martinez Martinez, Patricia do Socorro Queiroz Feio, Rose Mara Ortega, Sibeles Nascimento de Aquino, Victor Hugo Toralrizo e Wilfredo Alejandro Gonzalez Arriagada.**

À **FAPESP**, Fundação de Amparo à Pesquisa do Estado de São Paulo, pelo auxílio concedido na forma de bolsa de doutorado.

A **todos**, rendo meus sentimentos mais elevados.



## EPÍGRAFE

*“A ciência é a tentativa de compreender a realidade. É uma atividade quase religiosa, na mais ampla acepção da palavra”.*

**George Wald**

## RESUMO

Na infecção pelo HIV, as células dendríticas (CDs) podem desempenhar vários papéis, incluindo a provável captação inicial do HIV, transporte para os linfonodos, e posterior transferência para células T, desempenhando um importante papel no sistema imune. As manifestações orais observadas em pacientes infectados pelo HIV, incluindo aquelas associadas ao HSV-1 podem estar diretamente relacionadas à injúria das CDs. A proposta deste estudo foi identificar e quantificar as CDs intersticiais na língua de pacientes autopsiados com AIDS e portadores de infecção herpética lingual (n=10), pacientes com AIDS e sem lesões linguais (n=10) e pacientes sem AIDS e sem lesões linguais (n=10) por meio de reações imunoistoquímicas. Além disso, investigamos a população de CDs nos linfonodos e tonsilas palatinas de pacientes com AIDS (n=32) e sem AIDS (n=21). Nos tecidos linguais, foram utilizados os anticorpos contra CD1a e CD83 para identificação das CDs e o anticorpo contra HSV-1 para detecção do vírus da herpes simples tipo 1. Nos linfonodos e tonsilas palatinas foram utilizados além dos anticorpos contra CD1a e CD83, o anticorpo contra fator XIIIa. Para a quantificação das CDs nos tecidos linguais foi utilizado análise histomorfométrica convencional e nos tecidos linfóides foi aplicado o método analítico *Positive Pixel Count* (software *Image Scope*). Os resultados mostraram uma intensa depleção na população de CDs em tecidos linguais e linfóides de pacientes com AIDS e a infecção lingual pelo HSV-1 não potencializou a redução de CDs.

**Palavras-chave:** AIDS; células dendríticas; língua; linfonodos; tonsilas; vírus herpes simplex.

## **ABSTRACT**

During HIV infection, dendritic cells (DCs) may play several roles, including the probable initial uptake of HIV, transport to the lymph nodes, and subsequent transfer to T cells. Oral opportunistic infections observed in HIV-infected patients, including those associated with HSV-1 may be directly related to injury of DCs. The purpose of this study was to identify and quantify the interstitial DCs in the tongue of autopsied patients with AIDS and lingual herpes (n = 10), AIDS patients with normal tongues (n = 10) and non-AIDS patients with normal tongues (n = 10) by immunohistochemistry. Furthermore, we investigated the DCs population in lymph nodes and palatine tonsils of AIDS patients (n = 32) and non-AIDS patients (n = 21). CD1a and CD83 antibodies were carried out to identify DCs in lingual tissues and HSV-1 antibody for detection of herpes simplex virus type 1. In lymphoid tissues, CD1a, CD83 and factor XIIIa antibodies were carried out to identify DCs. Interstitial DCs were measured by conventional histomorphometry whereas the lymphoid DCs were measured by Positive Pixel Count Algorithm method using ImageScope software. The results showed a decreased population of DCs in lingual and lymphoid tissues of AIDS patients independently of the presence of concomitant infection by HSV-1.

**Key words:** AIDS; dendritic cells; tongue; lymph nodes; tonsils; herpes simplex virus.

## SUMÁRIO

<b>INTRODUÇÃO</b>	01
<b>CAPÍTULO 1:</b> <i>Reduced number of CD1a+ and CD83+ interstitial dendritic cells in herpetic lesions (HSV-1+) of the tongue in patients with advanced-stage AIDS</i>	05
<b>CAPÍTULO 2:</b> <i>Decreased CD1a+, CD83+ and Factor XIIIa+ dendritic cells in cervical lymph nodes and palatine tonsils of AIDS patients</i>	18
<b>CONCLUSÃO</b>	35
<b>REFERÊNCIAS</b>	36
<b>ANEXO</b>	40
<b>Anexo 1</b>	40
<b>Anexo 2</b>	41
<b>Anexo 3</b>	42

## INTRODUÇÃO

As células dendríticas (CDs) constituem uma família de células apresentadoras de antígenos (APCs) oriundas de progenitores hematopoiéticos da medula óssea e com extraordinária capacidade para interagir com os linfócitos T e B modulando as suas respostas (Steinman, 2012).

As CDs apresentam núcleo ovóide ou denteado com cromatina frouxa e um citoplasma abundante, exibindo mitocôndrias proeminentes, múltiplas organelas citoplasmáticas, como vesículas e túbulos e, usualmente, poucos lisossomos, embora estes últimos sejam encontrados em maior número nas CDs presentes no tecido conjuntivo de órgãos não linfóides (Hart, 1997; Banchereau & Steinman, 1998).

A heterogeneidade das CDs resulta da existência de linhagens celulares distintas e diferenças nos estágios de maturação (Shortman & Naik, 2007). Mclellan & Kämpgen (2000) afirmaram que as células dendríticas derivam de precursores mielóides e linfóides. Em humanos, o desenvolvimento de CDs via linfóide é controverso. As CDs mielóides e linfóides diferem em fenótipo, localização e função (Steinman *et al.*, 1997). Os subtipos de CDs que estão presentes em humanos e camundongos incluem as células dendríticas plasmocitóides (CDp), produtoras de interferon tipo-1, e as células dendríticas convencionais ou clássicas (CDc), especializadas em processamento e apresentação antigênica. Enquanto as CDp completam o desenvolvimento na medula óssea, a maioria das CDc completam o desenvolvimento em tecidos periféricos e linfóides (Liu & Nussenzweig, 2010). Citocinas adicionais e reguladores transcricionais são necessários durante as fases tardias de diferenciação das CDs (Satpathy *et al.*, 2011; Belz & Nutt, 2012). Durante processos infecciosos ou inflamatórios, subtipos adicionais de CDs podem ser gerados por monócitos e apresentar distintas funções (Cheong *et al.*, 2010).

Na presença de fatores de crescimento, tais como GM-CSF (fator estimulador de colônia para granulócitos e monócitos) e interleucina 4 (IL-4), as

células precursoras mielóides (CD11c+) desenvolvem funcionalmente e fenotipicamente características de CDs imaturas. As CDs encontradas em tecidos não-linfóides podem ser divididas em duas populações: células de Langerhans, que residem dentro do epitélio e as CDs intersticiais, presentes na derme e no interstício de órgãos parenquimatosos (Holíková *et al.*, 2002).

Na ausência de sinais inflamatórios ou infecções, as CD possuem um fenótipo caracterizado pela baixa expressão de moléculas do complexo de histocompatibilidade principal de classe II (MHC II) e das moléculas co-estimulatórias como CD80, CD86 e CD40. Após recebimento dos sinais antigênicos fornecidos por lipopolissacarídeo bacteriano (LPS), DNA bacteriano, RNA dupla fita ou citocinas inflamatórias (IL-1, TNF- $\alpha$ ), um irreversível processo de maturação é iniciado, incluindo perda da atividade endocítica, migração via vasos linfáticos para linfonodos e uma melhora na capacidade de estimulação das células T (Steinman *et al.*, 1997, Guernonprez *et al.*, 2002).

Durante o processo de maturação, a expressão do receptor de quimiocina CCR6 diminui e a expressão do receptor CCR7 aumenta. A quimiocina MIP-3 $\beta$ , ligando-se ao CCR7, guia a migração das CDs maduras para os linfonodos e sua fixação nas áreas de células T (Dieu *et al.*, 1998). Dessa forma, o processo de maturação das células dendríticas integra-se ao processo de migração das mesmas em direção às áreas T dos linfonodos, fazendo com que a probabilidade do encontro com um linfócito T antígeno-específico aumente. Nos tecidos linfóides, as CDs podem estar concentradas na zona de células T, sendo denominadas de CDs interdigitantes ou localizadas na zona de células B, denominadas de CDs foliculares (Noble *et al.*, 1996). Linfócitos B e T são os principais mediadores da atividade imunológica, sendo esta, em grande parte, dependente da interação com CDs (Banchereau & Steinman, 1998; Lanzavecchia, 2001).

Os receptores de reconhecimento de padrões (RRP) expressos pelas CDs incluem os receptores do tipo *Toll* (TLR), *C-type lectins* e o CD1a, os quais reconhecem características moleculares específicas expressas em patógenos

(Chen *et al.*, 2006). Além disso, esses receptores também estão envolvidos no reconhecimento de antígenos relacionados à doenças autoimunes (TLR7). Assim, essas células não só são cruciais na indução da imunidade, mas também têm um papel fundamental na indução de tolerância imunológica central e periférica (Colonna, 2006).

Além de interagir com as células T, as CDs também interagem diretamente com células B (Dubois *et al.*, 1997). As CDs estimulam a diferenciação de células B *naïve*, mediada por IL-12 e regulam a imunidade inata, interagindo com células NK e mediando indiretamente a liberação de interferon alfa (IFN- $\alpha$ ) (Banchereau *et al.*, 2001). Uma vez que o processo de apresentação antigênica é alcançado, as CDs sofrem apoptose via Fas/FasL nos tecidos linfóides secundários.

A infecção do organismo pelo vírus da imunodeficiência humana (HIV) é caracterizada pela seletiva depleção de linfócitos T CD4+, sugerindo um tropismo específico e efeito citopático desse vírus para subclasse de células T. Além dos linfócitos T, outras células como as pertencentes à família das CDs têm sido relatadas na literatura como possíveis alvos da infecção pelo HIV (Chou *et al.*, 2000). As CDs estão envolvidas na disseminação do HIV, pois a maioria das CDs expressam os principais receptores utilizados pelo HIV como CD4, CCR5 e CXCR4 (Smed-Sorensen *et al.*, 2005; Hladik *et al.*, 2007). O vírus pode ser transportado e replicar nas CDs imaturas, enquanto as CDs maduras eficientemente transmitem a infecção para as células T CD4+ (Frankel *et al.*, 1996). A doença provocada pelo HIV promove uma redução do número de CDs e diminui a capacidade das CDs estimularem as células T. Este declínio na capacidade estimulatória é provavelmente o resultado da perda de moléculas imunologicamente importantes para as CDs. Limitadas no combate contra a infecção pelo HIV, as CDs acabam favorecendo a transmissão do HIV para as células T e disseminando a doença para vários outros sítios anatômicos (Hewson *et al.*, 1999; Pope, 2000).

Linfonodos, tonsilas e baço de pacientes infectados pelo HIV-1 apresentam CDs que exibem menor expressão de moléculas co-estimulatórias do que

normalmente encontradas em tecidos linfóides de pacientes não infectados (Lore *et al.*, 2002; Dillon *et al.*, 2008). Linfonodos contaminados pelo HIV apresentam alto índice de apoptose de CDs que pode ser demonstrado pelos elevados níveis na expressão de caspase-3 ativada (Wijewardana *et al.*, 2010).

Além do HIV e devido a localização dos subgrupos de CDs na epiderme e derme/lâmina própria, as CDs são verdadeiros alvos de vários outros patógenos virais como citomegalovírus humano (CMV), o vírus do sarampo e o vírus herpes simples tipo 1 e 2 (HSV-1 e -2) (Halary *et al.*, 2002; Burleigh *et al.*, 2006; de Witte *et al.*, 2007).

Siegel *et al.* (1992) consideraram as infecções por HSV-1 e HSV-2 extremamente comuns em pacientes infectados pelo HIV. Em muitos casos, o HSV envolve a reativação do vírus latente. A frequência da recorrência do HSV-1 e HSV-2 depende principalmente do sítio afetado, ou seja, em regiões orofaciais o HSV-1 reativa mais comumente que o HSV-2, enquanto em regiões sacrais o HSV-2 é mais reativo (Lafferty *et al.*, 1987). O HSV-2 reativa de três a cinco vezes mais em pacientes com AIDS do que indivíduos não acometidos pela doença (Augenbraun *et al.*, 1995).

O HSV-1 tem desenvolvido vários mecanismos para evadir a ação imunológica das CDs. Dependendo da carga viral, as CDs são maciçamente infectadas pelo HSV resultando em apoptose (Rad *et al.*, 2003). Além disso, a infecção pelo HSV-1 afeta a função das CDs pela interferência no processo de maturação, incluindo desregulação de moléculas estimulatórias como CD1a, CD83 e MHC I (Raftery *et al.*, 2006; Kummer *et al.*, 2007). O HSV-1 também diminui a produção de interleucina 12 (IL-12), diminuindo a capacidade estimulatória das CDs (Theodoridis *et al.*, 2007).

Dessa forma, o presente estudo tentou promover um melhor entendimento da influência do HIV na população de CDs em linfonodos e tonsilas palatinas e o impacto da infecção combinada HIV-HSV na população de CDs intersticiais em tecidos linguais.



## CAPÍTULO 1

Artigo submetido para possível publicação no periódico *Histopathology*.

### **Reduced number of CD1a+ and CD83+ interstitial dendritic cells in herpetic lesions (HSV-1+) of the tongue in patients with advanced-stage AIDS.**

Rogério O Gondak,<sup>1</sup> Thais Mauad,<sup>2</sup> Oslei P Almeida<sup>1</sup> & Pablo A Vargas<sup>1</sup>

<sup>1</sup>*Department of Oral Diagnosis, Piracicaba Dental School, University of Campinas, Piracicaba, Brazil*

<sup>2</sup>*Department of Pathology, Sao Paulo University Medical School, São Paulo, Brazil.*

*Abbreviations:* Ab, antibody; Ag, antigen; AIDS, acquired immunodeficiency syndrome; DC, dendritic cell; H&E, haematoxylin and eosin; HAART, highly active antiretroviral therapy; HIV, human immunodeficiency virus; HSV, herpes simplex virus; iDC, interstitial dendritic cell; IL, interleukin; LC, Langerhans cell; MHC, major histocompatibility complex; pDC, plasmacytoid dendritic cell; TNF, tumor necrosis factor.

### **ABSTRACT**

*Aims:* The purpose of this study was to quantify and compare the density of interstitial dendritic cells (iDCs) in the tongue mucosa of AIDS patients with and without herpes simplex and normal tongue of non-AIDS patients using autopsy material.

*Methods and results:* CD83, CD1a and HSV-1 antibodies were used to identify mature DCs, immature DCs and herpes simplex type 1, respectively, by immunohistochemistry in tongue tissue from 20 AIDS patients (10 with lingual

herpes and 10 with normal tongue) and 10 from HIV-negative control patients. Quantification was performed by means of conventional morphometry and the results were expressed as positive cells per area of lamina propria. AIDS patients presented a lower density of CD83+cells ( $P < 0.001$ ) and CD1a+cells ( $P < 0.001$ ) compared to the non-AIDS control group. However, no differences in the number of iDCs was found in tongues from AIDS patients with or without herpes infection.

*Conclusions:* Individuals with advanced AIDS present a decreased population of iDCs independent of the presence of concomitant infection by HSV.

**Keywords:** AIDS, dendritic cells, herpes simplex, tongue, CD1a antigen; CD83 antigen.

## INTRODUCTION

Dendritic cells (DCs) are a heterogeneous population of cells with high phagocytic activity as immature cells and high cytokine-producing capacity as mature cells.<sup>1,2</sup> DCs are highly migratory cells that move from tissues to the T cell and B cell zones of lymphoid organs via afferent lymphatics and endothelial venules, and regulate T cell responses in the steady state and during infections.<sup>3,4</sup> The two major DC populations in oral tissues are: Langerhans cells (LCs) located in the mucosal epithelium and interstitial dendritic cells (iDCs), the equivalent of dermal DCs in the skin that are located in the subepithelium.<sup>5-7</sup>

Viruses manipulate the function of DCs to enhance their entry, spread, survival and transmission. Different viruses such as herpes viruses and human immunodeficiency virus (HIV) may have opposite effects on DC function, determined by the need for transfer to a primary target cell, replication within DCs or various immunoevasive mechanisms.<sup>8</sup>

We have previously reported the depletion of LCs in the intraepithelial areas in tongues from AIDS patients with different opportunistic infections.<sup>9</sup> In this work, we describe the effects of HIV and HSV infections on iDCs in the tongue.

## **MATERIALS AND METHODS**

The Ethics Committee of the Medical School of São Paulo University approved this study and the use of autopsy material.

### ***Patient population***

The tongues of 20 autopsied patients with advanced AIDS were collected from 1997 to 2009 in the Department of Pathology, São Paulo University, Medical School. Ten patients had a diagnosis of lingual herpes confirmed histologically and 10 had no microscopic alterations on the tongue. Moreover, normal tongues from 10 patients who died of other diseases not associated with AIDS were used as a control. Records of clinical data and autopsies of a part of this population have been previously described.<sup>9</sup>

### ***Tissue processing***

The tongues were fixed in 10% formalin for 24 hours and 6 transverse sections from each tongue were obtained. All fragments were embedded in paraffin and 3- $\mu$ m thick histological sections were submitted to H&E staining and immunohistochemistry for CD1a, CD83 and HSV-1.

### ***Immunohistochemistry***

Polyclonal HSV-1 antibody (Dako, 1:7000) was used for the detection of HSV infection. Monoclonal antibodies against CD1a (010, Dako, 1:80) and CD83 (1H4b, Novocastra, 1:20) were used for the identification of iDCs in the lamina propria of the tongues. The final antibody was used for staining of mature iDCs.

Antigen retrieval with citrate was performed for all antibodies. The slides were incubated with secondary antibodies conjugated with horseradish peroxidase (LSAB + System-HRP, Mouse / Rabbit, Dako) for 30 minutes at 37°C. Afterward, the slides were incubated with Streptavidin-HRP (Dako) for another 30 minutes and developed with chromogenic substrate (3,3 diaminobenzidine-DAB, Sigma).

The slides were then counterstained with Harris hematoxylin. Negative controls were performed for each reaction omitting the primary antibodies.

### ***Microscopic analysis***

Quantification of iDCs was performed using a light microscope (Carl Zeiss, Berlin, Germany) with a 40x objective and 8x reticulated square (Reichert, Vienna, Austria) having a length of 150  $\mu\text{m}$  and an area of 22,500  $\mu\text{m}^2$ . Cells that were positive for CD1a and CD83 in the lamina propria of all tongues were counted including the lesional areas (group with lingual herpes) and non-lesional areas (normal tongues). For each case, 7 sequential fields were quantified, totaling an area of 1  $\text{mm}^2$  of analysed tissue in each region.<sup>9</sup> Results were expressed as positive cells per  $\text{mm}^2$  of lamina propria.

### ***Statistical analysis***

Values are expressed as mean  $\pm$  SD or median (interquartile ranges). Comparison among groups was performed by ANOVA and Kruskal-Wallis test followed by the Bonferroni *post-hoc* test. A *P* value of  $< 0.05$  was considered as statistically significant. The statistical software SPSS version 17.0 was used for the analyses.

## **RESULTS**

### ***Control group***

The control group consisted of 6 male and 4 female patients. The mean age was  $55.1 \pm 4$  years (ranging from 49 to 60 years). The main autopsy findings included acute myocardial infarct, congestive heart failure, hypovolemic shock, pulmonary thromboembolism and subarachnoid haemorrhage.

### ***AIDS groups***

The AIDS groups consisted of 14 males and 6 females. The mean age was  $37 \pm 11$  years (ranging from 25 to 69 years). The mean CD4+ T lymphocyte blood counts were  $98 \pm 139$  cells/ $\mu$ L. The mean CD4+/CD8+ T-cell ratio was  $0.25 \pm 0.47$ . There were no differences in the CD4+ T lymphocytes blood counts and in the CD4+/CD8+ T-cell ratio between the two groups of AIDS patients ( $P = 0.721$ ). The main autopsy findings in AIDS patients were: cryptococcal meningitis, pneumonia, pneumocystosis, pulmonary thromboembolism, septic shock, tuberculosis and meningitis.

### ***Microscopic findings***

The histopathological findings in these samples have been published previously.<sup>10</sup>

Microscopically, acantholytic and multinucleated keratinocytes in the herpetic lesions of the tongue showed the typical molding of the nuclei as well as margination of the chromatin (Figure 1A). The diagnosis of HSV-1 was confirmed by immunohistochemistry (Figure 1B).

CD1a and CD83 staining showed positive cells with limited dendritic extensions in the lamina propria, mostly localized in the subepithelial region and near blood vessels. The density of CD1a+ cells was less than that of CD83+ cells.

### ***Interstitial dendritic cell quantification***

Patients with AIDS presented significantly lower densities of CD1a+ cells ( $12.53 \pm 11.99$  /mm<sup>2</sup>,  $P < 0.001$ ) and CD83+ cells ( $14.76 \pm 12.07$ /mm<sup>2</sup>,  $P < 0.001$ ) than the controls, which presented values of  $60.47 \pm 40.56$ /mm<sup>2</sup> and  $77.61 \pm 29.74$  /mm<sup>2</sup>, respectively, for CD1a and CD83 (Figure 2). On the other hand, the densities of iDCs were similar in the 2 groups of AIDS patients with or without herpes simplex infection of the tongue (CD1a,  $P = 0.856$  and CD83,  $P = 0.816$ ). The data are shown in Figure 3.

There were no correlations between CD1a+, CD83+ cells and CD4+ T-cells counts or CD4+/CD8+ T-cell count ratios (data not shown).

## DISCUSSION

In this work, we showed that the density of CD1a+ and CD83+ iDCs in the lamina propria of tongues from AIDS patients was lower than in non-AIDS patients. Interestingly, the density of iDCs was similar in the tongues of AIDS patients with or without lingual herpes infection (HSV-1). Similar findings were also observed in a previous study from our group comparing the population of LCs in tongues of AIDS patients with oral opportunistic infections.<sup>9</sup> To our knowledge, this is the first study of iDCs in AIDS patients with lingual herpes using autopsy material.

As sentinels of the immune system, DCs have important regulatory functions. Due to their specific location, DCs are a target for invading pathogens such as HIV-1 and HSV.<sup>11,12</sup> HSV-1 infection strongly affects DC function by interfering with DC maturation, including downregulation of costimulatory molecules as well as CD83 and CD1.<sup>13,14</sup>

According to Bosnjak *et al.*<sup>15</sup> HSV infections of the skin or mucosa are determined by complex interactions between virus immunoevasive mechanisms and the host immune system. HSV induces only partial impairment of DC function, and the infection is probably controlled by responses generated from uninfected DCs presenting infected cell debris.<sup>16,17</sup> Depending on the viral load, infected DCs are functionally compromised and may rapidly die, which would further decrease their contribution to overall T cell priming.<sup>18,19</sup>

A series of genetic lesions, idiopathic conditions and co-infections are associated with deficient DC responses to HSV and with severe primary HSV infections.<sup>20,21</sup> HIV co-infection is associated with low plasmacytoid dendritic cell (pDC) numbers and poor pDC responses to HSV.<sup>22</sup> Decreased numbers of circulating pDCs and HSV responsiveness were seen in persons with HSV-1 retinitis.<sup>23</sup> Moreover, HSV has developed several immune evasion mechanisms, including inhibition of complement and Ab binding, DC function, and MHC class I-mediated Ag presentation on infected cells.<sup>24</sup> DC maturation is required for optimal activation of naive T cells and entails a set of phenotypic changes that can be

induced directly by the pathogen via pattern recognition receptors or indirectly through danger signals, such as IL-1 $\beta$  or TNF- $\alpha$ , that are secreted by the surrounding cells.<sup>25</sup>

In the present study, we showed intense depletion of iDCs in groups independent of HSV infection. These findings suggest a greater potential role of HIV in the marked decline of the iDCs in the tongues of patients. Furthermore, larger numbers of CD83+ cells than CD1a+ cells were noted in all groups, in contrast to our previous study.<sup>9</sup> Because there are DCs in a more advanced stage of maturation in the lamina propria than in the oral epithelium, an increased expression of CD83+ cells is expected.<sup>26,27</sup>

Patients with HIV infection alone or HIV-HSV-1 coinfection showed no difference between CD4+/CD8+ cell counts ( $P = 0.58$ ). In a longitudinal study involving individuals with HIV with different rates of disease progression, Fontaine *et al.*<sup>28</sup> showed that myeloid DC levels were reduced in the blood of rapid and classic progressors, beginning in the acute phase of infection and persisting throughout the course of disease, despite successful therapy. This correlated with increased serum levels of DC-tropic chemokines, suggesting drainage to peripheral sites.<sup>29</sup>

A limitation of the current study was the age difference between the groups. Although there was no statistical difference among the ages of the AIDS patients ( $P = 0.39$ ), there were significant differences between AIDS and non-AIDS patients ( $P < 0.001$ ). Nevertheless some studies suggest that aging leads to a decline in immune cells, including dendritic cells.<sup>30,31</sup> In addition, it will be important to perform new studies that include HIV patients on highly active antiretroviral therapy (HAART) to verify the interference of this treatment on the population of DCs.

Thus, we conclude that advanced-stage AIDS patients suffer a profound depletion of iDCs in the tongue mucosa regardless of herpes infection. Further advances in this area are necessary for a better understanding of antiviral mechanisms.

## ACKNOWLEDGMENTS

This work was supported by the State of São Paulo Research Foundation (FAPESP: 10/51956-9) and the National Council for Scientific and Technological Development (CNPq - 302011/2010-2). There were no conflicts of interest. We also thank the São Paulo Death Verification Service for their assistance with material collection.

## DISCLOSURE/DUALITY OF INTEREST

The authors have no duality of interest to declare.

## REFERENCES

1. Banchereau J, Steinman RM. Dendritic cells and the control of immunity. *Nature* 1998; **392**; 245-252.
2. Mellman I, Steinman RM. Dendritic cells: specialized and regulated antigen processing machines. *Cell* 2001; **106**; 255-258.
3. Liu K, Victora GD, Schwickert TA *et al.* In vivo analysis of dendritic cell development and homeostasis. *Science* 2009; **324**; 392-397.
4. Waskow C, Liu K, Darrasse-Jèze G *et al.* The receptor tyrosine kinase Flt3 is required for dendritic cell development in peripheral lymphoid tissues. *Nat. Immunol.* 2008; **9**; 676-683.
5. Le Borgne M, Etchart N, Goubier A *et al.* Dendritic cells rapidly recruited into epithelial tissues via CCR6/CCL20 are responsible for CD8+ T cell crosspriming in vivo. *Immunity* 2006; **24**; 191–201.
6. Chalermarp N, Azuma M. Identification of three distinct subsets of migrating dendritic cells from oral mucosa within the regional lymph nodes. *Immunology* 2009; **127**; 558–566.

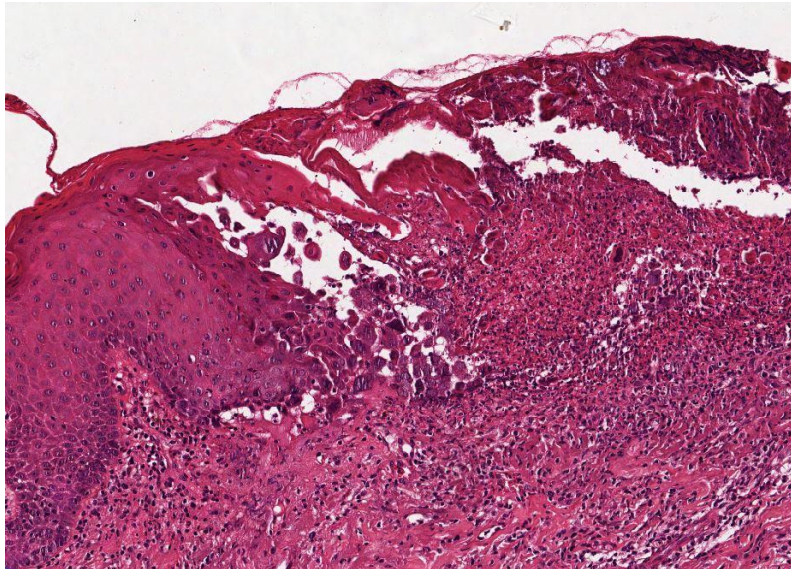


7. Jotwani R, Cutler CW. Multiple dendritic cell (DC) subpopulations in human gingiva and association of mature DCs with CD4+ T-cells in situ. *J. Dent. Res.* 2003; **82**; 736–741.
8. Cunningham AL, Abendroth A, Jones C, Nasr N, Turville S. Viruses and Langerhans cells. *Immunology and Cell Biology* 2010; **88**; 416-423.
9. Gondak RO, Alves DB, Silva LF, Mauad T, Vargas PA. Depletion of Langerhans cells in the tongue from patients with advanced-stage acquired immune deficiency syndrome: relation to opportunistic infections. *Histopathology* 2012; **60**; 497-503.
10. de Faria PR, Vargas PA, Saldiva PHN, Bohm GM, Mauad T, Almeida OP. Tongue diseases in advanced AIDS. *Oral Dis.* 2005; **11**; 72–80.
11. Burleigh L, Lozach PY, Schiffer C *et al.* Infection of dendritic cells (DCs), not DC-SIGN-mediated internalization of human immunodeficiency virus, is required for longterm transfer of virus to T cells. *J. Virol.* 2006; **80**; 2949–2957.
12. de Witte L, Abt M, Schneider-Schaulies S, van Kooyk Y, Geijtenbeek TB. Measles virus targets DC-SIGN to enhance dendritic cell infection. *J. Virol.* 2006; **80**; 3477–3486.
13. Raftery MJ, Winau F, Kaufmann SH, Schaible UE, Schonrich G. CD1 antigen presentation by human dendritic cells as a target for herpes simplex virus immune evasion. *J. Immunol.* 2006; **177**; 6207–6214.
14. Kummer M, Turza NM, Muhl-Zurbes P *et al.* Herpes simplex virus type 1 induces CD83 degradation in mature dendritic cells with immediate-early kinetics via the cellular proteasome. *J. Virol.* 2007; **81**; 6326–6338.
15. Bosnjak L, Miranda-Saksena M, Koelle DM, Boadle RA, Jones CA, Cunningham AL. Herpes simplex virus infection of human dendritic cells induces apoptosis and allows cross-presentation via uninfected dendritic cells. *J. Immunol.* 2005; **174**; 2220–2227.
16. Allan RS, Smith CM, Belz GT *et al.* Epidermal viral immunity induced by CD8a+ dendritic cells but not by Langerhans cells. *Science* 2003; **301**; 1925–1928.

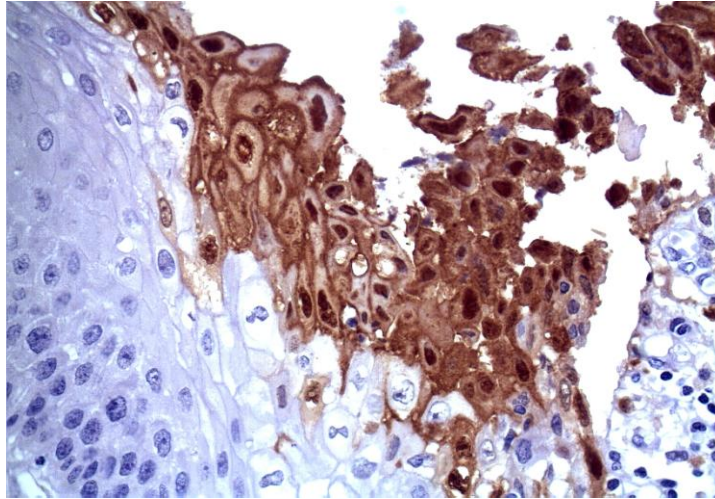
17. Allan RS, Waithman J, Bedoui S *et al.* Migratory dendritic cells transfer antigen to a lymph node-resident dendritic cell population for efficient CTL priming. *Immunity* 2006; **25**; 153–162.
18. Salio M, Cella M, Suter M, Lanzavecchia A. Inhibition of dendritic cell maturation by herpes simplex virus. *Eur. J. Immunol.* 1999; **29**; 3245–3253.
19. Jones CA, Fernandez MA, Herc K *et al.* Herpes simplex virus type 2 induces rapid cell death and functional impairment of murine dendritic cells in vitro. *J. Virol.* 2003; **77**; 11139–11149.
20. Sancho-Shimizu V, Perez de Diego R, Lorenzo L *et al.* Herpes simplex encephalitis in children with autosomal recessive and dominant TRIF deficiency. *J. Clin. Invest.* 2011; **121**; 4889-4902.
21. Tassone L, Moratto D, Vermi W *et al.* Defect of plasmacytoid dendritic cells in warts, hypogammaglobulinemia, infections, myelokathexis (WHIM) syndrome patients. *Blood* 2010; **116**; 4870-4873.
22. Abbo L, Vincek V, Dickinson G, Shrestha N, Doblecki S, Haslett PA. Selective defect in plasmacytoid dendritic cell function in a patient with AIDS-associated atypical genital herpes simplex vegetans treated with imiquimod. *Clin. Infect. Dis.* 2007; **44**; e25-27.
23. Kittan NA, Bergua A, Haupt S *et al.* Impaired plasmacytoid dendritic cell innate immune responses in patients with herpes virus-associated acute retinal necrosis. *J. Immunol.* 2007; **179**; 4219-4230.
24. Posavad CM, Koelle DM, Corey L. High frequency of CD8+ cytotoxic T-lymphocyte precursors specific for herpes simplex viruses in persons with genital herpes. *J. Virol.* 1996; **70**; 8165-8168.
25. Palucka K, Banchereau J. How dendritic cells and microbes interact to elicit or subvert protective immune responses. *Curr. Opin. Immunol.* 2002; **14**; 420-431.
26. Alyamkina EA, Leplina OY, Sakhno LV *et al.* Effect of double-stranded DNA on maturation of dendritic cells in vitro. *Cell Immunol.* 2010; **266**; 46-51.

27. Souto GR, Segundo TK, Costa FO, Aguiar MC, Mesquita RA. Effect of smoking on Langerhans and dendritic cells in patients with chronic gingivitis. *J. Periodontol.* 2011; **82**; 619-625.
28. Fontaine J, Coutlée F, Tremblay C, Routy JP, Poudrier J, Roger M. HIV infection affects blood myeloid dendritic cells after successful therapy and despite nonprogressing clinical disease. *J. Infect. Dis.* 2009; **199**; 1007–1018.
29. Fontaine J, Poudrier J, Roger M. Persistence of high blood levels of the chemokines CCL2, CCL19 and CCL20 during the course of HIV infection. *AIDS Res. Hum. Retroviruses* 2011; **27**; 655–657.
30. Linkova NS, Polyakova VO, Kvetnoy IM. Role of dendritic cells in the formation of subpopulation of cytotoxic T-lymphocytes in the thymus during its aging. *Bull. Exp. Biol. Med.* 2011; **151**; 457-459.
31. Orsini G, Legitimo A, Failli A, Massei F, Biver P, Consolini R. Enumeration of human peripheral blood dendritic cells throughout the life. *Int. Immunol.* 2012; **24**; 347-356.

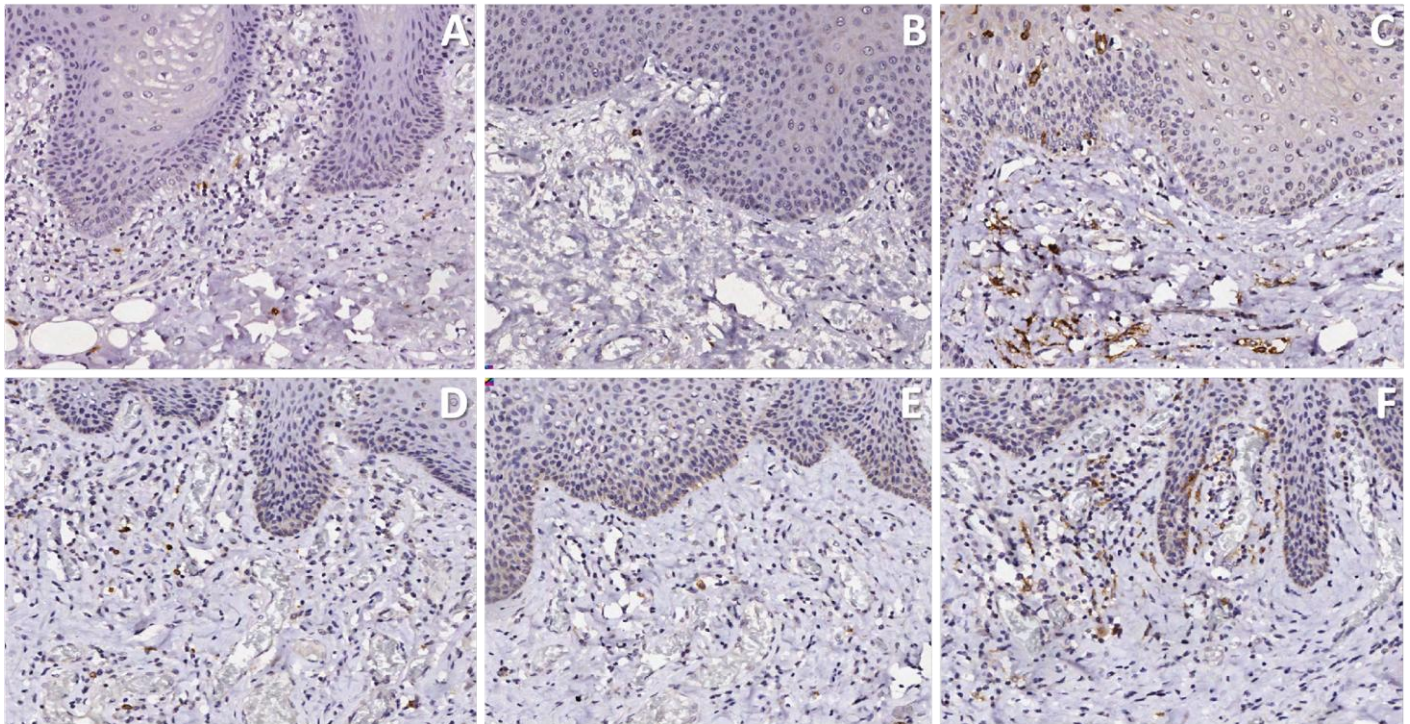
## FIGURES AND LEGENDS



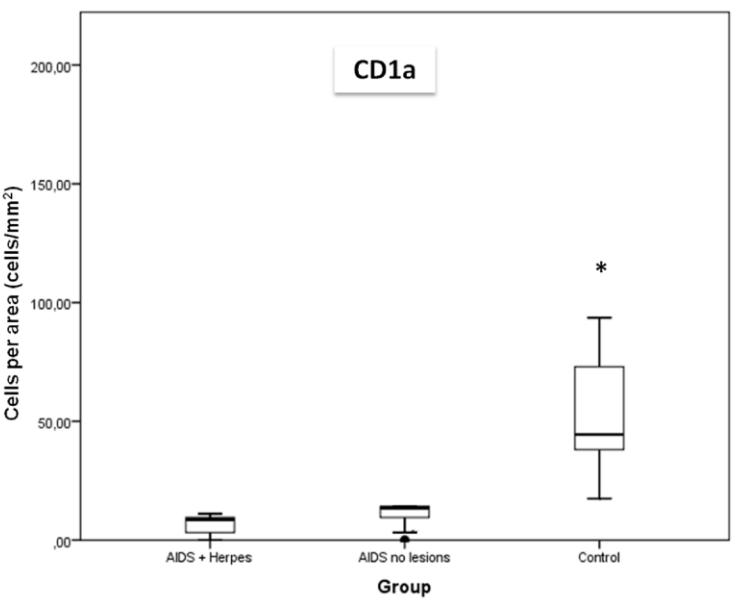
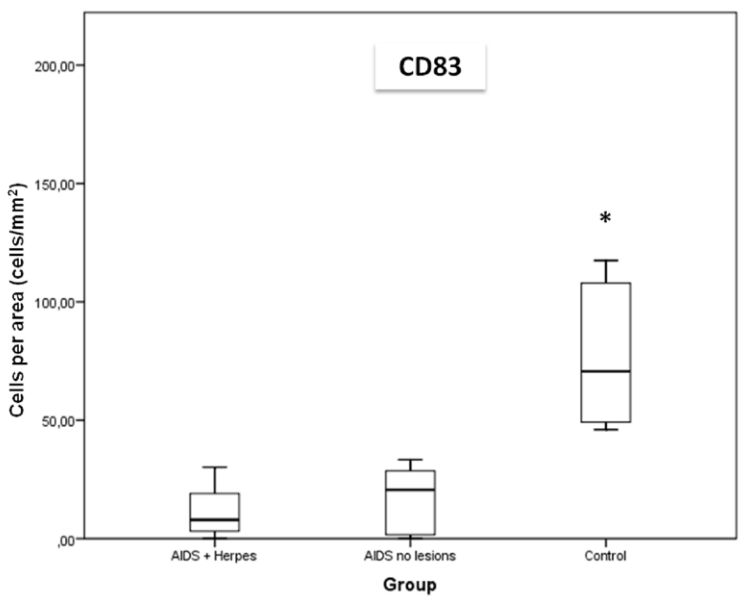
**Figure 1. A,** Epithelial cells infected with HSV showing typical molding of the nuclei and intense subepithelial inflammatory infiltrate (H&E, x 200).



**Figure 1. B,** Immunohistochemical detection of HSV-1 in epithelial cells (high magnification, 400 x).



**Figure 2.** Interstitial dendritic cells in the lamina propria of the tongue. **A,** CD1a+ cells (AIDS with herpes); **B,** CD1a+ cells (AIDS no lesions); **C,** CD1a+ cells (control group); **D,** CD83+ cells (AIDS with herpes); **E,** CD83+ cells (AIDS no lesions); **F,** CD83+ cells (control group). High magnification, 200 x.



**Figure 3.** Comparative analysis of CD1a+ and CD83+ cells among the groups. \*  $P < 0.001$  in relation to all acquired immune deficiency virus groups.

## CAPÍTULO 2

Artigo submetido para possível publicação no periódico *Histopathology*.

### **Decreased CD1a+, CD83+ and factor XIIIa+ dendritic cells in cervical lymph nodes and palatine tonsils of AIDS patients.**

Rogério O Gondak,<sup>1</sup> Thais Mauad,<sup>2</sup> Luciana Schultz,<sup>3</sup> Fernando A Soares,<sup>3</sup> Luiz P Kowalski<sup>4</sup> & Pablo A Vargas<sup>1</sup>

Short title: Dendritic cells in lymphoid tissue of AIDS patients

<sup>1</sup>*Department of Oral Diagnosis, Piracicaba Dental School, University of Campinas, Piracicaba, Brazil*

<sup>2</sup>*Department of Pathology, Sao Paulo University Medical School, São Paulo, Brazil.*

<sup>3</sup>*Department of Pathology, AC Camargo Hospital, São Paulo, Brazil.*

<sup>4</sup>*Department of Head & Neck, AC Camargo Hospital, São Paulo, Brazil.*

Conflict of interest:

The authors declare that they have no conflict of interest.

### **ABSTRACT**

*Aims:* The purpose of this study was to quantify and compare the density of dendritic cells (DCs) in cervical lymph nodes (LNs) and palatine tonsils (PTs) of AIDS and non-AIDS patients.

*Methods:* Factor XIIIa, CD1a and CD83 antibodies were used to identify conventional DCs by immunohistochemistry in LNs and PTs of 32 AIDS patients

and 21 HIV-negative control patients. Quantification was performed by the Positive Pixel Count analytical method.

*Results:* AIDS patients presented a lower density of Factor XIIIa+ cells ( $P < 0.001$ ), CD1a+cells ( $P < 0.05$ ) and CD83+ cells ( $P < 0.001$ ) in cervical LNs and PTs compared to the non-AIDS control group.

*Conclusion:* Overall depletion of DCs in lymphoid tissues of AIDS patients may be predictive of the immune system's loss of disease control.

**Keywords:** AIDS; dendritic cells; lymph node; palatine tonsil; immunohistochemistry.

## **INTRODUCTION**

Dendritic cells (DCs) are a heterogeneous population of cells with high phagocytic activity as immature cells and high cytokine-producing capacity as mature cells that work to maintain a balance between tolerance and protective immunity.<sup>1,2</sup> DCs are the most potent professional antigen-presenting cells required to initiate immune responses. After an antigen capture, DCs migrate to regional lymph nodes (LNs) via afferent lymphatics and endothelial venules regulating T cell responses in the steady state and during infections.<sup>3,4</sup>

Depending on location, function and level of maturation, DCs can present variable phenotypes. Immature DCs express CD1a and in the steady state are located at the epithelial surface of the skin, the gastrointestinal, respiratory, and genitourinary tracts<sup>5</sup> and in lymphoid organs.<sup>6</sup> Factor XIIIa+ DCs are located in the dermis as dermal DCs, in the interstitial areas of solid organs, and admixed with

lymphocytes in the interfollicular area of the LNs.<sup>7</sup> During the maturation process, DCs express CD83 as thymic DCs, circulating DCs, interdigitating reticulum cells present in the T cell zones of lymphoid organs, some germinal center cells, and monocyte derived DCs.<sup>8</sup> However, CD1a, factor XIIIa and CD83+ cells have rarely been investigated in LNs<sup>9,10</sup> or palatine tonsils (PTs) of AIDS patients.

DCs are susceptible to infection by HIV *in vitro* and *in vivo*.<sup>11,12</sup> HIV causes a marked depletion of DCs in HIV-1 positive patients, and impaired cytokine secretion and ability to stimulate T cells.<sup>13,14</sup>

We have previously reported the depletion of immature DCs in the intraepithelial areas of tongues from AIDS patients with different opportunistic infections.<sup>15</sup> In this work, we describe the effects of HIV infection on DCs in cervical LNs and PTs.

## **MATERIALS AND METHODS**

The Ethics Committee of the University of Campinas and University of São Paulo approved this study and the use of autopsy material according to ethical guidelines.

### ***Patient population***

Cervical LNs and PTs from 32 autopsied patients with AIDS were collected at the University of São Paulo between 1997 and 2011. In addition, 21 uninfected patients that had LNs and PTs dissected between 2010 and 2012 for diagnostic or therapeutic reasons at the University of Campinas and Instituto de Anatomia Patologica (Piracicaba, SP) were included in the study. Clinical charts and autopsy reports from all patients were reviewed and the last CD4+ and CD8+ T cell counts prior to the deaths of the 32 AIDS patients were obtained.



### ***Tissue processing***

Cervical LNs and PTs were fixed in 10% formalin for 24 hours and 6 transverse sections were obtained. All fragments were embedded in paraffin and 3- $\mu$ m thick histological sections were submitted to H&E staining and immunohistochemistry.

### ***Immunohistochemistry***

Immunoassays using monoclonal antibodies against CD1a (010, Dako, 1:80), CD83 (1H4b, Novocastra, 1:20) and Factor XIIIa (E980.1, Novocastra, 1:100) were carried out for the identification of DCs in the cervical LNs and PTs. Antigen retrieval with citrate was performed for all antibodies. The slides were incubated with secondary antibodies conjugated with horseradish peroxidase (LSAB + System-HRP, Mouse / Rabbit, Dako) for 30 minutes at 37°C. Afterward, the slides were incubated with Streptavidin-HRP (Dako) for another 30 minutes and developed with chromogenic substrate (3,3 diaminobenzidine-DAB, Sigma). The slides were counterstained with Harris hematoxylin. Negative controls were performed for each reaction, omitting the primary antibodies.

### ***Microscopic analysis***

Quantification was performed by the Positive Pixel Count Algorithm method using ImageScope software (Aperio, Vista, CA, USA). Positive Pixel Count is a multipurpose algorithm that quantifies the area and intensity of stains. Pixels were classified according to intensity of staining and colour. The intensity of staining was classified as strongly positive (red), positive (orange), weakly positive (yellow), or negative (blue) (Figure 1). A minimum area of 1mm<sup>2</sup> of lymphoid tissue was considered and the microscopic analysis was done at full 20x magnification. The results were expressed in percent positive area.

### ***Statistical analysis***

Statistical differences between groups were estimated using a standard non-parametric test (Mann-Whitney U-test). The results are presented as median and

interquartile ranges. Differences at  $P < 0.05$  were considered as statistically significant. The statistical software SPSS version 17.0 was used for the analyses.

## **RESULTS**

### ***Clinical findings***

The control group consisted of lymphoid tissue from 12 male patients and 9 females. The mean age was  $38.7 \pm 17.2$  years (ranging from 15 to 84 years). The main clinical findings in control patients were: diabetes, hepatitis B, cardiovascular disease, asthma and obesity.

The AIDS group consisted of 24 males and 8 females. The mean age was  $37.4 \pm 10.5$  years (ranging from 15 to 69 years). The mean CD4+ T lymphocyte blood counts were  $74 \pm 104$  cells/ $\mu$ L. The mean CD4+/CD8+ T-cell ratio was  $0.21 \pm 0.35$ . The main autopsy findings in AIDS patients were: pneumonia, pneumocystosis, pulmonary thromboembolism, septic shock, tuberculosis and meningitis.

### ***Microscopic findings***

Microscopically, factor XIIIa, CD1a and CD83 staining showed positive cells with abundant cytoplasm, ill-defined borders and interdigitating processes. These cells were located mainly in the T cell areas of secondary lymphoid organs. In control individuals, we observed a higher density of all markers in cervical LNs and PTs (Figures 2 and 3).

### ***Dendritic cells quantification***

Patients with AIDS had a smaller percentage of DCs in cervical LNs (Factor XIIIa+ cells,  $P < 0.001$ ; CD1a+ cells,  $P = 0.048$ ; and CD83+ cells,  $P < 0.001$ ) and PTs (Factor XIIIa+ cells,  $P < 0.001$ ; CD1a+ cells,  $P = 0.027$ ; and CD83+ cells,  $P < 0.001$ ) compared to the control group (Figure 4).

Within the AIDS group, there was no statistically significant difference in the percentage of DCs between cervical lymph nodes and palatine tonsils (Factor XIIIa+ cells,  $P = 0.989$ ; CD1a+ cells,  $P = 0.998$ ; and CD83+ cells,  $P = 0.999$ ). This finding was also observed between the two distinct anatomic regions in the control group (Factor XIIIa+ cells,  $P = 0.659$ ; CD1a+ cells,  $P = 0.994$ ; and CD83+ cells,  $P = 0.665$ ). The data are shown in Table 1.

## DISCUSSION

The continuous migration of DCs into secondary lymphoid organs such as LNs represents a fundamental element of immune surveillance and homeostasis.<sup>16</sup> Within LNs, DCs present antigens to cognate T cells, resulting in the induction of protective immunity.<sup>17,18</sup> In this study, we showed that the density of Factor XIIIa+, CD1a+ and CD83+ DCs in cervical LNs and PTs from AIDS patients was less than in non-AIDS patients. These findings extend the results seen in a previous study from our group that analysed the Langerhans cells population, a subset of DCs, in the tongues of AIDS patients,<sup>15</sup> demonstrating that the HIV virus promotes the overall depletion of DCs in lymphoid organs as well as oral tissues.

According to Donaghy et al.<sup>12</sup>, the decline in circulating DCs correlates with an increase in HIV-1 viral load and this depletion correlates with disease progression. HIV-1-exposed DCs retain their ability to mature phenotypically, which is crucial to their transition into potent antigen-presenting cells.<sup>19</sup> Moreover, the loss of DCs from blood could be a consequence of the increased migration of DCs to lymphoid organs or insufficient repopulation of blood DCs.<sup>20</sup>

DC biology suggests that half of the DCs within LNs enter from the bloodstream and the other half are believed to arise from lymph-migrating tissue DCs.<sup>21</sup> Within interfollicular areas of the lymph node cortex, the fibroblastic reticular cell network extends close to the subcapsular sinus floor and serves as a port of entry for cells arriving with the afferent lymph.<sup>22,23</sup> Activated DCs arrive largely via afferent lymph and remain confined to the subcapsular sinus of the afferent side of

the lymph node, migrating towards the deeper paracortical T cell zone through interfollicular areas of the cortex.<sup>16,24,25</sup> Only a minority of lymph node DCs in the steady state arise from DCs residing in upstream nonlymphoid organs. Instead, DCs that migrate through lymphatics from upstream tissues contribute substantially to the pool of lymph node DCs, mainly during inflammatory states.<sup>26</sup>

Immature and mature DCs were initially thought to occur in specific anatomic locations: immature DCs capture Ags in peripheral tissues whereas mature DCs present those Ags on their MHC molecules in the T cells areas of the draining lymphoid organs.<sup>27</sup> However, it has been shown that lymphoid organs such as tonsil, lymph node, thymus and spleen also contain large cohorts of immature DCs.<sup>6,28</sup> These DCs can either respond to infections reaching those organs and mature *in situ* or play a role in the maintenance of immunological peripheral tolerance.<sup>29,30</sup> This condition was observed in our study as the high density of factor XIIIa+ cells (immature DCs) in lymphoid tissues compared to CD83+ cells (mature cells). Moreover, factor XIIIa antibody can also be detected in a number of monocyte-derived macrophage lineages, including macrophages, histiocytic and dendritic reticulum cells, in LNs.<sup>31,32</sup> On the other hand, the density of CD1a+ cells was less than that shown by the other antibodies, because mature DCs, which are common in secondary lymphoid organs, express low levels of CD1a.<sup>33</sup>

After HIV crosses the mucosa or skin, it reaches the lymphoid tissue and permanent infection is established. The interaction between DCs and T-cells in lymphoid tissue is critical for the generation of immune responses. DCs are suggested to play a crucial role in the early events of HIV transmission by transporting the virus from the peripheral tissues to the lymphoid system and creating a perfect microenvironment for HIV-1 replication.<sup>34,35</sup> Some studies have suggested that DCs maintain their ability to stimulate T-cells after HIV exposure.<sup>36,37</sup>

During HIV infection, the majority of DCs can most likely respond to stimulation and present antigen to T cells, although the quality of the response may

be altered and exhibit a lower expression of molecules than what is normally found in lymphoid tissues.<sup>20,38</sup>

Nevertheless, factor XIIIa+, CD1a+ and CD83+ cells were located mostly in the cortical areas of LNs, in agreement with other authors<sup>39,40</sup> who reported that DCs were located in the T-cell-dependent areas of lymphoid tissues, in the skin, lungs and gut where antigens enter the body. The main DCs located in the T zone are designated interdigitating DCs, representing a population of mature DCs with high potential to stimulate lymphocytes and with high level expression of MHC class II and cytokines including IL-6, IL-10 and IL-13.<sup>1,41,42</sup>

Several investigations have demonstrated that DCs are also involved in regulating T-cell-mediated humeral immune responses, indicating that naive B cells interact with DCs in human tonsils.<sup>41,43</sup> Interdigitating dendritic cells (IDCs) interact with the large number of resting naive B cells directly in the T-cell area of the lymph node and are positive for mature-DC markers such as CD80, CD83 and CD86.<sup>44,45</sup>

DCs may influence B cell responses against HIV through contact or production of B cell growth factors such as B lymphocyte stimulator (BLyS/BAFF) that modulate the outcome of CD4 T cell HIV effectors.<sup>46</sup> Some longitudinal studies involving HIV patients with different rates of disease progression have shown that DC levels were reduced in the blood beginning in the acute phase of infection and persisting throughout the course of disease despite successful therapy.<sup>47</sup> This condition has been correlated with increased serum levels of DC-tropic chemokines and drainage to peripheral sites, and has also been associated with inflammatory conditions.<sup>48,49</sup>

The present study had some limitations. We studied the population of DCs in lymphoid tissues of patients with AIDS and severe immunosuppression because most of the patients died before highly active antiretroviral therapy (HAART) initiation. Hence, it would be interesting to study the distribution of DCs in LNs of HIV positive patients in different stages of disease or on HAART. A better understanding of the tissue distribution of DCs in HIV-infected patients may

contribute to the development of new therapeutic strategies and to inducing favourable adaptive anti-HIV immunity.<sup>38</sup>

In conclusion, advanced-stage AIDS patients have a profound depletion of DCs in cervical LNs and PTs that may be predictive of the immune system's loss of disease control. Advances regarding the role of DCs in HIV-1 infection will be important for the establishment of antiviral mechanisms and/or control of viral spread.

## **ACKNOWLEDGMENTS**

This work was supported by the State of São Paulo Research Foundation (FAPESP: 10/51956-9) and the National Council for Scientific and Technological Development (CNPq - 302011/2010-2). There were no conflicts of interest. We also thank the São Paulo Death Verification Service for their assistance with material collection.

## **REFERENCES**

1. Banchereau J, Steinman RM. Dendritic cells and the control of immunity. *Nature* 1998; 392; 245-252.
2. Mellman I, Steinman RM. Dendritic cells: specialized and regulated antigen processing machines. *Cell* 2001;106; 255-258.
3. Waskow C, Liu K, Darrasse-Jèze G, Guermonprez P, Ginhoux F, Merad M, Shengelia T, Yao K, Nussenzweig M. The receptor tyrosine kinase Flt3 is required for dendritic cell development in peripheral lymphoid tissues. *Nat. Immunol* 2008; 9: 676-683.
4. Liu K, Victora GD, Schwickert TA, Guermonprez P, Meredith MM, Yao K, Chu FF, Randolph GJ, Rudensky AY, Nussenzweig M. In vivo analysis of dendritic cell development and homeostasis. *Science* 2009; 324; 392-397.

5. Valladeau J, Ravel O, Dezutter-Dambuyant C, Moore K, Kleijmeer M, Liu Y, Duvert-Frances V, Vincent C, Schmitt D, Davoust J, Caux C, Lebecque S, Saeland S. Langerin, a novel C-type lectin specific to Langerhans cells, is an endocytic receptor that induces the formation of Birbeck granules. *Immunity* 2000; 12: 71-81.
6. Shortman K, Liu YJ. Mouse and human dendritic cell subtypes. *Nat Rev Immunol* 2002; 2: 151–161.
7. Duperrier K, Eljaafari A, Dezutter-Dambuyant C, Bardin C, Jacquet C, Yoneda K, Schmitt D, Gebuhrer L, Rigal D. Distinct subsets of dendritic cells resembling dermal DCs can be generated in vitro from monocytes, in the presence of different serum supplements. *J Immunol Methods* 2000; 238: 119-31
8. Wolenski M, Cramer SO, Ehrlich S, Steeg C, Fleischer B, von Bonin A. Enhanced activation of CD83-positive T cells. *Scand J Immunol* 2003; 58: 306-11.
9. Nemes Z, Adany R, Thomazy V. Selective visualization of human dendritic reticulum cells in reactive lymphoid follicles by the immunohistochemical demonstration of the subunit A of factor XIII (F-XIIIa). *Virchows Arch (Cell Pathol)* 1987;52:453–466.
10. Adany R, Szegedi A, Ablin R, Muszbek L. Fibrinolysis resistant fibrin deposits in lymph nodes with Hodgkin's disease. *Thromb Haemost* 1988;60:193–197.
11. MacDougall TH, Shattock RJ, Madsen C, Chain BM, Katz DR. Regulation of primary HIV-1 isolate replication in dendritic cells. *Clin Exp Immunol.* 2002;127:66-71.
12. Donaghy H, Gazzard B, Gotch F, Patterson S. Dysfunction and infection of freshly isolated blood myeloid and plasmacytoid dendritic cells in patients infected with HIV-1. *Blood* 2003; 101:4505–4511.
13. Barron MA, Blyveis N, Palmer BE, MaWhinney S, Wilson CC. Influence of plasma viremia on defects in number and immunophenotype of blood dendritic cell subsets in human immunodeficiency virus 1-infected individuals. *J Infect Dis* 2003; 187:26–37.

14. Almeida M, Cordero M, Almeida J, Orfao A. Different subsets of peripheral blood dendritic cells show distinct phenotypic and functional abnormalities in HIV-1 infection. *AIDS*. 2005;19:261-271
15. Gondak RO, Alves DB, Silva LF, Mauad T, Vargas PA. Depletion of Langerhans cells in the tongue from patients with advanced-stage acquired immune deficiency syndrome: relation to opportunistic infections. *Histopathology* 2012; 60; 497-503.
16. Förster R, Braun A, Worbs T. Lymph node homing of T cells and dendritic cells via afferent lymphatics. *Trends Immunol* 2012;33:271-80.
17. Steinman RM. Decisions about dendritic cells: past, present, and future. *Annu Rev Immunol* 2012;30:1-22.
18. Yamazaki S, Steinman RM. Dendritic cells as controllers of antigen-specific Foxp3<sup>+</sup> regulatory T cells. *J Dermatol Sci* 2009;54, 69–75.
19. Fonteneau JF, Larsson M, Beignon AS, McKenna K, Dasilva I, Amara A, Liu YJ, Lifson JD, Littman DR, Bhardwaj N. Human immunodeficiency virus type 1 activates plasmacytoid dendritic cells and concomitantly induces the bystander maturation of myeloid dendritic cells. *J Virol* 2004; 78:5223–5232.
20. Smed-Sörensen A, Loré K. Dendritic cells at the interface of innate and adaptive immunity to HIV-1. *Curr Opin HIV AIDS* 2011; 6:405–410.
21. Villadangos JA, Schnorrer P. Intrinsic and cooperative antigen-presenting functions of dendritic-cell subsets in vivo. *Nat. Rev Immunol* 2007;7:543 – 555 .
22. Alvarez, D. Vollmann EH, von Andrian UH. Mechanisms and consequences of dendritic cell migration. *Immunity* 2008; 29, 325–342
23. Schumann K, Lämmermann T, Brückner M, Legler DF, Polleux J, Spatz JP, Schuler G, Förster R, Lutz MB, Sorokin L, Sixt M. Immobilized chemokine fields and soluble chemokine gradients cooperatively shape migration patterns of dendritic cells. *Immunity* 2010; 32, 703–713.
24. Ohl L, Mohaupt M, Czeloth N, Hintzen G, Kiafard Z, Zwirner J, Blankenstein T, Henning G, Förster R. CCR7 governs skin dendritic cell migration under inflammatory and steady-state conditions. *Immunity* 2004; 21: 279 – 288 .



25. Wilson NS, Young LJ, Kupresanin F, Naik SH, Vremec D, Heath WR, Akira S, Shortman K, Boyle J, Maraskovsky E, Belz GT, Villadangos JA. Normal proportion and expression of maturation markers in migratory dendritic cells in the absence of germs or Toll-like receptor signaling. *Immunol Cell Biol* 2008; 86: 200 – 205.
26. Jakubzick C, Bogunovic M, Bonito AJ, Kuan EL, Merad M, Randolph GJ. Lymph-migrating, tissue-derived dendritic cells are minor constituents within steady-state lymph nodes. *J Exp Med* 2008; 205:2839-50.
27. Becker Y. Immunological and regulatory functions of uninfected and virus infected immature and mature subtypes of dendritic cells—a review. *Virus Genes* 2003; 26: 119–130.
28. Summers KL, Hock BD, McKenzie JL, Hart DN. Phenotypic characterization of five dendritic cell subsets in human tonsils. *Am J Pathol* 2001; 159: 285–295.
29. Wilson NS, El-Sukkari D, Belz GT, Smith CM, Steptoe RJ, Heath WR, Shortman K, Villadangos JA. Most lymphoid organ dendritic cell types are phenotypically and functionally immature. *Blood* 2003; 102: 2187–2194.
30. Wilson NS, Villadangos JA. Lymphoid organ dendritic cells: beyond the Langerhans cells paradigm. *Immunol Cell Biol* 2004; 82: 91–98.
31. Muszbek L, Yee VC, Hevessy Z. Blood coagulation factor XIII: structure and function. *Thromb Res* 94: 271–305, 1999
32. Adany R, Bardos H. Factor XIII subunit A as an intracellular transglutaminase. *Cell Mol Life Sci* 2003; 60: 1049–1060.
33. Peressin M, Holl V, Schmidt S, Decoville T, Mirisky D, Lederle A, Deleporte M, Xu K, Aubertin AM, Moog C. HIV-1 replication in Langerhans and interstitial dendritic cells is inhibited by neutralizing and Fc-mediated inhibitory antibodies. *J Virol* 2011; 85:1077-1085.
34. Pope M, Betjes MG, Romani N, Hirmand H, Cameron PU, Hoffman L, Gezelter S, Schuler G, Steinman RM. Conjugates of dendritic cells and memory T lymphocytes from skin facilitate productive infection with HIV-1. *Cell* 1994; 78:389–398

35. Pope M, Gezelter S, Gallo N, Hoffman L, Steinman RM. Low levels of HIV-1 infection in cutaneous dendritic cells promote extensive viral replication upon binding to memory CD4+ T cells. *J Exp Med* 1995; 182:2045–2056.
36. Moris A, Pajot A, Blanchet F, Guivel-Benhassine F, Salcedo M, Schwartz O. Dendritic cells and HIV-specific CD4+ T cells: HIV antigen presentation, T-cell activation, and viral transfer. *Blood* 2006; 108:1643–1651.
37. Lubong Sabado R, Kavanagh DG, Kaufmann DE, Fru K, Babcock E, Rosenberg E, Walker B, Lifson J, Bhardwaj N, Larsson M. In vitro priming recapitulates in vivo HIV-1 specific T cell responses, revealing rapid loss of virus reactive CD4 T cells in acute HIV-1 infection. *PLoS One* 2009; 4:e4256.
38. Alter G, Kavanagh D, Rihn S, Luteijn R, Brooks D, Oldstone M, van Lunzen J, Altfeld M. IL-10 induces aberrant deletion of dendritic cells by natural killer cells in the context of HIV infection. *J Clin Invest* 2010; 120:1905–1913.
39. Nestle FO, Filgueira L, Nickoloff BJ, Burg G. Human dermal dendritic cells process and present soluble protein antigens. *J Invest Dermatol* 1998;110:762–766.
40. Robert C, Fuhlbrigge R, Kieffer D, Ayehunic S, Hynes RO, Cheng G, Grabbe S, von Adrian VH, Kupper TS. Interaction of dendritic cells with skin endothelium: A new perspective in immunosurveillance. *J Exp Med* 1999;189:627–635.
41. Bjorck P, Flores-Romo L, Liu YJ. Human interdigitating dendritic cells directly stimulate CD40-activated naive B-cells. *Eur J Immunol* 1997; 27:1266–1274.
42. Steinman RM, Pack M, Inaba K. Dendritic cells in the T-cell areas of lymphoid organs. *Immunol Rev* 1997;156:25-37.
43. Feyette J, Dubois B, Vandenabeele S, Bridon JM, Vanbervliet B, Durand I, Banchereau J, Caux C, Briere F. Human dendritic cells skew switching of CD40-activated naive B-cells towards IgA1 and IgA2. *J Exp Med* 1997; 185:1909–1918
44. Takahashi K, Asagoe K, Teramoto N, Kondo E, Oka T, Hayashi K, Yoshino T, Akagi T. Morphological interaction of interdigitating dendritic cells with B and T-cells in human mesenteric lymph nodes. *Am J Pathol* 2001; 159:131–138.

45. Takahashi K, Nishikawa Y, Sato H, Oka T, Yoshino T, Miyatani K. Dendritic cells interacting mainly with B cells in the lymphoepithelial symbiosis of the human palatine tonsil *Virchows Arch* 2006; 448: 623–629.
46. Poudrier J, Roger M. Dendritic Cell Status Modulates the Outcome of HIV-Related B Cell Disease Progression. *PLoS Pathog* 2011; 7: e1002154
47. Fontaine J, Coutlée F, Tremblay C, Routy JP, Poudrier J, Roger M. HIV infection affects blood myeloid dendritic cells after successful therapy and despite nonprogressing clinical disease. *J Infect Dis* 2009; 199: 1007–1018.
48. del Rio ML, Bernhardt G, Rodriguez-Barbosa JI, Förster R. Development and functional specialization of CD103+ dendritic cells. *Immunol Rev* 2010; 234: 268–281.
49. Fontaine J, Chagon-Choquet J, Valcke HS, Poudrier J, Roger M. High expression levels of B Lymphocyte Stimulator (BLyS) by dendritic cells correlate with HIV-related B cell disease progression in humans. *Blood* 2011; 117:145–155.

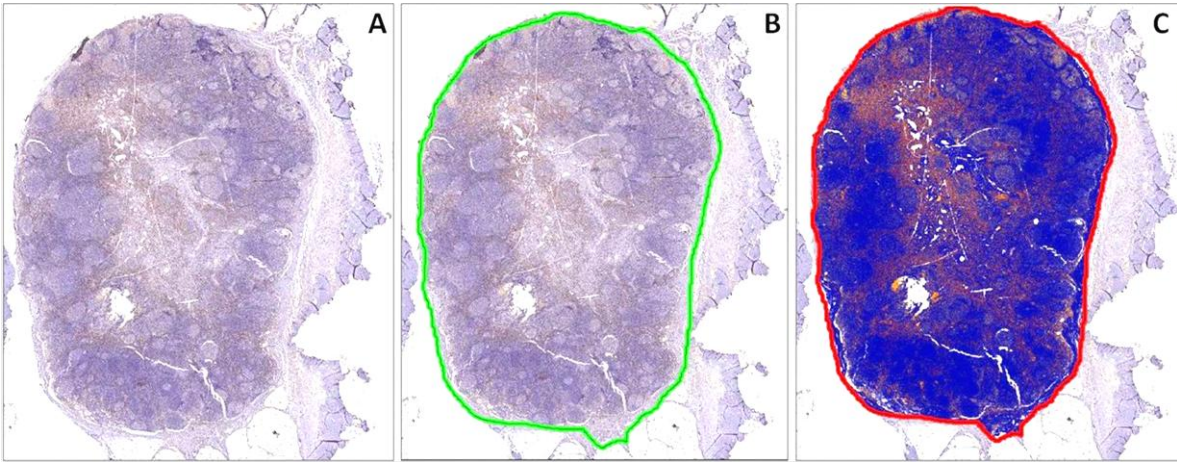
## TABLE

**Table 1.** Cell density in cervical lymph nodes and palatine tonsils.

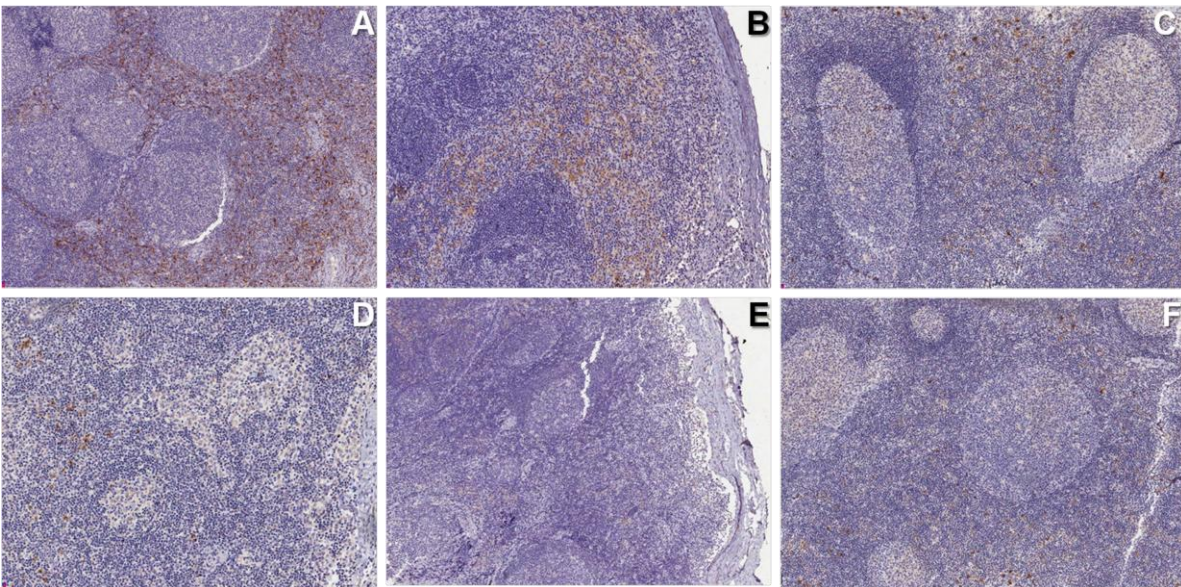
Cell types	Cell density (%) in			
	Cervical lymph node		Palatine tonsil	
	AIDS patients	Control group	AIDS patients	Control group
<b>Factor XIIIa</b>	7,52 ± 3,83	44,53 ± 20,18 <sup>a</sup>	5,76 ± 2,24	38,03 ± 13,70 <sup>a</sup>
<b>CD1a</b>	2,05 ± 0,98	11,83 ± 9,25 <sup>b</sup>	1,62 ± 0,77	11,28 ± 12,13 <sup>b</sup>
<b>CD83</b>	2,31 ± 1,44	15,48 ± 9,66 <sup>a</sup>	1,94 ± 1,21	16,47 ± 11,28 <sup>a</sup>

<sup>a</sup> *P* < 0.001 in relation to AIDS group. <sup>b</sup> *P* < 0.05 in relation to AIDS group.

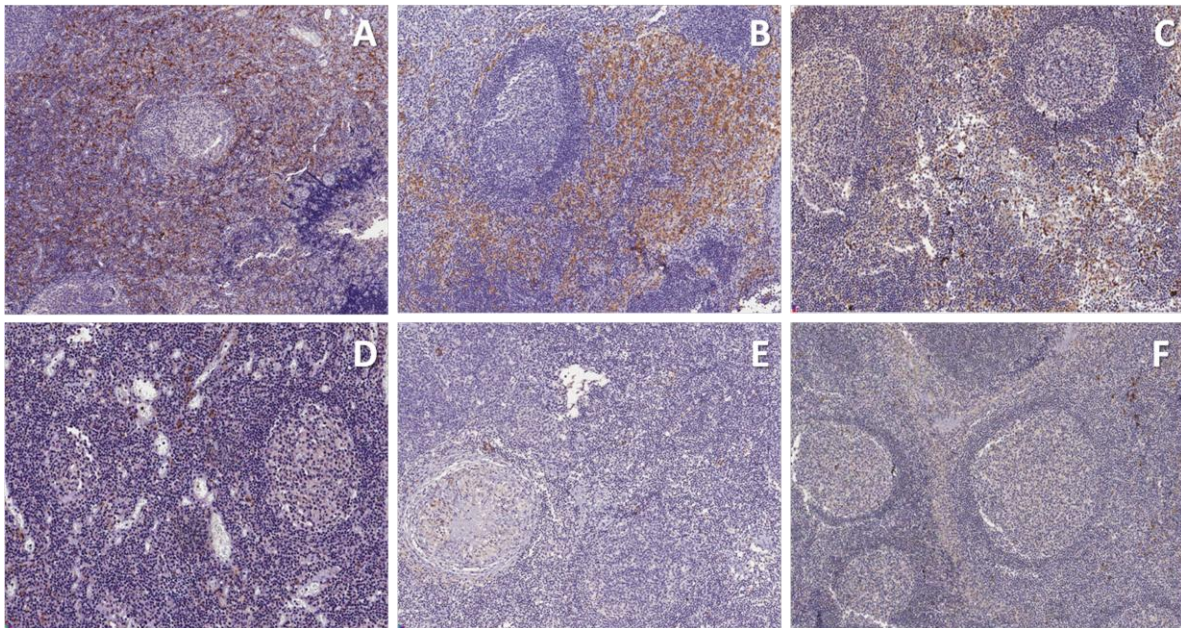
## FIGURES AND LEGENDS



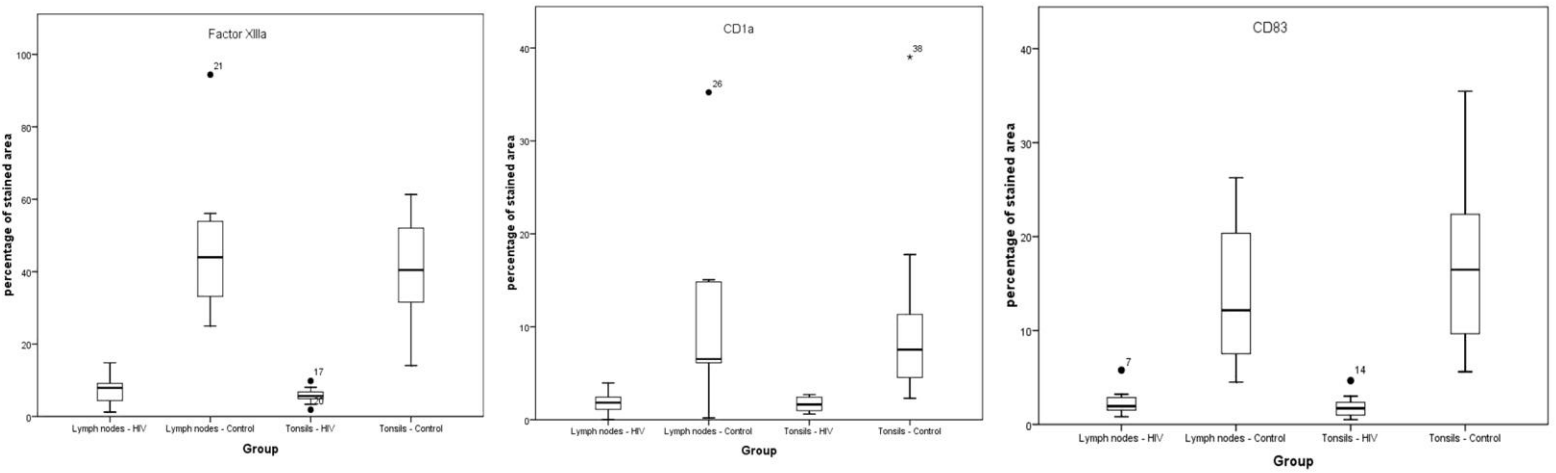
**Figure 1.** Immunostaining evaluation method using Image Scope software. A. Factor XIIIa+ cells in a cervical lymph node from a control patient. B. Delimitation of the area to be analyzed in mm<sup>2</sup>. C. Positive Pixel Count function measuring the intensity of staining according to specific colour (blue = negative, yellow = weakly positive, orange = medium positive, red = strongly positive).



**Figure 2. A,B,C;** Immunohistochemical expression of factor XIIIa+, CD1a+ and CD83+ cells in cervical lymph nodes in the control group, respectively. High concentrations of positive cells in the paracortical T cell zone through interfollicular areas of the cortex D,E,F; Factor XIIIa+, CD1a+ and CD83+ cells in the cervical lymph nodes in the AIDS group showing profound depletion of dendritic cells (high magnification, 200 x).



**Figure 3.** Representative immunohistochemical stainings of palatine tonsils. **A, B, C.** Factor XIIIa+, CD1a+ and CD83+ cells, respectively, in the control group. **D,E,F** Depletion of factor XIIIa+, CD1a+ and CD83+ cells, respectively, in the AIDS group (high magnification, 200 x).



**Figure 4.** Comparative analysis of Factor XIIIa+, CD1a+, CD83+ cells in cervical lymph nodes and palatine tonsils between the study groups.

## CONCLUSÃO

- Houve uma intensa redução na população de CDs intersticiais na língua de pacientes com AIDS;
- Pacientes com AIDS e portadores de infecção herpética lingual não apresentaram diferenças significativas na quantificação de CDs intersticiais quando comparados com pacientes com AIDS e sem lesões linguais;
- O HIV promoveu uma depleção significativa de CDs tanto em linfonodos cervicais quanto em tonsilas palatinas.

## REFERÊNCIAS\*

1. Steinman RM. Decisions about dendritic cells: past, present, and future. *Annu Rev Immunol.* 2012;30:1-22.
2. Hart DNJ. Dendritic cells: unique leukocyte populations which control the primary immune response. *J Amer Soc Hematol.* 1997;90:3245-87.
3. Banchereau J, Steinman RM. Dendritic cells and the control of immunity. *Nature.* 1998;392:245-52.
4. Shortman K, Naik SH. Steady-state and inflammatory dendritic cell development. *Nat Rev Immunol.* 2007;7:19-30.
5. Mclellan AD, Kämpgen E. Functions of myeloid and lymphoid dendritic cells. *Immunol Let.* 2000;72:101-5.
6. Steinman RM, Pack M, Inaba K. Dendritic cell development and maturation. *Adv Exp Med Biol.* 1997;417:1–6.
7. Liu K, Nussenzweig MC. Origin and development of dendritic cells. *Immunol Rev.* 2010;234:45-54.
8. Satpathy AT, Murphy KM, KC W. Transcription factor networks in dendritic cell development. *Semin Immunol.* 2011;23:388-97.
9. Belz GT, Nutt SL. Transcriptional programming of the dendritic cell network. *Nat Rev Immunol.* 2012;12:101-13.
10. Cheong C, Matos I, Choi JH, *et al.* Microbial stimulation fully differentiates monocytes to DC-SIGN/CD209(+) dendritic cells for immune T cell areas. *Cell.* 2010;143:416-29.
11. Holíková JPZ, Smetana Jr K, Riedel F, *et al.* The role of dendritic cells in the pharynx. *Eur Arch Otorhinolaryngol.* 2003;260:266–72.
12. Steinman RM, Pack M, Inaba K. Dendritic cell development and maturation. *Adv Exp Med Biol.* 1997;417:1–6.

---

\* De acordo com a norma da UNICAMP/FOP, baseada na norma do International Committee of Medical Journal Editors – Grupo Vancouver. Abreviatura dos periódicos em conformidade com o Medline.



13. Guermonprez P, Valladeau J, Zitvogel L, *et al.* Antigen presentation and T cell stimulation by dendritic cells. *Annu Rev Immunol.* 2002;20:621-67.
14. Dieu MC, Vanbervliet B, Vicari A, *et al.* Selective recruitment of immature dendritic cells by distinct chemokines expressed in different anatomic sites. *J Exp Med.* 1998;188:373-86.
15. Noble B, Frankel S, Gorfien J, *et al.* Microanatomical distribution of dendritic cells in normal tonsils. *Acta Otolaryngol Suppl.* 1996;523:94-7.
16. Lanzavecchia A, Sallusto F. Regulation of T cell immunity by dendritic cells. *Cell.* 2001;106:263-6.
17. Colonna M, Pulendran B, Iwasaki A. Dendritic cells at the host-pathogen interface. *Nat Immunol.* 2006;7:117-20.
18. Chen CH, Floyd H, Olson NE *et al.* Dendritic-cell-associated C-type lectin 2 (DCAL-2) alters dendritic-cell maturation and cytokine production. *Blood.* 2006;107:1459-67.
19. Dubois B, Vanbervliet B, Fayette J, *et al.* Dendritic cells enhance growth and differentiation of CD40-activated B lymphocytes. *J Exp Med.* 1997;185: 941-51.
18. Banchereau J, Schuler-Thurner B, Palucka K, *et al.* Dendritic cells as vectors for therapy. *Cell.* 2001;106:271-4.
19. Chou LL, Epstein J, Cassol AS, *et al.* Oral mucosal Langerhans cells as target effector and vector in HIV infection. *J Oral Pathol Med.* 2000;29:394-402.
20. Smed-Sorensen A, Lore K, Vasudevan J, *et al.* Differential susceptibility to human immunodeficiency virus type 1 infection of myeloid and plasmacytoid dendritic cells. *J Virol.* 2005;79:8861-9.
21. Hladik F, Sakchalathorn P, Ballweber L, *et al.* Initial events in establishing vaginal entry and infection by human immunodeficiency virus type-1. *Immunity* 2007;26:257-270.
22. Frankel SS, Wenig BM, Burke AP, *et al.* Replication of HIV-1 in dendritic cell-derived syncytia at the mucosal surface of the adenoid. *Science.* 1996;272:115-7.
23. Hewson T, Loone N, Moore M, *et al.* Interactions of HIV-1 with antigen presenting cells. *Immunol Cell Biol.* 1999;77:289-303.

24. Pope M. Mechanisms of mucosal immunity: How does the dendritic cell fit in? *AIDS Patient Care STDS*. 2000;14:207–10.
25. Lore K, Sonnerborg A, Broström C, *et al*. Accumulation of DC-SIGN+CD40+ dendritic cells with reduced CD80 and CD86 expression in lymphoid tissue during acute HIV-1 infection. *AIDS*. 2002;16:683–92.
26. Dillon SM, Robertson KB, Pan SC, *et al*. Plasmacytoid and myeloid dendritic cells with a partial activation phenotype accumulate in lymphoid tissue during asymptomatic chronic HIV-1 infection. *J Acquir Immune Defic Syndr*. 2008; 48:1–12.
27. Wijewardana V, Soloff AC, Liu X, *et al*. Early myeloid dendritic cell dysregulation is predictive of disease progression in simian immunodeficiency virus infection. *PLoS Pathog*. 2010;6:e1001235.
28. Halary F, Amara A, Lortat-Jacob H, *et al*. Human cytomegalovirus binding to DC-SIGN is required for dendritic cell infection and target cell transinfection. *Immunity*. 2002;17:653–64.
29. Burleigh L, Lozach PY, Schiffer C, *et al*. Infection of dendritic cells (DCs), not DC-SIGN-mediated internalization of human immunodeficiency virus, is required for long term transfer of virus to T cells. *J Virol*. 2006;80:2949–57.
30. de Witte L, Bobardt M, Chatterji U, *et al*. Syndecan-3 is a dendritic cell specific attachment receptor for HIV-1. *Proc Natl Acad Sci USA*. 2007;104:19464–9.
31. Siegel D, Golden E, Washington AE, *et al*. Prevalence and correlates of herpes simplex infections. The population-based AIDS in multiethnic neighborhoods study. *JAMA*. 1992;268:1702-8.
32. Lafferty WE, Coombs RW, Benedetti J, *et al*. Recurrences after oral and genital herpes simplex virus action: influence of site of infection and viral type. *N Engl J Med*. 1987;316:1444-9.
33. Augenbraun M, Feldman J, Chirgwin K, *et al*. Increased genital shedding of herpes-simplex virus type-2 in HIV-positive women. *Ann Intern Med*. 1995;123: 845-7.

34. Rad AN, Pollara G, Sohaib SM, *et al.* The differential influence of allogeneic tumor cell death via DNA damage on dendritic cell maturation and antigen presentation. *Cancer Res.* 2003;63:5143-50.
35. Raftery MJ, Winau F, Kaufmann SH, *et al.* CD1 antigen presentation by human dendritic cells as a target for herpes simplex virus immune evasion. *J Immunol.* 2006;177:6207–14.
36. Kummer M, Turza NM, Muhl-Zurbes P, *et al.* Herpes simplex virus type 1 induces CD83 degradation in mature dendritic cells with immediate-early kinetics via the cellular proteasome. *J Virol.* 2007;81:6326–38.
37. Theodoridis AA, Prechtel AT, Turza NM, *et al.* Infection of human dendritic cells with herpes simplex virus type 1 dramatically diminishes the mRNA levels of the prostaglandin E2 receptors EP2 and EP4. *Immunobiology.* 2007;212:827–38.



**COMITÊ DE ÉTICA EM PESQUISA**  
**FACULDADE DE ODONTOLOGIA DE PIRACICABA**  
**UNIVERSIDADE ESTADUAL DE CAMPINAS**

**CERTIFICADO**

O Comitê de Ética em Pesquisa da FOP-UNICAMP certifica que o projeto de pesquisa "**Análise das células dendríticas e sua correlação com as infecções virais e fúngicas diagnosticadas nas línguas, tonsilas palatinas e linfonodos cervicais de pacientes autopsiados com AIDS em estágio avançado**", protocolo nº 114/2010, dos pesquisadores Rogério Gondak, Marianne de Vasconcelos Carvalho, Oslei Paes de Almeida, Pablo Agustin Vargas e Thais Mauad, satisfaz as exigências do Conselho Nacional de Saúde - Ministério da Saúde para as pesquisas em seres humanos e foi aprovado por este comitê em 13/11/2010.

The Ethics Committee in Research of the School of Dentistry of Piracicaba - State University of Campinas, certify that the project "**Expression of dendritic cells and its correlation with viral and fungal infections in the tongue, palatine tonsils and cervical lymph nodes of autopsied patients with advanced AIDS**", register number 114/2010, of Rogério Gondak, Marianne de Vasconcelos Carvalho, Oslei Paes de Almeida, Pablo Agustin Vargas and Thais Mauad, comply with the recommendations of the National Health Council - Ministry of Health of Brazil for research in human subjects and therefore was approved by this committee at 11/13/2010.



**Prof. Dr. Pablo Agustin Vargas**  
Secretário  
CEP/FOP/UNICAMP



**Prof. Dr. Jacks Jorge Junior**  
Coordenador  
CEP/FOP/UNICAMP

Nota: O título do protocolo aparece como fornecido pelos pesquisadores, sem qualquer edição.  
Notice: The title of the project appears as provided by the authors, without editing.

## **Anexo 2 – Certificado da Comissão de Ética para Análise de Projetos de Pesquisa do Hospital das Clínicas da Faculdade de Medicina da Universidade de São Paulo (CAPPesq – FMUSP)**



### **APROVAÇÃO**

A Comissão de Ética para Análise de Projetos de Pesquisa - CAPPesq da Diretoria Clínica do Hospital das Clínicas e da Faculdade de Medicina da Universidade de São Paulo, em sessão de 01/07/2009, **APROVOU** o Protocolo de Pesquisa nº **0624/09**, intitulado: "**AVALIAÇÃO DAS CÉLULAS DE LANGERHANS NA LÍNGUA DE PACIENTES AUTOPSIADOS, COM AIDS EM ESTÁGIO AVANÇADO.**" apresentado pelo Departamento de **PATOLOGIA**.

Cabe ao pesquisador elaborar e apresentar à CAPPesq, os relatórios parciais e final sobre a pesquisa (Resolução do Conselho Nacional de Saúde nº 196, de 10/10/1996, inciso IX.2, letra "c").

Pesquisador (a) Responsável: **Profa. Dra. Thais Mauad**

Pesquisador (a) Executante: **Daniel Berretta Moreira Alves**

CAPPesq, 01 de Julho de 2009

**Prof. Dr. Eduardo Massad**  
**Presidente da Comissão de**  
**Ética para Análise de Projetos**  
**de Pesquisa**

Comissão de Ética para Análise de Projetos de Pesquisa do HCFMUSP e da FMUSP Diretoria Clínica do Hospital das Clínicas da Faculdade de Medicina da Universidade de São Paulo Rua Ovídio Pires de Campos, 225, 5º andar - CEP 05403 010 - São Paulo – SP Fone: 011 3069 6442 Fax: 011 3069 6492 e-mail: [cappesq@hcnet.usp.br](mailto:cappesq@hcnet.usp.br) / [secretariacappesq2@hcnet.usp.br](mailto:secretariacappesq2@hcnet.usp.br)

hf

**Anexo 3 – Declaração de alteração de Pesquisador Executante no Hospital das Clínicas da Faculdade de Medicina da Universidade de São Paulo (HC-FMUSP)**



**Ao**  
**Departamento de Patologia**

A Comissão de Ética para Análise de Projetos de Pesquisa - CAPPesq da Diretoria Clínica do Hospital das Clínicas e da Faculdade de Medicina da Universidade de São Paulo, em sessão de 24/02/2010, tomou conhecimento da **alteração do Pesquisador Executante** do Protocolo de Pesquisa nº **0624/09**, intitulado: **“Avaliação das Células de Langerhans na língua de pacientes autopsiados, com AIDS em estágio avançado”**, passando do **Daniel Berreta Moreira** para o **Rogério Gondak**.

CAPPesq, 24 de fevereiro de 2010..

**PROF. DR. EDUARDO MASSAD**  
**Presidente da Comissão Ética para Análise**  
**de Projetos de Pesquisa**