

ADEMAR TAKAHAMA JUNIOR

**AVALIAÇÃO CLÍNICA E HISTOPATOLÓGICA DE
TUMORES DA GLÂNDULA PARÓTIDA**

Tese apresentada à Faculdade de Odontologia de Piracicaba, da Universidade Estadual de Campinas, para a obtenção do Título de Doutor em Estomatopatologia.

Orientador: Prof. Dr. Luiz Paulo Kowalski

Co-orientador: Prof. Dr. Oslei Paes de Almeida

PIRACICABA
2008

**FICHA CATALOGRÁFICA ELABORADA PELA
BIBLIOTECA DA FACULDADE DE ODONTOLOGIA DE PIRACICABA**

Bibliotecária: Marilene Girello – CRB-8ª. / 6159

T139a Takahama Junior, Ademar.
Avaliação clínica e histopatológica de tumores da glândula parótida. / Ademar Takahama Junior. -- Piracicaba, SP : [s.n.], 2008.

Orientadores: Luiz Paulo Kowalski, Oslei Paes de Almeida.
Tese (Doutorado) – Universidade Estadual de Campinas, Faculdade de Odontologia de Piracicaba.

1. Neoplasias bucais. 2. Glândulas salivares. I. Kowalski, Luiz Paulo. II. Almeida, Oslei Paes de. III. Universidade Estadual de Campinas. Faculdade de Odontologia de Piracicaba. IV. Título.
(mg/fop)

Título em Inglês: Clinical and histopathological analysis of parotid gland tumors

Palavras-chave em Inglês (Keywords): 1. Mouth neoplasms. 2. Salivary glands

Área de Concentração: Semiologia

Titulação: Doutor em Estomatopatologia

Banca Examinadora: Luiz Paulo Kowalski, Mauro Kasuo Ikeda, Fábio de Abreu Alves
Márcio Ajudarte Lopes, Pablo Agustin Vargas

Data da Defesa: 21-05-2008

Programa de Pós-Graduação em Estomatopatologia



UNIVERSIDADE ESTADUAL DE CAMPINAS
FACULDADE DE ODONTOLOGIA DE PIRACICABA



A Comissão Julgadora dos trabalhos de Defesa de Tese de DOUTORADO, em sessão pública realizada em 21 de Maio de 2008, considerou o candidato ADEMAR TAKAHAMA JUNIOR aprovado.

PROF. DR. LUIZ PAULO KOWALSKI

PROF. DR. MAURO KASUO IKEDA

PROF. DR. FÁBIO DE ABREU ALVES

PROF. DR. MARCIO AJUDARTE LOPES

PROF. DR. PABLO AGUSTIN VARGAS

DEDICATÓRIA

*Aos meus **Pais**, pelo incentivo.*

*À **Juliana**, pelo carinho e companheirismo.*

AGRADECIMENTOS

À Faculdade de Odontologia de Piracicaba da Universidade Estadual de Campinas.

Ao meu orientador **Prof. Dr. Luiz Paulo Kowalski**.

Ao **Prof. Dr. Oslei Paes de Almeida**, co-orientador do trabalho.

Ao **Prof. Dr. Márcio Ajudarte Lopes**, meu orientador do mestrado e grande incentivador.

Ao **Prof. Dr. Jacks Jorge Junior**, coordenador do curso de pós-graduação de estomatopatologia.

Aos Professores do Departamento, **Edgard Graner, Oswaldo Di Hipólito Junior, Pablo Agustín Vargas e Ricardo Della Coletta**.

Ao Dr. **Álvaro Sanabria**, pela ajuda na realização das análises estatísticas.

Ao Dr. **Gustavo Melo Benevides**, pela ajuda na coleta dos dados.

À senhora **Hirde Contesini** e a todos os funcionários do SAME do Hospital A.C. Camargo, pela ajuda nas coletas das informações dos prontuários médicos.

Aos amigos, **Danyel Elias da Cruz Perez e Eduardo Rodrigues Fregnani**, que me ajudaram muito.

Aos funcionários e amigos do Orocentro, **Rogério, Cida, Débora e Elizabeth**.

Aos meus amigos especiais, **Alan, Guillermo, Jorge, Lilia, Maria Fernanda e Patrícia**.

Aos grandes amigos do Orocentro de terça, **Marcelo Bicudo, Mateus e Renata.**

Aos grandes amigos da pós-graduação, **Adrielle, Ana Terezinha, Andréia, Carolina Bitu, Débora, Fabiana, Fernanda, Lays, Lívia, Lucielma, Luiz, Marcelo, Marco Antônio, Mário, Michele Agostini, Michele Kellermann, Vander e Victor.**

Aos funcionários do Departamento, **Adriano, Ana Cristina, Rosa e João.**

Aos amigos de Piracicaba, **Carlos, Neymar, Laura, Marlise e Paula.**

RESUMO

Os tumores de glândulas salivares são raros, registrando-se cerca de 0,4 a 13,5 casos por 100000 pessoas por ano. A maioria desses tumores acometem a glândula parótida, representando de 64% a 80% dos casos, com predomínio de tumores benignos. Os objetivos deste trabalho foram avaliar as principais características clínicas e histopatológicas de tumores de parótida, selecionando todos os pacientes com tumor primário de parótida atendidos no Departamento de Cirurgia de Cabeça e Pescoço e Otorrinolaringologia do Hospital A. C. Camargo de São Paulo, entre 1953 e 2003. Os pacientes já tratados previamente em outra instituição ou com falta de informações clínicas ou histológicas nos prontuários hospitalares foram excluídos deste estudo. Um total de 600 casos foram selecionados, sendo 369 benignos e 231 malignos. Dentre os tumores benignos o adenoma pleomorfo foi o mais comum, correspondendo a 66,5% dos casos seguido pelo Tumor de Warthin com 25%. Dos malignos o mais comum foi o carcinoma mucoepidermóide. Dezenove casos (3,16%) correspondiam a tumores mesenquimais não linfóides, sendo 15 benignos e 4 malignos. A principal modalidade de tratamento para os tumores de parótida, tanto benignos como malignos, foi a ressecção cirúrgica, incluindo parotidectomias parciais, totais ou ampliadas. Em alguns casos de tumores malignos, terapias adjuvantes, principalmente a radioterapia, foram aplicadas. Os índices de recorrência local, regional e à distância dos tumores malignos foram de 10%, 8% e 9%, respectivamente. A análise multivariada indicou que a invasão clínica da pele, disfunção do nervo facial e o crescimento perineural foram os fatores mais significativos para a sobrevida livre de doença dos pacientes com carcinomas de parótida. Testando dois *scores* de prognóstico previamente publicados por Vander Poorten et al. (1999) e Carrillo et al. (2007), observamos uma melhor distinção do grupo de pacientes com pior prognóstico, e o melhor *score* foi o apresentado por Carrillo.

Palavras-chave: Neoplasia, Glândulas Salivares

ABSTRACT

Salivary gland tumors are rare, with an annual incidence of about 0,4 to 13,5 cases per 100000 people. Most of the cases affect the parotid gland, representing 64% to 80% of the cases and the majority is benign. The aim of this study was to analyze the main clinical and histopathological features of parotid gland tumors. We select all the patients with primary parotid tumors referred to the Department of Head and Neck Surgery and Otorhinolaryngology from A. C. Camargo Hospital from 1953 to 2003. The patients previously treated at another institution or with incomplete histological or clinical information were excluded. A total of 600 cases were selected, being 369 benign and 231 malignant. Pleomorphic adenoma was the most frequent benign tumor, corresponding to 66,5% of the cases followed by Warthin tumor with 25%. From the malignant tumors, the most common was the mucoepidermoid carcinoma. Nineteen cases (3,16%) were nonlymphoid mesenchymal tumors, being 15 benign and 4 malignant. The main treatment modality for the parotid tumors was the partial, total or extended parotidectomy. In some malignant cases, adjuvant therapies, mainly radiotherapy, were applied. The incidence of local, regional and distant recurrences were 10%, 8% e 9%, respectively. The multivariate analysis indicated clinical skin invasion, facial nerve dysfunction and perineural growth as the most significant recurrent disease-related prognostic factors for patients with parotid carcinoma. Testing two prognostic scores previously published by Vander Poorten et al. (1999) and Carrillo et al. (2007), the group with worse prognosis can be well characterized using both scores, but the best prognostic score was the presented by Carrillo.

Key-words: Neoplasms, Salivary Glands

SUMÁRIO

INTRODUÇÃO.....	01
CAPÍTULO 1: <i>Neoplasias da glândula parótida: análise de 600 pacientes atendidos em uma única instituição</i>	03
CAPÍTULO 2: <i>Nonlymphoid mesenchymal tumors of the parotid gland</i>	17
CAPÍTULO 3: <i>Comparison of two prognostic scores for patients with parotid carcinoma</i>	32
CONCLUSÕES.....	49
REFERÊNCIAS.....	51

INTRODUÇÃO

As glândulas salivares são órgãos exócrinos responsáveis pela produção e excreção de saliva. Compreendem três pares de glândulas maiores (parótida, submandibular e sublingual) e as glândulas menores. A glândula parótida é a maior e principal glândula salivar.

As neoplasias de glândulas salivares são raras com incidência anual em torno de 0,4 a 13,5 casos por 100.000 pessoas (Ellis et al. 1991). A frequência de neoplasias malignas variam de 0,4 a 2,6 casos por 100.000 pessoas (Pinkston & Cole, 1999). As neoplasias de glândulas salivares correspondem a cerca de 2 a 6,5% de todos os tumores da região de cabeça e pescoço (Spiro, 1986; Abiose et al., 1990). O pico de incidência dos tumores de glândulas salivares ocorre entre a sexta e sétima décadas de vida com média de cerca de 46 anos (Eveson, 1985; Auclair et al., 1991).

Cerca de 64 a 80% de todos os tumores de glândulas salivares ocorrem na parótida, atingindo mais frequentemente o lobo superficial (Spiro, 1986; Eveson & Cawson, 1985; Ellis et al., 1991). Dentre os tumores da parótida a maioria é benigna, correspondendo a cerca de 70 a 85% dos casos (Eneroth, 1971; Auclair et al., 1991; Eveson, 1985).

Cerca de 95% dos tumores da glândula parótida são de origem epitelial, outros 5% correspondem a neoplasias mesenquimais não linfóides e linfomas (Auclair et al., 1991; Kang et al., 1999; Sethi et al., 2006). Os tumores mesenquimais não linfóides correspondem principalmente a hemangiomas, linfangiomas e lipomas (Luna et al., 1991). A classificação histológica dos tumores epiteliais de glândula salivar epiteliais é difícil devido à grande variação morfológica (Van der Wal et al., 1998).

O adenoma pleomorfo é o tipo histológico mais comum entre as neoplasias de glândula salivar, e correspondem a cerca de 80% de todos os tumores benignos da parótida (Renehan et al., 1996). O tumor de Warthin é o segundo tipo mais comum de tumor benigno da glândula parótida, sendo quase exclusivo desta glândula, representando cerca de 10% a 29% dos tumores benignos da parótida. O tumor maligno de glândula salivar mais comum é o carcinoma mucoepidermóide, acometendo preferencialmente a glândula parótida, seguida das glândulas salivares menores, submandibular e sublingual (McGurk et al., 2003; Guntinas-Lichius et al., 2004). O carcinoma adenóide cístico é o

segundo mais freqüente, sendo que na parótida deve-se considerar também o carcinoma de células acinares, adenocarcinoma SOE e o carcinoma ex-adenoma pleomorfo (Spiro, 1986).

O tratamento de escolha para os tumores de parótida, tanto benignos quanto malignos, é a parotidectomia parcial, total ou ampliada, de acordo com a extensão da lesão (Lima et al., 2005). Em casos malignos a radioterapia pode ser útil como tratamento adjuvante, enquanto que a quimioterapia é pouco utilizada (Yu et al., 1987; Bull, 1999). As taxas de recorrência local, regional e à distância dos tumores malignos variam em torno de 40%, 15% e 11% respectivamente, e estão relacionadas a um pior prognóstico (Yu et al., 1987).

Muitos estudos têm sido publicados na intenção de identificar fatores que influenciam o prognóstico de pacientes com carcinoma de parótida. Bhattacharyya & Fried (2005) estudando 903 pacientes relataram idade, tamanho do tumor, grau de malignidade, extensão extraglandular e metástase linfonodal como os principais fatores que influenciam o prognóstico através de modelo de Cox para sobrevida global. Gallo et al. (1997) estudando 124 pacientes com carcinoma de parótida, também utilizando o modelo de Cox, mostraram que o estadio clínico e a infiltração do nervo facial foram os fatores mais importantes para o risco de metástases a distância. De acordo com Hocwald et al. (2001), linfonodos metastáticos e invasão perineural foram os fatores independentes mais importantes na sobrevida livre de doença em pacientes com tumores malignos da parótida. Por outro lado, Harbo et al. (2002), avaliando 136 pacientes com carcinoma de parótida, encontraram estadio TNM, invasão local e diferenciação histológica como fatores independentes de prognóstico.

Os principais objetivos deste trabalho foram analisar as principais características clínicas e histológicas de todos os tumores primários da glândula parótida atendidos no Departamento de Cirurgia de Cabeça e Pescoço e Otorrinolaringologia do Hospital A. C. Camargo de São Paulo, de 1953 a 2003. Além disso, identificar os principais fatores relacionados ao prognóstico dos pacientes com carcinoma de parótida e a possível validação de dois *scores* de prognóstico previamente publicados na literatura.

CAPÍTULO 1 (Artigo aceito para publicação na Revista Brasileira de Otorrinolaringologia)

Neoplasias da glândula parótida: análise de 600 pacientes atendidos em uma única instituição

Parotid gland neoplasia: analysis of 600 patients attended in a single institution

Ademar TAKAHAMA JUNIOR

Oslei Paes de ALMEIDA

Luiz Paulo KOWALSKI

RESUMO

Introdução. Os tumores de glândula salivar são raros e acometem principalmente a parótida, sendo a maioria de natureza benigna.

Objetivo. Avaliar, através de estudo retrospectivo, todos os casos de tumor de parótida atendidos no Departamento de Cirurgia de Cabeça e Pescoço do Hospital A. C. Camargo de São Paulo, durante o período de 1953 a 2003.

Material e Método. Todos os pacientes com tumores primários de parótida foram selecionados e os dados clínicos e histopatológicos foram analisados e descritos.

Resultados. Foram selecionados 600 casos de tumores primários de parótida, sendo 369 benignos e 231 malignos. Dentre os tumores benignos o adenoma pleomorfo correspondeu a 66,5% e o Tumor de Warthin a 25%. Dos malignos o mais comum foi o carcinoma mucoepidermóide seguido pelo carcinoma indiferenciado. A principal modalidade de tratamento, tanto para os benignos quanto para os malignos foi a ressecção cirúrgica através da técnica da parotidectomia parcial ou total. Em alguns casos de tumores malignos, terapias adjuvantes, principalmente a radioterapia, foram aplicadas. Os índices de recorrência local, regional e à distância dos tumores malignos foram de 10%, 8% e 9%, respectivamente.

Conclusão. O perfil dos pacientes com tumor primário de parótida atendidos no Departamento de Cirurgia de Cabeça e Pescoço do Hospital A.C. Camargo de São Paulo é formado predominantemente por adultos, com idade média de 48 anos e discreta predileção pelo gênero feminino. Os tumores benignos foram mais frequentes,

destacando-se o adenoma pleomorfo. A maioria dos pacientes foram tratados por parotidectomia parcial ou total. O uso de terapias adjuvantes, principalmente a radioterapia, foi reservada para casos específicos de tumores malignos.

Descritores: neoplasia, glândula parótida, adenoma pleomorfo, carcinoma mucoepidermóide

Abstract

Introduction. The salivary gland tumors are rare and affect mainly the parotid, most of them benign.

Purpose. To analyze, in a retrospective study, all cases of parotid tumors referred to the A.C. Camargo Hospital, Department of Head and Neck Surgery, during the period of 1953 to 2003.

Methods. All patients with primary parotid tumor were selected and clinical and histopathological data were analyzed and described.

Results. 600 cases of parotid tumors were selected; 369 benign and 231 malignant. Pleomorphic adenoma followed by Warthin's tumor were the most frequent benign tumors. From the malignant tumors, the most common was mucoepidermoid carcinoma, followed by undifferentiated carcinoma. The main treatment modality, both for benign and malignant tumors, was surgical resection with partial or total parotidectomy. In some malignant tumors adjuvant therapies, mainly radiotherapy, were applied. The incidence of local, regional and distant recurrences for the malignant tumors were 10%, 8% e 9%, respectively.

Conclusion. Patients with parotid tumor treated at A.C. Camargo Hospital – São Paulo, Department of Head and Neck Surgery were mainly adults, with mean age of 48 years and with a discreet predilection for females. Benign tumors, most of them PA, were more frequent than malignancies. Most of the patients were treated by partial or total parotidectomy. Adjuvant therapies, mainly radiotherapy, were applied in selected malignant cases.

Descriptors – neoplasia, parotid gland, pleomorphic adenoma, mucoepidermoid carcinoma

Introdução

As neoplasias de glândulas salivares constituem um grupo raro de tumores, com incidência anual de 1 para 100.000 indivíduos, correspondendo a cerca de 3% de todas as neoplasias da região de cabeça e pescoço¹. A média de idade dos pacientes com tumor de glândula salivar é de 45 anos, com pico de incidência na sexta e sétima décadas de vida^{2,3}. Os tumores benignos de glândulas salivares são mais freqüentes em mulheres, enquanto que as neoplasias malignas mostram pequena predileção pelo gênero masculino^{4,5}.

A glândula salivar mais freqüentemente acometida com tumores é a parótida, com cerca de 70% dos casos^{4,5,6}. Aproximadamente 80% dos tumores de parótida são benignos, sendo que o adenoma pleomorfo é o mais comum, seguido do Tumor de Warthin, correspondendo a 65% e 10% respectivamente, de todas as neoplasias da parótida⁴.

O tumor maligno de glândula salivar mais comum é o carcinoma mucoepidermóide, acometendo preferencialmente a glândula parótida, seguida das glândulas salivares menores, submandibular e sublingual^{5,6,7}. O carcinoma adenóide cístico é o segundo mais freqüente, sendo que na parótida deve-se considerar também o carcinoma de células acinares, adenocarcinoma SOE e o carcinoma ex-adenoma pleomorfo¹.

O principal sintoma de pacientes com neoplasia de parótida é o aumento de volume da região. Nos casos malignos outros sintomas como dor, paralisia facial e ulceração da pele podem estar presentes^{8,9}. O tratamento de escolha para os tumores de parótida, tanto benignos quanto malignos, é a parotidectomia parcial ou total, de acordo com a extensão da lesão¹⁰. Em casos malignos a radioterapia pode ser útil como tratamento adjuvante, enquanto que a quimioterapia é pouco utilizada^{6,11,12}. As taxas de recorrência local, regional e à distância dos tumores malignos variam em torno de 40%, 15% e 11% respectivamente, e estão relacionadas a um pior prognóstico⁶. Neste artigo fazemos a

descrição das características clínicas e histológicas de 600 tumores de parótida tratados no Hospital A. C. Camargo de São Paulo.

Métodos

Para este estudo foram selecionados todos os casos de tumor primário de parótida atendidos no Departamento de Cirurgia de Cabeça e Pescoço do Hospital A. C. Camargo de 1953 até 2003. Os critérios de exclusão para o estudo incluiu a não localização ou falta de informação nos prontuários, não localização dos blocos de parafina e das lâminas, e pacientes previamente submetidos a tratamento em outro serviço. As informações clínicas dos pacientes foram coletadas através dos prontuários médicos. Foi realizada a revisão histológica de todos os casos segundo a classificação da Organização Mundial de Saúde¹³.

Resultados

Foram selecionados para o estudo 600 casos, todos com as informações necessárias para as análises. 369 casos (60%) foram classificados como benignos, e 231 (40%) como malignos. A média geral de idade foi de 48,4 anos. Houve discreta predominância do gênero feminino (53%).

Benignos:

Os tumores benignos mais freqüentes foram o adenoma pleomorfo e o Tumor de Warthin, representando 66,5% e 25% dos casos respectivamente. Outros tumores menos freqüentes foram o adenoma de células basais, oncocitoma e mioepitelioma. Quinze casos foram diagnosticados como tumores de origem mesenquimal, sendo 5 linfangiomas, 5 neurofibromas, e 1 caso de lipoma, schwannoma, tumor fibroso solitário, lesão de células gigantes e meningioma (Tabela 1).

A média de idade dos pacientes com tumores benignos foi de 47 anos, com pico de incidência na quinta década de vida (Figura 1). Houve pequena predominância do gênero feminino, representando 55% dos casos. Nos adenomas pleomorfos esse predomínio foi maior, com 62% dos casos, por outro lado, nos Tumores de Warthin 65,5% dos casos ocorreram no gênero masculino. O tempo médio de queixa dos

pacientes foi de 40 meses, e os principais sintomas relatados foram aumento de volume da região (98% dos casos) e dor (11% dos casos). O tamanho médio dos tumores foi de 4 cm, variando de 1 a 30cm. Dez pacientes apresentaram tumores bilateralmente, ou seja, atingindo as duas glândulas parótida, todos com diagnóstico de Tumor de Warthin. Todos os pacientes foram tratados cirurgicamente, sendo 330 casos (90%) por parotidectomia parcial e 38 (10%) por parotidectomia total. Em 365 casos houve preservação total do nervo facial, e em 3 casos houve sacrifício de algum ramo. A principal complicação após o tratamento cirúrgico foi a síndrome de Frey (34 casos – 9%). Paralisia facial foi constatada em 34 casos, sendo temporária em 28 e permanente em 6 casos. Dez casos apresentaram recidiva local, entre 18 e 112 meses (média de 56 meses), todos com diagnóstico de adenoma pleomorfo.

Malignos:

O tumor maligno mais comum foi o carcinoma mucoepidermóide, seguido pelo carcinoma indiferenciado, carcinoma adenóide cístico, adenocarcinoma SOE, carcinoma de células acinares, carcinoma ex-adenoma pleomorfo e carcinoma espinocelular. Vinte e quatro neoplasias malignas eram de origem não epitelial, destas 14 eram linfomas. A média de idade dos pacientes com tumores malignos foi de 50 anos, com pico de incidência na sexta década de vida (Figura 2). Houve discreta predileção pelo gênero masculino, com 52% dos casos. O tempo de queixa médio foi de 35 meses, e o principal sintoma foi o aumento de volume na região (220 casos – 91%). Dor foi relatada em 30% dos casos; paralisia facial em 10% e trismo em 6%. O diâmetro médio dos tumores foi de 5,5 cm, variando de 1 a 20 cm.

Segundo o estadiamento clínico TNM, 23 casos foram classificados como T1, 80 como T2, 58 como T3, 70 como T4. Linfonodos palpáveis foram detectados em 39 casos, sendo N1 em 21, N2 em 8 e N3 em 10 casos. Três casos foram classificados como M1, todos apresentando metástases para os pulmões.

A cirurgia foi a principal modalidade terapêutica, sendo que em 36,3% dos casos foi realizada a parotidectomia parcial, em 57% a parotidectomia total e em 6,7% a parotidectomia ampliada, com ressecção de estruturas adjacentes como músculo, mandíbula, pavilhão auricular e pele. O nervo facial foi preservado em 72% dos casos, ressecado parcialmente em 9% e sacrificado em 19% dos casos. Em 73 casos, além da

parotidectomia foi feito o esvaziamento cervical, sendo confirmado linfonodos metastáticos no exame histopatológico em 38 casos. A radioterapia pós-operatória foi realizada em 72 casos, sendo a dose média empregada de 4800 Gy. Vinte e um casos foram tratados paliativamente por radioterapia exclusiva, e 6 casos por associação de radioterapia e quimioterapia. Quarenta e oito pacientes (21%) apresentaram recorrências. A recorrência local foi observada em 25 casos (10%), sendo em 13 casos exclusiva, em 4 associada com a recorrência regional, em 5 com a metástase à distância e em 2 associada a recorrência tanto regional quanto à distância. A recorrência regional foi observada em 19 casos (8%), sendo em 10 casos exclusiva e em 3 associada a metástase a distância. A metástase à distância foi constatada em 21 casos (9%), sendo em 10 casos exclusiva. O principal órgão afetado pelas metástases à distância foi o pulmão (10 casos).

De acordo com as últimas informações obtidas, observamos que 90 pacientes morreram pela doença, 91 estavam vivos sem doença, 13 estavam vivos com doença, 22 foram a óbito por outras causas e 15 foram perdidos de seguimento.

Discussão

A glândula parótida representa o principal sítio de ocorrência de tumores de glândulas salivares^{2,8}. Cerca de 64 a 80% de todos os tumores epiteliais primários de glândulas salivares acometem a parótida, sendo a maioria localizada no lobo superficial¹⁴. Nosso estudo avaliou 600 casos de tumores primários benignos e malignos de parótida.

O pico de incidência dos tumores de glândula salivar ocorre na sexta e sétima décadas de vida, com média de idade de 46 anos³. Satko et al.¹⁵ descreveram média de idade de 53 anos, variando de 2 a 87. A maioria dos estudos mostram que para os tumores malignos a média de idade é maior (cerca de 55 anos) em relação aos benignos (cerca de 45 anos)^{2,8,16}. Os nossos resultados confirmam estes dados, pois encontramos média geral de idade de 48,4 anos, sendo de 47 anos para os tumores benignos e 50 para os malignos.

A maioria dos estudos de revisão de séries de tumores de glândulas salivares relatam predominância no gênero feminino, tanto para os benignos quanto para os malignos^{8,14,17}. No entanto, de acordo com o tipo de tumor existe uma variação na predominância do gênero, como por exemplo no Tumor de Warthin, que apresenta

predominância em homens². Ito et al.¹⁶ observaram predominância no gênero feminino para os tumores benignos (58,5%), enquanto que para os casos malignos a predominância foi em homens (52,2%). No nosso estudo também observamos discreta predominância geral no gênero feminino, com 53% dos casos, sendo 55% nos casos benignos. Entretanto, para os tumores malignos, encontramos predominância no gênero masculino, com 52% dos casos.

A principal queixa de pacientes com tumor na parótida é o aumento de volume da região. Aproximadamente 50% dos tumores malignos de parótida apresentam características clínicas de tumores benignos como crescimento lento, mobilidade em relação aos tecidos adjacentes e ausência de sintomatologia. Entretanto, os outros 50% apresentam características de malignidade como paralisia facial, dor, trismo e fixação aos tecidos adjacentes¹⁸. Em nossos casos a maioria dos pacientes com tumores benignos apresentou aumento de volume. Nos malignos, além do aumento de volume, 34% dos pacientes também apresentaram dor, paralisia facial e/ou trismo.

Está bem estabelecido que os tumores benignos mais freqüentes são adenoma pleomorfo e Tumor de Warthin^{3,16}. Os dados deste trabalho mostraram que adenoma pleomorfo e Tumor de Warthin corresponderam a 66,5% e 25% dos casos respectivamente. A porcentagem encontrada dos casos de Tumor de Warthin no nosso estudo é alta se comparada com outras séries de tumores de parótida, onde este número varia de 9% a 15%^{8,14,15,19}.

Os tumores malignos correspondem a cerca de 15 a 30% dos tumores de parótida, e o carcinoma mucoepidermóide tem sido relatado como o mais comum, seguido do carcinoma adenóide cístico^{1,8,16}. Interessante que de acordo com Wahlberg et al.²⁰, que revisaram 2062 casos de carcinoma de parótida, o carcinoma mucoepidermóide foi o mais freqüente, entretanto em ordem decrescente foi seguido do adenocarcinoma SOE, carcinoma de células acinares, carcinoma adenóide cístico, carcinoma ex-adenoma pleomorfo e carcinoma indiferenciado. Na nossa série de tumores malignos também observamos predominância do carcinoma mucoepidermóide, seguido do carcinoma indiferenciado, carcinoma adenóide cístico, adenocarcinoma SOE, carcinoma de células acinares e carcinoma ex-adenoma pleomorfo.

O tratamento de escolha para os tumores benignos da glândula parótida é a parotidectomia, com conservação do nervo facial²¹. Geralmente a parotidectomia parcial é realizada nos tumores de parótida confinados ao lobo superficial, quando é feita a ressecção completa deste lobo. A remoção do lobo inteiro da parótida visa a obtenção de margem cirúrgica adequada, e evitar o rompimento de cápsula, minimizando, o risco de recorrência²². A parotidectomia total para tumores benignos é restrita aos casos onde há acometimento do lobo profundo da parótida²³. Considera-se que a ruptura da cápsula durante a ressecção cirúrgica e margens microscópicas positivas podem levar a recorrências²⁴. Todos os nossos casos benignos foram tratados por parotidectomia, e apenas 10 casos apresentaram recorrência local. O tratamento de escolha para os tumores malignos de parótida também é a parotidectomia, podendo ser parcial ou total, e a preservação do nervo facial deve ser feita sempre que possível¹⁰. A radioterapia adjuvante tem provado ser efetiva para melhor controle local e melhora na sobrevida^{12,25}. As taxas de recorrência local, regional e à distância dos tumores malignos de parótida correspondem aproximadamente a 40%, 15% e 11% respectivamente, e estão relacionadas a um pior prognóstico^{6,26}. A maioria dos nossos pacientes com tumores malignos também foram tratados por parotidectomia, sendo em alguns casos associados a terapias adjuvantes. O índice de recorrência local foi de 10%, regional 8% e à distância 9%, valores menores que os considerados na maioria dos relatos internacionais.

Conclusões

Em resumo, na casuística de 600 casos de tumores de parótida os tumores benignos foram os mais freqüentes. O adenoma pleomorfo foi o tipo mais comum entre todos os tumores. Dentre os tumores malignos o mais freqüente foi o carcinoma mucoepidermóide. O tratamento principal foi a excisão cirúrgica e a radioterapia foi reservada para casos específicos de tumores malignos. Quarenta e oito pacientes apresentaram algum tipo de recorrência durante o acompanhamento, correspondendo a 21% dos casos.

Referências

1. Ellis GL, Auclair PL. Tumors of the salivary glands. 3rd ed. Armed Forces Institute of Pathology: Washington; 1996.
2. Eveson JW, Cawson RA. Salivary gland tumours. A review of 2410 cases with particular reference to histological types, site, age and sex distribution. *J Pathol.* 1985;146:51-8.
3. Auclair PL, Ellis GL, Gnepp DR, Wenig BN, Janey CG. Salivary gland neoplasms: general considerations. In: Ellis GL, Auclair PL, Gnepp DR, editors. *Surgical pathology of the salivary glands.* Philadelphia: WB Saunders; 1991.p.135-64.
4. Nagler RM, Laufer D. Tumors of the major and minor salivary glands: review of 25 years of experience. *Anticancer Res.* 1997;17:701-7.
5. Pinkston JA, Cole P. Incidence rates of salivary gland tumors: results from a population-based study. *Otolaryngol Head Neck Surg.* 1999;120:834-40.
6. Yu GY, Ma DQ. Carcinoma of the salivary gland: a clinicopathologic study of 405 cases. *Semin Surg Oncol.* 1987;3:240-4.
7. Pires FR, Almeida OP, de Araujo VC, Kowalski LP. Prognostic factors in head and neck mucoepidermoid carcinoma. *Arch Otolaryngol Head Neck Surg.* 2004;130:174-80.
8. Spiro RH. Salivary neoplasms: overview of a 35-year experience with 2,807 patients. *Head Neck Surg.* 1986;8:177-84.
9. Przewozny T, Stankiewicz C. Neoplasms of the parotid gland in northern Poland, 1991-2000: an epidemiologic study. *Eur Arch Otorhinolaringol.* 2004;261:369-75.
10. Lim YC, Lee SY, Kim K, Lee JS, Koo BS, Shin HA, et al. Conservative parotidectomy for the treatment of parotid cancers. *Oral Oncol.* 2005;41:1021-7.
11. Kessler A, Handler SD. Salivary gland neoplasms in children: a 10-year survey at the Children's Hospital of Philadelphia. *Int J Pediatr Otorhinolaryngol.* 1994;29:195-202.
12. Bull PD. Salivary gland neoplasia in childhood. *Int J Pediatr Otorhinolaryngol.* 1999;49:S235-8.

13. Eveson JW, Auclair P, Gnepp DR, et al. Tumors of the Salivary Glands. In: Barnes L, Eveson JW, Reichart P, Sidransky D, editors. Pathology and genetics of head and neck tumors. World Health Organization Classification of Tumors. Lyon: IARC Press; 2005.p.209-281.
14. Ellis GL, Auclair PL, Gnepp DR, editors. Surgical Pathology of the Salivary Glands. Philadelphia: WB Saunders; 1991.
15. Satko I, Stanko P, Longauerova I. Salivary gland tumours treated in the stomatological clinics in Bratislava. J Craniomaxillofac Surg. 2000;28:56-61.
16. Ito FA, Ito K, Vargas PA, Almeida OP, Lopes MA. Salivary gland tumors in a Brazilian population: a retrospective study of 496 cases. Int J Oral Maxillofac Surg. 2005;34:533-6.
17. Williams NP, Boyd DL, Choy L, Hanchard B. Salivary gland lesions: a Jamaican perspective. Wet Indian Med J. 2001;50:62-5.
18. Snow GB. Tumours of the parotid gland. Clin Otolaryngol. 1979; 4: 457–68.
19. Fitzpatrick PJ, Black KM. Salivary gland tumors. J Otolaryngol. 1985;14:296-300.
20. Wahlberg P, Anderson H, Biörklund A, Möller T, Perfekt R. Carcinoma of the parotid and submandibular glands – a study of survival in 2465 patients. Oral Oncol. 2002;38:706-13.
21. Leverstein H, van der Wal JE, Tiwari RM, van der Waal I, Snow GB. Surgical management of 246 previously untreated pleomorphic adenomas of the parotid gland. Br J Surg. 1997;84:399-403.
22. McGurk M, Thomas BL, Renehan AG. Extracapsular dissection for clinically benign parotid lumps: reduced morbidity without oncological compromise. Br J Cancer. 2003;89:1610–3.
23. Guntinas-Lichius O, Kick C, Klussmann JP, Jungehuelsing M, Stennert E. Pleomorphic adenoma of the parotid gland: a 13-year experience of consequent management by lateral or total parotidectomy. Eur Arch Otorhinolaryngol. 2004;261:143–6.
24. Carew JF, Spiro RH, Singh B, Shah JP. Treatment of recurrent pleomorphic adenomas of the parotid gland. Otol Head Neck Surg. 1999;121:539-42.

25. Spiro IJ, Wang CC, Montgomery WW. Carcinoma of the parotid gland. Analysis of treatment results and patterns of failure after combined surgery and radiation therapy. *Cancer*. 1993;71:2699–705.
26. Harbo G, Bundgaard T, Pedersen D, Sogaard H, Overgaard J. Prognostic indicators for malignant tumours of the parotid gland. *Clin Otolaryngol*. 2002;27:512-6.

Tabela 1. Distribuição de 369 tumores benignos de glândula parótida tratados no Hospital AC Camargo, de acordo com o tipo histológico.

Tipo Histológico	Número de Casos	Porcentagem
Adenoma Pleomorfo	245	66,5%
Tumor de Warthin	93	25%
Adenoma de Células Basais	10	3%
Oncocitoma	4	1%
Mioepitelioma	2	0,5%
Tumores Mesenquimais	15	4%
TOTAL	369	100%

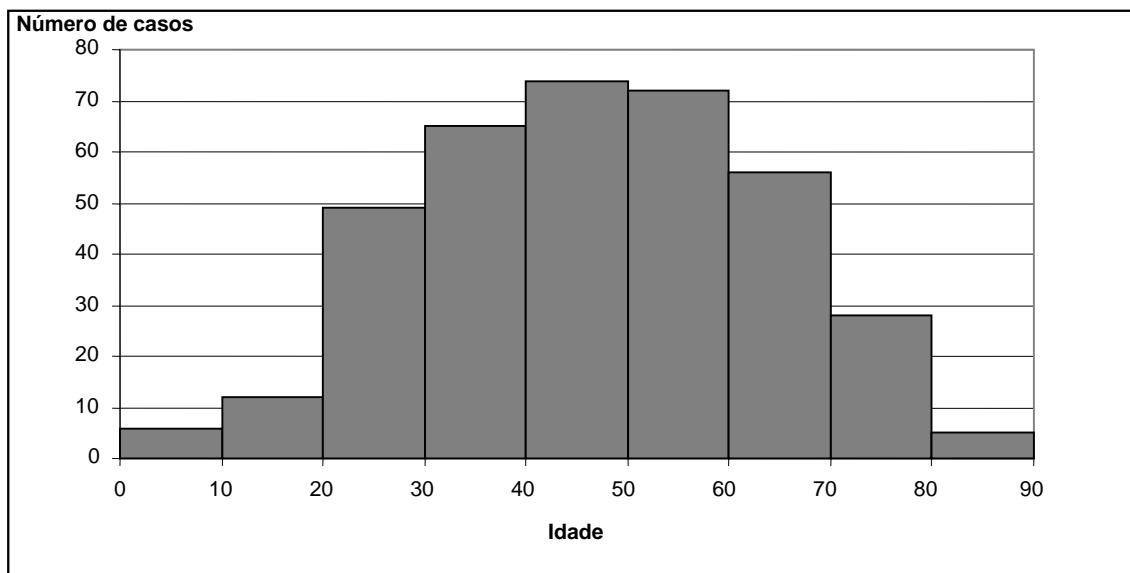


Figura 1. Distribuição de 369 tumores benignos de glândula parótida tratados no Hospital AC Camargo de acordo com a faixa etária.

Tabela 2. Distribuição de 231 tumores malignos de glândula parótida tratados no Hospital AC Camargo, de acordo com o tipo histológico.

Tipo Histológico	Número de Casos	Porcentagem
Carcinoma Mucoepidermóide	67	29%
Carcinoma Indiferenciado	33	13,5%
Carcinoma Adenóide Cístico	27	11%
Adenocarcinoma SOE	22	9%
Carcinoma de Células Acinares	20	8%
Carcinoma Ex Adenoma Pleomorfo	19	8%
Carcinoma Espinocelular	15	6%
Adenocarcinoma de Células Basais	5	3%
Carcinoma do Ducto Salivar	4	2%
Carcinoma Linfoepitelial	2	1%
Carcinoma Epitelial-Mioepitelial	1	0,5%
Carcinoma Oncocítico	1	0,5%
Carcinoma Mioepitelial	1	0,5%
Linfoma	14	6%
Tumor mesenquimal não linfóide	4	2%
TOTAL	231	100%

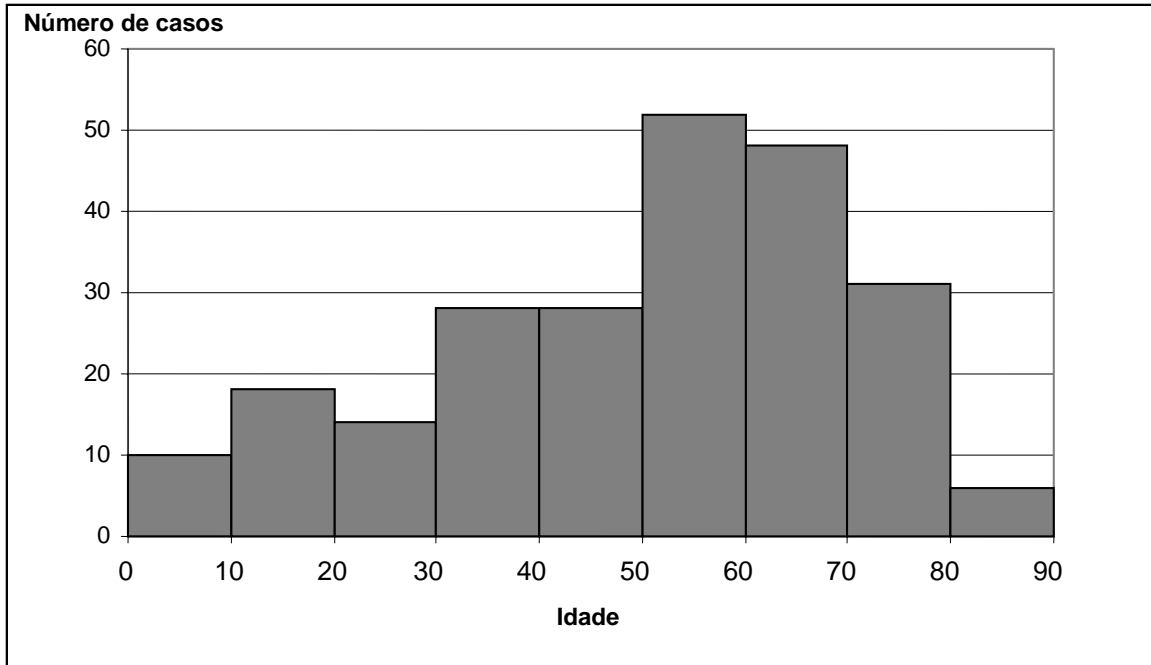


Figura 2. Distribuição de 231 tumores malignos de glândula parótida tratados no Hospital AC Camargo de acordo com a faixa etária.

CAPÍTULO 2 (Artigo publicado na *Oral Oncology*, 2008 Feb 15. [Epub ahead of print])

Nonlymphoid Mesenchymal Tumors of the Parotid Gland

Ademar Takahama Junior - DDS, MSc – ademartjr@yahoo.com.br

Jorge Esquiche León - DDS, MSc – jesquiche@yahoo.com.br

Oslei Paes de Almeida – DDS, PhD – oslei@fop.unicamp.br

Luiz Paulo Kowalski – MD, PhD – lp_kowalski@uol.com.br

Abstract

Salivary gland tumors are uncommon and most of them are of epithelial origin. Mesenchymal tumors affecting the parotid are extremely rare, and we present a series of 19 cases. All parotid tumors (600 cases) treated at the Department of Head and Neck Surgery from A.C. Camargo Hospital, Brazil from 1953 to 2003 were reviewed and 19 cases of nonlymphoid mesenchymal origin were selected. The histological characteristics were reviewed and clinical features were obtained from the medical charts. 15 out of 19 were benign tumors, including 5 lymphangiomas, 5 neurofibromas, and one case each of schwannoma, lipoma, solitary fibrous tumor, meningioma and giant cell tumor. Four malignant tumors were classified as rhabdomyosarcoma, fibrosarcoma, Langerhans cell histiocytosis and endodermal sinus tumor. From the malignant cases, only the patient with fibrosarcoma died due the tumor, the other 3 are alive with no signs of recurrence. In our series of 600 cases of parotid gland tumors, nonlymphoid mesenchymal tumors corresponded to 3.16% (19 cases; 15 benign and 4 malignant). All cases were treated by

surgery with no recurrences, except one case of fibrosarcoma whose patient died of distant metastasis.

Keywords – parotid gland, soft tissue neoplasms

Introduction

Salivary gland tumors are rare accounting for about 3% of all head and neck neoplasia. The parotid gland is the main site for these tumors, and about 95% of them are of epithelial origin.¹ Nonlymphoid mesenchymal tumors represent about 2 to 5 percent of all tumors of the parotid gland.^{2,3} Most of these tumors are benign, corresponding mainly to haemangiomas, lymphangiomas and lipomas.⁴ Schwannomas and neurofibromas also are relevant to be considered as they can originate from the facial nerve.²

Malignant mesenchymal tumors are rarely found in the major salivary glands, but almost any kind of sarcoma can arise primarily in the salivary glands.^{2,5-7} 80% of salivary glands sarcomas occur in the parotid gland, and a series of 11 cases, 3 were malignant fibrous histiocytomas, 2 neurosarcomas, 2 fibrosarcomas, 2 rhabdomyosarcomas and 2 osteosarcomas.⁸ The present study describes the clinical and histological characteristics of 19 cases of benign and malignant nonlymphoid mesenchymal neoplasms of the parotid gland.

Material and Methods

All patients with primary nonlymphoid mesenchymal tumors of the parotid gland, treated in the Department of Head and Neck Surgery of AC Camargo Hospital were included in this series. Clinical data were obtained from the hospital records and the

histopathological slides were reviewed. The tumors were considered primary of the parotid gland when the patient did not have a sarcoma in other site, patient evaluation excluded the possibility of metastatic disease and the gross and microscopic analysis excluded invasion from adjacent soft tissues. When necessary, immunohistochemistry was applied to confirm the diagnosis.

Results

Thirty three (5.3%) out of 600 cases of parotid gland tumors treated at the Department of Head and Neck Surgery from A.C. Camargo Hospital, São Paulo, Brazil, represented mesenchymal benign or malignant tumors. Fourteen cases of malignant lymphomas were not included in this study, and therefore a total of 19 cases were selected. (Figure 1)

Fifteen cases (76%) were classified as benign tumors, being 5 lymphangiomas, 5 neurofibromas, and one each of schwannoma, lipoma, solitary fibrous tumor, meningioma and giant cell tumor. The mean age was 25.1 years, being 12.4 and 20.8 for the patients with lymphangioma and neurofibroma respectively. There were 7 men and 8 women. The main complaint was local swelling and in one case of neurofibroma the patient also reported local pain. The mean diameter of the tumors was 4 cm. All cases were treated by surgical resection of the tumor, being partial parotidectomy in 8 cases and total parotidectomy in 7 cases. Facial nerve was resected in 3 cases, one each of neurofibroma, schwannoma and meningioma (table 1). No recurrences were found after a follow-up of 22 to 116 months (mean of 55.4 months). Immunohistochemistry was used

to confirm and better illustrate the cases of neurofibroma, schwannoma and solitary fibrous tumor.

Four cases (24%) were malignant, one case each of rhabdomyosarcoma, fibrosarcoma, Langerhans cells histiocytosis and endodermal sinus tumor. The mean age of the patients was 27.5 years, and two were male and two female (table 2). The main symptoms reported were of a parotid mass with fast growth and pain. The patient diagnosed with rhabdomyosarcoma was an 18-years-old man with a tumor in the right parotid region measuring about 4 cm. The patient was treated with radiotherapy and chemotherapy. After 16 years of follow-up the patient is alive without evidences of recurrence. The tumor was formed mainly by round cells and immunohistochemical analysis showed positivity for vimentin, desmin, MyoD1 and myogenin.

The patient with fibrosarcoma was an 88-year-old woman complaining of a painful large mass, measuring about 7 cm, in the right parotid region. The patient was treated with total parotidectomy with sacrifice of the facial nerve, but died after 3 months by lung metastasis. Histological examination revealed spindle cells arranged in fascicles, showing prominent pleomorphism and mitotic figures. In the immunohistochemical analysis the tumors cells were positive only for vimentin, and negative for AE1/3, desmin, S-100 and smooth-muscle actin.

The patient with Langerhans cell histiocytosis was a 3-year-old boy with a painfull swelling in the left parotid region for about 6 months. CT scan showed a large mass involving all the left parotid gland. The patient was treated by total parotidectomy with preservation of the facial nerve. On the histopathological and immunohistochemical analysis the diagnosis of Langerhans cell histiocytosis was established with the tumor

cells being positive for S-100, DND-53 and CD1a. Three months after surgery it was detected by CT recurrence in the temporal bone extending to the orbit. The patient was then treated with 8 cycles of vinblastine, and after 14 years of follow-up the patient is well and free of the disease.

The endodermal sinus tumor (previously reported by SREDNI et al.⁹), affected a 16-months-old girl with a fast growing parotid tumor. The patient was treated by surgical resection and the diagnosis was established by immunohistochemical positiveness for AE1/AE3, vimentin, alpha-fetoprotein and placental alkaline phosphatase. The patient received adjuvant chemotherapy and brachithrapy and no signs of recurrence were found after 5 years of follow-up.

Most of the benign tumors were localized and encapsulated, not invading the glandular tissue, only in the cases of lymphangiomas the tumor cells arose diffusely through the gland. All the four malignant cases invaded the glandular tissue, some of them destructing the acinar and ductal components.

Discussion

Excluding haematopoietic neoplasms, mesenchymal tumors represent 1.9-4.7% of all salivary gland tumors. Most are benign, and 85% involve the parotid.¹⁰ Our series presented 19 cases of nonlymphoid mesenchymal tumors, corresponding to 2.8% of all patients with parotid tumors treated at our institution.

The most frequent mesenchymal neoplasms of the salivary glands are vascular, mainly haemangiomas and lymphangiomas, accounting for about 40% of the cases.^{2,4} Neurofibroma and Schwannoma are the most common neural tumors reported.² Among

the fibroblastic and myofibroblastic benign tumors there are case reports of nodular faciitis, fibromatosis, haemangiopericytoma and solitary fibrous tumor.^{10,11} Lipomas, granular cell tumor, angiomyoma, glomangioma, myxoma, fibrous histiocytoma, giant cell tumor, osteochondroma were also seen in the salivary glands.¹⁰ Seifert & Oehne¹² reported 106 cases of benign mesenchymal tumors of the salivary glands, and 45% of the cases represented angiomas (haemangiomas and lymphangiomas), 22.5% lipomas and 16% were neurogenic (schwannomas and neurofibromas). In our series the most common types of benign mesenchymal tumors were lymphangioma and neurofibroma, with 5 cases each. There are about 20 cases of haemangiomas of the parotid region registered in our hospital; however, they were not included in the present series because we selected only the cases treated at the Department of Head and Neck Surgery, and with histopathological diagnosis. We also reported one case each of lipoma, schwannoma, solitary fibrous tumor, giant cell tumor and meningioma. Giant cell tumor has been rarely reported in the parotid gland, as well as solitary fibrous tumor.¹³⁻¹⁷ There are about 60 intraparotid schwannomas described in the literature, frequently presenting as an asymptomatic slow-growing mass.¹⁸ Extracranial meningiomas are extremely rare; Nichols et al.¹⁹ and Shetty et al.²⁰ reported cases involving the parotid gland region. It is considered that extracranial meningiomas originate from arachnoid cells rests of cranial nerve sheaths.²¹

Salivary gland sarcomas are rare, corresponding to only 0.3% of all salivary gland neoplasms.³ Almost any kind of sarcomas can arise primarily in the salivary glands, and usually they affect an older population than the benign tumors. Clinically, parotid sarcomas present as a painful and fast growing nodule or swelling, sometimes with facial

paralysis.²² In our cases swelling and pain were the main complaints. Auclair et al.²³ described 67 cases of sarcomas and sarcomatoid neoplasms of the salivary gland, 59 of them in the parotid gland, and the most common were malignant schwannoma and fibrosarcoma. Luna et al.⁸ reported 11 cases of parotid sarcomas classified as malignant fibrous histiocytoma, neurosarcoma, rhabdomyosarcoma, fibrosarcoma and osteosarcoma. In our series there were only 4 cases of malignant mesenchymal tumors, representing 0.66% and 1,6% of all parotid tumors and parotid malignancies respectively. There were one case each of rhabdomyosarcoma, fibrosarcoma, Langerhans cell histiocytosis and endodermal sinus tumor.

Langerhans cell histiocytosis of the parotid gland has been rarely reported in the English literature, and to our knowledge our case is the fourth and the second in a child. Darvishian et al.²⁴ reported one case in a 34-year-old Korean male treated by parotidectomy and chemotherapy. Iqbal et al.²⁵ and Kojima et al.²⁶ described cases of Langerhans cell histiocytosis involving bilaterally the parotid gland, the first one in an 18-month-old boy and the second in an 81-year-old woman.

The case of endodermal sinus tumor, previously reported by Sredni et al.⁹, was the second case reported in the literature.²⁷ The endodermal sinus tumor is a germ cell neoplasm that usually involves the gonads and is very rare in the extragonadal sites. The main extragonadal sites reported are the mediastinum, vagina, brain and retroperitoneum.²⁸

Different from the epithelial malignancies of the parotid, and similarly to sarcomas of other parts of the body, sarcomas of the parotid frequently develop distant metastasis. Seven out of 11 patients with parotid sarcomas reported by Luna et al.⁸,

developed distant metastasis. They also showed that prognosis is related to tumor size, histological type and grade. Follow-up data of 42 patients with sarcomas of the parotid gland revealed 17 local recurrences, 16 metastases, and 15 patients died of the disease.²³ In our series, the patient with parotid fibrosarcoma was the only one who died due the disease, after lung metastasis. The other 3 patients were alive without signs of tumor activity or recurrences.

Nonlymphoid mesenchymal tumors of the parotid gland are extremely rare, but they must be considered in the differential diagnosis. Vascular tumors are the most common among the benigns, and the malignants are quite variable. Although surgery is the main form of treatment, radiotherapy and chemotherapy are also used depending of the tumor characteristics. Different from the more common epithelial parotid tumors, sarcomas frequently need immunohistochemistry for final diagnosis. Distant metastases are common in sarcomas, while among the epithelial salivary malignancies this is not usual, but adenoid cystic carcinoma is a very important exception. It is also important to determine that the sarcoma is primary of the parotid, and therefore it is fundamental to rule out possibility of metastasis.

References

1. Auclair PL, Ellis GL, Gnepp DR, Wenig BN, Janey CG. Salivary gland neoplasms: general considerations. In: Ellis GL, Auclair PL, Gnepp DR, editors. Surgical pathology of the salivary glands. Philadelphia: WB Saunders, 1991. p. 135-164.
2. Ellis GL, Auclair PL, Gnepp DR, editors. Surgical Pathology of the Salivary Glands. Philadelphia: WB Saunders. 1991.
3. Cawson RA, Gleeson RJ, Eveson JW, editors. Pathology and Surgery of the Salivary Glands. Oxford: ISIS Medical Media. 1997.
4. Seifert G, Miehke A, Haubrich J, Chilla R, editors. Diseases of the Salivary Glands: Pathology – Diagnosis – Treatment – Facial Nerve Surgery. Stuttgart: Thieme Publishing Group. 1986.
5. Chandan VS, Fung EK, Woods CI, de la Roza G. Primary pleomorphic liposarcoma of the parotid gland: a case report and review of the literature. *Am J Otolaryngol* 2004;25(6):432-437.
6. Botev B, Casale M, Vincenzi B, D'Ascanio L, Santini D, Esposito V, et al. A giant sarcoma of the parotid gland: a case report and review of the literature. *In Vivo* 2006;20(6B):907-910.
7. Sethi A, Mrig S, Sethi D, Mandal AK, Agarwal AK. Parotid gland leiomyosarcoma in a child: An extremely unusual neoplasm. *Oral Surg Oral Med Oral Pathol Oral Radiol Endod* 2006;102(1):82-84.

8. Luna MA, Tortoledo E, Ordonez NG, Frankenthaler RA, Batsakis JG. Primary sarcomas of the major salivary glands. *Arch Otolaryngol Head Neck Surg*. 1991;117(3):302–306.
9. Sredni ST, Cunha IW, Carvalho-Filho NP, Magrin J, Pinto CAL, Lopes LF. Endodermal Sinus Tumor of the Parotid Gland in a Child. *Ped Dev Pathol* 2004;7(1):77-80.
10. Gnepp DR. Soft Tissue Tumors of the Salivary Gland. In: Barnes L, Eveson JW, Reichart P, Sidransky D, editors. Pathology and genetics of head and neck tumors. World Health Organization Classification of Tumors. Lyon: IARC Press, 2005. p. 209-281.
11. Guarino M, Giordano F, Pallotti F, Ponzi S. Solitary fibrous tumor of the submandibular gland. *Histopathology* 1998;32(6):571-573.
12. Seifert G, Oehne H. Mesenchymal (non-epithelial) salivary gland tumors. Analysis of 167 tumor cases of the salivary gland register. *Laryngol Rhinol Otol (Stuttg)* 1986;65(9):485-491.
13. Itoh Y, Taniguti Y, Arai K. A case of giant cell tumor of the parotid gland. *Ann Plast Surg* 1992;28(2):183-186.
14. Ferreiro JA, Nascimento AG. Solitary fibrous tumor of the major salivary glands. *Histopathology* 1996;28(3):261-264.
15. Guerra MF, Amat CG, Campo FR, Perez JS. Solitary fibrous tumor of the parotid gland: a case report. *Oral Surg Oral Med Oral Pathol Oral Radiol Endod* 2002;94(1):78-82.

16. Gerhard R, Fregnani ER, Falzoni R, Siqueira SA, Vargas PA. Cytologic features of solitary fibrous tumor of the parotid gland. A case report. *Acta Cytol* 2004;48(3):402-406.
17. Torabinejad S, Kumar PV, Hashemi SB, Rahimi A. Osteoclastomalike giant cell tumor of the parotid gland: report of a case with fine needle aspiration diagnosis. *Acta Cytol* 2006;50(1):80-83.
18. Caughey RJ, May M, Schaitkin BM. Intraparotid facial nerve schwannoma: diagnosis and management. *Otolaryngol Head Neck Surg* 2004;130(5):586-592.
19. Nichols RD, Knighton RS, Chason JL, Strong DD. Meningioma in the parotid region. *Laryngoscope* 1987;97(6):693-696.
20. Shetty C, Avinash KR, Auluck A, Mupparapu M. Extracranial meningioma of the parapharyngeal space: report of a case and review of the literature. *Dentomaxillofac Radiol* 2007;36(2):117-120.
21. Friedman CD, Costantino PD, Teitelbaum B, Berktold RE, Sisson Sr GA. Primary extracranial meningiomas of the head and neck. *Laryngoscope* 1990;100(1):41-48.
22. Auclair PL, Ellis GL. Nonlymphoid sarcomas of the major salivary glands. In: Ellis GL, Auclair PL, Gnepp DR, editors. *Surgical pathology of the salivary glands*. Philadelphia: WB Saunders, 1991. p. 514-527.
23. Auclair PL, Langloss JM, Weiss SW, Corio RL. Sarcomas and sarcomatoid neoplasms of the major salivary gland regions. A clinicopathologic and

immunohistochemical study of 67 cases and review of the literature. *Cancer* 1986;58(6):1305-1315.

24. Darvishian F, Hirawat S, Teichberg S, Wolk D, Allen SL, Hadju SI. Langerhans' cell histiocytosis in the parotid gland. *Ann Clin Lab Sci* 2002;32(2):201-206.
25. Iqbal Y, Al-Shaalan M, Al-Alola S, Afzal M, Al-Shehri S. Langerhans cell histiocytosis presenting as a painless bilateral swelling of the parotid glands. *J Pediatr Hematol Oncol* 2004;26(5):276-278.
26. Kojima M, Itoh H, Shimizu K, Matsuda H, Sakata N, Masawa N. Incidental Langerhans cell histiocytosis of the parotid gland resembling zone B-cell lymphoma: a case report. *J Oral Pathol Med* 2006;35(10):630-632.
27. Viva E, Zorzi F, Annibale G, Stefini S, Baronchelli C, Bonetti MF. Endodermal sinus (yolk sac) tumor of the parotid gland: a case report. *Int J Pediatr Otorhinolaryngol* 1992;24(3):269-274.
28. Oh C, Kendler A, Hernandez E. Ovarian endodermal sinus tumor in a postmenopausal woman. *Gynecol Oncol* 2001;82(2):392-394.

Table 1. Diagnosis and clinical characteristics of 15 patients with benign mesenchymal tumors of the parotid gland

Patient number	Diagnosis	Age (years)	Gender	tumor size (cm)	Treatment
1	Lymphangioma	1	M	4	TP/FP
2	Lymphangioma	5	F	6	PP/FP
3	Lymphangioma	9	F	4	TP/FP
4	Lymphangioma	10	M	4	TP/FP
5	Lymphangioma	37	M	3	PP/FP
6	Neurofibroma	3	F	4	PP/FP
7	Neurofibroma	8	F	3	PP/FP
8	Neurofibroma	26	M	2	TP/FP
9	Neurofibroma	30	F	3	TP/FS
10	Neurofibroma	37	M	4	PP/FP
11	Schwannoma	21	M	6	PP/FS
12	Lipoma	26	F	4	PP/FP
13	Solitary fibrous tumor	73	F	3	TP/FP
14	Giant cell tumor	31	M	4	PP/FP
15	Meningioma	60	F	7	TP/FS

TP= total parotidectomy; PP=partial parotidectomy; FP=facial nerve preserved; FS=facial nerve sacrificed

Table 2. Diagnosis and clinical characteristics of 4 patients with malignant mesenchymal tumors of the parotid gland

Patient number	Diagnosis	Age	Gender	Diameter of the tumor (cm)	Treatment	Outcome
1	Rhabdomyosarcoma	18	M	4	CT+RT	A/NED
2	Fibrosarcoma	88	F	4	TP/FS	DOD
3	Langerhans Cell Histiocytosis	3	M	2	TP/FP+CT	A/NED
4	Endodermal Sinus Tumor	1	F	5	TP/FP+CT+BT	A/NED

TP= total parotidectomy; PP=partial parotidectomy; FP=facial nerve preserved; FS=facial nerve sacrificed; CT=chemotherapy; RT=radiotherapy; A/NED=alive with no evidence of disease; DOD=died of disease.

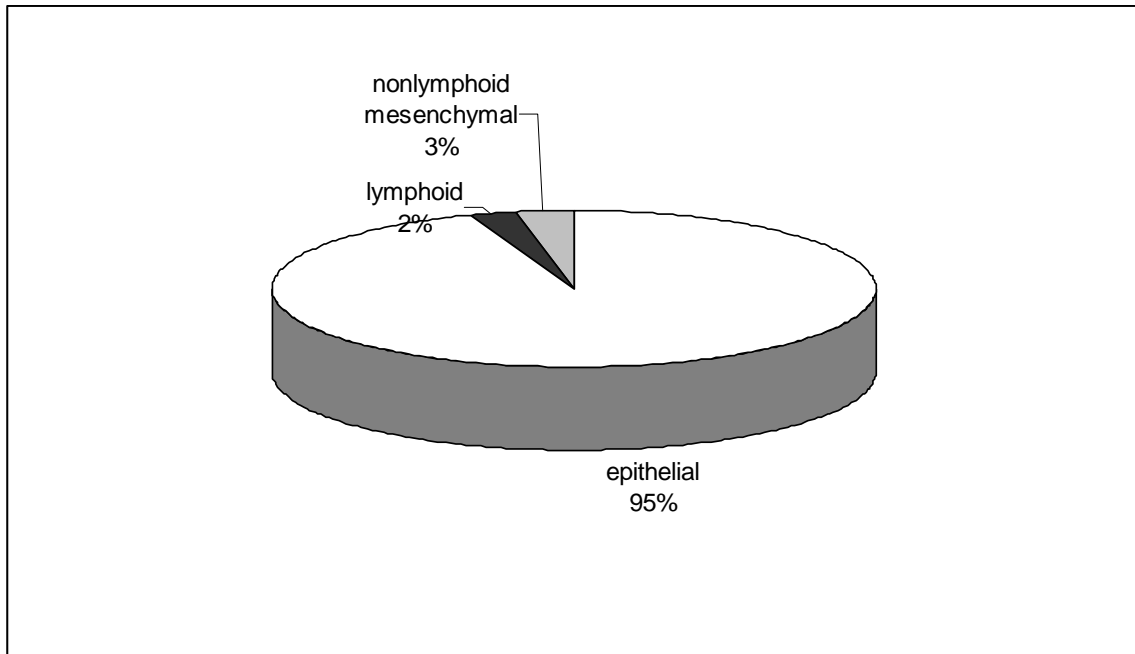


Figure 1. Distribution of 600 cases of parotid tumors treated at the Department of Head and Neck Surgery from A. C. Camargo Hospital according to the tissue of origin.

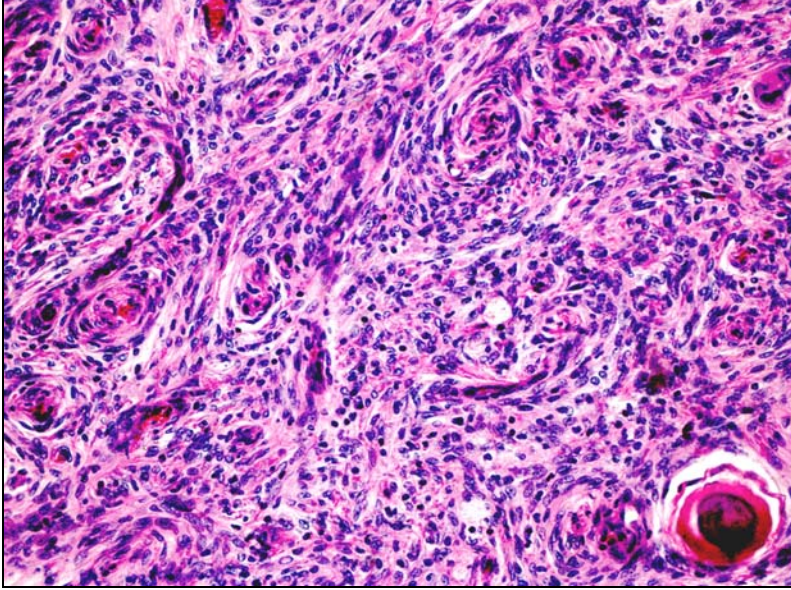


Figure 2. Parotid meningioma showing cells with whorl formation and a psammoma body. (Hematoxylin-eosin stain; original magnification x200)

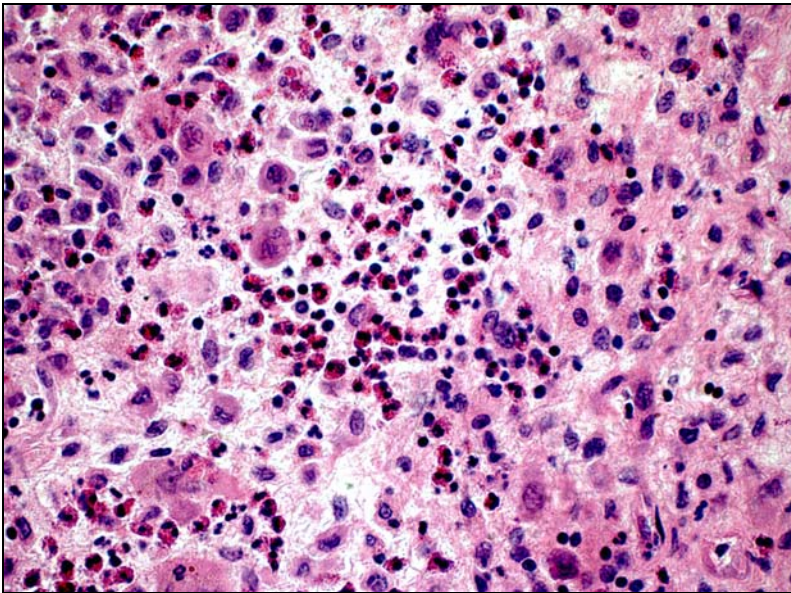


Figure 3. Langerhans Cell Histiocytosis showing typical neoplastic cells with grooved and folded nuclei and some eosinophils. (Hematoxylin-eosin stain; original magnification x400)

Comparison of two prognostic scores for patients with parotid carcinoma

Ademar Takahama Junior

Álvaro Sanabria

Gustavo Melo Benevides

Oslei Paes de Almeida

Luiz Paulo Kowalski

Abstract

BACKGROUND. Salivary glands present a wide diversity in histopathological types and biological behaviors, complicating the search for prognostic factors.

METHODS. We compared two prognostic scores previously published by Vander Poorten et al. (1999)¹ and Carrillo et al. (2007)² for patients with parotid carcinoma, in a retrospective series of 175 consecutive patients from A.C. Camargo Hospital, São Paulo, Brazil. Demographics and clinical data were collected from the medical charts and the histopathological slides were reviewed and classified according to 2005 version of World Health Organization.

RESULTS. Cox multivariate analysis indicated clinical skin invasion, facial nerve function and perineural growth as the most significant recurrent disease-related prognostic factors. On the follow-up, 24,6% of the patients experienced recurrences. The 5-year overall and disease-free survival rate was 73.5% (65.3%-80.0%) and 71.1% (62.7%-77.9%), respectively. According to the VANDER POORTEN score analysis, PS2 was calculated for 148 patients that were divided according to the recommended cutoff points: 43 patients with PS2=1; 47 with PS2=2; 7 with PS2=3 and 31 with PS2=4. The 5-year disease-free-survival for PS2 were respectively 76%, 81%, 69% and 35%. In the Carrillo's score, 8 patients (39%) were classified as 1-low-risk; 76 (43%) as 2-intermediate-risk and 31 (18%) as 3-high-risk and the 5-year disease-free survival rate were 84%, 73% and 34% respectively.

CONCLUSIONS. Although Carrillo's score showed more distinct survival curves, determination of groups with a more favorable prognosis was difficult for both

scores. On the other hand, the group with worse prognosis can be well characterized using both scores.

Condensed abstract

On this study we compared two prognostic scores for patients with parotid carcinoma using information about 175 patients from A. C. Camargo Hospital – Brazil. Carrillo's score showed more distinct survival curves and for both scores the group with worse prognosis were better characterized.

Introduction

Parotid carcinomas are rare, representing about 2% of all head and neck malignancies.³ Salivary glands present a wide diversity in histopathological types and biological behaviors, complicating the search for prognostic factors.^{4,5} Harbo et al. (2002)⁶, found TNM, local invasion and histological differentiation as independent prognostic predictors for malignant parotid tumor, while Hocwald et al. (2001)⁷ reported positive lymph nodes and perineural invasion as the most important factors.

Prognostic models are used to determine patient outcome, considering patient and disease characteristics, but they do not always work well in populations different from those where the index was developed. Therefore it is recommended its validation in different settings.⁸ Vander Poorten et al. (1999)¹ published the first prognostic model for patients with parotid carcinoma, performing a Cox proportional hazards regression analysis based on 151 parotid carcinoma patients from the Netherlands Cancer Institute. According to the results, they created a prognostic index defining four groups of patients according to the risk of recurrence. This prognostic index was successfully confirmed by the same author but with a different group of patients, using the Nationwide 1985-1994 Dutch Head and Neck Oncology Cooperative Group Database.⁵ Carrillo et al. (2007)² reported another prognostic score for patients with parotid carcinoma, where the logistic regression analysis showed that tumor size, facial nerve palsy, grade of differentiation, patient age and surgical margins were recurrence-associated factors. Based on this model they defined three (low, moderate and high) postoperative risk groups.

The aim of this study was to assess prognostic factors previously described in a different sample of patients with parotid carcinoma and to make an external validation of these two prognostic models.

Materials and Methods

This study was approved by the A.C. Camargo Hospital Committee of Ethics. Patients with primary parotid carcinoma treated with curative intent at the Department of Head and Neck Surgery and Otorhinolaryngology from A. C. Camargo Hospital, São Paulo, Brazil, from 1955 to 2003 were included on this study. During this period homogeneous treatment strategies for parotid cancer, partial or total parotidectomy with

or without facial nerve preservation, followed by radiotherapy in cases of bad prognosis predictors (perineural invasion, skin or facial nerve invasion, lymph node metastases, adverse histopathology, positive margins after surgery) were followed by surgeons. Inclusion criteria were the same reported by Vander Poorten et al. (1999)¹ and Carrillo et al. (2007)². Variables were collected from the medical charts, including demographic and clinical data, and used in the two prognostic score models previously mentioned. Patients without sufficient follow-up data, previously treated in another institution or with incomplete information on the medical charts were excluded. All histopathological slides were reviewed according to the World Health Organization classification (version 2005).

Outcomes were overall and disease-free survival. The first defined as time from the first treatment date to death by any cause or last objective information registered in the clinical chart and the latter as time from the first treatment date to date of recurrence, either loco-regional or systemic, or death by parotid tumor or last objective information registered in the clinical chart. All collected data entered in a database (Excel, Microsoft), and for the statistical analysis, commercially available software (Stata 8.0, Stata Corporation, Texas, USA) was used. Descriptive statistics were used to show the distribution of variables in the population. For the evaluation of prognostic factors defined by other indexes in our population, we conducted an univariate analysis (Kaplan–Meier method) exploring the relationship between the baseline variables and the outcome events. The log-rank test was used to define statistical significance. Continuous and discrete variables were categorized to facilitate data analysis and presentation. In cases of ordinal variables, an indicator variable was created for each level in order to use it in the Cox proportional hazard regression analysis. The Cox proportional hazard regression analysis was used to assess the independent effect of prognostic factors for overall and specific mortality. The selection of variables was made by using the results of univariate analysis and clinical criteria. A stepwise backward Cox regression was then used to prove the independent contribution of variables in the final model, using a $P = 0.2$ for entry into the model. After multivariate analysis, only variables with a $P < 0.05$ were considered associated with the outcome. For statistically significant variables, HR (hazard ratio) with a 95% IC was reported. For all statistical tests, $P < 0.05$ was considered statistically significant.

The prognostic score for each patient was calculated according to the previous models published by Vander Poorten et al. (1999)¹ and Carrillo et al. (2007)². The Vander Poorten score is divided in PS1 and PS2, where PS1 was calculated with the characteristics of the patients before surgery (age, pain on presentation, clinical T and N classification, skin invasion and facial nerve dysfunction). The PS2 included histopathological characteristics, like perineural invasion and surgical margins, calculated after surgery. We decided to use the PS2 model, considering that it includes information from the hystopathological report, which makes prediction more accurate. The formula to calculate PS2 is:

$$PS2 = 0.018 A + 0.39 T + 0.34 N + 0.70 S + 0.56 F + 0.78 PG + 0.65 PM$$

(*A* = age at diagnosis [years], *T* = clinical T classification [*T1* = 0, *T2* = 1, *T3* = 2, *T4* = 3], *N* = clinical N classification [*N0* = 0, *N1* = 1, *N2a* = 2, *N2b* = 3, *N2c* = 4, *N3* = 5], *S* = skin invasion [1 = no invasion, 2 = invasion], *F* = facial nerve dysfunction [1 = intact function, 2 = paresis-paralysis], *PG* = perineural growth in the resection specimen [1 = no, 2 = yes], *PM* = positive surgical margins [1 = no, 2 = yes]). A downloaded software to calculate PS1 and PS2 is available online (<http://www.uzleuven.be/parotid>).

According to the values found for PS2 the patients were divided into 4 groups where PS2 < 3.99 (PS2 = 1), PS2 = 3.99-4.80 (PS2 = 2), PS2 = 4.81-5.67 (PS2 = 3), and PS2 > 5.67 (PS2 = 4).

The Carrillo score considers clinical T classification, surgical margins, age and tumor differentiation, calculated as shown below, where Y represents the predicted probability for recurrence:

$$Y = \frac{1}{1 + e^{-[-3.31 + (0.452 * T3) + (2.264 * T4 \text{ without FP}) + (1.3 * \text{with FP}) + (1.6878 * \text{middle-age}) + (0.046 * \text{older age}) + (1.102 * \text{margin}) + (1 * \text{moderately or poorly differentiated}) + (2.766 * \text{undifferentiated})]}}$$

This calculation may also be performed with the help of a software downloaded online (<http://www.incan.edu.mx>). According to the value of Y, the patients are classified 3 groups, representing high, intermediate and low risk for recurrence.

For validation of the prognostic scores already described, we calculated the predicted survival for each patient using the mathematic models described by each author. With these values, we classified patients, as suggested, in different levels of risk, and we constructed a survival curve for each prognostic index, comparing with survival data obtained from the predicted values.

Results

Considering the criteria of exclusion, from the 231 patients with parotid carcinoma treated at our institution, 175 were selected for this study. Age ranged from 2 to 91 years (mean of 49), and 91 were male (52%) and 84 female (48%). Pain was reported by 49 patients (28%). Eighteen cases had clinical invasion of the skin (10,3%). Nineteen patients (11%) reported some grade of paresis or paralysis of the facial nerve on the first visit. According to the TNM classification 22 patients (12.57%) were T1, 66 (37.71%) T2, 41 (23.43%) T3 and 46 (26.29%) T4. 149 patients (85.14%) were classified as N0, 15 (8.57%) as N1, 5 (2.86%) as N2a, 5 (2.86%) as N2b and 1 (0.57%) as N3. None patient presented distant metastasis at admission.

The histopathological analysis showed a predominance of mucoepidermoid carcinoma with 57 cases (32,5%), followed by undifferentiated carcinoma (25 patients; 14,3%), adenoid cystic carcinoma (22 patients; 12,5%), carcinoma ex pleomorphic adenoma (17 patients; 9.71%), adenocarcinoma NOS (16 patients; 9.14%) and acinic cell carcinoma (16 patients; 9.14%). Fifty cases presented perineural invasion (28,5%) and 18 cases (10,3%) showed positive surgical margins.

163 cases were treated by surgery, 63 by superficial parotidectomy, 90 by total parotidectomy, of these 50 and 40 with and without conservation of the facial nerve, respectively. 84 patients (48%) were treated only by surgery, 79 (45%) with surgery and radiotherapy, 10 (6%) exclusively with radiotherapy, one case each (0,5%) with chemotherapy only or radiotherapy plus chemotherapy. Isolated radiotherapy, chemotherapy or the combination of these two modalities were applied in patients with inoperable disease because of local extension or systemic contraindication, or because of patient's choice.

On the follow-up, 43 patients (24,6%) experienced recurrences, including 24 (13,7%) with local, 18 (10,3%) with regional and 17 (9,7%) with distant recurrences. Six patients had both local and regional recurrences, other six patients had local and distant recurrences, 2 had simultaneous regional and distant recurrences and another 2 had simultaneous local, regional and distant recurrences. The 5-year overall and disease-free survival rate was 73.5% (65.3%-80.0%) and 71.1% (62.7%-77.9%), respectively. The multivariate analysis showed that clinical skin invasion, facial nerve function and perineural growth were the most significant recurrent disease-related prognostic factors (table 1).

According to the Vander Poorten score analysis, PS2 was calculated for 148 patients that were divided according to the recommended cutoff points: 43 patients with PS2=1; 47 with PS2=2; 7 with PS2=3 and 31 with PS2=4. The 5-year disease-free-survival for PS2 were respectively 76%, 81%, 69% and 35% (Figure 1a). In the Carrillo score, 68 patients (39%) were classified as 1-low-risk; 76 (43%) as 2-intermediate-risk and 31 (18%) as 3-high-risk and the 5-year disease-free survival rate were 84%, 73% and 34% respectively (Figure 1b).

Table 2 shows the distribution of demographic and clinical variables between the different populations used to develop and validate the Vander Poorten and Carrillo scores. (Table 2)

Discussion

Several studies have been performed to identify prognostic factors for patients with parotid carcinoma. Bhattacharyya and Fried (2005)⁹ studying 903 patients reported age, tumor size, grade, extraglandular extension and nodal positivity as the main factors influencing survival in the Cox model for overall survival. Gallo et al. (1997)¹⁰ studying 124 patients with parotid carcinoma, using a multivariate Cox proportional hazards analysis, showed that clinical stage and facial nerve infiltration were the most important factors in predicting the risk of distant metastasis. According to Hocwald et al. (2001)⁷ positive lymph nodes and perineural invasion are important independent predictors of disease-free survival in patients with malignant parotid tumor. On the other hand, Harbo et al. (2002)⁶ studying 136 patients with parotid carcinoma, found TNM, local invasion

and histological differentiation as independent prognostic predictors. In our series, using the multivariate Cox regression model for disease-free survival, clinical skin invasion, facial nerve function and perineural growth were the most significant prognostic factors. North et al. (1990)¹¹ also reported skin invasion and facial nerve impairment as predictors of either poor survival and local control. Perineural growth has also been reported as predictor of poor survival and distant recurrence.^{10,12}

Prognostic models are widely used in cancer and other diseases to determine patient outcome considering patient and disease characteristics. The main reasons to construct such models are to inform treatment modalities and other clinical decisions for patients and their families, and to stratify patients by disease severity in clinical trials. Authors tend to confirm the validity of their own models, but usually others are less successful in doing so.⁸ Vander Poorten et al. (1999)¹ reported the first prognostic score for patients with parotid carcinoma. This score was based on 151 patients, and it considered relevant factors to predict tumor recurrence. The final analysis resulted in two scores, one for pretreatment and another for post-treatment factors. These same authors reported an external validation of their score in another group of patients.⁵ Carrillo et al. (2007)² reported another prognostic score for patients with parotid carcinoma, where the main prognostic factors were tumor size, age of the patient, surgical margin and tumor grade. According to this score, patients were classified in three categories: low, intermediate and high risk of recurrence. Both authors let available online the necessary software for other authors to test the efficiency of their scores. When validating the prognostic scores with our sample of patients with parotid carcinoma, we found that these scores didn't have the same results as those originally reported. The discriminative ability was not as good as previously described, especially for Vander Poorten score. These findings can be explained by differences in population used to develop the scores, and this difficult in confirming the validation of scores is not unusual in the literature.

Comparing our group of patients with those of Vander Poorten (1999, 2003)^{1,5}, the distribution of sex, type of surgery, skin invasion, perineural growth and facial nerve dysfunction were similar. Nevertheless, we had a larger proportion of younger patients, 29% X 13% < 40 years-old in ours and Vander Poorten series respectively. More important, our group had more T4 patients than Vander Poorten's (26.3% vs 9%).

Therefore, the higher proportion of T1-2 tumors in Vander Poorten's series can explain the better prognosis of their low risk patients. The number of cases with positive margins was greater in Vander Poorten's than in our series (64% vs 11%), and this may explain that the majority of patients were treated by combination of surgery and radiotherapy in his series (82% vs 45%). Although we had a greater proportion of T4 tumors, we had a lower frequency of positive margins. Also, our group showed less local recurrence, helping to explain the differences obtained with the prognostic index. In fact, the most important difference occurred in the histopathological classification. In our group mucoepidermoid carcinoma prevalence, in terms of percentage, was almost double than in Vander Poorten's (32% vs 15%), and undifferentiated carcinoma was also more common (14% vs 9%).

Loco-regional and distant recurrences are very important factors for prognosis. Considering all types of recurrences in both Vander Poorten's series (1999 and 2003)^{1,5} the values were similar, 34% and 35% respectively. Distant metastases, associated or not with loco/regional metastases, also were similar corresponding to 68.4% and 74% respectively. In our series 43 patients (24,6%) experienced recurrences, the majority were loco/regional (90.3%) and only 9.7% were distant metastases. These differences explain that the 5-year-disease-free survival in our series (71.1%) was also higher when compared to Vander Poorten's 1999¹ and 2003⁵ groups, 64% and 59% respectively. Distant metastasis can be related to various factors, as histological type, age, T stage, positive margins after initial surgery and radiotherapy.

In comparison, Carrilo's group (2007)² was more similar to ours. The main differences were a higher proportion of advanced cases in their series (74% T3-4 vs 50% and 39% N+ vs 15%); more dysfunction of facial nerve (30% vs 11%); less superficial parotidectomies (13% vs 36%); greater number of positive margins (46% vs 11%), and a higher frequency of radiotherapy associated to primary surgery (82% vs 45%). Carrillo (2007)² also reported a greater number of patients with recurrences, 53 (41.7%), being 28 local or loco/regional and 26 with distant metastases (49%). In general, Carrilo's group showed more aggressive tumors than ours, when first treated and in terms of total and distant recurrences.

The results of Vander Poorten's score showed that PS2 data, considering discrimination among the first three groups (1, 2 and 3) was not good. Only for the group 4, with the worst prognosis, the curve was evidently discriminated. The Carrillo's score showed a better distinction among the groups, however with very close values for the groups with low and intermediate risk. Again, the group with high risk was better discriminated from the others. A new classification using only two risk levels (low and high), joining levels 1 and 2 for low risk and levels 3 and 4 for high risk in the Vander Poorten's score, or levels 1 and 2 in the low risk for the Carrillo's score, could offer a better prognostic discrimination, as shown in figures 2a and 2b.

In conclusion, according to our results, Carrillo's score better defined the prognostic groups for our patients. Both scores (Carrillo and Vander Poorten) clearly discriminate the group with worst prognosis for parotid carcinoma. We suggest that the use of only two groups, low and high risk, can make these prognostic scores for parotid carcinoma more useful and would be easier reproducible.

References

1. Vander Poorten VLM, Balm AJM, Hilgers FJM, et al. The development of a prognostic score for patients with parotid carcinoma. *Cancer*. 1999;85:2057-2067.
2. Carrillo JF, Vazquez R, Ramirez-Ortega MC, Cano A, Ochoa-Carrillo FJ, Onate-Ocana LF. Multivariate prediction of the probability of recurrence in patients with carcinoma of the parotid gland. *Cancer*. 2007;109:2043-2051.
3. Lima RA, Tavares MR, Dias FL, et al. Clinical prognostic factors in malignant parotid gland tumors. *Otolaryngol Head Neck Surg*. 2005;133:702-708.
4. Wahlberg P, Anderson H, Bjorklund A, et al. Carcinoma of the parotid and submandibular glands – a study of survival in 2465 patients. *Oral Oncol*. 2002;38:706-713.
5. Vander Poorten VLM, Hart AAM, van der Laan BFAM, et al. Prognostic index for patients with parotid carcinoma: external validation using the nationwide 1985-1994 Dutch Head and Neck Oncology Cooperative Group database. *Cancer*. 2003;97:1453-1463.
6. Harbo G, Bundgaard T, Pedersen D, et al. Prognostic indicators for malignant tumors of the parotid gland. *Clin Otolaryngol*. 2002;27:512-516.
7. Hocwald E, Korkmaz H, Yoo GH, et al. Prognostic factors in major salivary gland cancer. *Laryngoscope*. 2001;111:1434-1439.
8. Altman DG, Royston P. What do you mean by validating a prognostic model? *Statist Med* 2000;19:453-473.
9. Bhattacharyya N, Fried MP. Determinants of survival in parotid gland carcinoma: a population-based study. *Am J Otolaryngol* 2005;26:39-44.
10. Gallo O, Franchi A, Bottai GV, Fini-Storchi I, Tesi G, Boddi V. Risk factors for distant metastases from carcinoma of the parotid gland. *Cancer* 1997;80:844-851.
11. North CA, Lee D, Piantadosi S, Zahurak M, Johns ME. Carcinoma of the major salivary glands treated by surgery or surgery plus postoperative radiotherapy. *Int J Radiat Oncol Biol Phys* 1990;18:1319-1326.
12. Frankenthaler RA, Luna MA, Lee SS, Ang KK, Byers RM, Guillaumondegui OM, et al. Prognostic variables in parotid gland cancer. *Arch Otolaryngol Head Neck Surg* 1991;117:1251-1256.

Table 1. Factors associated with high risk for recurrence after Cox multivariate survival analysis

Factor	Haz Ratio	[95% Conf. Interval]	
Clinical skin invasion	5.00	2.33	10.70
Perineural growth	1.88	0.99	3.56
Facial nerve dysfunction	1.96	0.85	4.49

Table 2. Differences between populations used to develop and validate prognostic scores for parotid carcinoma

Variable	Vander Poorten et al. 1999	Vander Poorten et al. 2003	Carrillo et al. 2007	A.C. Camargo
Age		<40 30 13% 40-70 119 52% >70 82 35%	≤29 25 20% 30-55 41 32% ≥56 61 48%	<40 51 29.1% 40-70 101 57.7% >70 23 13.2% <29 31 17.7% 30-55 68 38.9% >55 76 43.4%
Sex	Male 89 53% Female 79 47%	Male 126 55% Female 105 45%	Male 63 49.6% Female 64 50.4%	Male 91 52% Female 84 48%
Histological classification	Adenocarcinoma 45 33% Acinic cell 27 20% Adenoid cystic 18 13% Mucoepidermoid 14 10% Undifferentiated 14 10% Squamous cell 9 7% Ex pleomorphic adenoma 8 6%	Adenoid cystic 36 16% Acinic cell 33 15% Mucoepidermoid 32 14.5% Ex pleomorphic adenoma 24 11% Undifferentiated 20 9% Adenocarcinoma 18 8% Squamous cell 17 8% Salivary duct 10 4.5% Epithelial-myoepithelial 7 3% Papillary 5 2% cystadenocarcinoma Polymorphous low-grade 3 1% Oncocytic 2 1% Myoepithelial 1 0.5% Mucinous 1 0.5% Other carcinomas 6 3% Cytology only 6 3%	Mucoepidermoid 44 34% Adenoid cystic 20 16% Adenocarcinoma 18 14% Acinic cell 12 9% Squamous cell 11 9% Undifferentiated 11 9% Ex pleomorphic adenoma 6 5% Myoepithelial 5 4%	Mucoepidermoid 57 32.6% Undifferentiated 25 14.3% Adenoid cystic 22 12.6% Ex pleomorphic adenoma 17 9.7% Adenocarcinoma 16 9.1% Acinic cell 16 9.1% Squamous cell 11 6.3% Basal cell 4 2.3% Salivary duct 3 1.7% Myoepithelial 2 1.1% Epithelial-myoepithelial 1 0.6% Oncocytic 1 0.6%

T	T1 27 16% T2 52 31% T3 29 17% T4 32 19% missing 28 17%	T1 35 19% T2 85 46% T3 47 26% T4 17 9%	T1 or T2 33 26% T3 46 36% T4 48 38%	T1 22 12.6% T2 66 37.7% T3 41 23.4% T4 46 26.3%
N	N0 131 78% N1 8 5% N2-N3 27 16% N missing 2 1%	N0 193 85% N1 9 4% N2a 7 3% N2b 15 7% N3 3 1%	N0 77 61% N1, N2 or N3 50 39%	N0 149 85.1% N1 15 8.5% N2a 5 2.9% N2b 5 2.9% N3 1 0.6%
Facial nerve dysfunction		intact 186 81% paresis-paralysis 45 19%	intact 89 70% paresis-paralysis 38 30%	intact 156 89% paresis-paralysis 19 11%
Neck dissection			No 73 57% Yes 54 43%	no 95 54.3% radical nd 45 25.7% mod nd 2 1.1% functional 1 0.6% sohd 20 11.4% n.a. 12 6.9%
Type of surgery		Local excision 15 6% superficial parotidectomy 63 27% total parotidectomy cons vii 88 38% total parotidectomy sac vii 51 22% debulking 2 1% No surgery 12 5%	Superficial parotidectomy 15 13% Total parotidectomy 97 87%	local excision 2 1.1% superficial parotidectomy 63 36% total parotidectomy cons vii 50 28.6% total parotidectomy sac vii 40 22.9% vii static recons 3 1.7% n.a. 12 6.9% debulking 5 2.8%

Positive margins		No 71 31% Yes 148 64% n.a. 12 5%	Negative 69 54% Positive 58 46%	No 130 74.3% Yes 19 10.9% n.a. 26 14.8%
Treatment modality		Surgery 29 13% Surgery + rt 190 82% Rt 11 4.5% Rt + Qt 1 0.5%	Surgery 8 6.29% Surgery + rt 104 82% Rt 15 11.81%	surgery 84 48% surgery+rt 79 45.1% rt 10 5.7% ct 1 0.6% ct+rt 1 0.6%
Perineural growth		no 159 69% yes 60 26% n.a. 12 5%		no 125 71.4% yes 50 28.6%
Skin invasion		no 211 91% yes 20 9%		no 157 89.7% yes 18 10.3%

Figure 1a. Five year disease-free survival curves by PS2 based on the Vander Poorten score.

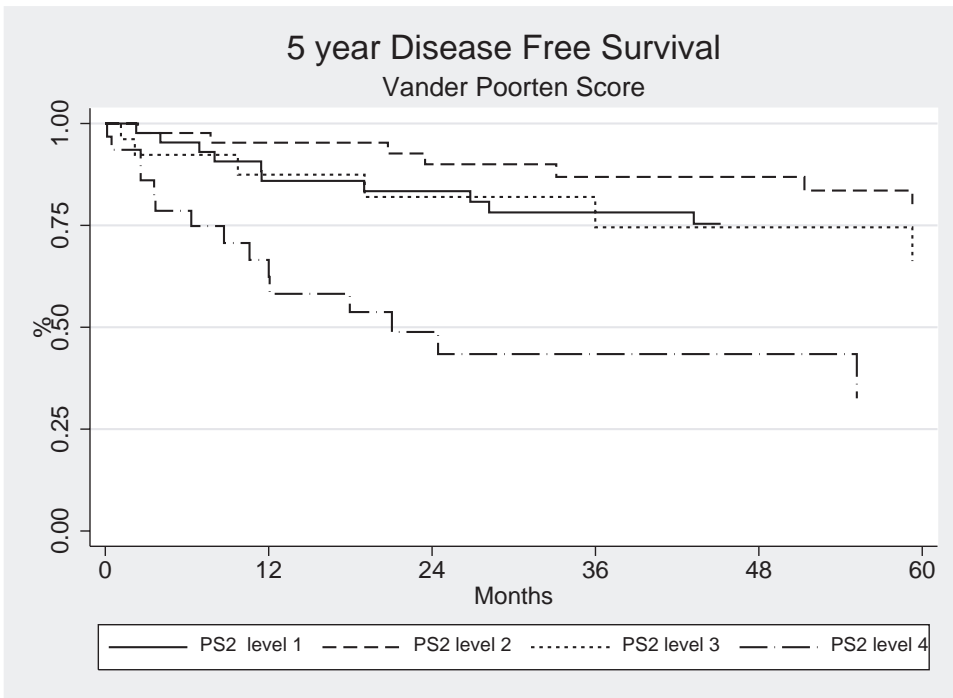


Figure 1b. Five year disease-free survival curves based on the Carrillo score.

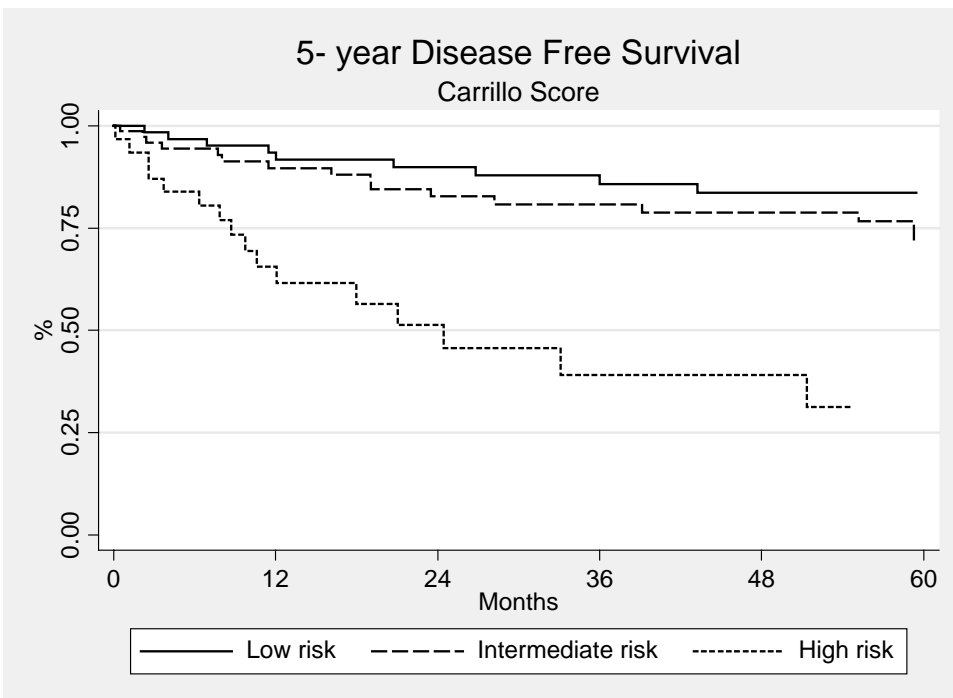


Figure 2a. Five year disease-free survival curves based on the modified Vander Poorten score.

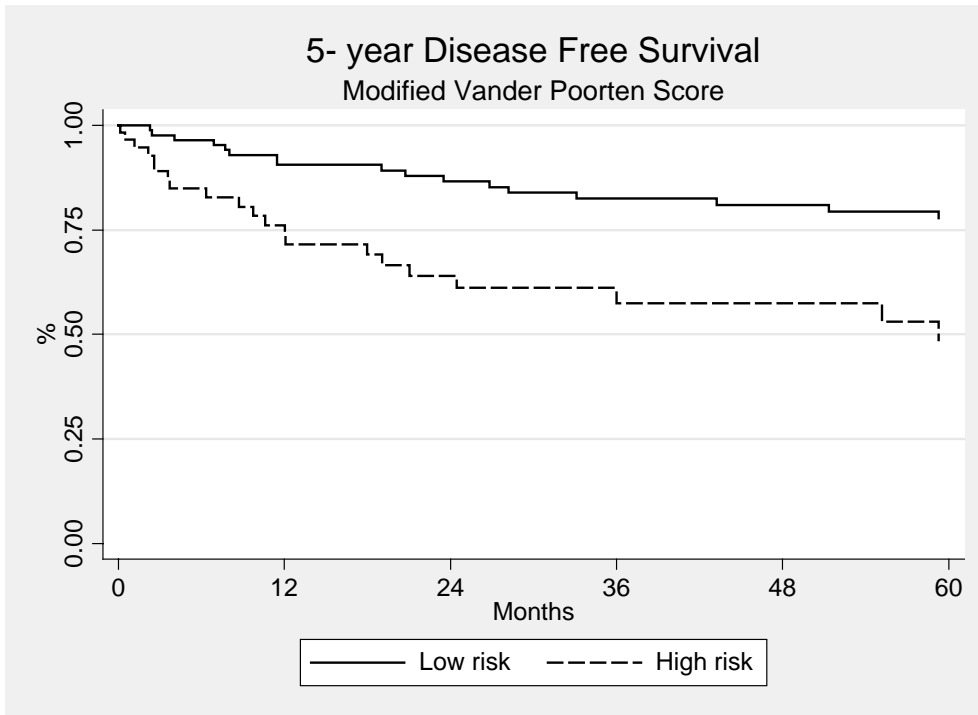
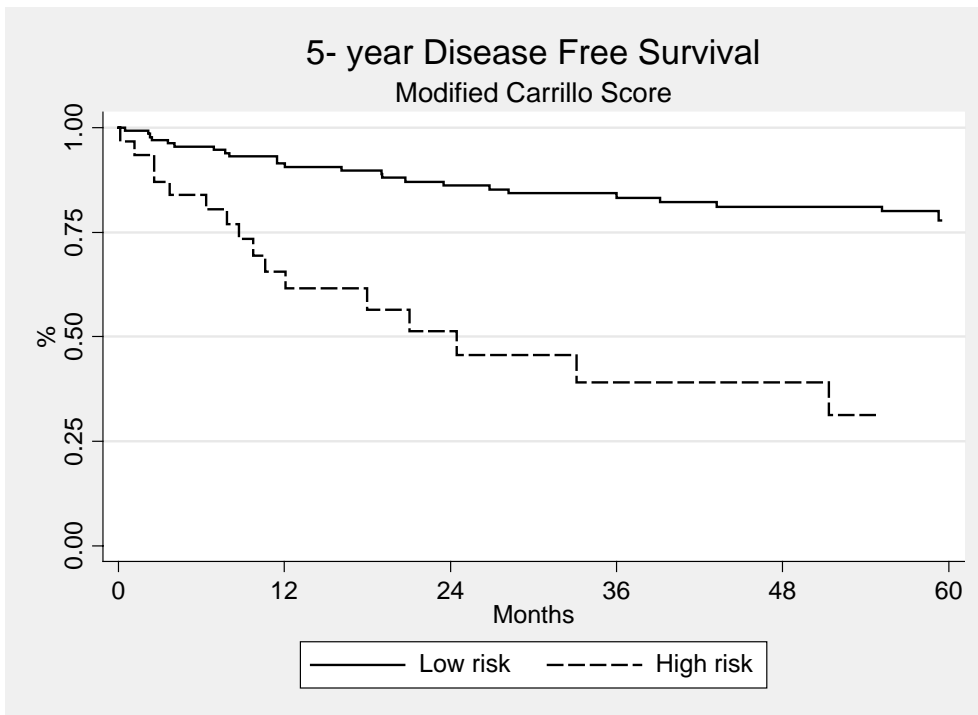


Figure 2b. Five year disease-free survival curves based on the modified Carrillo score.



CONCLUSÕES

1. Os tumores primários da glândula parótida representaram um total de 600 casos tratados no Hospital A.C. Camargo em um período de 50 anos.
2. Os tumores benignos foram os mais freqüentes, destacando-se o adenoma pleomorfo.
3. Dentre os tumores malignos o mais comum foi o carcinoma mucoepidermóide, existindo uma grande quantidade de casos de difícil diagnóstico, sendo classificados como carcinoma indiferenciado ou adenocarcinoma SOE.
4. Trinta e três casos representavam tumores de origem mesenquimal, sendo 19 não-linfóides e 14 linfóides.
5. Dentre os tumores mesenquimais não-linfóides, 15 eram benignos (5 linfangiomas, 5 neurofibromas, 1 schwannoma, 1 lipoma, 1 tumor fibroso solitário, 1 tumor de células gigantes e 1 meningioma) e 4 malignos (rabdomiossarcoma, fibrossarcoma, histiocitose de células de Langerhans e tumor do seio endodérmico).
6. O tratamento principal dos 175 casos de carcinomas de parótida selecionados para o estudo de fatores prognósticos foi a excisão cirúrgica, e a radioterapia foi reservada para casos específicos de tumores malignos. Quarenta e três pacientes apresentaram algum tipo de recorrência durante o acompanhamento, correspondendo a 24,6% dos casos.
7. A sobrevida global e livre de doença em 5 anos para os pacientes com carcinoma de parótida foi de 73,5% e 71,1%, respectivamente.
8. Os principais fatores relacionados à recorrência foram a invasão clínica da pele, disfunção do nervo facial e crescimento perineural histológico.
9. O uso de *scores* de prognóstico propostos por Vander Poorten et al. (1999) e Carrillo et al. (2007) para pacientes com carcinoma de parótida pode ser útil, no entanto, dos dois modelos testados observamos que a melhor distinção é feita com o grupo de pior prognóstico. O modelo proposto por Carrillo et al., que inclui as variáveis idade, grau histológico, tamanho do tumor e margem cirúrgica, mostrou-

se mais eficiente na distinção de grupos prognósticos que o de Vander Poorten et al.

REFERÊNCIAS*

1. Abiose BO, Oyejide O, Ogunniyi J. Salivary gland tumours in Ibadan, Nigeria: a study of 295 cases. *Afr J Med Sci* 1990;19:195-9.
2. Auclair PL, Ellis GL, Gnepp DR, Wenig BN, Janey CG. Salivary gland neoplasms: general considerations. In: Ellis GL, Auclair PL, Gnepp DR, editors. *Surgical pathology of the salivary glands*. Philadelphia: WB Saunders; 1991.p.135-64.
3. Bhattacharyya N, Fried MP. Determinants of survival in parotid gland carcinoma: a population-based study. *Am J Otolaryngol* 2005;26:39-44.
4. Bull PD. Salivary gland neoplasia in childhood. *Int J Pediatr Otorhinolaryngol*. 1999;49:S235-8.
5. Ellis GL, Auclair PL, Gnepp DR, editors. *Surgical Pathology of the Salivary Glands*. Philadelphia: WB Saunders; 1991.
6. Eneroth CM. Salivary gland tumors in the parotid gland, submandibular gland and the palate region. *Cancer* 1971;27:1415-8.
7. Eveson JW, Cawson RA. Salivary gland tumours. A review of 2410 cases with particular reference to histological types, site, age and sex distribution. *J Pathol*. 1985;146:51-8.
8. Gallo O, Franchi A, Bottai GV, Fini-Storchi I, Tesi G, Boddi V. Risk factors for distant metastases from carcinoma of the parotid gland. *Cancer* 1997;80:844-851.
9. Guntinas-Lichius O, Kick C, Klussmann JP, Jungehuelsing M, Stennert E. Pleomorphic adenoma of the parotid gland: a 13-year experience of consequent management by lateral or total parotidectomy. *Eur Arch Otorhinolaryngol* 2004;261:143–6.
10. Harbo G, Bundgaard T, Pedersen. Prognostic indicators for malignant tumors of the parotid gland. *Clin Otolaryngol*. 2002;27:512-516.

* De acordo com a norma da UNICAMP/FOP, baseadas na norma do International Committee of Medical Journal Editors – Grupo de Vancouver. Abreviatura dos periódicos em conformidade com o Medline.

11. Hocwald E, Korkmaz H, Yoo GH. Prognostic factors in major salivary gland cancer. *Laryngoscope*. 2001;111:1434-1439.
12. Kang J, Levinson JA, Hitti IF. Leiomyosarcoma of the parotid gland: a case report and review of the literature. *Head Neck* 1999;21:168-71.
13. Lima RA, Tavares MR, Dias FL. Clinical prognostic factors in malignant parotid gland tumors. *Otolaryngol Head Neck Surg*. 2005;133:702-708.
14. Luna MA, Tortoledo E, Ordonez NG, Frankenthaler RA, Batsakis JG. Primary sarcomas of the major salivary glands. *Arch Otolaryngol Head Neck Surg*. 1991;117:302-6.
15. McGurk M, Thomas BL, Renehan AG. Extracapsular dissection for clinically benign parotid lumps: reduced morbidity without oncological compromise. *Br J Cancer* 2003;89:1610-3.
16. Pinkston JA, Cole P. Incidence rates of salivary gland tumors: results from a population-based study. *Otolaryngol Head Neck Surg* 1999;120:834-840.
17. Renehan A, Gleave EN, McGurk M. An analysis of the treatment of 114 patients with recurrent pleomorphic adenomas of the parotid gland. *Am J Surg* 1996;172:710-4.
18. Sethi A, Mrig S, Sethi D, Mandal AK, Agarwal AK. Parotid gland leiomyosarcoma in a child: An extremely unusual neoplasm. *Oral Surg Oral Med Oral Pathol Oral Radiol Endod* 2006;102:82-4.
19. Spiro RH. Salivary neoplasms: overview of a 35-year experience with 2,807 patients. *Head Neck Surg*. 1986;8:177-84.
20. Van de Wal JE, Leverstein H, Snow GB, Kraaijenhagen HA, Van der Wal I. Parotid gland tumors: histologic reevaluation and reclassification of 478 cases. *Head Neck* 1998.
21. Yu GY, Ma DQ. Carcinoma of the salivary gland: a clinicopathologic study of 405 cases. *Semin Surg Oncol*. 1987;3:240-4.



**COMITÊ DE ÉTICA EM PESQUISA
FACULDADE DE ODONTOLOGIA DE PIRACICABA
UNIVERSIDADE ESTADUAL DE CAMPINAS**



CERTIFICADO

O Comitê de Ética em Pesquisa da FOP-UNICAMP certifica que o projeto de pesquisa "**Avaliação clinicopatológica e imunohistoquímica de tumores da glândula parótida**", protocolo nº **085/2007**, dos pesquisadores **ADEMAR TAKAHAMA JUNIOR** e **OSLEI PAES DE ALMEIDA**, satisfaz as exigências do Conselho Nacional de Saúde – Ministério da Saúde para as pesquisas em seres humanos e foi aprovado por este comitê em 07/11/2007.

The Ethics Committee in Research of the School of Dentistry of Piracicaba - State University of Campinas, certify that the project "**Clinicopathological and immunohistochemical analysis of parotid gland tumors**", register number **085/2007**, of **ADEMAR TAKAHAMA JUNIOR** and **OSLEI PAES DE ALMEIDA**, comply with the recommendations of the National Health Council – Ministry of Health of Brazil for research in human subjects and therefore was approved by this committee at 07/11/2007.


Prof. Cíntia Pereira Machado Tabchoury

Secretária
CEP/FOP/UNICAMP


Prof. Jacks Jorge Júnior
Coordenador
CEP/FOP/UNICAMP

Nota: O título do protocolo aparece como fornecido pelos pesquisadores, sem qualquer edição.
Notice: The title of the project appears as provided by the authors, without editing.

CENTRO DE TRATAMENTO E PESQUISA
HOSPITAL
DO CÂNCER
A. C. CAMARGO

São Paulo, 29 de junho de 2005.

Ao
Dr. Ademar Takahama Junior

Ref.: Projeto de Pesquisa n.º 711/05
"Estudo clinicopatológico, imunohistoquímico e análise de fatores prognósticos em
carcinomas de glândula paróidea".

Prezado Doutor:

Seu projeto de pesquisa, acima mencionado, foi apreciado pela Comissão de Ética em Pesquisa (CEP) do Hospital do Câncer em sua última reunião de 28/06/2005. Os membros desta comissão aprovaram a realização deste estudo.

Informações a respeito do andamento do referido projeto deverão ser encaminhadas à secretaria do CEP dentro de 12 meses.

Atenciosamente,

Dr. Daniel Deheinzelin
Coordenador Interino da Comissão de Ética em Pesquisa

C.C
Orientador: Prof. Dr. Luiz Paulo Kowalski