

**MARCELO DINIZ CARVALHO**

Cirurgião-Dentista

Mestre em Periodontia

**AVALIAÇÃO HISTOMÉTRICA DO EFEITO DO VIDRO BIOATIVO  
(PERIOGLAS<sup>®</sup>) E DO PLASMA RICO EM PLAQUETAS (PRP), E SUA  
ASSOCIAÇÃO À REGENERAÇÃO TECIDUAL GUIADA NO TRATAMENTO DE  
DEFEITOS PERIODONTAIS EM CÃES.**

Tese apresentada à Faculdade de Odontologia de Piracicaba - UNICAMP, como parte dos requisitos para obtenção do título de doutor em Clínica Odontológica na Área de Periodontia.

Orientador Prof. Dr.: Enilson Antonio Sallum

Co-orientador Prof. Dr.: Francisco Humberto Nociti Júnior

Piracicaba

2008

**FICHA CATALOGRÁFICA ELABORADA PELA  
BIBLIOTECA DA FACULDADE DE ODONTOLOGIA DE PIRACICABA**

Bibliotecária: Marilene Girello – CRB-8ª / 6159

C253a Carvalho, Marcelo Diniz.  
Avaliação histométrica do efeito do vidro bioativo (Perioglas®) e do plasma rico em plaquetas (PRP), e sua associação à regeneração tecidual guiada no tratamento de defeitos periodontais em cães. / Marcelo Diniz Carvalho. -- Piracicaba, SP : [s.n.], 2008.

Orientadores: Enilson Antonio Sallum, Francisco Humberto Nociti Júnior.

Tese (Doutorado) – Universidade Estadual de Campinas, Faculdade de Odontologia de Piracicaba.

1. Doença periodontal. 2. Cirurgia bucal. 3. Regeneração óssea. I. Sallum, Enilson Antonio. II. Nociti Júnior, Francisco Humberto. III. Universidade Estadual de Campinas. Faculdade de Odontologia de Piracicaba. IV. Título.

(mg/fop)

Título em Inglês: Histometric evaluation of bioactive glass, platelet-rich plasma and their association with guided tissue regeneration on the treatment of periodontal defects in dogs

Palavras-chave em Inglês (Keywords): 1. Periodontal disease. 2. Mouth surgery. 3. Bone regeneration

Área de Concentração: Periodontia

Titulação: Doutor em Clínica Odontológica

Banca Examinadora: Enilson Antonio Sallum, Sérgio de Toledo, Sérgio Luís Scombatti de Souza, Joni Augusto Cirelli, Giuseppe Alexandre Romito

Data da Defesa: 14-03-2008

Programa de Pós-Graduação em Clínica Odontológica



UNIVERSIDADE ESTADUAL DE CAMPINAS  
FACULDADE DE ODONTOLOGIA DE PIRACICABA



A Comissão Julgadora dos trabalhos de Defesa de Tese de DOUTORADO, em sessão pública realizada em 14 de Março de 2008, considerou o candidato MARCELO DINIZ CARVALHO aprovado.



---

PROF. DR. ENILSON ANTONIO SALLUM



---

PROF. DR. SÉRGIO LUIS SCOMBATTI DE SOUZA



---

PROF. DR. GIUSEPPE ALEXANDRE ROMITO



---

PROF. DR. SÉRGIO DE TOLEDO



---

PROF. DR. JONI AUGUSTO CIRELLI

## DEDICATÓRIA

Dedico de coração e alma este trabalho aos meus pais Arnaldo e Maria de Fátima, que ajudaram a me tornar a pessoa que sou hoje. À minha avó, Maria Rosa de Oliveira, uma das responsáveis por eu estar aqui hoje. Às minhas irmãs Viviane e Larissa pelo carinho e amor e ao Artur, pela renovação do sentimento de alegria e união que trouxe em nossa família. Vocês sempre farão parte de meus pensamentos e permanecerão eternamente cravados em meu coração.

## **AGRADECIMENTOS**

Agradeço a **Deus**, por ter me concedido a dádiva da vida na terra.

Ao Prof. Dr. **Enilson Antonio Sallum**, meu orientador, pelo exemplo de seriedade e espírito de liderança que utiliza para conduzir a Área de Periodontia;

Ao Prof. Dr. **Francisco Humberto Nociti Jr.**, meu co-orientador, pelo exemplo de competência e dedicação à pesquisa.

Ao Prof. Dr. **Antônio Wilson Sallum**, mais que um professor, mais que um orientador, um pai para todos nós;

Ao Prof. Dr. **Sérgio de Toledo**, por ter possibilitado meu ingresso na Periodontia, pelo exemplo de calma e serenidade e pela alegria que me trouxe ao aceitar o convite para participar da minha banca de doutorado;

Ao Prof. Dr. **Márcio Zaffalon Casati**, pelo incentivo e exemplo de conduta;

Ao Prof. Dr. **Antônio Fernando Martorelli de Lima**, *in memoriam*.

À Universidade Estadual de Campinas, na pessoa do Magnífico Reitor Prof. Dr. **José Tadeu Jorge**;

À Direção da Faculdade de Odontologia de Piracicaba, da Universidade Estadual de Campinas, nas pessoas do Diretor **Francisco Haiter Neto** e Vice-Diretor **Marcelo de Castro Meneghim**;

Ao Prof. **Mário Alexandre Coelho Sinhoreti**, coordenador geral dos cursos de Pós-Graduação;

Aos professores Dr. **Karina Gonzales Silveiro Ruiz**, Dr. **José Flávio Affonso de Almeida**, Dra. **Flávio Henrique Baggio Aguiar**, por terem participado do meu exame de qualificação, ajudando a engrandecer meu trabalho;

Ao Sr. **Wanderley Francisco Vieira e Fábio**, bioteristas da FOP-UNICAMP e a Sra. **Rosa**, faxineira do biotério da FOP-UNICAMP, pela atenção comigo e pelos cuidados dispensados aos animais durante a pesquisa;

A Srta. **Eliete Aparecida F. Lima**, pela indiscutível competência, amizade e apoio. E ainda pela paciência nos momentos mais difíceis;

A Sra. **Mariana P.F. Lazarim**, primeiramente pela ajuda durante os infinitos momentos dentro do laboratório de periodontia e também pela prontidão constante nos momentos de sufoco;

Aos colegas doutores e/ou professores **Antonieta, Juliana, Bruno, Luciana, Patrícia, Poliana, João, Ângela, Robert, Suzana, Renato e Fernando**, aos quais devo parte de meu conhecimento. Obrigado pelos momentos de alegria em Piracicaba, além da ajuda de forma direta ou indireta para a concretização deste sonho;

Aos colegas de mestrado e doutorado **Danilo, Cléverson, Fabíola, Gabriela, Mariana, Saulo, Bruno, Daiane, Érica, Sandro, Guilherme, Ivana, Tatiana Meulman, Monica Grazieli, Mirella, Fernanda Velasco, Ana Paula Giorgetti, Wagner Filho, Renato Casarin, Mauro Pedrine, Liana Linhares, Fernanda Ribeiro, Fabricia Suaid, Daniela Feitosa, Beatriz Bezerra, Ezymar e Thaisangela**.

Aos amigos **Bruno César Gurgel e Patrícia Furtado Gonçalves**, pela ajuda inicial para realização deste estudo;

Aos amigos **Mauro Pedrini Santamaria e Fabrícia Ferreira Suaid**, que participaram efetivamente de todo o processo de desenvolvimento deste estudo, além de terem acompanhado parte de minha vida durante todo este período, me apoiando, aconselhando e agüentando as variações de humor e reclamações.

A amiga **Ângela**, que com sua calma e equilíbrio sempre soube dar atenção e demonstrar preocupação com todos. Obrigado pelo apoio e pelos conselhos que tanto me ajudaram no início desta caminhada;

Ao “velho/novo” amigo, **Marcelo Tavares de Oliveira**, seu companheirismo é incomparável e sua amizade eterna;

Em especial ao amigo **Bruno**, por ter sido um companheiro nesta vida em Piracicaba e pela amizade que sempre demonstrou ter por mim. Você também é um amigo eterno;

Ao casal de amigos, **Fábio Mitsui e Alessandra Mitsui**, pelo enorme apoio e amizade dispensados antes e durante esta nova jornada que inicio em Manaus.

Sem vocês me apoiando e ajudando seria muito mais difícil. E não poderia deixar de agradecer a longa hospedagem 5 estrelas no “Hotel Mitsui”;

Ao **Marcelo H. Napimoga** (Hermes), pelo companheirismo e amizade que nasceram na graduação;

Aos amigos da **República Biotério**, com quem inúmeros momentos de alegria e tristeza foram divididos. Obrigado pela amizade e pela união que ainda persiste entre muitos de nós;

À **Flávia Oliveira dos Santos Pelegrini**, minha companheira durante grande parte desta jornada, em quem encontrei apoio, amizade e amor para chegar aqui. Obrigado pelo companheirismo, compreensão, carinho, amizade e amor. Sem eles não teria sido tão feliz como fui durante todo esse tempo.

E finalmente, a todos os meus familiares e aqueles que de alguma forma contribuíram para realização deste trabalho.

*Meus sinceros agradecimentos*

## EPÍGRAFE

“A VIDA É UMA SUCESSÃO CONTÍNUA DE OPORTUNIDADES”

Gabriel Garcia Marquez



## RESUMO

O objetivo do presente trabalho foi avaliar histometricamente o efeito do plasma rico em plaquetas (PRP), do vidro bioativo (Perioglas<sup>®</sup>) e sua associação sobre a regeneração periodontal em defeitos intra-ósseos de 3 paredes, além de sua combinação à regeneração tecidual guiada (RTG) em defeitos de furca grau II em cães. Foram incluídos 9 cães, fêmeas, de raça indefinida e pesando aproximadamente 15Kg. Os animais tiveram os segundos e quartos pré-molares e segundos molares mandibulares extraídos. Decorridas 12 semanas das extrações, foram criados cirurgicamente 4 defeitos intra-ósseos de 3 paredes (dimensões 4x4x4mm), sendo 2 nas faces mesiais e 2 nas faces distais dos primeiros molares mandibulares. Outros 2 defeitos do tipo furca grau II (5x2mm) foram criados na face vestibular dos terceiros pré-molares mandibulares. Em todos os defeitos foram utilizados dispositivos para cronificação durante 4 semanas. Uma semana após a remoção dos dispositivos de cronificação, os animais foram então submetidos à cirurgia para tratamento dos defeitos. O lado que recebeu os tratamentos com o PRP foi inicialmente sorteado, sendo então designados aleatoriamente os respectivos tratamentos: Controle (C); Vidro Bioativo (VB); Plasma Rico em Plaquetas (PRP) e PRP+VB, para os defeitos intra-ósseos. O lado que recebeu os tratamentos PRP e VB+PRP teve o defeito de furca grau II tratado com a associação do PRP+VB+RTG, sendo o dente contra lateral tratado com VB+RTG. Decorridas 12 semanas das cirurgias de tratamento, os animais foram sacrificados. Após processamento histológico, procedeu-se com a avaliação histométrica. Não foram observadas diferenças significantes para os parâmetros avaliados nos defeitos intra-ósseos. A extensão de epitélio foi  $2,24 \pm 0,58$  mm,  $1,94 \pm 0,37$  mm,  $1,97 \pm 0,37$  mm e  $1,81 \pm 0,61$  mm para, Controle, VB, PRP e PRP + VB, respectivamente. A adaptação conjuntiva sem formação de cimento foi  $0,90 \pm 0,28$  mm,  $0,84 \pm 0,41$  mm,  $1,07 \pm 0,27$  mm e  $1,15 \pm 0,32$  mm, respectivamente. A extensão de novo cimento foi  $2,63 \pm 0,70$  mm,  $2,56 \pm 0,36$  mm,  $2,37 \pm 0,38$  mm e

3,10±0,47 mm, respectivamente. A extensão de novo osso foi 4,77±0,44 mm, 4,64±0,68 mm, 4,67±0,46 mm e 4,84±0,42 mm, respectivamente. A porcentagem de preenchimento do defeito foi 47% no grupo C, 50% com VB, 53% com PRP e 50% com VB+PRP. Para os defeitos de furca verificou-se diferença significativa na formação de novo cemento em favor do grupo VB+PRP+RTG ( $p=0,035$ ). Dentro dos limites deste estudo pode-se concluir que o uso do VB e PRP de forma isolada ou associada não promoveram efeito adicional à regeneração periodontal em defeitos intra-ósseos de três paredes em cães. Entretanto, pode-se concluir também que o uso do PRP promoveu uma maior formação de cemento em defeitos de furca grau II em cães, quando associado ao VB e à RTG.

Palavras-chave: doença periodontal; vidro bioativo; plasma rico em plaquetas; regeneração periodontal; defeitos periodontais; defeito intra-ósseo; defeito de furca grau II.

## ABSTRACT

The objective of the present study was to evaluate at the histological level the effect of platelet-rich plasma (PRP), bioactive glass (BG) and his association on periodontal regeneration of 3-wall intrabony defects and its combination with guided tissue regeneration (GTR) on the regeneration of class II lesions in dogs. Nine mongrel dogs with approximately 15Kg were used in the experiment. The animals had the second premolar, fourth premolar and second molar at the mandible extracted. After twelve weeks, three-wall intra-bony defects (4x4x4m) were surgically created at the mesial and distal aspect of first mandibular molar. Class II furcation lesions (5x2mm) were surgically created, bilaterally, at the buccal aspect of mandibular third premolar. All defects were exposed to plaque accumulation for 1 month. One week after to remove the cronification devices, the defects were submitted to treatments. All treatments with PRP were located at the same side. Intrabony and class II furcation defects were randomly assigned to: Control (C); BG; PRP and PRP+BG, and PRP+BG+GTR and BG+GTR, respectively. Dogs were sacrificed 90 days after the surgeries and the blocks containing the experimental specimens were processed for histological analysis. No statistically significant differences were observed in all parameters for the treatment of intrabony defects. The extension of total epithelium (sulcular and junctional epithelium) was  $2.24 \pm 0.58$  mm,  $1.94 \pm 0.37$  mm,  $1.97 \pm 0.37$  mm and  $1.81 \pm 0.61$  mm for, Control, BG, PRP and PRP+BG, respectively. The new connective tissue adjacent to the root without cementum formation was  $0.90 \pm 0.28$  mm,  $0.84 \pm 0.41$  mm,  $1.07 \pm 0.27$  mm and  $1.15 \pm 0.32$  mm, respectively. The extension of new cementum was  $2.63 \pm 0.70$  mm,  $2.56 \pm 0.36$  mm,  $2.37 \pm 0.38$  mm and  $3.10 \pm 0.47$  mm, respectively. The length of new bone was  $4.77 \pm 0.44$  mm,  $4.64 \pm 0.68$  mm,  $4.67 \pm 0.46$  mm and  $4.84 \pm 0.42$  mm, respectively. The percentage of bone filling was 47% on the control group, 50% with BG, 50% with PRP+BG and 53% with PRP. At the class II furcation, no statistically significant differences were observed in defect extension and new bone ( $p=0.29$ ).The

extension of new cementum was  $9.64 \pm 1.53$  mm and  $11.00 \pm 1.05$  mm ( $p=0.03$ ) to GTR+BG and GTR+BG+PRP, respectively. Within the limits of this study, it can be concluded that PRP, BG and their association was not able to increase the amount of periodontal regeneration obtained to the treatment of 3-wall intrabony defects in dogs. However, it can be assumed that PRP promoted an increase of cementum regeneration when applied in association with BG and GTR for the treatment of class II furcation lesions in dogs.

Key Words: periodontal disease/surgery; glass, bioactive; platelet-rich plasma (PRP); periodontal regeneration; periodontal defects; intra-bony defects; class II furcation.

## SUMÁRIO

<b>Introdução</b>	<b>1</b>
<b>Capítulo 1 - Platelet-rich plasma and bioactive glass on the treatment of periodontal intra-bony defects: a histometrical study in dogs.</b>	<b>5</b>
<b>Capítulo 2 – Treatment of class II furcation lesions with guided tissue regeneration (GTR) associated with bioactive glass and platelet-rich plasma (PRP): a histometrical study in dogs.</b>	<b>28</b>
<b>Conclusão</b>	<b>49</b>
<b>Referências</b>	<b>50</b>
<b>Anexo</b>	<b>53</b>

## INTRODUÇÃO

Os objetivos da terapia periodontal incluem a eliminação e controle da infecção, e posterior correção anatômica dos defeitos produzidos pela doença, através da regeneração do osso alveolar, ligamento periodontal e cemento (Froum *et al.*, 2002). Considerando a regeneração periodontal, sabe-se que a mesma envolve um processo multifatorial com uma seqüência de eventos biológicos incluindo adesão, migração, multiplicação e diferenciação celular (Giannobile, 1996).

Apesar da completa regeneração dos tecidos periodontais ainda não ter sido alcançada, significantes progressos têm sido realizados através do uso da regeneração tecidual guiada (RTG) (Cortellini & Tonetti, 2000), enxertos ósseos (Rosen *et al.*, 2000), e mais recentemente fatores de crescimento (Camargo *et al.*, 2002). Como cada uma das técnicas citadas apresenta aspectos específicos no que tange a obtenção da regeneração periodontal, tem sido sugerido que a associação de uma ou mais técnicas poderia então melhorar os resultados, quando comparadas a qualquer técnica utilizada isoladamente (Camargo *et al.*, 2002).

O uso da RTG tem demonstrado resultados favoráveis quanto à regeneração periodontal quando aplicados aos defeitos de furca grau II. Vários autores têm reportado ganhos significativos para nível clínico de inserção horizontal e vertical, além de completo fechamento de furca em até 67% dos casos utilizando diferentes tipos de barreiras, como membranas de politetrafluoretileno-expandido ePTFE (Blumenthal, 1993), colágeno (Wang *et al.*, 1994), celulose (Simonpietri *et al.*, 2000) e ácido polilático (Polsson *et al.*, 1995).

A utilização dos enxertos ósseos vem sendo explorada na regeneração periodontal (Nasr *et al.*, 1999), através do uso de diferentes materiais de preenchimento, observando-se uma superioridade nos resultados obtidos com os enxertos autógenos (Ross & Cohen, 1968; Dragoo & Sullivan, 1973; Hiatt *et al.*, 1978; Schallhorn & McClain, 1988; Bowers *et al.*, 1989; Park *et al.*, 2001). Entretanto, algumas desvantagens vêm sendo vinculadas ao seu uso: segundo

sítio cirúrgico, maior tempo cirúrgico, morbidade pós-operatória e quantidade limitada de material (Dragoo & Sullivan, 1973; Bowers *et al.*, 1989; Zinner & Small, 1996; Karring *et al.*, 1997).

Alternativas para a sua substituição ou associação têm sido avaliadas, mostrando resultados promissores com o uso de enxertos aloplásticos. Inicialmente introduzido por Hench *et al.*, (1971), o vidro bioativo vem sendo estudado na última década apresentando resultados encorajadores no que se refere à regeneração periodontal (Wilson & Low, 1992; Fetner *et al.*, 1994) e na melhora dos parâmetros clínicos (Low *et al.*, 1997; Zamet *et al.*, 1997; Froum *et al.*, 1998; Andereg *et al.*, 1999; Park *et al.*, 2001).

O vidro bioativo é um tipo de cerâmica bioativa que consiste de SiO<sub>2</sub> (45%), CaO (24,5%), Na<sub>2</sub>O (24,5%) e P<sub>2</sub>O<sub>5</sub> (6%), com tamanho de partícula variando entre 90 e 710μ, e formato irregular - Perioglass<sup>®</sup> (NovaBone Products, LLC - USA) (Karatzas *et al.*, 1999). Em contato com os fluídos corpóreos, ele tem a capacidade de formar em sua superfície uma camada de hidróxi-carbono-apatita e sílica, na qual são incorporadas fibras colágenas, produzindo uma forte adesão entre o vidro bioativo e o tecido do hospedeiro, compatível quimicamente e estruturalmente com a composição mineral do osso (Karatzas *et al.*, 1999; Low *et al.*, 1997). A partir da formação dessas camadas e incorporação de colágeno, ocorre a migração de células osteogênicas para a área do defeito por volta de 7 a 10 dias. Ao mesmo tempo, pode ser verificada a regeneração do cemento e do ligamento periodontal na superfície radicular (Greenspan, 1999).

Dessa forma, o vidro bioativo poderia ser considerado um material osteocondutor e osteoindutor (Xynos *et al.*, 2000; Yuan *et al.*, 2001), sendo ainda, atribuído ao mesmo uma boa capacidade de hemostasia, tamanho de partículas que permita um arranjo adequado para a vascularização, biocompatibilidade, além da capacidade de inibir o crescimento epitelial (Wilson *et al.*, 1981; Wilson *et al.*, 1988; Wilson & Low, 1992; Wilson *et al.*, 1993; Park *et al.*, 2001).

Apenas a partir do início da década de 90 iniciaram-se os estudos, em seres vivos, avaliando histologicamente o efeito do vidro bioativo no reparo

periodontal. Sendo que até o atual momento poucos estudos histológicos foram desenvolvidos, a fim de esclarecer a real eficácia do uso do vidro bioativo em defeitos periodontais (Schepers *et al.*, 1993a,b; Fetner *et al.*, 1994; Karatzas *et al.*, 1999; Stavropoulos *et al.*, 2003). Apesar de poucos trabalhos histológicos, estudos clínicos desenvolvidos a partir da metade da década de 90, avaliando a eficácia do vidro bioativo no tratamento de defeitos intra-ósseos, apresentaram sucesso nos resultados, quando comparado ao tratamento periodontal convencional (Low *et al.*, 1997; Zamet *et al.*, 1997; Froum *et al.*, 1998; Ong *et al.*, 1998; Anderegg *et al.*, 1999; Nevis *et al.*, 2000; Park *et al.*, 2001).

Mais recentemente, tem-se dado ênfase na utilização do plasma rico em plaquetas (PRP) no tratamento de defeitos ósseos periodontais. O gel de PRP é derivado de uma preparação autógena de concentrado de plaquetas (Whitman *et al.*, 1997), que tem sido aplicado em procedimentos de cirurgia óssea, implantodontia e periodontia (Kim *et al.*, 2002; Froum *et al.*, 2002; Grag *et al.*, 2000). O PRP contém citocinas e fatores de crescimento, entre eles o fator de crescimento derivado de plaquetas (PDGF) e o fator de crescimento transformador  $\beta$  (TGF- $\beta$ ), os quais auxiliam na maturação acelerada de enxertos ósseos (Christie *et al.*, 1997). Tais fatores de crescimento podem regular a atividade dos osteoblastos e osteoclastos durante o processo de remodelação óssea, além de iniciar e controlar a reparação após um trauma (Lind, 1996).

Estudos têm mostrado comprovada eficiência no tratamento de lesões de furca (Park *et al.*, 1995), de defeitos ósseos ao redor de implantes de titânio quando associado a enxertos ósseos (Whitman & Berry, 1998), e ainda quando associados a RTG (Petrungaro, 2002). Quando associados à RTG e enxertos ósseos, também foi demonstrado sucesso para o tratamento de defeitos intra-ósseos e de furca grau II (de Obarrio *et al.*, 2000; Lekovic *et al.*, 2002; Camargo *et al.*, 2002).

Apesar de resultados clínicos favoráveis ao seu uso associado a outras técnicas, apenas um estudo avalia histologicamente sua associação à RTG no tratamento de lesões de furca grau III (Park *et al.*, 1995). Até o atual momento não



existem estudos controlados, que avaliem histologicamente seu uso associado a materiais para preenchimento ósseo para o tratamento de defeitos intra-ósseos e nem mesmo sua associação com RTG e substitutos ósseos para o tratamento de lesão de furca grau II em cães.

Dessa forma se torna de fundamental importância a execução de estudos que forneçam dados histológicos que suportem seu uso isoladamente ou associado a outras técnicas regenerativas no tratamento de defeitos periodontais.

# **PLATELET-RICH PLASMA AND BIOACTIVE GLASS ON THE TREATMENT OF PERIODONTAL INTRA-BONY DEFECTS: A HISTOMETRICAL STUDY IN DOGS.**

**Running title:** PRP and bioactive glass in the Treatment of bone defects.

**Key findings:** The treatment of intra-bony defects was evaluated by using PRP and bioactive glass. No significant differences were observed among the treatments, even when PRP and bioactive glass were associated.

## **Authors:**

MARCELO DINIZ CARVALHO

FABRÍCIA FERREIRA SUAID

MAURO PEDRINE SANTAMARIA

FRANCISCO HUMBERTO NOCITI JÚNIOR

MÁRCIO ZAFFALON CASATI

ANTONIO WILSON SALLUM

ENILSON ANTONIO SALLUM

## **ABSTRACT**

Background: Some clinical studies have demonstrated beneficial effects with the use of Platelet-rich plasma (PRP) and bioactive glass (BG) on periodontal parameters. This study was designed to evaluate, histometrically, the efficacy of platelet-rich plasma (PRP) and bioactive glass (BG) on the treatment of periodontal intra-bony defects. Methods: Nine mongrel dogs were used in the experiment. Three-wall intra-bony defects (4x4x4m) were surgically created at the mesial and distal aspect of first mandibular molar and exposed to plaque accumulation for 1 month. The defects were randomly assigned to: control, BG, PRP, PRP+BG. Dogs were sacrificed 90 days after the surgeries and the blocks containing the experimental specimens were processed for histological analysis. The histometric

parameters evaluated were: length of sulcular and junctional epithelium, connective tissue adaptation, new cementum, new bone, percentage of bone filling and defect extension. Results: No statistically significant differences were observed among the groups in the evaluated parameters. The extension of total epithelium (sulcular and junctional epithelium) was  $2.24 \pm 0.58$  mm,  $1.94 \pm 0.37$  mm,  $1.97 \pm 0.37$  mm and  $1.81 \pm 0.61$  mm for, Control, BG, PRP and PRP+BG, respectively. The new connective tissue adjacent to the root without cementum formation was  $0.90 \pm 0.28$  mm,  $0.84 \pm 0.41$  mm,  $1.07 \pm 0.27$  mm and  $1.15 \pm 0.32$  mm, respectively. The extension of new cementum was  $2.63 \pm 0.70$  mm,  $2.56 \pm 0.36$  mm,  $2.37 \pm 0.38$  mm and  $3.10 \pm 0.47$  mm, respectively. The length of new bone was  $4.77 \pm 0.44$  mm,  $4.64 \pm 0.68$  mm,  $4.67 \pm 0.46$  mm and  $4.84 \pm 0.42$  mm, respectively. The percentage of bone filling was 47% on the control group, 50% with BG, 50% with PRP+BG and 53% with PRP. Conclusion: Within the limits of this study, it was concluded that the use of PRP, BG and their association do not promote additional effect to the periodontal regeneration of 3-wall intra-bony defects in dogs.

KEY WORDS: periodontal disease/surgery; glass, bioactive; platelet-rich plasma (PRP); periodontal regeneration.

## **INTRODUCTION**

The ultimate goal of periodontal therapy includes not only the arrest of progressive periodontal disease but also the restitution of those parts of the supporting apparatus which have been destroyed by disease.<sup>1</sup> Several clinical procedures have been used for this purpose so far, such as bone grafts,<sup>2-5</sup> application of growth factors,<sup>6-12</sup> or their combination.<sup>13,14</sup>

The complex series of events associated with periodontal regeneration involves recruitment of locally derived progenitor cells to the site. Therefore, the key to periodontal regeneration is to stimulate the progenitor cells to re-occupy the defects.<sup>15</sup> Growth factors are vital modulators during this process which can induce the migration, attachment, proliferation and differentiation of periodontal progenitor

cells.<sup>16</sup> Platelet-rich plasma (PRP) is derived from concentrated platelets, that contain a greater concentration of autologous growth factors including platelet-derived growth factor (PDGF), transforming growth factor beta (TGF- $\beta$ ), vascular endothelial growth factor (VEGF), insulin-like growth factor (IGF-I), and epithelial growth factor (EGF)<sup>17-23</sup>. Early studies have focused on PRP application to bone graft material, showing that it leads to earlier bone regeneration and soft tissue healing, as well as greater density of mature trabecular bone<sup>12</sup>. Several studies using histological techniques suggested that PRP preparations may enhance local bone formation<sup>12, 22, 24</sup>, while others did not confirm these findings<sup>21, 25, 26, 27</sup>.

The ability of bioactive glass (BG) particles to promote bone repair has been assessed in several experimental models<sup>28-31</sup>. BG particles have been shown to undergo chemical transformation when they are implanted.<sup>32</sup> This process leads to the formation of silica gel on the surface of the particles followed by the precipitation of amorphous calcium phosphate that in turn crystallizes as hydroxycarbonate apatite by incorporating carbonates from the surrounding medium.<sup>32</sup> Hench & Polak (2002)<sup>33</sup> have shown that the release of ions (Na, Ca, and Si) from BG materials control the cell cycle leading to the differentiation and proliferation of bone cells, modulation of the expression of genes that regulate osteogenesis, and the synthesis of growth factors.

Some studies have encouraged the use of PRP to bone and periodontal regeneration. Even though, BG seems to be considered a promising alloplastic bone graft. To the author's knowledge, no histological study evaluating the use of PRP, BG and their association for the treatment of intra-bony defects has yet been reported in the literature. Therefore, the goal of this investigation is to evaluate, histometrically, the healing of surgically created intra-bony defects in dogs treated with BG, PRP and PRP+BG.

## **MATERIAL AND METHODS**

Nine adult female mongrel dogs were included in the experiment (mean weigh = 15 Kg). The study protocol has been approved by the Institutional

Committee of Research with Animals. The surgical procedures were performed under general anesthesia with intravenous injection of a 3% sodium pentobarbital solution (0.5 ml/Kg). The mandibular second and fourth premolars and second molars had been extracted previously and the extraction sites had been allowed to heal for 2 months. After buccal and lingual mucoperiosteal flaps were elevated and 4x4x4mm 3-wall intra-bony defects were created at the mesial and distal aspect of the left and right mandibular first molar<sup>34</sup> (Figure 1).

The defects were filled with gutta-percha to prevent spontaneous regeneration and exposed to plaque accumulation for a period of one month (Figure 2). After this period, scaling and root planing was performed and a regimen of daily brushing plus topical application of 0.1% chlorhexidine gluconate was instituted for 7 days prior to the surgical procedures.

#### PRP Preparation

Blood was obtained 30 minutes before the administration of anesthesia. Three tubes (5ml), containing 0.5ml of 3.2% sodium citrate solution as an anticoagulant, were drawn from each dog. The tubes were centrifuged at 1,200 rpm for 10 minutes at room temperature. The blood was thus separated into 3 basic parts: red blood cells (at the bottom of the tube), platelet enriched plasma (a discrete grey line in the middle of the tube) and platelet poor plasma (at the top of the tube). The portion corresponding to the platelet poor plasma was discarded from each tube and the remaining content was centrifuged again at 1,200 rpm for 15 minutes. Four hundred  $\mu$ l of the middle portion, corresponding to the platelet enriched plasma, were pipetted from each tube. In order to obtain the gel, 30 $\mu$ l of 10% calcium chloride was added to PRP and heated in a water bath at 37° C. The gel was achieved after a period from 10 to 15 minutes<sup>35</sup>.

#### Defect Treatment

Mucoperiosteal flaps were carefully reflected on the lingual and buccal aspect. The root surface was instrumented with curettes, the apical notch was re-

established at the base of the defect and the coronal notch at the top of the defect. Each defect in each animal (a total of 4 defects / animal) was randomly assigned to one of the following treatments (the treatments with PRP were located at the same side):

*Control*: the defect was naturally filled with coagulum;

*BG (Perioglas)*: BG particles were applied filling the defect;

*PRP*: after obtaining the PRP gel, it was immediately applied on the defect;

*PRP+BG*: BG was incorporated to the PRP (1:1) and this assemblage was immediately taken to a water bath at 37°C what enable the formation of a mixture of the gel and the BG graft.

Primary, tension-free wound closure was accomplished following defect treatment, with the gingival flaps positioned and sutured with interrupted sutures<sup>†</sup> at their presurgical position. Immediately after the surgeries, an intramuscular injection of penicillin (1.5ml – 150,000 IU) was given to the animal. The same antibiotic was repeated four days after surgeries.

Post-operative plaque control was performed by irrigation with a solution of 1% chlorexidine gluconate (every other day). After 90 days, under general anesthesia, the animals were sacrificed with a perfusion of 10% neutral formalin solution. The jaws were dissected and the blocks containing the experimental specimens were obtained. They were decalcified in a solution of equal parts of 50% formic acid and 20% sodium citrate for 5 months. The decalcified specimens were washed in running water, dehydrated and embedded in paraffin. Bucco--lingual sections of 7 µm were obtained. They were stained with Hematoxylin and eosin.

Five sections representing the midbuccal portion of each defect were selected for the histometric procedures. The sections were blindly presented for measurements by one examiner. The following distances were measured:

*Total Epithelium (sulcular and junctional epithelium)*: from the gingival margin to the apical border of the junctional epithelium.

*Connective tissue adaptation (without cementum)*: from the apical border of the junctional epithelium to the coronal end of new cementum.

*New cementum*: from the apical notch to the most coronal part of new cementum.

*New bone (bone position)*: from the apical notch to the most coronal extent of new bone. Negative values were assigned when the bony crest was located apically to the apical notch.

*New bone area*: percentage of newly formed alveolar bone to the defect area.

*Defect extension*: from the apical notch to the coronal notch.

The measurements were performed using a microscope<sup>‡</sup> with a 1.25/.035 objective associated with a video camera<sup>§</sup>/computer/software<sup>||</sup>. The extension of total epithelium, connective tissue adaptation, new cementum, new bone and defect extension were obtained by a linear measurement (x 20). The new bone area, were measured through lines intersections that made possible to mark the presence or absence of bone (intersection with bone / intersections without bone x 20).

#### Statistical analysis

Mean values for each parameter were obtained per defect. The mean values for all groups were determined using the individual means from the 9 dogs. After confirming normal distribution (Shapiro-Wilk test), the Friedman test was carried out to check the hypothesis of no difference between groups regarding the evaluated parameters. The values of  $P \leq 0.05$  were considered statistically significant.

## RESULTS

### I - Clinical Observations

Clinically, the healing response was favorable for all treatments. No suppuration or abscess formation was observed during the 90 days.

## II - Histological Observations

No undesirable reactions like inflammation and foreign body reactions were observed. All groups presented a similar healing pattern on all the extension of the defect, characterized by the presence of a great amount of new cementum (approximately 50% of the defects), new bone up to the top of the defect, a small amount of connective tissue and epithelium (Figure 3). On the defects treated with BG, it was observed the presence of a considerable amount of graft particles remaining. Some defects presented bone in contact and surrounding the BG particles (Figure 4). However this was not a common finding. Almost all defects presented a very dense connective tissue surrounding the remaining particles with some areas suggesting the formation of new bone. Root resorption and ankylosis was not observed. Connective tissue with collagen fibers running parallel to the root surface was also observed in these areas and on the surfaces that do not presented new cementum but presented new bone.

## III – Histometric Measurements

The histometric results are shown in Table 1. No statistically significant difference was found among all groups in all parameters.

## **DISCUSSION**

The use of different regenerative approaches in the treatment of periodontal defects has demonstrated a limited clinical result. Some techniques have been used in association, aiming to increase their effect on periodontal regeneration. This study compares the use of bioactive glass (BG), platelet-rich plasma (PRP) and their association on the treatment of intra-bony defects in dogs.

The need for an alternative to autologous and allogenic bone grafts have encouraged researches to develop a material that could be safe, surgically



convenient, offer pecuniary benefits, and predictably promote regeneration with a reduced morbidity. Recently, BG has been used to bone and periodontal regeneration based on its osteoconductive properties. Clinical reports have demonstrated favorable results after the use of BG in terms of reducing probing depth and improving clinical attachment levels <sup>36-42</sup>,. In addition, BG have demonstrated a similar clinical response to demineralized freeze-dried bone (DFDBA) on the treatment of intra-bony defects <sup>43</sup>.

In spite of the benefits showed by clinical studies using BG, histological results of human and animal studies have demonstrated a limited effect on bone and periodontal regeneration. Schimit *et al* (1997)<sup>44</sup>, compared a porous bone mineral with biologically active glass and observed a small amount of new bone after the use of active glass. They observed a reduction on the amount of bioactive glass between 4 and 8 weeks without any sign of osteoclast response. The authors suggested that other cell phenotype or solution-mediated processes were responsible for the reduction. Add to this fact, it was observed a more robust fibrous response on defects treated with bioactive glass. In the present study the histological evaluation was carried out at the end of 90 days. At this time, the groups treated with BG, demonstrated residual material frequently surrounded by a dense connective tissue. However it was noted in some defects, the presence of BG particles in direct contact to bone and areas suggesting the presence of a non mature bone.

Histological observations after treatment of periodontal defects with BG in nonhuman primates showed a significant increase of new cementum and inhibition of downgrowth of junctional epithelium in comparison with open flap debridement <sup>45</sup>. The authors supported part of these findings on the nonhuman primate model, justifying being a better situation to observe the real effect of BG in comparison to open flap debridement.

In the present study, the 3-wall intra-bony defects were filled with gutta-percha and submitted to plaque accumulation for a period of one month. The results of the control group are in accordance with the previous report that

demonstrated a high potential of regeneration of these defects, with the formation of almost 75% of new cementum<sup>22</sup>. In the present study the observed new cementum formation was approximately 57% in the control group. It can be hypothesized that the smaller value observed for this parameter when compared to the literature might have been a consequence of the plaque accumulation period included in the protocol. The 3-wall intra-bony defect has been used in animal studies probably because this type of defect is a common indication for regenerative techniques in a clinical set<sup>22, 34, 46</sup>. According to Kim et al (2004)<sup>22</sup>, healing of intrabony defects appears to be dependent on the number of bone walls of the defect. Increasing the number of walls would increase the potential for regeneration as a consequence of wound stability and uneventful maturation of the tooth-gingival flap interface. The 3-wall intrabony defect can be considered a reproducible model to evaluate different regenerative procedures and a preclinical model that are relatively easy to manage and from which homogeneous healing outcomes may be expected<sup>22</sup>. Considering these defect characteristics (contained defect with an ideal condition for coagulum stability), the good response of the control group was an expected finding and it represented a great challenge for the tested materials.

When using BG to promote bone regeneration<sup>47, 48</sup>, it could be possible to achieve an osteoconductive effect improving bone filling and providing direct contact of the bone to the particles of the graft. The present study corroborated with the hypothesis of BG acting as osteoconductive graft, demonstrating new bone formation on periodontal bone defects and direct contact of new bone with BG particles in some defects.

Histological evaluation of BG on the treatment of intra-bony defects in humans showed a significant apical proliferation of epithelium in most of the sections to a subosseous level, approaching the limit of the original defect. It was observed only a limited amount of new cementum and connective tissue attachment at the most apical portion of the defects, excepting one of the cases that presented new cementum and connective tissue formation<sup>49</sup>. However, a

recent histological study <sup>50</sup>, evaluating the use of BG on the treatment of 2-wall intra-bony defects in monkeys, suggested that this graft can exert an osteostimulatory effect. This was demonstrated by the new bone formation on the particles located distant from the defect wall. Also, the authors reported an inhibitory effect on the apical migration of the epithelium. In the present study, it was not observed an extensive apical migration of the epithelium and it was demonstrated the presence of new cementum and bone regeneration, even on the coronal areas of the defect.

It is known that periodontal ligament cells exhibit phenotypic characteristics consistent with osteoblast-like cells and have the potential to differentiate into osteoblasts and/or cementoblasts <sup>51</sup>. The polypeptide growth factors (PGFs) have been applied to promote periodontal regeneration. PGFs, are molecules that have been identified in the periodontal tissues and that are implicated in the growth and differentiation of cells from these tissues <sup>52, 53</sup>. PRP is a novel approach to obtain autologous PGFs, specifically platelet growth factor (PDGF) and transforming growth factor  $\beta$  (TGF $\beta$ ). PRP stimulates PDL cells and fibroblastic cell proliferation in vitro <sup>54, 55</sup>. Consequently, by ordering these cellular responses into a series of related events, PRP may efficiently facilitate wound-healing and tissue regeneration. In addition, PRP suppressed epithelial cell division in vitro <sup>56</sup>. Its ability to suppress epithelial cell proliferation seems advantageous for periodontal regeneration by favoring the formation of a new connective tissue attachment on the root surface. The results of the present study do not suggest that the use of PRP can promote an additional effect in terms of periodontal regeneration of 3 wall intra-bony defects. There are only a few studies comparing the clinical and histological effects of PRP/graft with graft material alone. Hanna *et al* (2004) <sup>57</sup>, demonstrated that the association of PRP and bovine-derived xenografts produced a greater reduction of pocket depth and gain on clinical attachment level, both statistically significant. That corroborate with the findings reported to Okuda *et al.* (2005) <sup>58</sup>, when PRP was associated with hydroxyapatite for the treatment of intra-bony defects. In spite of these clinical results, other clinical studies failed to

demonstrate additional effect of PRP on periodontal and bone regeneration <sup>1, 59-63</sup>. In a 3-wall peri-implant defects in dogs, treated with PRP associated to xenogenic bone graft, PRP demonstrated a low bone regenerative potential <sup>63</sup>. The same authors also reported no significant effect with the addition of PRP to xenogenic bone grafts on bone mineral density or graft maturity <sup>65</sup>. These observations corroborate with the results of the present study, which do not demonstrate any additional effect of PRP on periodontal and bone regeneration of 3 wall intra-bony defects.

The ideal platelet and growth factors concentration to promote periodontal regeneration has not been established. To the date, there is insufficient information about growth factor interactions and how they influence the activations of gene expression and protein production. In the present study, the achieved percentage mean of platelet concentration was 227.02 % (mean of 463,015 platelets/ $\mu$ L) in relation to blood platelets count. Lacoste *et al.*(2003) <sup>66</sup> reported that growth factors may act at specific times and at appropriate concentrations and this may be other explanation for the different results in studies with PRP.

The technique to produce PRP in the present study was introduced by Jahn (2002) <sup>67</sup> and was used in other animal studies by our group, Casati *et al.*(2007) <sup>35</sup>. This technique enables to produce a platelet concentration generally four times greater than the whole blood. As the use of thrombin in this kind of study is not allowed in our country. Instead of thrombin, 10% calcium chloride was added to PRP and heated in a water bath at 37° C in the present study. Lacoste *et al.* <sup>66</sup> performed a study that measured the concentrations of bFGF, VEGF, PDGF-BB and TGF- $\beta$ 1 released from platelet concentrate and whole blood, before and after the addition of calcium alone, thrombin alone and various concentrations of calcium and thrombin. They observed that calcium chloride, regardless of the use of thrombin, released platelet growth factors. In this study, the concentration of growth factors that was released was sufficient to promote endothelial cell proliferation in vitro <sup>66</sup>.

One of the limitations of this study is that data collected from animal models may not be directly applied to human populations due to species specific differences such as healing rates and disease activity.

Within the limits of this animal study, it was concluded that PRP, BG and their combination do not exert additional effect to periodontal regeneration in 3-wall intra-bony defects in dogs. More studies are necessary to investigate the advantages and limitations of these grafts in the treatment of periodontal defects.

#### **REFERENCES:**

1. Froum SJ, Gomez C, Breault MR. Current concepts of periodontal regeneration. A review of the literature. N Y State Dent J 2002; 68:14-22.
2. Sperling I, Kozlovsky A, Tal H. Contiguous autogenous transplant-nineteen years' clinical and radiographic follow-up: a case report. Quintessence Int 1994; 25: 555-560.
3. Richardson CR, Mellonig JT, Brunsvold MA, McDonnell HT, Cochran DL. Clinical evaluation of Bio-Oss: a bovine-derived xenograft for the treatment of periodontal osseous defects in humans. J Clin Periodontol 1999; 26: 421-428.
4. Nevins ML, Camelo M, Rebaudi A, Lynch SE, Nevins M. Three-dimensional micro-computed tomographic evaluation of periodontal regeneration: a human report of intrabony defects treated with Bio-Oss collagen. Int J Periodontics Restorative Dent 2005;25:365-373.
5. Han J, Meng HX, Xu L. Clinical evaluation of bioactive glass in the treatment of periodontal intrabony defects. Chin J Stomatol (Chin) 2002; 37: 225-227.
6. Lynch SE, de Castilla GR, Williams RC, Kiritsy CP, Howell TH, Reddy MS, *et al.* The effects of short-term application of a combination of platelet-derived and insulin-like growth factors on periodontal wound healing. J Periodontol 1991; 62: 458-467.
7. Howell TH, Fiorellini JP, Paquette DW, Offenbacher S, Giannobile WV, Lynch SE. A phase I/II clinical trial to evaluate a combination of recombinant human

- platelet-derived growth factor-BB and recombinant human insulin-like growth factor-I in patients with periodontal disease. *J Periodontol* 1997; 68: 1186-1193.
8. Ray AK, Jones AC, Carnes DL, Cochran DL, Mellonig JT, Oates TW Jr. Platelet-derived growth factor-BB stimulated cell migration mediated through p38 signal transduction pathway in periodontal cells. *J Periodontol* 2003; 74: 1320-1328.
  9. Ojima Y, Mizuno M, Kuboki Y, Komori T. In vitro effect of platelet-derived growth factor-BB on collagen synthesis and proliferation of human periodontal ligament cells. *Oral Diseases* 2003; 9: 144-151.
  10. Huang KK, Shen C, Chiang CY, Hsieh YD, Fu E. Effects of bone morphogenetic protein-6 on periodontal wound healing in a fenestration defect of rats. *J Periodontal Res* 2005; 40: 1-10.
  11. Nevins M, Giannobile WV, McGuire MK, Kao RT, Mellonig JT, Hinrichs JE, *et al.* Platelet-derived growth factor stimulates bone fill and rate of attachment level gain: results of a large multicenter randomized controlled trial. *J Periodontol* 2005; 76:2205-2215.
  12. Marx RE, Carlson ER, Eichstaedt RM, Schimmele SR, Strauss JE, Georgeff KR. Platelet-rich plasma: growth factor enhancement for bone grafts. *Oral Surg Oral Med Oral Pathol Oral Radiol Endod* 1998; 85: 638-646.
  13. Tonetti MS, Cortellini P, Lang NP, Suvan JE, Adriaens P, Dubravec D, *et al.* Clinical outcomes following treatment of human intrabony defects with GTR/bone replacement material or access flap alone. A multicenter randomized controlled clinical trial. *J Clin Periodontol* 2004; 31: 770-776.
  14. Sculean A, Windisch P, Keglevich T, Gera I. Clinical and histologic evaluation of an enamel matrix protein derivative combined with a bioactive glass for the treatment of intrabony periodontal defects in humans. *Int J Periodontics Restorative Dent* 2005; 25: 139-147.
  15. Gottlow J, Nyman S, Karring T, Lindhe J. New attachment formation as the result of controlled tissue regeneration. *J Clin Periodontol* 1984;11:494-503.
  16. Giannobile WV. Periodontal tissue engineering by growth factors. *Bone* 1996; 19: 23S-37S.

17. Galgut PN, Waite IM, Bookshaw JD, Kingston CP. A 4-year controlled clinical study into the use of a ceramic hydroxylapatite implant material for the treatment of periodontal bone defects. *J Clin Periodontol* 1992; 19: 570–577.
18. Garrett S, Bogle G. Periodontal regeneration with bone grafts. *Curr Opin Periodontol* 1994; 168–177.
19. Genco RJ (1987) Highlights of the conference and perspectives for the future. *J Periodontal Res* 22:164–171.
20. Gunsolley J, Elswick RK, Davenport JM. Equivalence and superiority testing in regeneration clinical trials. *J Periodontol* 1998; 69: 521–527.
21. Jakse N, Tangl S, Gilli R, Berghold A, Lorenzoni M, Eskici A, Haas R, Pertl C. Influence of PRP on autogenous sinus grafts: an experimental study on sheep. *Clin Oral Implants Res* 2003; 14: 578–583.
22. Kim SG, Kim WK, Park JC, Kim HJ. A comparative study of osseointegration of Avana implants in a demineralized freeze-dried bone alone or with platelet-rich plasma. *J Oral Maxillofac Surg* 2002; 60: 1018–1025.
23. Klein F, Kim TS, Hassfeld S, Staehle HJ, Reitmeir P, Holle R, Eickholz P. Radiographic defect depth and width for prognosis and description of periodontal healing of intrabony defects. *J Periodontol* 2001; 72: 1639–1646
24. Fennis JP, Stoelinga PJ, Jansen JA. Mandibular reconstruction: a histological and histomorphometric study on the use of autogenous scaffolds, particulate corticocancellous bone grafts and platelet-rich plasma in goats. *Int J Oral Maxillofac Surg* 2004; 33: 48–55.
25. Aghaloo TL, Moy PK, Freymiller EG. Investigation of platelet-rich plasma in rabbit cranial defects: a pilot study. *J Oral Maxillofac Surg* 2002; 60: 1176–1181.
26. Fürst G, Gruber R, Tangl S, Sanroman F, Watzek G. Effects of fibrin sealant protein concentrate with and without platelet released growth factors on bony healing of cortical mandibular defects. *Clin Oral Implants Res* 2004; 15: 301–307.
27. Fürst G, Gruber R, Tangl S, Zechner W, Haas R, Mailath G, Sanroman F, Watzek G. Sinus grafting with autogenous platelet-rich plasma and bovine

- hydroxyapatite. A histomorphometric study in minipigs. *Clin Oral Implants Res* 2003; 14: 500–508.
28. Schepers EJ, Ducheyne P. Bioactive glass particles of narrow size range for the treatment of oral bone defects: a 1-24 month experiment with several materials and particle sizes and size ranges. *J Oral Rehabil* 1997; 24: 171- 81.
  29. Wheeler DL, Stokes KE, Park HM, Hollinger JO. Evaluation of particulate bioglass in a rabbit radius ostectomy model. *J Biomed Mater Res* 1997; 35: 249-54.
  30. Turunen T, Peltola J, Makkonen T, Helenius H, Yli-Urpo A, Happonen R-P. Bioactive glass granules and polytetrafluoroethylene membrane in the repair of bone defects adjacent to titanium and bioactive glass implants. *J Mater Sci Mater Med* 1998; 9: 403-7.
  31. Gorustovich A, Rosenbusch M, Guglielmotti MB. Characterization of bone around titanium implants and bioactive glass particles: an experimental study in rats. *Int J Oral Maxillofac Implants* 2002; 17: 644-50.
  32. Radin S, Ducheyne P, Falaize S, Hammond A. In vitro transformation of bioactive glass granules into Ca-P shells. *J Biomed Mater Res* 2000; 49: 264-72.
  33. Hench LL, Polak JM. Third-generation biomedical materials. *Science* 2002; 295: 1014-7.
  34. Kim CK, Kim HY, Chai JK, Cho KS, Moon IS, Choi SH, Sottosanti JS, Wikesjö UM. Effect of a calcium sulfate implant with calcium sulfate barrier on periodontal healing in 3-wall intrabony defects in dogs. *J Periodontol.* 1998 Sep; 69(9): 982-8.
  35. Casati MZ, de Vasconcelos Gurgel BC, Gonçalves PF, *et al.* Platelet-rich plasma does not improve bone regeneration around peri-implant bone defects-a pilot study in dogs. *Int J oral Maxillofac Surg* 2007; 36:132-136.
  36. Low SB, King CJ, Krieger J. An evaluation of bioactive ceramic in the treatment of periodontal osseous defects. *Int J Periodontics Restorative Dent.* 1997 Aug;17(4):358-67.



37. Froum SJ, Weinberg MA, Tarnow D. Comparison of bioactive glass synthetic bone graft particles and open debridement in the treatment of human periodontal defects. A clinical study. *J Periodontol.* 1998 Jun;69(6):698-709.
38. Sculean A, Barbé G, Chiantella GC, Arweiler NB, Berakdar M, Brex M. Clinical evaluation of an enamel matrix protein derivative combined with a bioactive glass for the treatment of intrabony periodontal defects in humans. *J Periodontol.* 2002 Apr;73(4):401-8.
39. Mengel R, Soffner M, Flores-de-Jacoby L. Bioabsorbable membrane and bioactive glass in the treatment of intrabony defects in patients with generalized aggressive periodontitis: results of a 12-month clinical and radiological study. *J Periodontol.* 2003 Jun;74(6):899-908.
40. Mengel R, Schreiber D, Flores-de-Jacoby L. Bioabsorbable membrane and bioactive glass in the treatment of intrabony defects in patients with generalized aggressive periodontitis: results of a 5-year clinical and radiological study. *J Periodontol.* 2006 Oct;77(10):1781-7.
41. Sculean A, Pietruska M, Arweiler NB, Auschill TM, Nemcovsky C. Four-year results of a prospective-controlled clinical study evaluating healing of intrabony defects following treatment with an enamel matrix protein derivative alone or combined with a bioactive glass. *J Clin Periodontol.* 2007 Jun;34(6):507-13. Epub 2007 Apr 23.
42. Demir B, Sengün D, Berberoğlu A. Clinical evaluation of platelet-rich plasma and bioactive glass in the treatment of intra-bony defects. *J Clin Periodontol.* 2007 Aug;34(8):709-15.
43. Lovelace TB, Mellonig JT, Meffert RM, Jones AA, Nummikoski PV, Cochran DL. Clinical evaluation of bioactive glass in the treatment of periodontal osseous defects in humans. *J Periodontol.* 1998 Sep;69(9):1027-35.
44. Schmitt JM, Buck DC, Joh SP, Lynch SE, Hollinger JO. Comparison of porous bone mineral and biologically active glass in critical-sized defects. *J Periodontol.* 1997 Nov;68(11):1043-53.

45. Karatzas S, Zavras A, Greenspan D, Amar S. Histologic observations of periodontal wound healing after treatment with PerioGlas in nonhuman primates. *Int J Periodontics Restorative Dent.* 1999 Oct;19(5):489-99.
46. Choi SH, Kim CK, Cho KS, Huh JS, Sorensen RG, Wozney JM, Wikesjö UM. Effect of recombinant human bone morphogenetic protein-2/absorbable collagen sponge (rhBMP-2/ACS) on healing in 3-wall intrabony defects in dogs. *J Periodontol.* 2002 Jan; 73(1): 63-72.
47. Hall EE, Meffert RM, Hermann JS, Mellonig JT, Cochran DL. Comparison of bioactive glass to demineralized freeze-dried bone allograft in the treatment of intrabony defects around implants in the canine mandible. *J Periodontol.* 1999 May;70(5):526-35.
48. Cancian DC, Hochuli-Vieira E, Marcantonio RA, Garcia Júnior IR. Utilization of autogenous bone, bioactive glasses, and calcium phosphate cement in surgical mandibular bone defects in *Cebus apella* monkeys. *Int J Oral Maxillofac Implants.* 2004 Jan-Feb;19(1):73-9.
49. Nevins ML, Camelo M, Nevins M, King CJ, Oringer RJ, Schenk RK, Fiorellini JP. Human histologic evaluation of bioactive ceramic in the treatment of periodontal osseous defects. *Int J Periodontics Restorative Dent.* 2000 Oct;20(5):458-67.
50. Villaça JH, Novaes AB Jr, Souza SL, Taba M Jr, Molina GO, Carvalho TL. Bioactive glass efficacy in the periodontal healing of intrabony defects in monkeys. *Braz Dent J.* 2005;16(1):67-74. Epub 2005 Aug 17.
51. Basdra EK, Komposch G. Osteoblast-like properties of human periodontal ligament cells: an in vitro analysis. *Eur J Orthod* 1997;19:615-621.
52. Graves DT, Cochran DL. Mesenchymal cell growth factors. *Crit Rev Oral Biol Med* 1990; 1: 17-36.
53. Kiritsy CP, Lynch AB, Lynch SE. Role of growth factors in cutaneous wound healing: a review. *Crit Rev Oral Biol Med.* 1993;4(5):729-60. 11 de Camargo *et al.*, 2002

54. Kawase T, Okuda K, Wolff LF, Yoshie H. Platelet-rich plasma-derived fibrin clot formation stimulates collagen synthesis in periodontal ligament and osteoblastic cells in vitro. *J Periodontol* 2003; 74:858-864.
55. Kawase T, Okuda K, Saito Y, Yoshie H. In vitro evidence that the biological effects of Platelet-rich plasma on periodontal ligament cells is not mediated solely by constituent transforming-growth factor- $\beta$  or platelet-derived growth factor. *J Periodontol* 2005; 76:760-767.
56. Okuda K, Kawase T, Momose M, *et al.* Platelet-rich plasma contains high levels of platelet-derived growth factor and transforming growth factor- $\beta$  and modulates the proliferation of periodontally related cells in vitro. *J Periodontol* 2003; 74:849-857.
57. Hanna R, Trejo PM, Weltman RL. Treatment of intrabony defects with bovine-derived xenograft alone and in combination with platelet-rich plasma: a randomized clinical trial. *J Periodontol.* 2004 Dec;75(12):1668-77.
58. Okuda K, Tai H, Tanabe K, Suzuki H, Sato T, Kawase T, Saito Y, Wolff LF, Yoshiex H. Platelet-rich plasma combined with a porous hydroxyapatite graft for the treatment of intrabony periodontal defects in humans: a comparative controlled clinical study. *J Periodontol.* 2005 Jun;76(6):890-8.
59. Wiltfang J, Schlegel KA, Schultze-Mosgau S, Nkenke E, Zimmermann R, Kessler P. Sinus floor augmentation with beta-tricalciumphosphate (beta-TCP): does platelet-rich plasma promote its osseous integration and degradation? *Clin Oral Implants Res.* 2003 Apr;14(2):213-8.
60. Klongnoi B, Rupprecht S, Kessler P, Thorwarth M, Wiltfang J, Schlegel KA. Influence of platelet-rich plasma on a bioglass and autogenous bone in sinus augmentation. An explorative study. *Clin Oral Implants Res.* 2006 Jun;17(3):312-20.
61. Döri F, Nikolidakis D, Húszár T, Arweiler NB, Gera I, Sculean A (a). Effect of platelet-rich plasma on the healing of intrabony defects treated with an enamel matrix protein derivative and a natural bone mineral. *J Clin Periodontol.* 2007 Nov 21; [Epub ahead of print].

62. Döri F, Huszár T, Nikolidakis D, Arweiler NB, Gera I, Sculean A (b). Effect of platelet-rich plasma on the healing of intrabony defects treated with an anorganic bovine bone mineral and expanded polytetrafluoroethylene membranes. *J Periodontol.* 2007 Jun;78(6):983-90.
63. Döri F, Huszár T, Nikolidakis D, Arweiler NB, Gera I, Sculean A (c). Effect of platelet-rich plasma on the healing of intra-bony defects treated with a natural bone mineral and a collagen membrane. *J Clin Periodontol.* 2007 Mar;34(3):254-61.
64. Sánchez AR, Sheridan PJ, Eckert SE, Weaver AL (a). Regenerative potential of platelet-rich plasma added to xenogenic bone grafts in peri-implant defects: a histomorphometric analysis in dogs. *J Periodontol.* 2005 Oct;76(10):1637-44.
65. Sánchez AR, Eckert SE, Sheridan PJ, Weaver AL (b). Influence of platelet-rich plasma added to xenogeneic bone grafts on bone mineral density associated with dental implants. *Int J Oral Maxillofac Implants.* 2005 Jul-Aug;20(4):526-32.
66. Lacoste E, Martineau I, Gagnon G. Platelet concentrates: effects of calcium and thrombin on endothelial cell proliferation and growth factor release. *J Periodontol* 2003; 74: 1498–1507.
67. Jahn RS. A new methodology to produce PRP [thesis]. São Paulo: Universidade de Santo Amaro/ Faculdade de Odontologia; 2002.

## FOOTNOTES

† (Vicryl), Ethicon INC, São José dos Campos, Brazil.

‡ Zeiss Axioskop 2 ,Carl Zeiss Instruments, Gottingen, Germany.

§ DXC- 107 A/107 AP, Sony Eletronics, Inc., Shinagawa-Ku, Japan.

|| Image Pro Plus Version 3.0, Media Cybernetics, Silver Spring, MD.

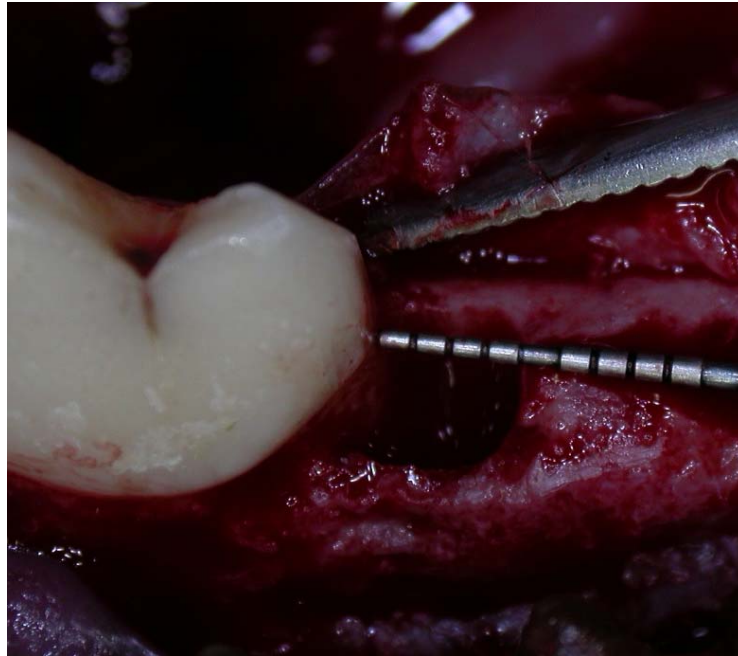
Table 1- Mean and Standard Deviation (SD) for the parameters evaluated to all treatments (Control, BG, PRP and PRP + BG).

Parameters \ Mean ± SD	Control	BG	PRP	PRP + BG	p <sup>†</sup>
Total epithelium	2.31 ± 0.74	1.97 ± 0.53	2.12 ± 0,44	2.13 ± 0.67	0.45
Connective tissue	0.93 ± 1.22	0.83 ± 0.69	1.07 ± 1.37	1.54 ± 1.29	0.59
New cementum	3.18 ± 1.28	3.32 ± 1.08	3.41 ± 1.10	3.41 ± 1.10	0.85
<i>New bone</i>	4.72 ± 0.50	4.59 ± 0.58	4.33 ± 0,28	4.33 ± 0.28	0.85
<i>New bone area</i>	0.47 ± 0.09	0.50 ± 0.20	0.53 ± 0,05	0.50 ± 0.11	0.63
<i>Defect extension</i>	4.42 ± 0.14	4.45 ± 0.41	4.40 ± 0.27	4.40 ± 0.27	0.74

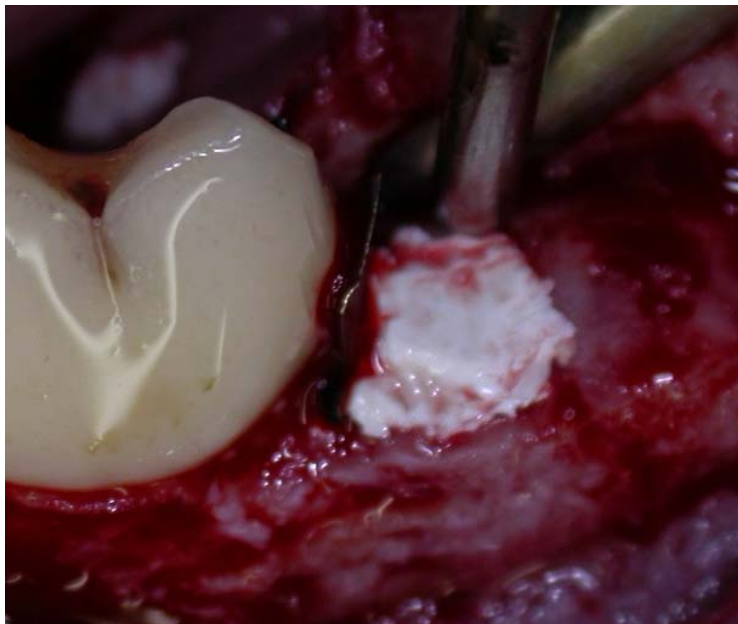\* Values in millimeters, except to New bone area (%).

† Shapiro- Wilk test (p > 0.05)

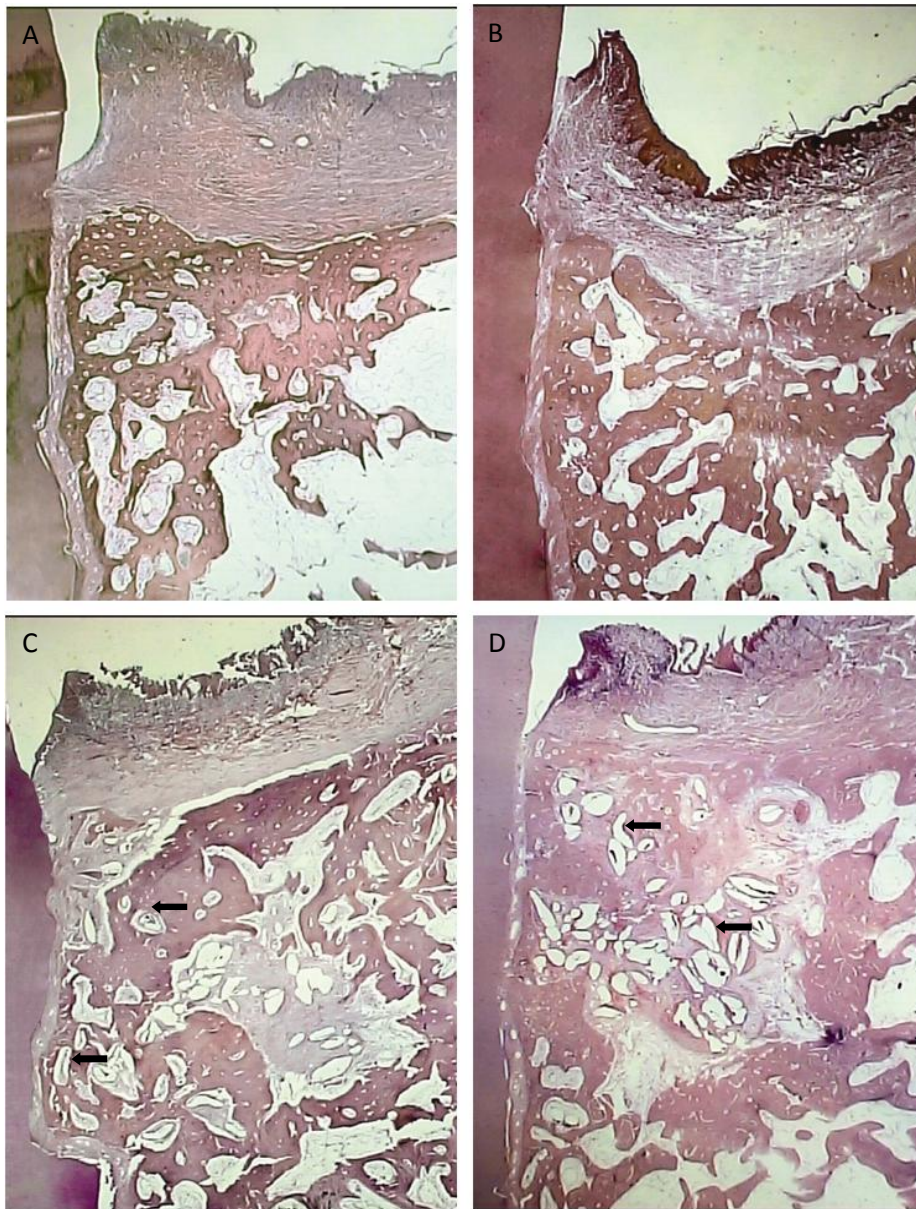
**Figure 1-** Clinical view of surgically created 3-wall intrabony defect (4x4x4mm) at the mesial aspect of first mandibular molar.



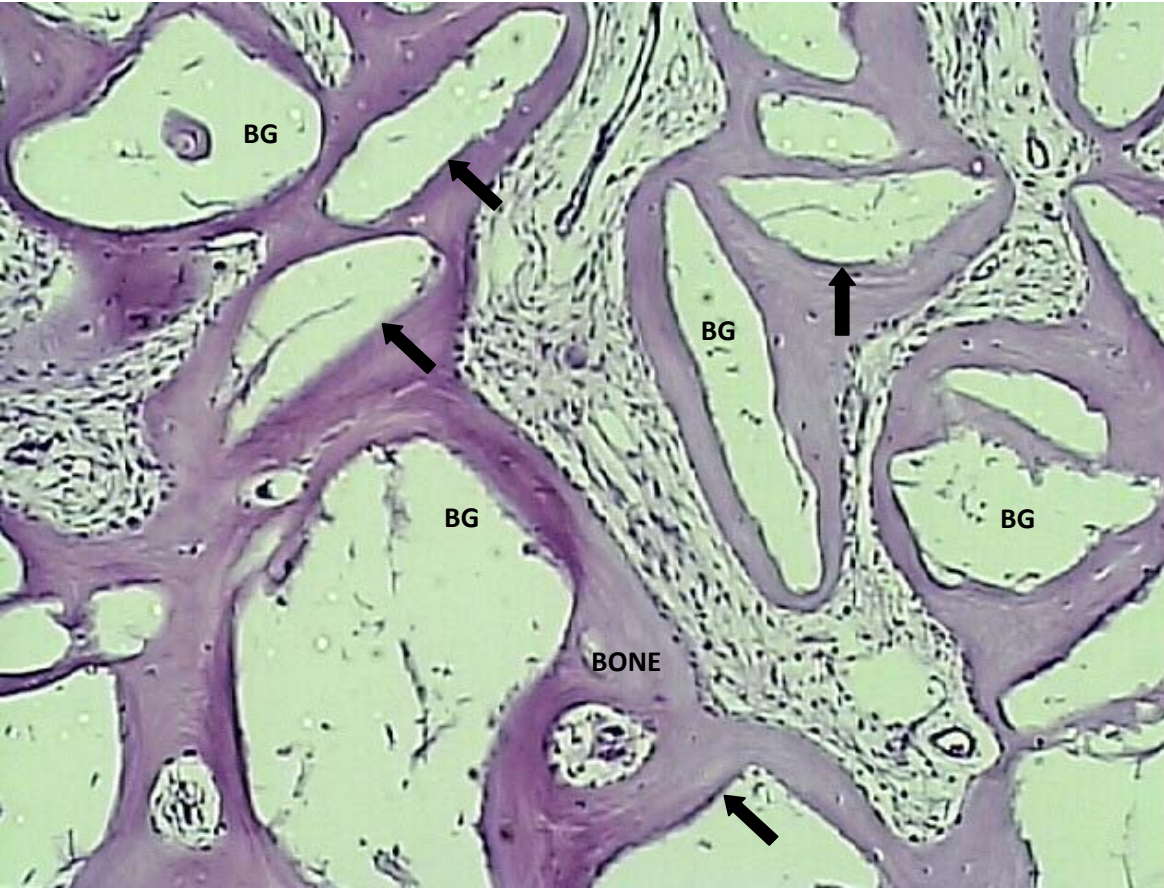
**Figure-** Clinical view of the insertion of gutta-percha and the disposable to promote plaque accumulation for one month.



**Figure 3-** Photomicrograph of a 3-wall intrabony defect showing new bone and cementum formation above apical notch (H&E, original magnification x20). A) Control; B) PRP; C) BG; D) PRP+BG. New cementum could be observed until the middle of the defect and new bone near to the coronal notch, demonstrating histological defect filling with periodontal regeneration (A, B, C and D). Particles of BG could be observed surrounded by new bone and connective tissue (C and D). Arrows indicated areas with new bone in contact with BG particles.



**FIGURE 4-** New bone formation observed on 3-wall intrabony defect (H&E, original magnification x100). Arrows indicate direct bone in contact with BG.





## **TREATMENT OF CLASS II FURCATION LESIONS WITH GUIDED TISSUE REGENERATION (RTG) ASSOCIATED WITH BIOACTIVE GLASS AND PLATELET-RICH PLASMA (PRP): A HISTOMETRICAL STUDY IN DOGS.**

**Running title:** PRP and bioactive glass in the Treatment of furcation defects.

**Key findings:** The treatment of class II furcation lesions was clinically evaluated by using the association of GTR, bone graft and PRP. It was confirmed the effectiveness of this modality of regenerative treatment for grade

### **Authors:**

MARCELO DINIZ CARVALHO

FABRÍCIA FERREIRA SUAID

MAURO PEDRINE SANTAMARIA

FRANCISCO HUMBERTO NOCITI JÚNIOR

MÁRCIO ZAFFALON CASATI

ANTONIO WILSON SALLUM

ENILSON ANTONIO SALLUM

### **ABSTRACT**

**Background:** Some clinical studies have demonstrated a successful use of Platelet-rich plasma (PRP) in association with GTR and bone graft on periodontal regeneration of intra bony defects and class II furcation lesions. The purpose of this study was to evaluate, histometrically, the effect of platelet-rich plasma (PRP) on the treatment of class II furcation lesions.

**Methods:** Nine mongrel dogs were used in the experiment. Class II furcation lesions (5x2mm) were surgically created, bilaterally, at the buccal aspect of mandibular third premolar and exposed to plaque accumulation for 1 month. The defects were randomly assigned to: GTR+BG and GTR+BG+PRP. Dogs were

sacrificed 90 days after the surgeries and the blocks containing the experimental specimens were processed for histological analysis. The histometric parameters evaluated were: length of new cementum, new bone and defect extension.

Results: No statistically significant differences were observed in defect extension and new bone ( $p=0.29$ ). The extension of new cementum was  $9.64 \pm 1.53$  mm and  $11.00 \pm 1.05$  mm for GTR+BG and GTR+BG+PRP, respectively ( $p=0.03$ )

Conclusion: Within the limits of this study, it was concluded that the use of PRP in association with GTR and BG enhance the amount of new cementum when applied to the treatment of class II furcation lesions in dogs.

KEY WORDS: periodontal disease/surgery; guided tissue regeneration; GTR; glass, bioactive; platelet-rich plasma (PRP); periodontal regeneration.

## INTRODUCTION

Teeth with furcation involvement undergo more extensive and rapid clinical probing attachment loss and are lost with greater frequency than single-rooted teeth <sup>1, 2, 3</sup>. Although regeneration of periodontal tissue is the ultimate goal of periodontal therapy, regeneration is not a predictable healing outcome after conventional treatment <sup>4</sup>.

With the advent of regenerative techniques, a new concept of periodontal treatment based on the principle of cellular selection<sup>5</sup> and guided tissue regeneration <sup>6</sup>, permits the treatment of teeth with furcation lesions by more conservative surgical methods. Various studies reported gains in horizontal and vertical clinical attachment, with complete closure of the furcation in up to 67% of the cases using different types of mechanical barriers <sup>7, 8, 9, 10</sup>. Despite of the very promising results based on reports of substantial attachment gain and bone fill of furcations, GTR is technique sensitive and could be associated with increased postoperative problems. A major drawback to ePTFE and other non-resorbable membranes is the need for their removal after 4 to 6 weeks, often with a surgical

procedure, that adds to patient morbidity and may disturb the young healing regenerative tissue <sup>11</sup>.

Bone replacement graft have achieved similar results to GTR, demonstrating a 55% overall improvement either complete or partial furcation fill compared to 52% for GTR <sup>12</sup>. The use of bioactive glass (BG) compared to an ePTFE barrier may produce equal clinical results <sup>11</sup>. When used in a variety of periodontal and oral surgical applications, BG has shown good clinical and histological profiles <sup>13, 14, 15, 16</sup>.

In the past decade, several cytokines, or growth factors, have received attention because they can regulate migration, attachment, proliferation and/or differentiation of periodontal ligament cells into hard tissue cells and have been shown to enhance regeneration *in vivo* experiments <sup>17, 18, 19, 20</sup>. Recently, there has been an increasing interest in the potential applications of polypeptide growth factors (PGFs), influence by the fact that of all PGFs know, platelet-derived growth factor (PDGF) has shown to exert a favorable effect on periodontal regeneration as measured by gain in clinical attachment and defect fill in humans <sup>21</sup>. A convenient technique to obtain a high concentration of the PGFs like transforming growth factor  $\beta$  (TGF $\beta$ ) and PDGF is by preparing autologous platelet-rich plasma (PRP)<sup>22</sup>.

Considering that the most favorable outcome of periodontal regenerative procedures in furcations lesions has been achieved with a combination of graft material and guided tissue regeneration (GTR) <sup>13, 23, 24, 25, 26</sup>, the goal of the present study is to investigate the histological effect of PRP associated with GTR (resorbable barrier) and bioactive glass (bone graft) on the regeneration of class II furcation lesions created in dogs.

## **MATERIAL AND METHODS**

Nine adult female mongrel dogs were included in the experiment (mean weigh = 15 Kg). The study protocol has been approved by the Institutional Committee of Research with Animals. The surgical procedures were performed under general anesthesia with intravenous injection of a 3% sodium pentobarbital

solution (0.5 ml/Kg). The mandibular second and fourth premolars had been bilaterally extracted previously and the extraction sites had been allowed to heal for 2 months. In order to create the defects a buccal mucoperiosteal flap was raised to expose the alveolar buccal bone. Experimental class II furcations were created in the third premolar. Osteotomy was done in the furcation area with high-speed diamond burs with constant irrigation and with Nos. 1 and 2 Ochsenbein chisels (Hu-Friedy). The furcations lesions were standardized with a millimeter probe and measured approximately 5.0mm in the apico-occlusal direction and 2.0mm in the bucco-lingual direction (Figure 1), following a technique previously described<sup>27</sup>.

The defects were filled with gutta-percha to induce an inflammatory response due to plaque accumulation for a period of one month (Figure 2). After this period, scaling and root planing was performed and a regimen of daily brushing plus topical application of 0.1% chlorhexidine gluconate was instituted for 7 days prior to the surgical procedures.

#### PRP Preparation

Blood was obtained several minutes before the administration of anesthesia. Three tubes (5ml), containing 0.5ml of 3.2% sodium citrate solution as an anticoagulant, were drawn from each dog. The tubes were centrifuged at 1,200 rpm for 10 minutes at room temperature. The blood was thus separated into 3 basic parts: red blood cells (at the bottom of the tube), platelet enriched plasma (a discrete grey line in the middle of the tube) and platelet poor plasma (at the top of the tube). The portion corresponding to the platelet poor plasma was discarded from each tube and the remaining content was centrifuged again at 1,200 rpm for 15 minutes. Four hundred µl of the middle portion, corresponding to the platelet enriched plasma, were pipetted from each tube. In order to obtain the gel, 30µl of 10% calcium chloride was added to PRP and heated in a water bath at 37° C. The gel was achieved after a period from 10 to 15 minutes<sup>28</sup>.

## Defect Treatment

Mucoperiosteal flaps were carefully reflected on the buccal aspect of the experimental sites, bilaterally, to perform reconstructive surgery. The granulation tissue was removed by curettage, and the exposed root surface was instrumented. On the root surface, the base of the defect was marked with curettes to establish a landmark for the histomorphometric analysis. Each defect in each animal (a total of 2 defects / animal) was randomly assigned to one of the following treatments:

*GTR + BG (Perioglas)*: BG particles were applied filling the defect and absorbable membrane (Gore-Tex, WL Gore) was adapted to the defect;

*GTR + BG + PRP*: BG was incorporated to the PRP (1:1) and this assemblage was immediately taken to a water bath at 37°C what enable the formation of a mixture of the gel and the BG graft. This mixture was applied filling the defect and absorbable membrane was adapted to the defect.

Primary, tension-free wound closure was accomplished following defect treatment, with the gingival flaps positioned and sutured with interrupted sutures<sup>†</sup> at their presurgical position. Immediately after the surgeries, an intramuscular injection of penicillin (1.5ml – 150,000 IU) was given to the animal. The same antibiotic was repeated four days after surgeries.

Post-operative plaque control was performed by irrigation with a solution of 1% chlorhexidine gluconate (every other day). After 90 days, under general anesthesia, the animals were sacrificed with a perfusion of 10% neutral formalin solution. The jaws were dissected and the blocks containing the experimental specimens were obtained. They were decalcified in a solution of equal parts of 50% formic acid and 20% sodium citrate for 5 months. The decalcified specimens were washed in running water, dehydrated and embedded in paraffin. Bucco-lingual sections of 7 µm were obtained. They were stained with Hematoxylin and eosin.

Five sections representing the midbuccal portion of each defect were selected for the histometric procedures. The sections were blindly presented for measurements by one examiner. The following distances were measured:

*New cementum*: extension of cementum on the root surface limited by the notch on the mesial and distal aspect of the defect.

*New bone*: extension of bone from the apical limit (determined by the notch) of the defect to the most coronal extent of new bone.

*Defect extension*: extension from the apical limit of the defect (determined by the notch) to the furcation fornix.

The measurements were performed using a microscope<sup>†</sup> with a 1.25/.035 objective associated with a video camera<sup>§</sup>/computer/software<sup>||</sup>. The extension of total epithelium, connective tissue adaptation, new cementum, new bone and defect extension were obtained by a linear measurement.

#### Statistical analysis

Mean values for each parameter were obtained per defect. The mean values for all groups were determined using the individual means from the 9 dogs. After confirming normal distribution, the paired t-test was carried out to check the hypothesis of no difference between groups regarding the evaluated parameters. The values of  $P \leq 0.05$  were considered statistically significant.

## RESULTS

### I - Clinical Observations

Clinically, the healing response was favorable for all treatments. No suppuration or abscess formation was observed during the 90 days and no exposure of membranes was observed in both groups during the healing period.

### II - Histological Observations

There were no instances of epithelial downgrowth, ankylosis or root resorption observed in all sites. No inflammation and foreign body reactions indicating toxicity were observed. A similar healing pattern was observed in both groups regarding defect filling, remaining graft particles, formation of new

cementum and new bone (Figure 3). The defect filling was achieved with both treatments in all sites. All defects presented variables amounts of BG remaining particles with different sizes. Various defects in both groups presented bone surrounding BG particles and bone in direct contact with these graft particles. Some small areas of the defects presented a very dense connective tissue surrounding the remaining particles. Connective tissue with collagen fibers running parallel to the root surface was also observed in these areas and on the root surface adjacent to areas that presented new bone formation (Figure 4).

### III – Histometric Measurements

The histometric results are shown in Table 1. Statistically significant difference was observed between treatments in the cementum extension ( $p=0.03$ ).

## DISCUSSION

In this study, it was evaluated if local application of platelet-rich plasma (PRP) on class II furcation lesions would enhance periodontal regeneration when associated with guided tissue regeneration (GTR) and bioactive glass (BG). Previous clinical report, applying GTR, bone graft and PRP demonstrated effectiveness of this therapy on periodontal regeneration of class II furcations<sup>22</sup>. Also other clinical reports, evaluating the same association on the treatment of intrabony defects demonstrated similar results<sup>29, 30, 31</sup>.

This is the first report on the use of an association of GTR/BG/PRP in the treatment of furcation lesions in dogs. The present study corroborates with previous clinical studies<sup>22, 29, 30, 31</sup>, demonstrating a positive result with the use of this combination of therapeutic modalities for periodontal regeneration. It was observed a great amount of periodontal regeneration in almost all defects of both treatments. After the treatment with PRP the amount of new cementum was significantly greater than in the group without PRP ( $p=0.03$ ). The use of different regenerative approaches in the treatment of periodontal defects has demonstrated

a limited result in terms of regeneration. Therefore, combined approaches has been suggested <sup>13, 23, 25, 26</sup>, aiming to increase the amount of periodontal regeneration. This possibility was confirmed in the present study with the group RTG+BG+PRP for the treatment of class II furcation lesions in dogs.

It has been demonstrated that when a bone graft or substitute is combined with the GTR procedure in furcation lesions, a greater amount of defect fill is observed <sup>13, 23, 25, 26</sup>. This advantage can be explained by the osteoconductive and/or osteoinductive properties of the graft materials. One of the promising bone substitutes that have been investigated is the bioactive glass (BG), a safe and surgical convenient material that has been suggested as an osteoconductive graft <sup>32, 33, 34</sup>. An osteostimulatory effect has also been suggested to this material by some researchers, which demonstrated this effect at histological level <sup>35</sup> when applied the material for the treatment of 2-wall intra-bony defects in monkeys. The authors reported an inhibitory property on the apical migration of the epithelium and new bone formation on the particles located distant from the defect walls. This healing pattern was not observed in open flap debridement group.

The sites treated with GRT+BG showed new cementum and new bone regeneration with defect filling. These results are in accordance with previous reports, which demonstrated beneficial effects with the association of GTR and bone substitutes <sup>13, 23, 25, 26</sup>. Clinical studies do not provide information about the nature of the healing process after these procedures. Therefore, histological evaluation of periodontal defects is the only reliable method to determine the healing response of the periodontal soft and hard tissue on sites treated with GTR and/or bone substitutes.

Evidence supporting the use of PRP has been based on the idea that this preparation contains polypeptide growth factors (PGFs). These are molecules that have been identified in the periodontal tissues and have been implicated in the growth and differentiation of cells from periodontal tissues <sup>36, 37</sup>. Some specific PGFs, like PDGF and TGF $\beta$ , could promote the growth and differentiation of the periodontal ligament and alveolar bone cells and could be responsible for the



clinical improvement observed in experimental sites. PRP is a method to obtain autologous PGFs, specifically PDGF and TGF $\beta$ . In vitro studies suggested that members of the TGF $\beta$  superfamily and PDGF act as proliferation and differentiation agents on a preosteoblastic cell line<sup>38</sup>. In vitro studies also demonstrated that PRP stimulates PDL cells and fibroblastic cell proliferation<sup>39, 40</sup>.

Other interesting feature of PRP is its sticky consistency due to its high fibrin content. The fibrin component of PRP may work as a hemostatic agent aiding in stabilizing the graft material and the blood clot<sup>41, 42</sup>. The fibrin component of PRP may also adhere to the root surface impeding migration of cells from the flap<sup>43</sup>.

No histological studies have evaluated the use of PRP in association with GTR and bone grafts. To our knowledge, this is the first study that evaluated, in the histological level, the effect of the association of GTR, BG and PRP on periodontal regeneration of class II furcation lesions in dogs. Clinical reports have already demonstrated that the association of GTR, bone substitutes and PRP could be an effective modality of periodontal regenerative therapy for intrabony defects and class II furcation lesions as revealed by gain in clinical attachment, defect fill at reentry, reducing probing depth, vertical defect fill and horizontal defect fill<sup>22, 29, 30, 31</sup>.

Clinical and histological studies comparing the effects of PRP/graft with graft material have been previously reported. Hanna et al (2004)<sup>44</sup>, demonstrated that the association of PRP and bovine-derived xenografts produce a greater reduction on pocket depth and gain on clinical attachment level, both statistically significant. That corroborate with the findings reported to Okuda et al. (2005)<sup>45</sup>, when PRP was associated with hydroxyapatite for the treatment of intra-bony defects. In spite of these clinical results, other clinical studies failed to demonstrate additional effect of PRP on periodontal and bone regeneration<sup>46-51</sup>. In 3-wall peri-implant defects in dogs treated with PRP associated to xenogenic bone graft, a low bone regenerative potential was observed<sup>52</sup>. The same authors also reported no significant effect with the addition of PRP to xenogenic bone grafts on bone mineral density or graft maturity<sup>53, 54</sup>. The present results demonstrated that PRP

promoted additional effect to periodontal regeneration, increasing the amount of new cementum when associated with GTR and BG. However, no additional effect was observed for new bone formation when compared to GTR+BG.

To the date, there is insufficient information about growth factor interactions and how they influence the activations of gene expression and protein production. Also, the ideal platelet and growth factors concentration to promote periodontal regeneration has not been established. Lacoste et al.(2003)<sup>55</sup> reported that growth factors may act at specific times and at appropriate concentrations and this may be other explanation for the different results in studies with PRP. In the present study, the achieved percentage mean of platelet concentration was 227.02 % (mean of 463,015 platelets/ $\mu$ L) in relation to blood platelets count.

The technique to produce PRP in the present study was introduced by Jahn (2002)<sup>56</sup> and was used in other animal studies by our group, Casati et al. (2007)<sup>38</sup>. This technique enables to produce a platelet concentration generally four times greater than the whole blood. Lacoste et al. <sup>55</sup> performed a study that measured the concentrations of bFGF, VEGF, PDGF-BB and TGF- $\beta$ 1 released from platelet concentrate and whole blood, before and after the addition of calcium alone, thrombin alone and various concentrations of calcium and thrombin. They observed that calcium chloride, regardless of the use of thrombin, released platelet growth factors. In this study, the concentration of growth factors that was released was sufficient to promote endothelial cell proliferation in vitro<sup>55</sup>. As the use of thrombin in this kind of study is not allowed in our country, instead of thrombin, 10% calcium chloride was added to PRP and heated in a water bath at 37° C in the present study.

Future studies are required to clarify the mechanism of action of PRP in the periodontal regeneration process and the ideal platelet and growth factors concentration to adequately promote periodontal regeneration. Within the limits of this animal study, it was concluded that PRP in association with GTR and BG enhance the amount of new cementum when applied to the treatment of class II furcation lesions in dogs.

## REFERENCES:

1. McFall WT Jr. Tooth loss in 100 treated patients with periodontal disease. A long-term study. *J Periodontol.* 1982 Sep; 53(9): 539-49.
2. Payot P, Bickel M, Cimasoni G. Longitudinal quantitative radiodensitometric study of treated and untreated lower molar furcation involvements. *J Clin Periodontol.* 1987 Jan; 14(1): 8-18.
3. Wang HL, Burgett FG, Shyr Y, Ramfjord S. The influence of molar furcation involvement and mobility on future clinical periodontal attachment loss. *J Periodontol.* 1994 Jan; 65(1): 25-9.
4. Egelberg J. Regeneration and repair of periodontal tissues. *J Periodontal Res.* 1987 May; 22(3): 233-42.
5. Melcher AH. On the repair potential of periodontal tissues. *J Periodontol.* 1976 May; 47(5): 256-60.
6. Gottlow J, Nyman S, Karring T, Lindhe J. New attachment formation as the result of controlled tissue regeneration. *J Clin Periodontol* 1984;11:494-503.
7. Pontoriero R, Lindhe J, Nyman S, Karring T, Rosenberg E, Sanavi F. Guided tissue regeneration in degree II furcation-involved mandibular molars. A clinical study. *J Clin Periodontol.* 1988 Apr; 15(4): 247-54.
8. Wang HL, O'Neal RB, Thomas CL, Shyr Y, MacNeil RL. Evaluation of an absorbable collagen membrane in treating Class II furcation defects. *J Periodontol.* 1994 Nov; 65(11): 1029-36.
9. Simonpietri-C JJ, Novaes AB Jr, Batista EL Jr, Filho EJ. Guided tissue regeneration associated with bovine-derived anorganic bone in mandibular class II furcation defects. 6-month results at re-entry. *J Periodontol.* 2000 Jun; 71(6): 904-11.
10. Polson AM, Garrett S, Stoller NH, Greenstein G, Polson AP, Harrold CQ, Laster, L. Guided tissue regeneration in human furcation defects after using a biodegradable barrier: a multi-center feasibility study. *J Periodontol.* 1995 May; 66(5): 377-85.

11. Yukna RA, Evans GH, Aichelmann-Reidy MB, Mayer ET. Clinical comparison of bioactive glass bone replacement graft material and expanded polytetrafluoroethylene barrier membrane in treating human mandibular molar class II furcations. *J Periodontol*. 2001 Feb; 72(2): 125-33.
12. Evans GH, Yukna RA, Gardiner DL, Cambre KM. Frequency of furcation closure with regenerative periodontal therapy. *J West Soc Periodontol Periodontal Abstr*. 1996; 44(4): 101-9.
13. Schallhorn RG & McClain PK. Combined osseous composite grafting, root conditioning and guided tissue regeneration. *Int J Periodontics Restorative Dent* 1988; 8(4): 831.
14. Wilson J, Clark AE, Hall M, Hench LL. Tissue response to bioglass endosseous ridge maintenance implants. *J Oral Implantol* 1993;19: 295-302.
15. Wilson J & Low SB. Bioactive ceramics for periodontal treatment: Comparative studies in the Patus monkey. *J Applied Biomaterials* 1992; 3: 123-129.
16. Lovelace TB, Mellonig JT, Meffert RM, Jones AA, Nummikoski PV, Cochran DL. Clinical evaluation of bioactive glass in the treatment of periodontal osseous defects in humans. *J Periodontol*. 1998 Sep;69(9):1027-35.
17. Lynch SE, Williams RC, Polson AM, Howell TH, Reddy MS, Zappa UE, Antoniades HN. A combination of platelet-derived and insulin-like growth factors enhances periodontal regeneration. *J Clin Periodontol*. 1989 Sep; 16(8): 545-8.
18. Kinoshita A, Oda S, Takahashi K, Yokota S, Ishikawa I. Periodontal regeneration by application of recombinant human bone morphogenetic protein-2 to horizontal circumferential defects created by experimental periodontitis in beagle dogs. *J Periodontol*. 1997 Feb; 68(2): 103-9.
19. Sigurdsson TJ, Lee MB, Kubota K, Turek TJ, Wozney JM, Wikesjö UM. Periodontal repair in dogs: recombinant human bone morphogenetic protein-2 significantly enhances periodontal regeneration. *J Periodontol*. 1995 Feb; 66(2): 131-8.

20. Giannobile WV, Ryan S, Shih MS, Su DL, Kaplan PL, Chan TC. Recombinant human osteogenic protein-1 (OP-1) stimulates periodontal wound healing in class III furcation defects. *J Periodontol*. 1998 Feb; 69(2): 129-37.
21. Howell, T. H., Fiorellini, J. P., Paquette, D. W., Offenbacher, S., Giannobile, W. V. & Lynch, S. E. A phase I/III clinical trial to evaluate a combination of recombinant human-derived growth factor-BB and recombinant human insulin-like growth factor-I in patients with periodontal disease. *Journal of Periodontology* 1997 68, 1186–1193.
22. Lekovic V, Camargo PM, Weinlaender M, Vasilic N, Aleksic Z, Kenney EB. Effectiveness of a combination of platelet-rich plasma, bovine porous bone mineral and guided tissue regeneration in the treatment of mandibular grade II molar furcations in humans. *J Clin Periodontol* 2003; 30: 746–751.
23. Lekovic, V., Kenney, E. B., Carranza, F. A. Jr. & Danilovic, V. Treatment of class II furcation defects using porous hydroxyapatite in conjunction with a polytetrafluoroethylene membrane. *Journal of Periodontology* 1990 61, 575–578.
24. Anderegg, C. R., Martin, S. J., Gray, J. L., Mellonig, J. T. & Gher, M. E. Clinical evaluation of the use of decalcified freeze-dried bone allograft with guided tissue regeneration in the treatment of molar furcation invasions. *Journal of Periodontology* 1991 62, 264–268.
25. McClain, P. K. & Schallhorn, R. G. Long-term assessment of combined osseous composite grafting, root conditioning, and guided tissue regeneration. *International Journal of Periodontics and Restorative Dentistry* 1993 13, 9–27.
26. Wallace, S. C., Gellin, R. G., Miller, M. C. & Mishkin, D. J. Guided tissue regeneration with and without decalcified freeze-dried bone in mandibular class II furcation invasions. *Journal of Periodontology* 1994 65, 244–254.
27. Regazzini PF, Novaes AB Jr, de Oliveira PT, Palioto DB, Taba M Jr, de Souza SL, Grisi MF. Comparative study of enamel matrix derivative with or without GTR in the treatment of class II furcation lesions in dogs. *Int J Periodontics Restorative Dent*. 2004 Oct; 24(5): 476-87.

28. Casati MZ, de Vasconcelos Gurgel BC, Gonçalves PF, *et al.* Platelet-rich plasma does not improve bone regeneration around peri-implant bone defects-a pilot study in dogs. *Int J oral Maxillofac Surg* 2007; 36:132-136.
29. de Obarrio, J. J., Aruz-Dutari, J. I., Chamberlain, T. M. & Croston, A. The use of autologous growth factors in periodontal surgical therapy: platelet gel biotechnology – case reports. *International Journal of Periodontics and Restorative Dentistry* 2000 20, 487–497.
30. Lekovic V, Camargo PM, Weinlaender M, Vasilic N, Kenney EB. Comparison of platelet-rich plasma, bovine porous bone mineral, and guided tissue regeneration versus platelet-rich plasma and bovine porous bone mineral in the treatment of intrabony defects: a reentry study. *J Periodontol.* 2002 Feb;73(2):198-205.
31. Camargo, P. M., Lekovic, V., Weinlaender, M., Vasilic, N., Madzarevic, M. & Kenney, E. B. Platelet-rich plasma and bovine porous bone mineral combined with guided tissue regeneration in the treatment of intrabony defects in humans. *Journal of Periodontal Research* 2002 37, 300–306.
32. Karatzas S, Zavras A, Greenspan D, Amar S. Histologic observations of periodontal wound healing after treatment with PerioGlas in nonhuman primates. *Int J Periodontics Restorative Dent.* 1999 Oct;19(5):489-99.
33. Choi SH, Kim CK, Cho KS, Huh JS, Sorensen RG, Wozney JM, Wikesjö UM. Effect of recombinant human bone morphogenetic protein-2/absorbable collagen sponge (rhBMP-2/ACS) on healing in 3-wall intrabony defects in dogs. *J Periodontol.* 2002 Jan; 73(1): 63-72.
34. Hall EE, Meffert RM, Hermann JS, Mellonig JT, Cochran DL. Comparison of bioactive glass to demineralized freeze-dried bone allograft in the treatment of intrabony defects around implants in the canine mandible. *J Periodontol.* 1999 May;70(5):526-35.
35. Nevins ML, Camelo M, Nevins M, King CJ, Oringer RJ, Schenk RK, Fiorellini JP. Human histologic evaluation of bioactive ceramic in the treatment of

- periodontal osseous defects. *Int J Periodontics Restorative Dent.* 2000 Oct;20(5):458-67.
36. Basdra EK, Komposch G. Osteoblast-like properties of human periodontal ligament cells: an in vitro analysis. *Eur J Orthod* 1997;19:615-621.
  37. Graves DT, Cochran DL. Mesenchymal cell growth factors. *Crit Rev Oral Biol Med* 1990; 1: 17-36.
  38. Strayhorn, C. L., Garrett, J. S., Dunn, R. L., Benedict, J. J. & Somerman, M. J. Growth factors regulate expression of osteoblast-associated genes. *Journal of Periodontology* 1999 70, 1345–1354.
  39. Kiritsy CP, Lynch AB, Lynch SE. Role of growth factors in cutaneous wound healing: a review. *Crit Rev Oral Biol Med.* 1993;4(5):729-60.
  40. Kawase T, Okuda K, Wolff LF, Yoshie H. Platelet-rich plasma-derived fibrin clot formation stimulates collagen synthesis in periodontal ligament and osteoblastic cells in vitro. *J Periodontol* 2003; 74:858-864.
  41. Wikesjö, U. M. E., Nilveus, R. E. & Selvig, K.E. Significance of early healing events on periodontal repair. A review. *Journal of Periodontology* 1992 63, 158–165.
  42. Polson, A. M. & Proye, M. P. Fibrin linkage: a precursor for new attachment. *Journal of Periodontology* 1983 54, 141–147.
  43. Gottlow J, Nyman S, Karring T, Lindhe J. New attachment formation as the result of controlled tissue regeneration. *J Clin Periodontol.* 1984 Sep;11(8):494-503.
  44. Hanna R, Trejo PM, Weltman RL. Treatment of intrabony defects with bovine-derived xenograft alone and in combination with platelet-rich plasma: a randomized clinical trial. *J Periodontol.* 2004 Dec;75(12):1668-77.
  45. Okuda K, Kawase T, Momose M, et al. Platelet-rich plasma contains high levels of platelet-derived growth factor and transforming growth factor- $\beta$  and modulates the proliferation of periodontally related cells in vitro. *J Periodontol* 2003; 74:849-857.

46. Froum SJ, Gomez C, Breault MR. Current concepts of periodontal regeneration. A review of the literature. *N Y State Dent J* 2002; 68:14-22.
47. Okuda K, Tai H, Tanabe K, Suzuki H, Sato T, Kawase T, Saito Y, Wolff LF, Yoshiex H. Platelet-rich plasma combined with a porous hydroxyapatite graft for the treatment of intrabony periodontal defects in humans: a comparative controlled clinical study. *J Periodontol.* 2005 Jun;76(6):890-8.
48. Wiltfang J, Schlegel KA, Schultze-Mosgau S, Nkenke E, Zimmermann R, Kessler P. Sinus floor augmentation with beta-tricalciumphosphate (beta-TCP): does platelet-rich plasma promote its osseous integration and degradation? *Clin Oral Implants Res.* 2003 Apr;14(2):213-8.
49. Klongnoi B, Rupprecht S, Kessler P, Thorwarth M, Wiltfang J, Schlegel KA. Influence of platelet-rich plasma on a bioglass and autogenous bone in sinus augmentation. An explorative study. *Clin Oral Implants Res.* 2006 Jun;17(3):312-20.
50. Döri F, Nikolidakis D, Húszár T, Arweiler NB, Gera I, Sculean A (a). Effect of platelet-rich plasma on the healing of intrabony defects treated with an enamel matrix protein derivative and a natural bone mineral. *J Clin Periodontol.* 2007 Nov 21; [Epub ahead of print].
51. Döri F, Huszár T, Nikolidakis D, Arweiler NB, Gera I, Sculean A (b). Effect of platelet-rich plasma on the healing of intrabony defects treated with an anorganic bovine bone mineral and expanded polytetrafluoroethylene membranes. *J Periodontol.* 2007 Jun;78(6):983-90.
52. Döri F, Huszár T, Nikolidakis D, Arweiler NB, Gera I, Sculean A (c). Effect of platelet-rich plasma on the healing of intra-bony defects treated with a natural bone mineral and a collagen membrane. *J Clin Periodontol.* 2007 Mar;34(3):254-61.
53. Sánchez AR, Sheridan PJ, Eckert SE, Weaver AL (a). Regenerative potential of platelet-rich plasma added to xenogenic bone grafts in peri-implant defects: a histomorphometric analysis in dogs. *J Periodontol.* 2005 Oct;76(10):1637-44.



54. Sánchez AR, Eckert SE, Sheridan PJ, Weaver AL (b). Influence of platelet-rich plasma added to xenogeneic bone grafts on bone mineral density associated with dental implants. *Int J Oral Maxillofac Implants*. 2005 Jul-Aug;20(4):526-32.
55. Lacoste E, Martineau I, Gagnon G. Platelet concentrates: effects of calcium and thrombin on endothelial cell proliferation and growth factor release. *J Periodontol* 2003; 74: 1498–1507.
56. Jahn RS. A new methodology to produce PRP [thesis]. São Paulo: Universidade de Santo Amaro/ Faculdade de Odontologia; 2002.

## FOOTNOTES

† (Vicryl), Ethicon INC, São José dos Campos, Brazil.

‡ Zeiss Axioskop 2 ,Carl Zeiss Instruments, Gottingen, Germany.

§ DXC- 107 A/107 AP, Sony Eletronics, Inc., Shinagawa-Ku, Japan.

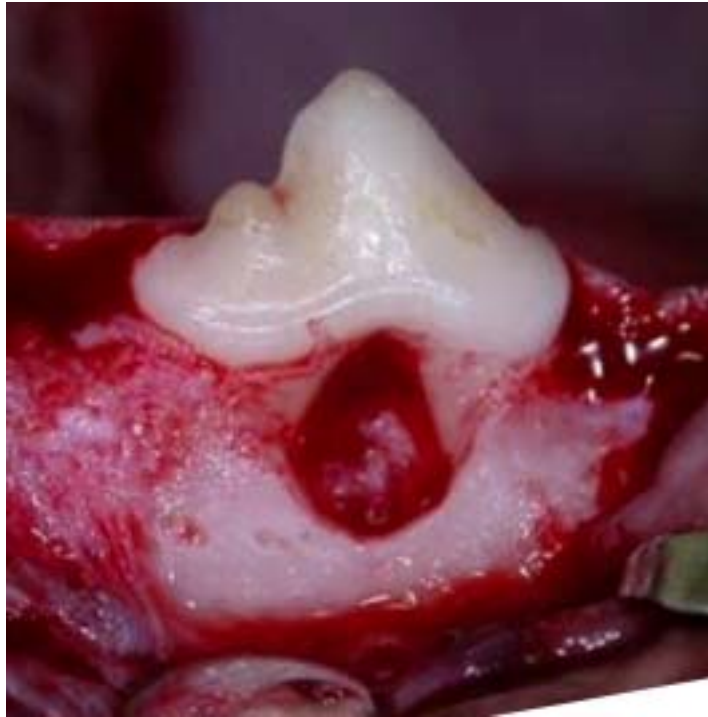|| Image Pro Plus Version 3.0, Media Cybernetics, Silver Spring, MD.

Table 1- Mean and Standard Deviation (SD) for the parameters evaluated to both treatments (RTG+BG and RTG+BG+PRP).

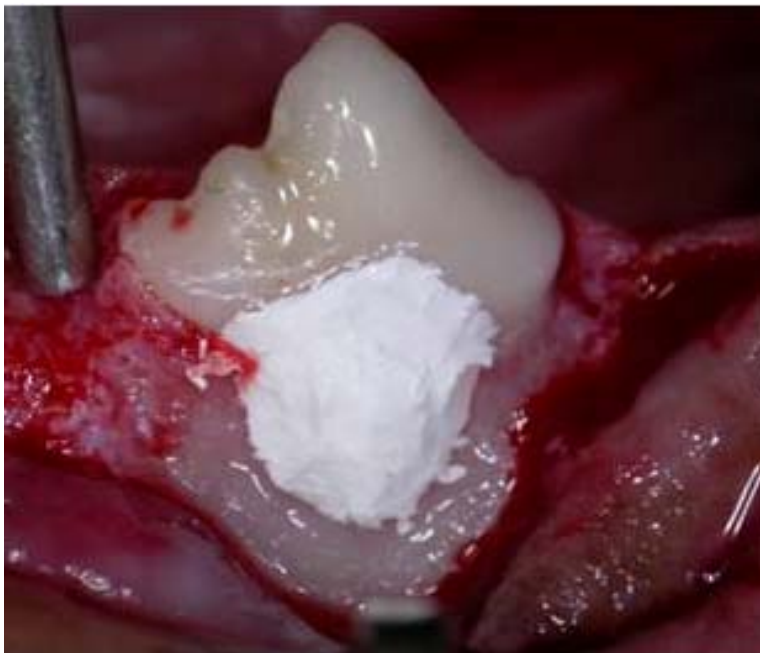Parameters	RTG+BG	RTG+BG+PRP	p <sup>†</sup>
<i>Defect high</i>	5.07 ± 0.60	5.11 ± 0.58	0.29
<i>Defect extension</i>	11.38 ± 0.96	11.45 ± 1.15	0.32
New cementum extension	9.17 ± 2.02	11.07 ± 1.19	0.01
<i>New bone (high)</i>	3.94 ± 0.96	4.46 ± 0.59	0.31
<i>Connective extension</i>	2.33 ± 0.96	-	0.02
<i>Epithelial extension</i>	3.24 ± 0.71	-	0.08

\* Values in millimeters; † paired-test (p > 0.05)

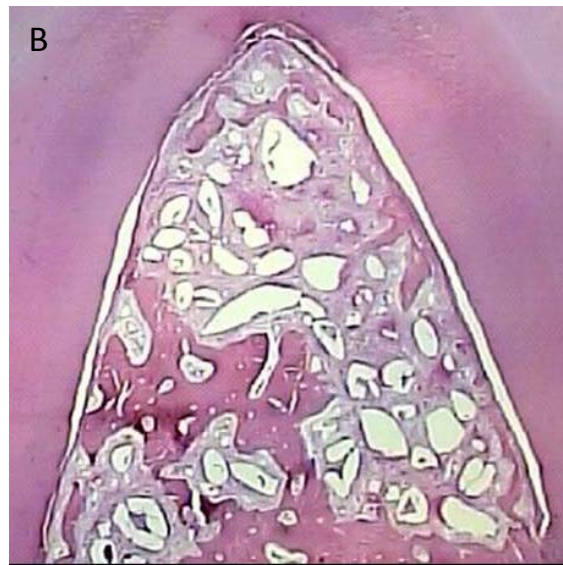
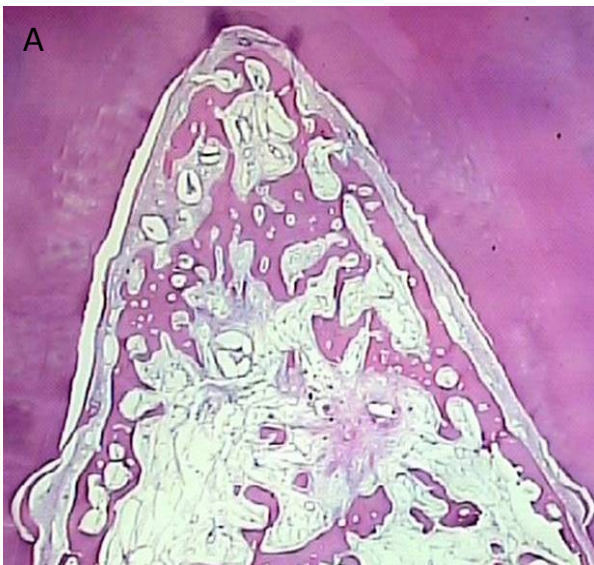
**Figure 1-** Clinical aspect of Class II furcation defect (5x2mm).



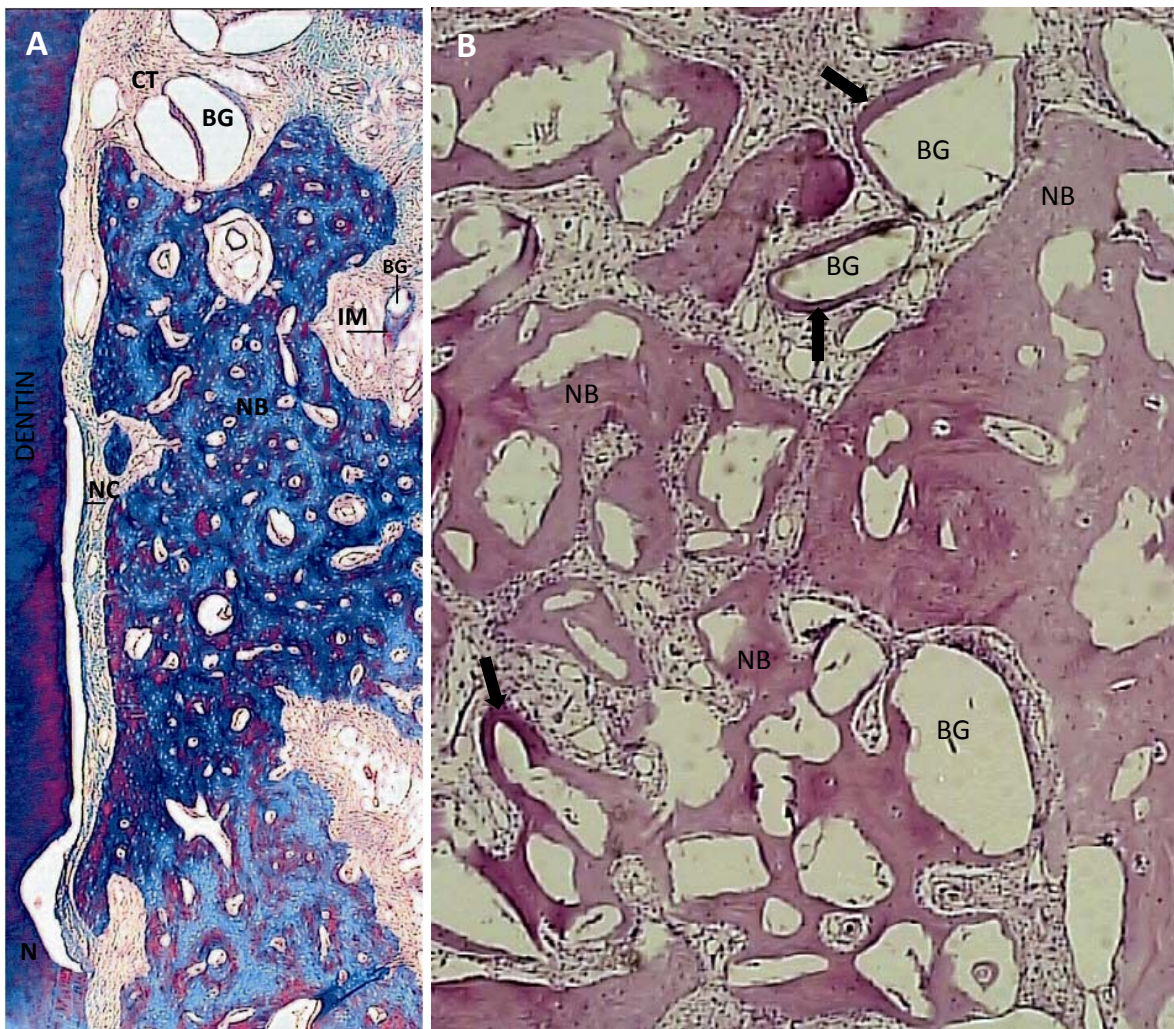**Figure 2-** Clinical aspect of Class II furcation defect filled with gutta-percha.



**Figure 3-** Mesiodistal histologic section of Class II furcation lesion 12 weeks after treatment defect (H&E, original magnification x20): **A)** BG+GTR and **B)** PRP+BG+GTR. Both treatments promote defect fill, demonstrating cementum and bone regeneration. Above to the notch (N), new cementum of reduced thickness was observed. Remaining BG particles were observed surrounded by bone, connective tissue and some areas suggest the presence of a newly formed bone adjacent to BG particles.



**Figure 4- A)** Photomicrograph of a Mesiodistal histologic section of Class II furcation lesion (PRP+BG+GTR) 12 weeks after treatment defect (Masson trichrome stain, original magnification x40). New cementum (NC) was observed above the notch (N). Remaining BG particles were observed surrounded by new bone (NB), connective tissue (CT) and areas suggesting the presence of immature bone (IB) in contact with BG; **B)** Histologic section of the PRP+BG+GTR defect, 12 weeks after treatment (H&E, original magnification x100). Remaining BG particles could be observed surrounded by NB and CT. Some areas indicated the new bone formation occurring around BG particles (arrows).



## **CONCLUSÃO**

Dento dos limites deste estudo pode-se concluir que o uso do VB e PRP de forma isolada ou associada não promoveram efeito adicional à regeneração periodontal em defeitos intra-ósseos de três paredes em cães. Entretanto, pode-se concluir também que o uso do PRP promoveu uma maior formação de cemento em defeitos de furca grau II em cães, quando associado ao VB e à RTG.

## REFERÊNCIAS\*

- Anderegg CR, Alexander DC, Friedman M. A bioactive glass particle in the treatment of molar furcation ivasions. J Periodontol 1999; 70: 384-387.
- Blumenthal NM. A clinical comparison of collagen membranes with e-PTFE membranes in the treatment of human mandibular buccal class II furcation defects. J Periodontol. 1993 Oct; 64(10): 925-33.
- Bowers GG, Chadroff B, Carnevale R, et al. Histologic evaluation of new human attachment apparatus formation in humans: PartII. J Periodontol 1989; 60: 675-682.
- Christie RJ, Carrington L, Alving B. Postoperative bleeding induced by topical bovine thrombin: report of two cases. Surgery 1997; 121(6): 708-10.
- Cortellini P & Tonetti M. Focus on intrabony defects: guided tissue regeneration. Periodontol 2000 2000; 22: 104-132.
- Dragoo M & Sullivan M. A clinical and histologic evaluation of autogenous iliac bone grafts in humans. PartI. Wound healing 208 months. J Periodontol 1973; 44: 599-612.
- Fetner AE, Martigan MS, Low SB. Periodontal repair using Perioglas in nonhuman primates: Clinical and histologic evaluation. Compendium Continuing Educ Dent 1994; 15: 932-939.
- Garg AK. The use of platelet-rich plasma to enhance the success of bone grafts around dental implants. Dent Implantol Update 2000; 11(3): 17-21.
- Greenspan DC. Bioactive glass: Mechanisms of bone bonding. Swed Dent J 1999; 91: 31-35.
- Hench LL, Splinter RJ, Allen WC, Greenlee TK. Bonding mechanisms at the interface of ceramic prosthetic materials. J Biomed Mater Res 1971; 2: 117-141.
- Hiatt WH, Schallhorn RG, Aaronian AJ. The induction of new bone and cementum formation. IV. Microscopic examination of the periodontium following

---

\* De acordo com a norma da UNICAMP/FOP, baseada no modelo Vancouver. Abreviatura dos periódicos em conformidade com o Medline.

human bone and marrow allograft, autograft and nongraft periodontal regenerative procedures. J Periodontol 1978; 49: 495-512.

Lind M. Growth factors: possible new clinical tools. A review. Acta Orthop Scand 1996; 67(4): 407-17.

Nasr HF, Aichelmann-Reidy ME, Yukna RA. Bone and bone substitutes. Periodontol 2000 1999; 19:74-86.

Ong MMA, Eber RE, Korsnes MI, MacNeil RL, Glickman GN, Shyr Y, Wang HL. Evaluation of a bioactive glass alloplast in treating periodontal intrabony defects. J Periodontol 1998; 69: 1346-1354.

Park JB, Matsuura M, Han KY, *et al.* Periodontal regeneration in class III furcation defects of beagle dogs using guided tissue regenerative therapy with platelet-derived growth factor. J Periodontol 1995; 66(6): 462-77.

Park JS, Suh JJ, Choi SH, Moon IS, Cho KS, Kim CK, Chai JK. Effects of pretreatment clinical parameters on bioactive glass implantation in intrabony periodontal defects. J Periodontol 2001; 72: 730-740.

Petrungaro PS. Immediate restoration of multiple teeth implants for aesthetic implant restorations. Implant Dent 2002; 11(2): 118-127.

Rosen PS, Reynolds MA, Bowers GM. The treatment of intrabony defects with bone grafts. Periodontol 2000 2000; 22: 88-103.

Ross SE & Cohen DW. The fate of a free osseous tissue autograft. A clinical and histologic case report. Periodontics 1968; 6: 145-151.

Schepers EJG, Ducheyne P, Barbier L. Clinical application of bioactive glass granules of narrow size range on dental osseous lesions. Bioceramics 1993a; 6: 361-364.

Schepers EJG, Ducheyne P, Barbier L, Schepers S. Bioactive glass particles of narrow size range: A new material for the repair of bone defects. Implant Dent 1993b; 2: 151-156.

Stavropoulos A, Kostopoulos L, Nyengaard JR, Karring T. Deproteinized bovine bone (Bio-Oss) and bioactive glass (Biogran) arrest bone formation when used



as an adjunct to guided tissue regeneration (GTR). An experimental study in the rat. *J Clin Periodontol* 2003; 30: 636-643.

Wang HL, O'Neal RB, Thomas CL, Shyr Y, MacNeil RL. Evaluation of an absorbable collagen membrane in treating Class II furcation defects. *J Periodontol*. 1994 Nov; 65(11): 1029-36.

Whitman DH, Berry RL. A technique for improving the handling of particulate cancellous bone and marrow grafts using platelet gel. *J Oral Maxillofac Surg* 1998; 56(10): 1217-8.

Whitman DH, Berry RL, Green DM. Platelet gel: an autologous alternative to fibrin glue with applications in oral and maxillofacial surgery. *J Oral Maxillofac Surg* 1997; 55(11): 1294-1299.

Wilson J, Merwin GE. Biomaterials for facial bone augmentation: Comparative studies. *J Biomed Mater Res* 1988; 22 (suppl.): 159-177.

Wilson J, Pigott GH, Schoen FJ, Hench LL. Toxicology and biocompatibility of bioglasses. *J Biomed Mater Res* 1981; 15: 805-817.

Xynos ID, Edgar AJ, Buttery LD, Hench LL, Polak JM. Ionic products of bioactive glass dissolution increase proliferation of human osteoblast and induce insulin-like growth factor II mRNA expression and protein synthesis. *Biochem Biophys Res Commun* 2000; 276:461-465.

Zamet JS, Darbar UR, Griffiths GS, *et al*. Particulate bioglass as a grafting material in the treatment of periodontal intrabony defects. *J Clin Periodontol* 1997; 24: 410-418.

Zinner ID & Small SA. Sinus-lift graft: using the maxillary sinuses to support implants. *Journal of American Dental Association* 1996; 127: 51-57.

## ANEXO

26-Dec-2007

Dear Prof. Sallum,

I am pleased to inform you that your manuscript, Platelet-rich plasma and connective tissue graft in the treatment of gingival recessions: a histometric study in dogs. (JOP-07-0339.R2), is accepted for publication in the Journal of Periodontology, with an acceptance date of 02-Oct-2007.

Please complete and return a Copyright Agreement at your earliest convenience. This form can be found in the upper right-hand corner of your screen at <http://mc.manuscriptcentral.com/jperio> under "Instructions & Forms." A copy is also attached here.

Please fax or e-mail this form to Bethanne Wilson (fax: 312-573-3225; e-mail: [bethanne@perio.org](mailto:bethanne@perio.org)).

Note that all authors must sign this form. In assigning the copyright, you agree to an embargo on the material contained in the manuscript until such time as you are advised of a publication date, and shall not release the manuscript or any part thereof to any individual, organization, or institution. If you wish to use any portion of the manuscript in an oral presentation at a meeting of a recognized scientific organization, you may request such permission from the Journal of Periodontology.

Further information regarding publication date, page proofs, and reprints will come to you directly from the Managing Editor. Thank you for your support of the Journal of Periodontology.

Sincerely,

Dr. Steven Engebretson

Journal of Periodontology

E-mail: [steven.engebretson@stonybrook.edu](mailto:steven.engebretson@stonybrook.edu)