

Images in medicine

Oral pemphigus vulgaris after Chilean earthquake

César Rivera^{1,2,3,8}, Bernardo Venegas⁴

¹Unit of Histology and Embryology, Department of Basic Biomedical Sciences, Faculty of Health Sciences, University of Talca, Talca, Chile, ²Department of Oral Diagnosis, School of Dentistry, State University of Campinas (UNICAMP), Piracicaba, São Paulo, Brazil, ³Mass Spectrometry Laboratory, Brazilian Biosciences National Laboratory - CNPEM, Campinas, São Paulo, Brazil, ⁴Unit of Oral Pathology, Department of Stomatology, Faculty of Health Sciences, University of Talca, Talca, Chile

⁸Corresponding author: César Rivera, Unit of Histology and Embryology, Department of Basic Biomedical Sciences, Faculty of Health Sciences, University of Talca, Talca, Chile, Department of Oral Diagnosis, School of Dentistry, State University of Campinas (UNICAMP), Piracicaba, São Paulo, Brazil, Mass Spectrometry Laboratory, Brazilian Biosciences National Laboratory - CNPEM, Campinas, São Paulo, Brazil

Key words: Oral pemphigus vulgaris, earthquake, Chile

Received: 29/03/2014 - Accepted: 04/07/2014 - Published: 16/07/2014

Pan African Medical Journal. 2014; 18:219 doi:10.11604/pamj.2014.18.219.4273

This article is available online at: <http://www.panafrican-med-journal.com/content/article/18/219/full/>

© César Rivera et al. The Pan African Medical Journal - ISSN 1937-8688. This is an Open Access article distributed under the terms of the Creative Commons Attribution License (<http://creativecommons.org/licenses/by/2.0>), which permits unrestricted use, distribution, and reproduction in any medium, provided the original work is properly cited.

Image in medicine

A 62-year-old male, was referred for the management of extremely painful oral ulcerations with surrounding erythema on the soft palate and cheeks (A-C). He reported that ulcers began after the Chilean earthquake in 2010. His medical history was not significant. Ulcerations showed remissions and exacerbations since earthquake. On clinical examination, skin and other sites involvement was not found. An incisional biopsy was taken from the cheek region. Histopathological examination revealed suprabasilar blister formation associated with acantholysis (D and E). Hence, a final diagnosis of oral pemphigus vulgaris (OPV) was made based on histopathological pattern and clinical features. Treatment regimen included oral prophylaxis; prednisone and betamethasone 3-4 times daily for topical application. The patient was controlled every 2 weeks for the first 1 month. The lesions had diminished and increased healing with steroids within 4 weeks of starting the

treatment. The patient was kept under observation for 12 months and the lesions showed signs of recurrence. Pemphigus vulgaris (PV) is a chronic inflammatory disease that affects the skin and the mucus membrane. It is a rare disease (0.1-0.5 cases/100,000 inhabitants/year), with onset in the fifth or sixth decade of life. Oral lesions are the first manifestation in 50-90% of cases. PV results from an autoimmune process in which IgG antibodies are produced against normal desmosomal adhesion molecules (desmoglein 3, 1 and cadherin family) on the cell membrane of keratinocytes. Recent evidence suggests that anxiety, depression, and psychological stress are correlated with the occurrence and intensity of associated OPV symptoms. OPV is a condition that has no cure. The response to treatment in oral lesions is much slower in comparison to cutaneous lesions.

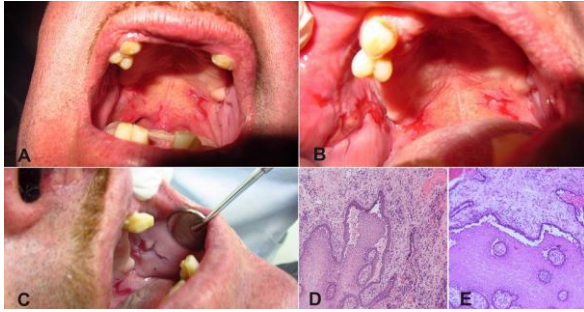


Figure 1: Asymmetric ulcerations with surrounding erythema on the patient's soft palate (A). Ulceration on the left cheek extended (B). Affected right cheek (C). Epithelial multilayered tissue with papillary hyperplasia. Suprabasilar separation (intraepithelial vesicle) with non-adherent spinous cells floating in blister fluid (Tzanck cells)(D). The basal layer is seen attached to the underlying connective tissue without interruption. (E) Connective tissue having an area of intense infiltrated inflammatory mononuclear and abundant vascular

spaces with high congestion of erythrocytes (E).