

## Anatomical features of the urethra and urinary bladder catheterization in female mice and rats. An essential translational tool<sup>1</sup>

Características anatômicas da cateterização da uretra e bexiga de camundongos e ratos fêmeas.  
Instrumento essencial na pesquisa pré clínica

Leonardo Oliveira Reis<sup>1</sup>, Josep Maria Gaya Sopena<sup>II</sup>, Wagner José Fávaro<sup>III</sup>, Mireia Castilho Martin<sup>IV</sup>, Antônio Felipe Leite Simão<sup>V</sup>, Rodolfo Borges dos Reis<sup>VI</sup>, Murilo Ferreira de Andrade<sup>VII</sup>, Josep Domingo Domenech<sup>VIII</sup>, Carlos Cordon Cardo<sup>IX</sup>

<sup>I</sup>PhD, Urologic Oncology Division, Department of Urology, University of Campinas (UNICAMP), Campinas-SP, Brazil. Herbert Irving Comprehensive Cancer Center, Columbia University, New York, USA. Responsible for intellectual and scientific content of the study, acquisition and interpretation of data, responsible for manuscript preparation, manuscript writing, critical revision, designed the protocol. Involved with technical procedures, supervised all phases of the study.

<sup>II</sup>MD, Herbert Irving Comprehensive Cancer Center, Columbia University, New York, New York, USA. Department of Urology. Fundació Puigvert. Univesitat Autònoma de Barcelona, UAB, Barcelona, Sain. Acquisition and interpretation of data, responsible for manuscript preparation, manuscript writing, critical revision, designed the protocol.

<sup>III</sup>PhD, Department of Anatomy, Institute of Biosciences, Universidade Estadual Paulista (UNESP), Bocatatu-SP, Brazil. Department of Anatomy, Cellular Biology, Physiology and Biophysics, Institute of Biology, University of Campinas (UNICAMP), Campinas, Sao Paulo, Brazil. Acquisition and interpretation of data, responsible for manuscript preparation, manuscript writing.

<sup>IV</sup>PhD, Herbert Irving Comprehensive Cancer Center, Columbia University, New York, New York, USA. Critical revision, designed the protocol, involved with technical procedures, supervised all phases of the study.

<sup>V</sup>MD, Urologic Oncology Division, Department of Urology, University of Campinas (UNICAMP), Campinas-SP, Brazil. Critical revision.

<sup>VI</sup>PhD, Assistant Professor, Division of Urology, Department of Surgery and Anatomy, Faculty of Medicine of Ribeirao Preto of University of Sao Paulo (FMRP-USP), Ribeirao Preto-SP, Brazil. Critical revision.

<sup>VII</sup>MD, Urologic Division, Department of Surgery and Anatomy, FMRP-USP. Ribeirao Preto-SP, Brazil. Critical revision.

<sup>VIII</sup>PhD, Herbert Irving Comprehensive Cancer Center, Columbia University, New York, New York, USA. Critical revision.

<sup>IX</sup>PhD, Herbert Irving Comprehensive Cancer Center, Columbia University, New York, New. Responsible for intellectual and scientific content of the study, critical revision supervised all phases of the study.

---

### ABSTRACT

**PURPOSE:** To present fundamental anatomical aspects and technical skills necessary to urethra and urinary bladder catheterization in female mice and rats.

**METHODS:** Urethral and bladder catheterization has been widely utilized for carcinogenesis and cancer research and still remains very useful in several applications: from toxicological purposes as well as inflammatory and infectious conditions to functional aspects as bladder dynamics and vesicoureteral reflux, among many others.

**RESULTS:** Animal models are in the center of translational research and those involving rodents are the most important nowadays due to several advantages including human reproducibility, easy handling and low cost.

**CONCLUSIONS:** Although technical and anatomical pearls for rodent urethral and bladder access are presented as tackles to the advancement of lower urinary tract preclinical investigation in a broaden sight, restriction to female animals hampers the male microenvironment, demanding future advances.

**Key words:** Urinary Tract. Rodent Diseases. Anatomy. Rats.

---

### RESUMO

**OBJETIVO:** Apresentar aspectos anatômicos fundamentais e habilidades técnicas necessárias para cateterismo da uretra e bexiga em ratos e camundongos fêmeas.

**MÉTODOS:** Cateterismo vesical tem sido amplamente utilizado na pesquisa do câncer e carcinogênese, além de várias outras aplicações, desde fins toxicológicos, condições inflamatórias e infecciosas até aspectos funcionais como a dinâmica vesical e refluxo vesico-ureteral, entre muitos outros.

**RESULTADOS:** Os modelos animais estão no centro da investigação de translação e os roedores são os mais importantes devido a várias vantagens, incluindo reprodutibilidade humana, o fácil manuseio e baixo custo.

**CONCLUSÕES:** Apesar de permitir o desenvolvimento da investigação pré-clínica do trato urinário inferior, o modelo se restringe aos animais do sexo feminino, de modo que avanços futuros são necessários.

**Descritores:** Sistema Urinário. Doenças dos Roedores. Anatomia. Ratos.

---

## Introduction

Urinary bladder catheterization may be required for a variety of clinical and experimental reasons. Animal models provide a vehicle for the understanding of basic biological questions, and through their use the adequate control of experimental design is possible so that rigorous experiments can be performed to test a hypothesis<sup>1</sup>.

The female rodent external urinary ostium is easily visualized and rests anterior to the vaginal opening, making urinary tract catheterization easier in the rodents than in other species. However, the anatomical features of urinary bladder catheterization do still need to be further described, once it is poorly explained in literature, limiting the reproducibility of most related protocols.

The use of urethral approach in rodents is only possible under general anesthesia<sup>2</sup>. Special care must be taken to minimize the risk of introducing infection into urinary tract during the procedure. Recently, it has been shown that catheters, lubricating gels and speculums must be clean but not necessarily sterilized before use, in contrast with what had been published before<sup>3</sup>.

Rodent models are currently the most significant due to several advantages including easy handling, low cost, human reproducibility and the understanding of rodent anatomy, physiology and genetic, being in the heart of translational research.

While most if not all the articles involving intravesical access neglect the bladder catheterization report in the methods section, limiting the description to: "... polytetrafluoroethylene coated intravenous catheter was inserted in the bladder through the urethra."

### *Anatomical issues*

The urinary bladder of the rodents is a hollow, muscular, distensible organ that serves as a reservoir for storage and periodic release of urine. Urine enters the bladder through ureters and exits via the urethra. In rodents, the bladder is located in the dorso-caudal area of the abdominopelvic cavity. When emptied of urine, the bladder is an ovoid structure with a maximum diameter of approximately 4 mm<sup>3,4</sup>.

On histological examination, a transitional epithelium, uniformly three cell layers deep is seen to line the entire bladder. Bladder capacity ranges from 400-500 ml in humans, and in rodents, it differs between mice (0.15ml) and rats (1.00ml)<sup>5</sup>.

The urinary bladder is divided into two distinct regions: a) the bladder dome or bladder body which mainly consists of detrusor smooth muscle and b) bladder neck or bladder base; a small region which consists of the trigone and extends from the ureters to the urethra<sup>5</sup>.

The female urethra lying immediately ventral to the vagina is approximately 9 mm in length and opens independently of the vagina. The external urethral ostium lies dorsally to the clitoris in a common cone-shaped skin protrusion, which also receives the openings of the paired clitoral gland. At about midway along its

length from the bladder, it passes through and almost adjacent to the pubic symphysis, from which it is separated by a small amount of adipose tissue<sup>3,4</sup>.

For most of its length, the urethral lumen, which had never seen to be completely occluded, is lined by a pseudostratified cuboidal epithelium, which can be up to eight cells deep. At the bladder neck the epithelium becomes transitional in type and is continuous with that of the bladder<sup>3,4</sup>. Distally, the urethra is lined by stratified squamous epithelium that becomes keratinized towards the external ostium. In transverse section the urethral lumen is variable in shape.

At its external opening, the lumen is a vertical slit, which, more proximal to the bladder, opens laterally, forming a cross shape. Expansion of its horizontal component and a reduction of the vertical component produce a crescent slit which tends towards a horseshoe shape in the region of the pubic symphysis. For the remainder of its length to the bladder, the lumen tends towards an "H" shape in section, by means of vertical expansions of the horseshoe shape<sup>4</sup>. The shape of the urethral lumen was found to be similar in both old and young mice and in perfusion and immersion fixed specimens<sup>3,4</sup>.

This study aims to transfer basic knowledge of a fundamental translational tool.

## Methods and Results

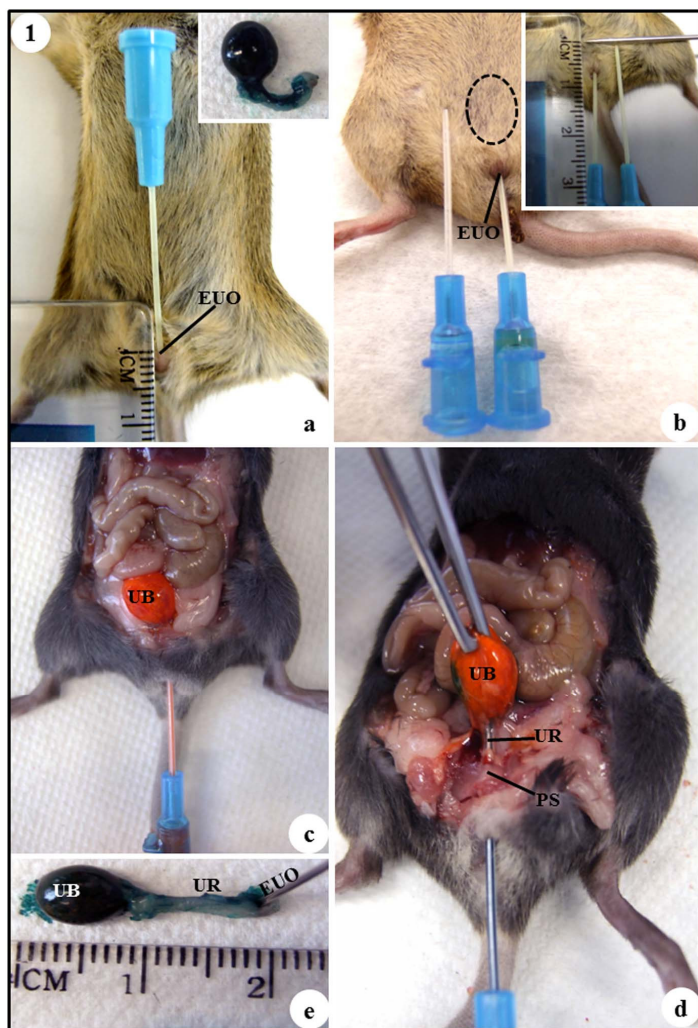
### *Animals and proceedings*

The present work describes the anatomical features of the technique for short-term urinary bladder catheterization in the adult female mice and rats. All procedures were done according to the guidelines of the Brazilian College for Animal Experimentation (COBEA) under Institutional Committee for Ethics in Animal Research approval.

In order to perform bladder catheterization, female mice and rats (of any lineage), all around 7 weeks old, were anesthetized with 10% ketamine (60 mg/kg, i.m.) and 2% xylazine (5 mg/kg, i.m.) and remained anesthetized for approximately 45 minutes to prevent distress, to carry out the technique safely and to avoid animal pain. A 22 and 20 Gauge polytetrafluoroethylene (GA)-BD Angiocath™ angiocatheter were used for urinary bladder catheterization in mice and rats, respectively. Procedures for urinary catheterization were similar for both mice and rats.

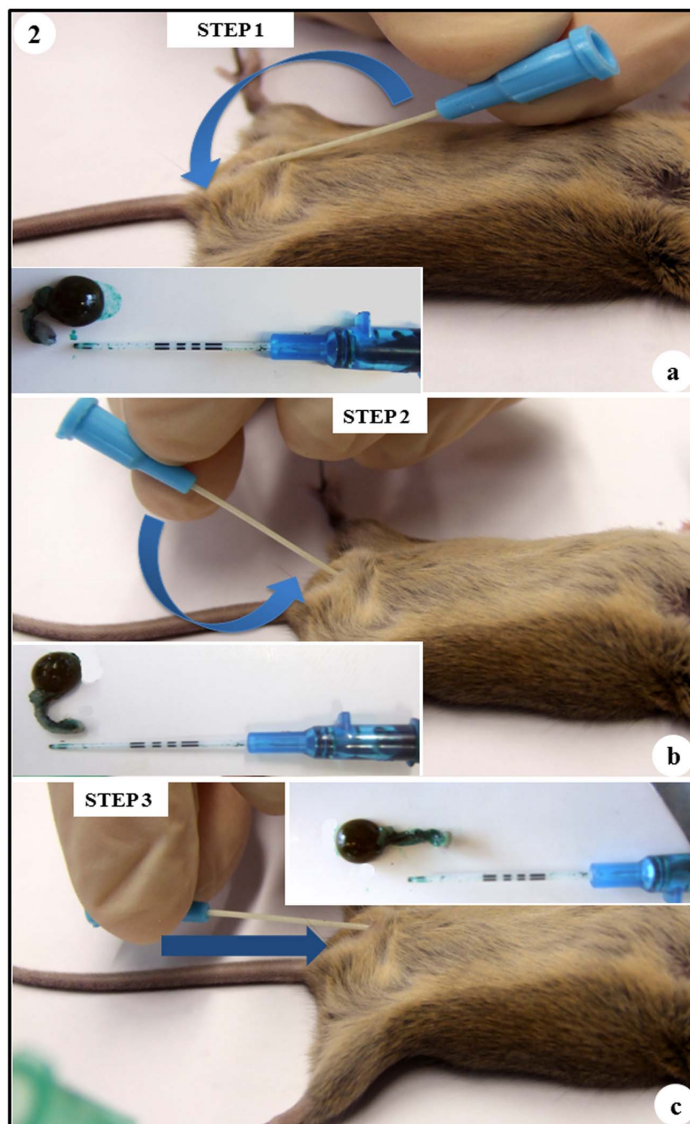
### *Technical report*

Under anesthesia, the animals were positioned in dorsal recumbence, and before performing urethra catheterization the micturition was induced through a mild lower abdomen massage (Figure 1a). The external urethral ostium was normally better identified by means of a mild compression near the vulva and is lubricated with xylocaine gel.



**FIGURE 1** - (a) Catheter introduced 3 mm in the external urethral ostium (catheter tip 3mm inside the distal urethra); **inset**: lateral view of the removed urinary bladder and female urethra in anatomical position. (b) Catheter introduced in the urinary bladder (**dotted line**); external catheter represents the correct position in the urinary bladder; **inset**: catheter introduced 7 mm in the urinary bladder. (c) Ventral view of the abdominopelvic cavity. (d) The pubic symphysis region was dissected showing female urethra and urinary bladder. (e) Measurements of the urinary bladder (length: 8 mm) and female urethra (length: 11 mm) after alignment. **a – e**: EUO – external urethral ostium, PS – pubic symphysis, UB – urinary bladder and UR – female urethra.

The catheter was carefully introduced into the external urethral ostium by 3 mm, paralleling the distal urethra axis in a cranial to caudal direction (Figures 1a and 2a). To access the urinary bladder, the female urethra was aligned through a 180° circular caudal movement of the proximal tip of the catheter keeping static its distal tip (Figures 1b and 2b). After, the catheter was introduced 7 mm more into the urinary bladder - (Figures 1c, 1d and 2c), totaling 10 mm of insertion at this final step.



**FIGURE 2** - Fundamental Steps of Urinary Bladder Catheterization. (a) **Step 1**: endovenous catheter carefully into the external urethral ostium by 3 mm, paralleling the urethra axis in a cranial to caudal direction; **inset**: representative position of the urinary bladder and female urethra after catheter insertion in the external urethral ostium. (b) **Step 2**: alignment of the female urethra after catheter insertion in the distal 3mm of the urethra; **inset**: representative position of the endovenous catheter in the urethra - **alignment step**. (c) **Step 3**: after female urethra alignment, the catheter is introduced in the urinary bladder (7 mm), lateral view – catheter paralleling the spinal cord; **inset**: representative position of the urinary bladder and female urethra after complete catheter insertion in the bladder. **a – c**: The arrows indicate the movement of the catheter in both urethra and urinary bladder catheterization steps.



In the presented figures mice urinary bladder and urethra were stained for better identification. The urinary bladder is located in the dorso-caudal area of the abdominopelvic cavity and shows a length of 8 mm and capacity of 0.15 ml (Figures 1c, 1d and 1e). The female urethra was identified immediately ventral to the vagina and shows length of 11 mm when dissected and aligned (Figures 1c, 1d and 1e). Also, the urethra presented a horseshoe shape in the region of the pubic symphysis in its anatomical position (Figures 1a, 1d, 2a and 2b).

Due to the anatomical horseshoe shape of rodents' urethra we found the critical points for bladder catheterization were the movements to align the urethra – steps 2 and 3 (Figures 2b and 2c). In case of not progression, we realized that to remove the entire catheter and to re-start from the step 1 (Figure 2a) decreases the risk of false tracks. Catheter rotation on its own axis was a useful trick in some challenging cases. Gentle movements, catheter lubrication and the improving of technical skills after a few number of cases (short learning curve) reduced the risk of urethral injuries. On the other hand we realized that 10 mm catheter progression is enough to get the bladder and to prevent bladder perforation by the catheter tip, being 3mm for step 1 and 7mm for step 3 (Figures 2a and 2c). In the learning curve of bladder catheterization, a warning mark at 10 mm from the catheter tip is very useful; never go further.

In case of urethral bleeding or edema as well as suspicious of bladder perforation, the animal should keep at rest for at least 24 hours with subsequent evaluation.

In long term protocols in which multiple catheterizations are necessary, urethral stenosis and subsequent infection can develop, usually after trauma, requiring animal sacrifice. In some circumstances, depending on the instilled substance, bladder calculus can develop, with difficult but not precluding catheterization.

Not all but about half of animals suffering relevant urethral or bladder perforation will die in the subsequent 24 to 72 hours. After this threatening period, half of survivals will develop complications in the following catheterization due to urethral stenosis or infection and most need sacrifice. For those surviving bladder perforation, bladder defect is buffered by the greater omentum.

Utilizing clean catheters and lubricant gel is enough to avoid infection and antibiotics are not routinely utilized in the experimental protocols. Infection and complications are virtually all related to trauma and difficult catheterization.

## **Discussion**

The structure and function of rodents' lower urinary tract is remarkably similar to that of humans and both species share similar gene expression profiles suggesting that rodent would pose as an interesting experimental model compared to alternative animals. Additionally, the inbred rodents can be supplied in larger amounts and present virtually identical biological behaviors, what certainly is a virtuous advantage<sup>6</sup>.

Compared to cell cultures, a carefully orchestrated process of multiple lively sequential steps, each of which is dependent on dynamic interactions with the microenvironment, requires animal models, which are also important since require consideration of

drug delivery, pharmacokinetics and potential toxicity, mostly in bladder diseases (urothelial cancer, interstitial cystitis, etc.).

The relatively low number of cellular layers represents a short barrier for penetration of treatment into deep tissue layers. The potential of local instillation in the case of non muscle invasive bladder cancer is one of the extraordinary examples of a direct administration of therapeutics against a solid tumor<sup>6</sup>.

Nowadays, a new anti-cancer drug rise up each 3 months, presenting different mechanisms and much more specific action in specific tissues than other times. The target therapy is established in cancer treatment and needs to be checked out in action on specific proposed tissue.

The bladder catheterization described in the present study has shown to be simple to use and easy to reproduce. The procedure demands a few seconds for each animal, making it possible to use many animals in short time. One of the main advantages of this model is cheapen the costs; this method enables testing drug with smaller quantities of drugs than the other predecessors because this model was specifically mice developed, those ones did not turn the attention for this issue. In the context of new cancer drugs development, it is very important because mice are lighter around ten times than rats. Even larger species like the ferret greatly increases the costs of research into new anti-cancer drugs<sup>7</sup>.

Transurethral therapy can overcome the delivery problem and cause a breakthrough in clinical applications of certain therapeutics. Moreover, the pharmacological activity can be controlled locally and possible off-target effects should be limited to the urinary bladder and the estimated side effect would be less than that of systemic administration. Intravesical instillation of a given drug is easier to tolerate than systemic, as the drug is only contained within the environment of the urothelium.

Animals must not be repeatedly turned in order to warrant bladder exposure to the instilled substance. Once the bladder is previously evacuated and is collapsed, a very few volume (less than its 10% capacity) is enough to cover and bathe the entire bladder urothelium, acting in the whole surface; on the other hand, routinely the entire bladder capacity is instilled to limit dilution by urine.

Furthermore, the anatomical and technical knowledge for bladder catheterization opens a broaden avenue for endoscopic purposes in rodents and should be complemented using small animal imaging, such as high frequency imaging among others.

Throughout over 4 years experience with thousands of rats and mice catheterized in multiple different protocols we recently proposed an upper urothelial cancer animal model through intravesical instillation of carcinogen under pressure and utilizing an infusion volume of 130-150% of rat bladder capacity, culminating in vesicoureteral reflux of carcinogen<sup>1</sup>.

Though it is described in the literature the utilization of catheters from 24 to 18 Gauge depending on the animal size, ranging from 22 to 20 Gauge catheters for mice and rats, respectively, have rendered better results regarding easy and not traumatic catheterization.

While in the female, the reproductive products do not exit through the urethra; in the male, the urethral orifice is more difficult to visualize and urethra travels through the penis and is the passage for sperm during reproduction as well as the tract for urine at other times<sup>3</sup>.

Until now, transurethral bladder access is only possible in females and better understanding of the somewhat complex male rodent anatomy, added to catheterization technique evolution including utilization of a guide-wire as well as small animal instrumental improvements and developments may render this possible in males in the near future, expanding the tool to the male microenvironment.

### Conclusions

Although utilized in miscellaneous experimental procedures all over the world, usually brief and uninformative description of rodents' bladder catheterization prevents the necessary dissemination and wisdom of the technique. Animal models are an important field for improvement and development, which impacts directly the quality of science, once improving its tools is one of the fronts of getting better and more useful results in translational research. Urethral and bladder rodent access model has much to be improved as demonstrated by recent related anatomical, functional and technical research.

### References

1. Reis LO, Fávaro WJ, Ferreira U, Billis A, Fazuoli MG, Cagnon VH. Evolution on experimental animal model for upper urothelium carcinogenesis. *World J Urol.* 2010;28:499-505.
2. Mulder GJ, Scholtens E, Meijer DK. Collection of metabolites in bile and urine from the rat. *Methods Enzymol.* 1981;77:21-30.
3. Krinke, GJ. *The Laboratory Rat.* San Diego, CA: Academic Press. 2000.
4. Phillips JI, Davies I. The comparative morphology of the bladder and urethra in young and old female C57BL/1crfat mice. *Exp Geront.* 1980;15:551-62.
5. Andersson KE, Arner A. Urinary bladder contraction and relaxation: physiology and pathophysiology. *Physiol Rev.* 2004;84:935-86.
6. Reis LO, Pereira TC, Favaro WJ, Cagnon VH, Lopes-Cendes I, Ferreira U. Experimental animal model and RNA interference: a promising association for bladder cancer research. *World J Urol.* 2009;27:353-61.
7. Marini RP, Esteves MI, Fox JG. A technique for catheterization of the urinary bladder in the ferret. *Lab Anim.* 1994;28:155-7.

---

### Correspondence:

Leonardo Oliveira Reis  
Rua Votorantim, 51/43  
13073-090 Campinas - SP Brasil  
Tel./Fax (55 19)3521-7481  
[reisleo@unicamp.br](mailto:reisleo@unicamp.br)

Conflict of interest: none

Financial source: none

---

<sup>1</sup>Research performed at Herbert Irving Comprehensive Cancer Center, Columbia University, New York, USA.

Presented at the XII National Congress on Experimental Surgery of the Brazilian Society for Development of Research in Surgery-SOBRADPEC, 2011 October 26-29 Ribeirao Preto-SP, Brazil.