

CASE REPORT

FATAL DISSEMINATED PARACOCCIDIOIDOMYCOSIS IN A TWO-YEAR-OLD CHILD

Ricardo M. PEREIRA(1), Antonia Terezinha TRESOLDI(1), Marcus T.N. da SILVA(1) & Fábio BUCARETCHI(1)

SUMMARY

A two year-old female child was admitted at the Pediatric Intensive Care Unit in a septic shock associated with a lymphoproliferative syndrome, with history of fever, adynamia and weight loss during the last two months. On admission, the main clinical and laboratory manifestations were: pallor, jaundice, disseminated enlarged lymph nodes, hepatosplenomegaly, crusted warts on face, anemia, eosinophilia, thrombocytopenia, increased direct and indirect bilirubin, alkaline phosphatase, and gammaglutamyl transpeptidase. A parenteral administration of fluids, dobutamine and mechanical ventilation was started, without improvement of the clinical conditions. A direct examination of exsudate collected from cervical lymph node revealed numerous oval-to-around cells with multiple budding, like a “pilot wheel” cell, suggesting *Paracoccidioides brasiliensis*. Even though treatment with intravenous sulfamethoxazole-trimethoprine was soon started, the child died 36 hours after hospital admission. Disseminated paracoccidioidomycosis was confirmed in the autopsy. This is the youngest case of paracoccidioidomycosis in children reported in the literature.

KEYWORDS: Paracoccidioidomycosis; *Paracoccidioides brasiliensis*; Lymphoproliferative syndrome; Children.

INTRODUCTION

Paracoccidioidomycosis (PCM) is a fungal disease caused by the dimorphic fungus *Paracoccidioides brasiliensis*, and is considered the predominant systemic mycosis in Latin America^{5,6}. The geographic region where PCM is found stretches from Mexico to Argentina, mainly in Brazil, where 80% of the cases have been described, mainly in the southeastern and mid-western regions of the country^{6,9,17}. In comparison with adults, PCM in children is uncommon. According to some studies, only 5% of the described cases are under 14 years, most of them between 10 and 14 years old^{2,5,7-11,13-16,18,19}. Since there are no reports of PCM in children under 3 years, the aim of this study is to report a fatal disseminated PCM in a 2-year-old child.

CASE REPORT

A two-year-old female child, coming from an urban area of Mogi Guaçu, São Paulo State, was admitted at the Pediatric Intensive Care Unit/Hospital de Clínicas/Universidade Estadual de Campinas, in septic shock associated to a lymphoproliferative syndrome. She presented a two-month history of intermittent fever, adynamia, weight loss (3 kg), progressive appearance of disseminated enlarged lymph nodes and warts on the face. No respiratory complaints were reported. On admission, she was pale, normothermic, with a mild jaundice, coldness of the

extremities, a poor peripheral perfusion, a blood pressure difficult to measure (50 mmHg/30 mmHg), tachycardia (180 beats/min), tachypnea (50 breaths/min), crusted warts on the face, disseminated enlarged lymph nodes (bilateral anterior and posterior cervical, right axillary and bilateral inguinal) hardened, coalescent and without fistulization, enlargement of the liver (6 cm below the right costal margin) and of the spleen (6 cm below the left costal margin). The main laboratory features were anemia (7.1 g/dl hemoglobin), leukocytes count (5,400 cells/mm³, with 20% of eosinophils), thrombocytopenia (55,000 platelets/mm³), increased direct (1.2 mg/dL) and indirect bilirubin (1.1 mg/dL), alkaline phosphatase (1,458 IU/L) and gammaglutamyl transpeptidase (628 IU/L) levels.

She was treated with parenteral infusion of crystalloid and colloidal fluids, dobutamine, mechanical ventilation and undergone hemodynamic monitoring (CVP, MAP, HR and ECG). The direct examination of exudate collected from cervical lymph node drainage revealed numerous oval-to-round cells with multiple budding, like a “pilot wheel” cell, suggesting *P. brasiliensis*. With the hypothesis of disseminated paracoccidioidomycosis intravenous sulfamethoxazole-trimethoprim (10 mg/kg trimethoprim) was started six hours after admission. Despite these therapeutic procedures, no improvement of the clinical conditions was observed. The child died 36 hours after hospital admission, preventing the complete PCM serological investigation and fungus cultures.

(1) Departamento de Pediatria FCM/UNICAMP, Campinas, S.P., Brasil.

Correspondence to: Ricardo M. Pereira, Rua Dr. Shigeo Mori 860, Cidade Universitária, 13084-081 Campinas, São Paulo, Brasil. E-mail: ricardom.p@uol.com.br

The autopsy histological findings showed the presence of granulomatous lesions containing *P. brasiliensis* in the skin, tongue, epiglottis, several lymph nodes, liver (Fig. 1), spleen and bone marrow. Histological examination of the lungs showed hyaline membranes lining the alveoli, suggesting severe acute lung injury, without presence of fungus. Renal congestion and slightly sparse liver cell necrosis were also observed. No abnormalities were observed in adrenal glands.

DISCUSSION

This is the youngest reported case of disseminated form of PCM in children according to the literature reviewed (Medline 1966 - 2003 and LILACS 1982 - 2003).

Clinically, the PCM syndrome in children has been reported as both disseminated and localized forms. Differently from adults, where the lung involvement is common, most children with PCM present reticuloendothelial system involvement, characterized as a febrile lymphoproliferative syndrome^{2,4,6,7,9}. In addition, children older than 10 years tend to present greater involvement of the osteoarticular and tegument systems than children under this age. Younger children are likely to present a more frequent liver and spleen involvement^{2,4,7,8,10,11}. Gastrointestinal tract, bone marrow, adrenal gland, testis, brain, kidney

and heart are occasionally involved^{1,14,19}. According to the greatest pediatric clinical series of PCM retrospectively reviewed (N = 52, 1944-1974), the lethality rate was 7.7%¹⁴. Our group have followed, from 1980 to nowadays, 63 children infected with *P. brasiliensis*, including the child herein reported, 93.9% of them with disseminated forms, with a lethality rate of 10% (being submitted, 2003).

While in adults, males are more commonly afflicted than females, at a mean ratio of 10:1, PCM affects children in the same ratio in both sexes^{5,6}. It has been postulated that the female hormones or immunological factors dependent of these hormones could offer a natural protection against this fungal disease⁶.

The non-specific main laboratory changes more frequently reported in children with PCM are anemia, eosinophilia, hypergammaglobulinemia, hypoalbuminemia, increased alkaline phosphatase levels and elevated erythrocyte sedimentation rate^{9,11,13}. The abnormal liver function tests observed in this case, suggesting cholestasis, could be related to extrinsic obstruction of bile ducts by lymph nodes, liver cell necrosis and the effects of septic inflammatory response²⁰. Unfortunately, in this patient, the overwhelming outcome of the septic syndrome prevented the realization of a thorough immunologic investigation, including HIV and PCM serological screens.

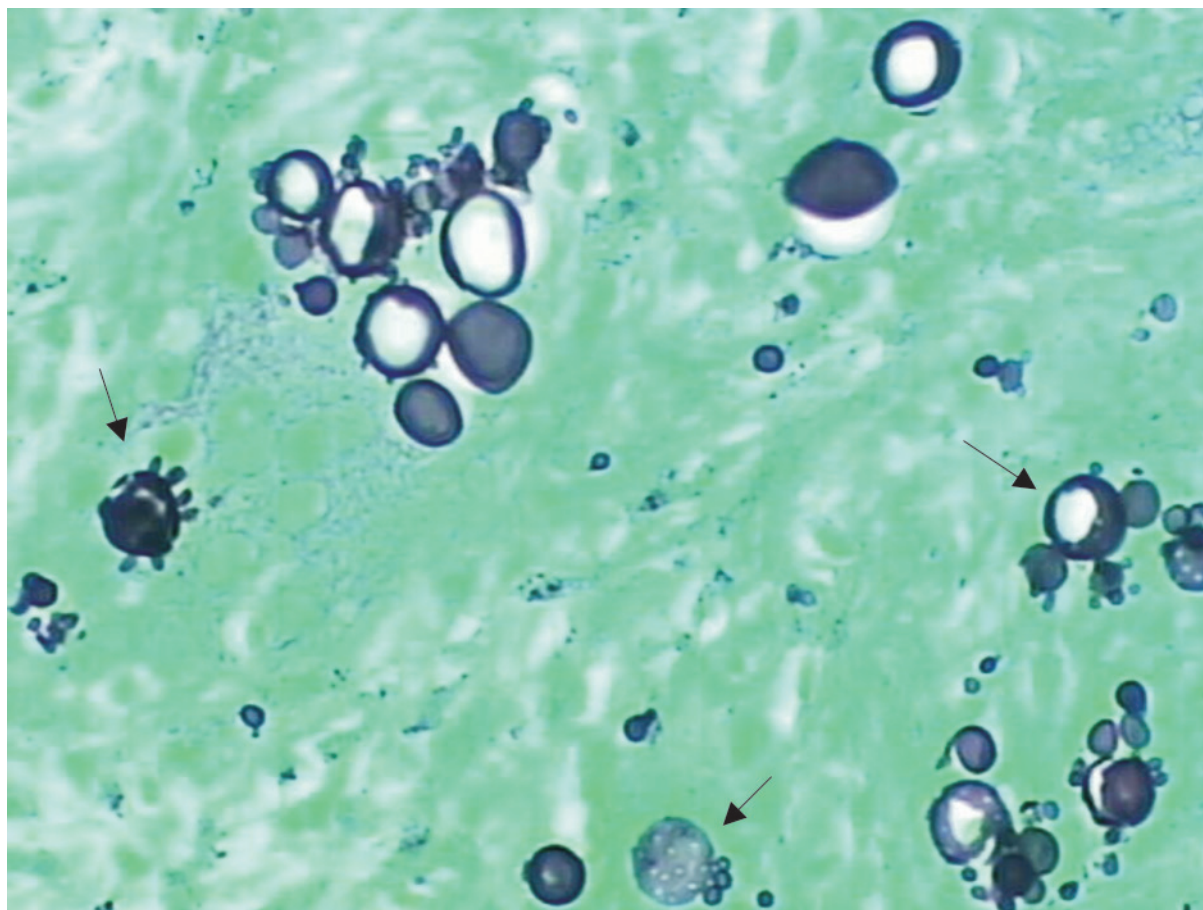


Fig. 1 - Numerous oval-to-round cells with multiple budding (arrows) in liver (Grocott stain 200X).

The PCM pathogenesis has still not been established. On the other hand, it has been accepted that PCM results from and/or triggers a decrease of the cellular defense mechanisms, increasing the risk of severe systemic infections^{1,3,6}. However, in this case, it is reasonable to suppose that the septic syndrome was directly related to *P. brasiliensis* infection, as already described elsewhere^{1,3}. This inference is supported by the negative findings of bacterial pathogens on the blood cultures (two samples) and the autopsy findings of disseminated fungal yeast forms.

The clinical presentation of disseminated histoplasmosis is quite similar to PCM. Although much more rare than PCM in children in Brazil, this etiology should be considered in the differential diagnosis¹². The morphological aspects of fungus collected from direct examination plus necropsy histological features discharged this diagnosis.

PCM in children is very uncommon under the age of seven. However, this diagnosis should be reminded in children with febrile lymphoproliferative syndrome associated with anemia, eosinophilia and hypergammaglobulinemia, living in endemic areas. In these cases, mainly in the severely ill children, an empirical treatment with intravenous amphotericin B, should be considered while the specific laboratory studies (direct examination, histological studies, cultures and/or serologic tests) are being performed. Since this child was very young in order to consider PCM as the main diagnosis of septic shock upon admission, amphotericin B was not soon started. In addition, we have obtained good results in the treatment of 15 children with severe disseminated forms of PCM, treated exclusively with intravenous sulphamethoxazole-trimethoprim (being submitted, 2003).

RESUMO

Paracoccidioidomicose disseminada fatal em criança de dois anos

Uma menina de dois anos foi internada em Unidade de Terapia Intensiva com o diagnóstico de choque séptico associado a síndrome linfoproliferativa febril, adinamia e perda de peso nos últimos dois meses. Na admissão, as principais manifestações clínicas e laboratoriais eram: palidez, icterícia, aumento ganglionar em todas as cadeias superficiais, hepatoesplenomegalia, lesões crostosas em face, anemia, eosinofilia, plaquetopenia, elevação de bilirrubina indireta e direta, de fosfatase alcalina e de gama glutamil transferase. A terapêutica instituída foi infusão de fluidos, dobutamina e ventilação mecânica, sem melhora das condições clínicas, seguido da introdução de sulfametoxazol-trimetoprima. O exame direto do linfonodo revelou numerosas estruturas ovaladas, com múltiplos brotamentos, como “roda de leme” sugerindo *Paracoccidioides brasiliensis*. A paciente evoluiu para o óbito 36 horas após a internação. Paracoccidioidomicose disseminada foi confirmada na necropsia. Trata-se do caso mais jovem de paracoccidioidomicose reportado na literatura consultada.

REFERENCES

1. AZULAY, R.D.; VELLOSO, M.B.; SUGUIMOTO, S.Y.; ISHIDA C.E. & PEREIRA JUNIOR, A.C. - Acute disseminated paracoccidioidomycosis. Septic shock. *Int. J. Derm.*, **27**: 510-511, 1988.
2. BARBOSA, G.I. - Paracoccidioidomicose na criança. *Rev. Pat. trop.*, **21**: 269-383, 1992.

3. BERNARD, G.; ORII, N.M.; MARQUES, H.H.S. *et al.* - Severe acute paracoccidioidomycosis in children. *Pediat. infect. Dis. J.*, **13**: 510-515, 1994.
4. BITTENCOURT, A.L.; FREIRE de ANDRADE, J.A. & FILHA, S.P. - Paracoccidioidomycosis in a four-year-old boy. *Mycopathologia (Den Haag)*, **93**: 55-59, 1986.
5. BLOTTA, M.H.S.L.; MAMONI, R.L.; OLIVEIRA, S.J. *et al.* - Endemic regions of paracoccidioidomycosis in Brazil: a clinical and epidemiologic study of 584 cases in the southeast region. *Amer. J. trop. Med. Hyg.*, **61**: 390-394, 1999.
6. BRUMMER, E.; CASTANEDA, E. & RESTREPO, A. - Paracoccidioidomycosis: an update. *Clin. Microbiol. Rev.*, **6**: 89-117, 1993.
7. CASTRO, R.M. & DEL NEGRO, G. - Particularidades clínicas da paracoccidioidomicose na criança. *Rev. Hosp. Clín. Fac. Med. S. Paulo*, **31**: 194-198, 1976.
8. FARHAT, C.K.; RAIMUNDO, M.E.C.; GASPAR, J.M. *et al.* - Paracoccidioidomicose na criança: relato de dois casos. *J. Pediat. (Rio de J.)*, **60**: 226-231, 1986.
9. FERREIRA, M.S. - Contribuição para o estudo clínico-laboratorial e terapêutico da formação juvenil da paracoccidioidomicose. *Rev. Pat. trop.*, **22**: 267-406, 1993.
10. FONSECA, E.R.S.; PARDAL, P.P.O. & SEVERO, L.C. - Paracoccidioidomycosis in children in Belém, Pará State, Brazil. *Rev. Soc. bras. Med. trop.*, **32**: 31-33, 1999.
11. HILDEBRANDO, T.M.; ROSÁRIO FILHO, N.A.; TELLES FILHO, F.Q. *et al.* - Paracoccidioidomicose na criança. Aspectos clínicos e laboratoriais em 25 casos. *J. Pediat. (Rio de J.)*, **63**: 92-97, 1987.
12. LEISSA, B. & WIEDERMANN, B.L. - Histoplasmosis. In: FEIGIN, R.D. & CHERRY, J.D., ed. *Textbook of pediatric infectious diseases*. Philadelphia, W.B. Saunders, 1992. p. 1952-1964.
13. LONDERO, A.T.; GONÇALVES, A.J.R.; TERRA, G.M.F. & NOGUEIRA, S.A. - Paracoccidioidomycosis in Brazilian children: a critical review (1911-1994). *Arq. bras. Pediat.*, **4**: 128-137, 1997.
14. LONDERO, A.T. & MELO, I.S. - Paracoccidioidomycosis in childhood. A critical review. *Mycopathologia (Den Haag)*, **82**: 49-55, 1983.
15. MARTINS, R.M.; MARQUES, J.L.O.; GARCEZ, I.C.S. *et al.* - Paracoccidioidomicose: relato de caso em criança de três anos de idade com forma disseminada. *J. Pediat. (Rio de J.)*, **61**: 319-322, 1986.
16. OCHOA, M.T.; FRANCO, L. & RESTREPO, A. - Características de la paracoccidioidomicosis infantil: informe de cuatro casos. *Medicina U.P.B. (Medellín)* **10**: 97-108, 1991.
17. PANIAGO, A.M.M.; AGUIAR, J.I.A.; AGUIAR, E.S. *et al.* - Paracoccidioidomicose: estudo clínico e epidemiológico de 422 casos observados no estado do Mato Grosso do Sul. *Rev. Soc. bras. Med. trop.*, **36**: 455-459, 2003.
18. ROSÁRIO FILHO, N.A.; TELLES FILHO, F.Q.; COSTA, O. & MARINONI, L.P. - Paracoccidioidomycosis in children with different skeletal involvement. *Rev. Inst. Med. trop. S. Paulo*, **27**: 337-340, 1985.
19. TERRA, G.M.F.; RIOS-GONÇALVES, A.J.; LONDERO, A.T. *et al.* - Paracoccidioidomicose em crianças. Apresentação de casos. *Arq. bras. Med.*, **65**: 8-15, 1991.
20. THIJIS, L.G.; GROENEVELD, A.B.J. & HACK, C.E. - Multiple organ failure in septic shock. In: RIETSCHEL, E.T. & WAGNER, H., ed. *Pathology of septic shock: current topics in microbiology and immunology*. Berlin, Springer, 1997. p. 211-237.

Received: 15 August 2003

Accepted: 11 December 2003