

CLINICAL SCIENCES

ENDOSCOPIC STUDY OF THE INTRANASAL OSTIUM IN EXTERNAL DACRYOCYSTORHINOSTOMY POSTOPERATIVE. INFLUENCE OF SALINE SOLUTION AND 5-FLUOROURACIL

Marilisa Nano Costa, Ana Maria Marcondes, Eulalia Sakano, Newton Kara-José

Costa MN, Marcondes AM, Sakano E, Kara-José N. Endoscopic study of the intranasal ostium in external dacryocystorhinostomy postoperative. Influence of saline solution and 5-fluorouracil. Clinics. 2007;62(1):41-6.

PURPOSE: To study, through endoscopy, the postoperative structural changes of the intranasal ostium following external dacryocystorhinostomy and to evaluate the influence of saline solution and 5-fluorouracil.

METHODS: Fifty patients were distributed into the following groups: Group SS—dacryocystorhinostomy and an injection of saline solution during surgery (13 patients); Group 5-FU1—dacryocystorhinostomy and an injection of 5 fluorouracil during surgery (17 patients); Group C—dacryocystorhinostomy only (11 patients); Group 5-FU3—dacryocystorhinostomy and 3 injections, 1 during surgery and 1 on the third and fifth postsurgical days (9 patients).

RESULTS: Pair-wise group comparisons using the nonparametric Mann-Whitney test revealed that there was a significant reduction of the ostium area only in Group 5-FU1 vs. Group SS on the 60th postoperative day ($P < .01$); however, a comparative study among the 4 groups using the Kruskal-Wallis test showed no significant changes in the ostium area on the 60th postoperative day. The ostium area within groups at the 30th vs 60th postoperative day was significantly reduced for Group C ($P < .05$; Mann-Whitney test); no significant changes were found for the other groups.

DISCUSSION: These results suggest that the use of 5-fluorouracil in external dacryocystorhinostomy does not significantly influence the final size of the surgical fistula as determined 2 months postsurgery.

KEYWORDS: Fluorouracil. Dacryocystorhinostomy. Endoscopy. Dacryocystitis.

INTRODUCTION

Dacryocystorhinostomy is a surgical technique in which an anastomosis is made between the lacrimal sac and the nasal cavity. It is indicated for most of chronic dacryocystitis. The percentage of success with dacryocystorhinostomy presented by several authors is usually greater than 90%, regardless of the surgical technique used.^{1,2}

In spite of technical advances, recurrences may occur within 4 to 6 weeks after surgery.³ Anatomic conditions and

affections that may lead to lack of success include a small lacrimal sac and ethmoid cells in the bone trepanation area,⁴ Paget's disease,⁵ sarcoidosis,⁶ nasal fracture, medium turbinate hypertrophy, septal deviation, and nasal cavity synechia.⁷

The most frequent postoperative conditions associated with recurrences are obstruction of the intranasal ostium by healing or granulation tissue, nasal cavity synechia,⁸ inadequate size and position of the osteotomy,⁹ mucosa flap fall,⁷ and incomplete lacrimal sac opening.¹⁰

In dacryocystorhinostomy, several materials, such as a polyethylene tubing,¹¹ silicone sponge,¹² silicone tubing,² and absorbable gelatin sponge,¹³ have been used in the anastomosis to prevent ostium obstruction by healing or granulation tissue.

State University of Campinas – Campinas/SP – Brasil.

Email: m.nano@uol.com.br

Received for publication on September 22, 2006.

Accepted for publication on October 16, 2006.

At the time of writing, antimetabolites are frequently used when treating a number of ocular pathologies characterized by the proliferation of non-neoplastic cells; 5-fluorouracil (5-FU) is one of such drugs, because it has a powerful inhibitory effect on mitosis. Responses are generally good when compared to other antimetabolites and 5-FU has been shown to have a powerful inhibitory effect on growing fibroblasts.¹⁴

The Fluorouracil Filtering Surgery Study Group (FFSS), formed in the United States in 1989, evaluated the results of trabeculectomy with the use of subconjunctival 5-FU. Subconjunctival 5-FU injections were recommended after trabeculectomy in patients with uncontrolled glaucoma with poor prognosis, especially with aphakic glaucoma, and in patients with previous surgical failure.¹⁵ The FFSS concluded after 5 years of follow-up that 5-FU greatly improves the surgical prognosis of trabeculectomy.¹⁶ Use of 5-FU is a safe and effective method by which a significant number of failing filtration blebs can be rescued from failure.¹⁷

This study aimed at studying, through endoscopy the postoperative structural changes of the intranasal ostium that take place following external dacryocystorhinostomy, as well as to evaluate the influence of the use of saline solution versus 5-FU on the evolution of the ostium, seeking a complementary alternative for the treatment of dacryocystitis with a poor prognosis.

MATERIALS AND METHODS

Patients with dacryocystitis were selected from the Ophthalmology Clinic of the State University of Campinas Clinic Hospital (Brazil). The hospital's Ethics Commission approved the research protocol.

Ophthalmologic, clinical, laboratory, and nasal endoscopy exams were performed for all the patients before the surgery. Patients with nasal affections, such as severe septal deviation, turbinate hypertrophy, nasal fractures, and other lacrimal system problems, were excluded from the study.

Fifty patients underwent external dacryocystorhinostomy associated with the use or not of 5-FU. We adopted the surgical technique that uses only 2 anterior flaps from the lacrimal sac mucosa and the nasal mucosa, respectively. We standardized the size of the osteotomy at 10 mm for all the patients. The suture of the mucosa flaps was done with vycryl 5-0, and the stitches were placed at an adjacent subcutaneous tissue level to prevent the flaps from falling.

Patients were randomly distributed into 4 groups as follows: Group SS—dacryocystorhinostomy and an injection of saline solution during the surgery (13 patients); Group 5-FU1—dacryocystorhinostomy and an injection of 5-FU

during the surgery (17 patients); Group C—dacryocystorhinostomy only (11 patients); Group 5-FU3—dacryocystorhinostomy and 3 injections of 5-FU, 1 injection during surgery and 1 on the third and fifth postoperative days (9 patients).

Preparation of the solution for Group 5-FU1 prior to the surgery was as follows: 1 mL of 5-FU (250 mg/10 mL) was added to 4 mL of 0.9% saline solution; 0.50 mL (2.5 mg) of this solution was injected into the nasal mucosa at the end of the surgery. The saline solution used in this preparation was also used for Group SS. At the end of the surgical procedure, 0.50 mL of the appropriate solution was injected into the nasal mucosa beside the inferior edge of the ostium with an insulin syringe and needle.

The solution for Group 5-FU3 was prepared as follows: 4 mL of 5-FU (250 mg/10 mL) was added to 6 mL of 0.9% saline solution, and 0.50 mL (5 mg) was injected as previously described into the nasal mucosa at the end of surgery. The same dose was repeated in the third and fifth postoperative days. For those postoperative treatments, 10% Xylocaine spray was administered as the topical anesthetic, and subsequently, the 5-FU solution was injected into the nasal mucosa using a 30-gauge needle and an insulin syringe into the same area where it had been injected during the surgical procedure. The total dose used over the 3 injections was 15 mg.

The patients were examined on the 7th, 30th, and 60th postoperative days, when they underwent ophthalmologic, probe, and irrigation exams of the lacrimal system, as well as endoscopic evaluation of the surgical area of the nasal cavity. We performed vertical and horizontal measurement of the ostium with an L measurer divided into millimeters on one side (Figure 1). A rigid Hopkins telescope of 4 mm diameter and with a 30° optical axis (Storz model) was used, which allowed clear viewing of the nasal cavity. Endoscopy was performed on the patients in the dorsal decubitus position after topical anesthesia with nasal packing

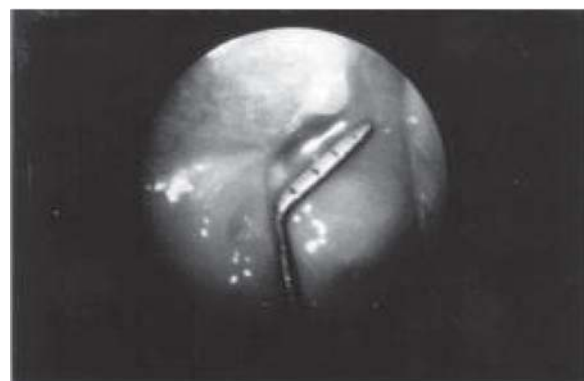

Figure 1 - Surgical ostium - measurement of the vertical diameter with a L measurer

soaked in 2.5% neotutocaine solution with 1/1000 adrenaline. In order to evaluate the dimensions of the surgical ostium, an approximate calculation of the area was performed based on the predominant shape found at endoscopy. The determination of the area was based on the formula for the calculation of an elliptic area: $A = r/4 \times V \times H$, using the measurement of 2 opposed diameters of the ostium (Figure 1). By convention, the horizontal diameter (H) was the one parallel to the lacrimal sac, and the vertical diameter (V) was the one perpendicular to the first one.

The ostium area on the 60th postoperative day was compared among the 4 groups using the nonparametric Kruskal-Wallis test. Pair-wise comparisons between groups regarding the area of the ostium on the 60th postoperative day were using the nonparametric Mann-Whitney test. Within-group changes at the 30th vs 60th postoperative day were tested with the nonparametric Mann-Whitney test. A *P* value less than .05 was taken to indicate a significant difference.

RESULTS

Endoscopic evaluation

The incidence of nasal mucosa flap fall was as follows: 1 case (7.7%) in Group SS, 10 cases (59%) in Group 5-FU1, 3 cases (27%) in Group C, and 5 cases (56%) in Group 5-FU3. In none of the cases was there a fall of the entire flap with occlusion of the surgical ostium.

An oval ostium shape predominated in all the groups as follows: 10 cases (77%) in Group SS, 8 cases (47%) in Group 5-FU1, 10 cases (91%) in Group C, and 5 cases (56%) in Group 5-FU3. The remaining cases presented a round ostium shape.

The comparative study between the 4 groups using the Kruskal-Wallis test did not show significant changes on the 60th postoperative day; however, the pair-wise comparisons revealed that the ostium area of Group SS was significantly larger than that of Group 5-FU1 (*P* < .01, Mann-Whitney test) (Figure 2).

Regarding changes in the ostium area between the 30th and the 60th days, an increase of the ostium area occurred in 3 cases (23%) in Group SS (SS), 5 cases (29%) in Group 5-FU1, 1 case (9.1%) in Group C, and 3 cases (33%) in Group 5-FU3. A decrease in the ostium area was observed in 4 cases (31%) in Group SS, 9 cases (53%) Group 5-FU1, 1 case (9.1%) in Group C, and 3 cases (33%) in Group 5-FU3; There was no change in the ostium area for 12 cases as follows: 6 cases (46%) in Group SS, 3 cases (18%) in Group 5-FU1, 1 case (9.1%) in Group C, and 2 cases (22%) in Group 5-FU3. The change in area from the 30th to the

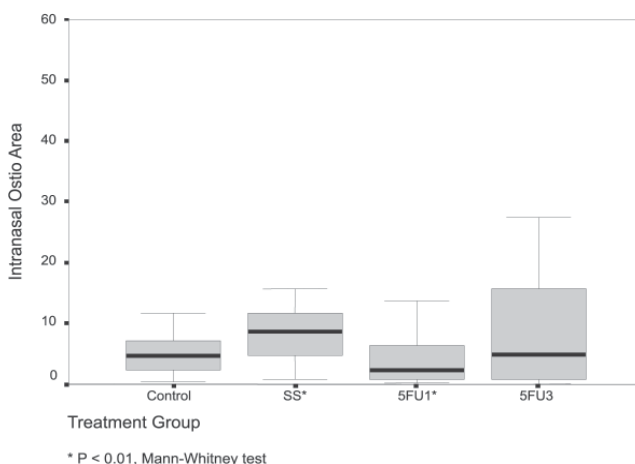


Figure 2 - The graph shows the postoperative intranasal ostium areas by treatment group on the 60th postoperative day

60th postoperative day was significantly reduced only in Group C (*P* < .05, Mann-Whitney test) (Figure 3). No other significant differences were found regarding this parameter.

Granulation tissue was present at the intranasal ostium level in all the groups as follows: 6 cases (46%), 10 cases (59%), 3 cases (27%), and 3 cases (33%) in Groups SS, 5-FU1, C, and 5-FU3, respectively. Extraction of the granulation tissue was performed only in symptomatic patients with an ostium blockage that impeded lacrimal drainage as follows: 3 cases in Group SS, 4 cases in Group 5-FU1, and 1 case in Group 5-FU3. In all of these cases there was epiphora and disappearance of secretion.

Persistent epiphora was observed in 4 patients. The endoscopic evaluation in the first week showed the presence of a bone fragment in the surgical fistula in 1 of these cases (Group C), which was removed on the same occasion. In another symptomatic patient, a patent lacrimal system was

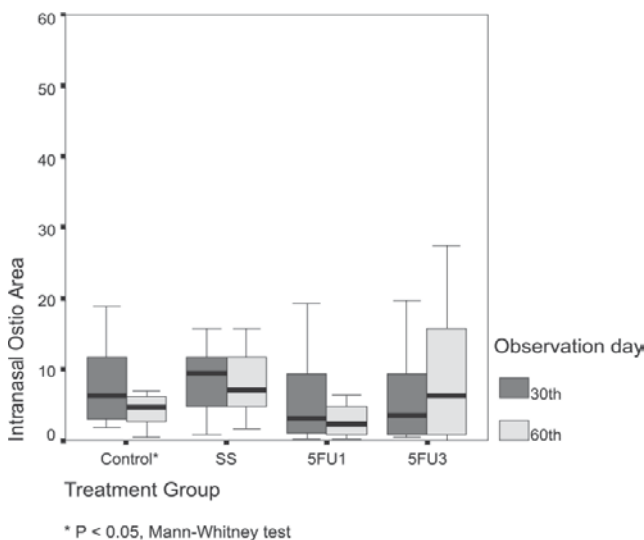


Figure 3 - The graph describes the ostium area at the 30th vs 60th postoperative day, by treatment group

observed. We suspected that the lacrimation was due to a maxillary sinusitis, since the endoscopy showed the presence of secretion from the main ostium of the maxillary sinus. In the other 2 cases, we observed a concentric increase of healing tissue that greatly decreased the size of the ostium in one of the patients (Group 5-FU1), and completely occluded it in the other (Group 5-FU3).

Comparing the number of flap falls among the several groups (Figure 4), there were no significant differences during the observation period. When the data was reorganized into 3 categories (saline solution, control, and 5-FU; Figure 5), there were significantly more flap falls in the 5-FU group compared to saline solution group (Group SS) (Mann-Whitney test, $P < .01$).

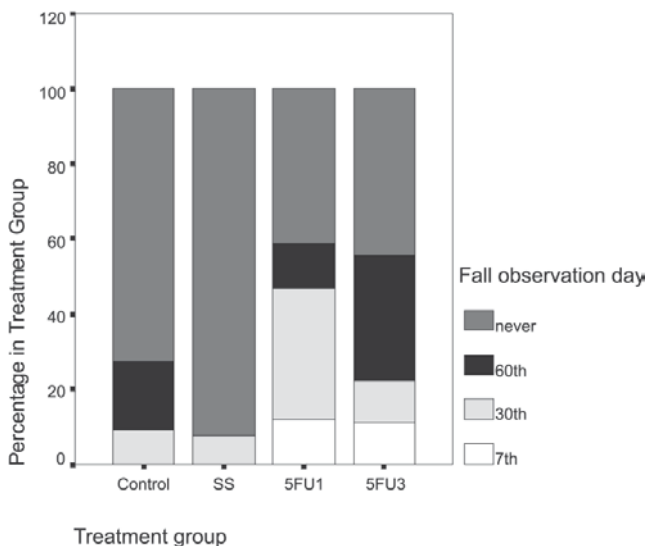


Figure 4 - Percentage of flap falls on 7th, 30th, and 60th days after surgery, by 4 groups (C, SS, 5-FU¹, and 5-FU³)

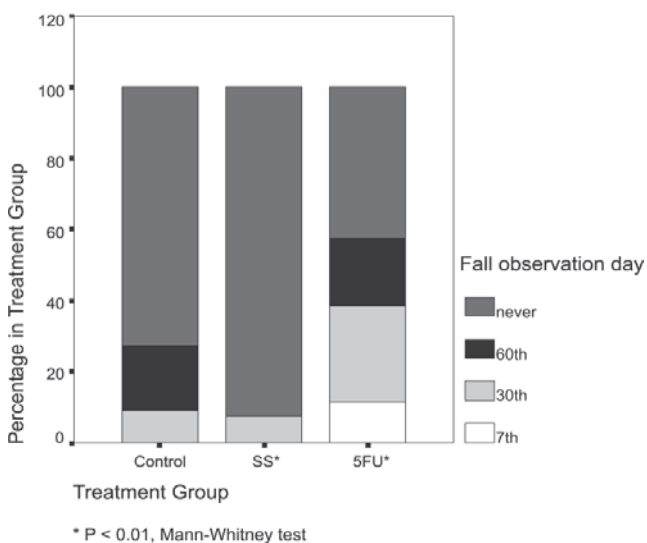


Figure 5 - Percentage of flap falls on 7th, 30th, and 60th postoperative day, by 3 groups (C, SS, and 5-FU)

There was no significant difference concerning the occurrence of granulation tissue among the groups ($P = .361$).

Among the 50 patients who underwent dacryocystorhinostomy, only 1 experienced a total ostium occlusion by the healing tissue, and there was persistent epiphora in 2 others. The presence of ostium with a much-reduced area was observed for these last cases.

No nasal, ocular, or systemic complications from the use of 5-FU were observed in this study.

DISCUSSION

In this study, the size of the final surgical ostium was always smaller than the initial surgical orifice. This result is similar to that of Linberg et al,¹⁸ who showed that an ample osteotomy did not necessarily result in a larger intranasal ostium. Those authors attributed the reduction of the ostium area to the contracture of the wound during the healing process. Although in the present study the size of the osteotomy was the same in all the patients, there was great variation of the ultimate intranasal ostium among the subjects of the same group, suggesting the presence of several factors that could influence the final result.

The distinct decrease in the healed intranasal ostium area when compared to the surgical opening is not surprising, considering normal healing processes. Ross¹⁹ described the stages of the healing process as follows: hemostasis, inflammation, and remodeling. The healing contracture takes place during the last stage of the process.

If the size of the final ostium is related to the healing process, it is valid to assume that the use of a drug that inhibits fibroblast proliferation would result in a larger ostium area. The option to use 5-FU was based on the fact that these antimetabolites have produced positive results in ocular surgeries, when the main objective is to interfere with the healing process.

A single dose of 5-FU has been shown to be effective in the treatment of massive periretinal proliferation, as is shown in the experimental work of Blumenkrans et al.²⁰ This antimetabolite has also been used to improve surgical prognosis in the eyes of human patients with glaucoma.¹⁵ Until 1989, most researchers used a 105-mg dose in patients with high-risk glaucoma; later, reduced dosages were used, producing similar results with much fewer side effects.^{21;22} The occurrence of a flap fall in the 5-FU groups occurred regardless of the dosage and the frequency of dosing. Flap falls have been cited as the cause of recurrence, as they block the surgical ostium.⁷ Endoscopy showed that the flap could partially return to the nasal mucosa plane. A complete flap fall was not present in any of the cases.

Kao et al²³ observed that the ostium area was signifi-

cantly reduced in patients in whom only endonasal dacryocystorhinostomy was performed, compared to those that also received an intrasurgical injection of mitomycin. The authors concluded that this was due to the use of the antimetabolite. The evaluation via helical computed tomographic dacryocystography of the effect of intrasurgical mitomycin in patients undergoing external dacryocystorhinostomy revealed that the use of this antimetabolite resulted in larger ostium areas.²⁴ In contrast, in the present study, the results obtained at the 60-day follow-up evaluation revealed that the ostium area was distinctly larger in patients receiving a saline solution injection than in patients receiving a 5-FU injection. Additionally, the number of flap falls of the nasal mucosa was less frequent in patients receiving a saline injection compared to those receiving 5-FU injections.

Group C (control group) presented the natural evolution of the ostium using the technique of 2 anterior flaps, characterized by the consistent occurrence of a distinct decrease in area of the surgical ostium as well as the occurrence of flap falls. Since all possible determinant causes of the flap fall, such as the use of quickly absorbing thread and inadequate fixation of sutures, were avoided, the most probable causes of this occurrence were the growing and thickening of the healing tissue or the partial return of the nasal mucosa to its original position.

The number of nasal mucosa flap falls was significantly greater in the groups receiving 5-FU injections compared to the group receiving a saline solution injection. The proportion of flap falls in the Group C was smaller than that in the 5-FU groups and larger than that in Group SS; however, this variation was not statistically significant.

The within-group evaluation showed that the decrease

in the area between the 30th and 60th postoperative days was statistically significant only in Group C. This finding indicates that the smaller decrease in area could be the influence of the mechanical factor of the injection, rather than the effect of 5-FU.

In the present study, the endoscopic evaluation revealed that the occurrence of epiphora was not related to the ostium size.

We can assume that in the 2 symptomatic cases in which the lacrimal pathway was patent, a much reduced ostium area could have hindered the proper lacrimal drainage in these patients. The persistence of a bone fragment in the surgical area and the presence of ethmoid cells in the osteotomy area that were observed in these cases could have caused the healing exacerbation, significantly decreasing the ostium. In the only case where there was complete surgical ostium occlusion, the presence of ethmoid cells during the surgery was verified. According to Picó,⁴ ethmoid cells constitute anatomic variations that predispose surgical failure.

Endoscopy was crucial for clearing up persistent epiphora, providing information for correct diagnosis and treatment. Good results were obtained with the removal of granulation tissue or hematic crust that was blocking the central ostium area.

According to Piaton et al²⁵ and Bakri et al,²⁶ the use of 5-FU in patients undergoing laser dacryocystorhinostomy did not improve the surgical prognosis compared to the results obtained with patients who underwent only the surgical treatment. Accordingly, the results of this study indicate that the use of 5-FU in external dacryocystorhinostomy is also without a significant influence in the final size of the surgical fistula at the 60 days postsurgery.

RESUMO

Costa MN, Marcondes AM, Sakano E, Kara-José N. Estudo endoscópico do óstio intranasal no pós-operatório de dacriocistorrinostomia externa e influência do uso de solução salina e de 5 fluorouracil. Clinics. 2007;62(1):41-6.

OBJETIVO: Estudar, através da endoscopia, as alterações estruturais pós-operatórias do óstio intranasal na dacriocistorrinostomia externa, e avaliar a influência da solução salina e do 5 fluorouracil.

MÉTODOS: Cinquenta pacientes foram distribuídos nos seguintes grupos: Grupo SS— 13 pacientes submetem-se à dacriocistorrinostomia com uso de solução salina; Grupo 5-FU1- 17 pacientes submetem-se à dacriocistor-

rinostomia e injeção de 5 fluorouracil; Grupo C—11 pacientes submetem-se apenas à dacriocistorrinostomia; Grupo 5-FU3- 9 pacientes submetem-se à dacriocistorrinostomia associada a três injeções de 5 fluorouracil.

RESULTADOS: A comparação pareada pelo teste não paramétrico de Mann-Whitney revelou redução significativa da área do óstio apenas na comparação Grupo 5-FU1 vs. Grupo SS, no 60° dia após a cirurgia ($P < .01$). No entanto, um estudo comparativo entre os 4 grupos usando o teste de Kruskal-Wallis não revelou diferenças significativas na área do óstio no 60° dia após a cirurgia. Na comparação intra-grupos, a área do óstio no 30° vs 60° dia após a cirurgia mostrou redução significativa para o Grupo C

($P < .05$; teste de Mann-Whitney); nenhuma outra comparação apresentou diferenças significativas.

DISCUSSÃO: O resultado deste estudo sugere que o uso de 5 fluorouracil na dacriocistorrinostomia externa não influencia significativamente no tamanho final da fístula ci-

rúrgica durante os dois meses de avaliação.

UNITERMOS: Fluorouracil. Dacriocistorrinostomia. Endoscopia. Dacriocistite.

REFERENCES

1. Dupuy-Dutemps L, Bourguet J. Procédés plastiques des dacryocystorhinostomies. *Ann Oculist.* 1921;159:241-61.
2. Older J. Routine use of a silicone stent in a dacryocystorhinostomy. *Ophthalmic Surg.* 1982;13:911-15.
3. Dayal Y. External dacryocystorhinostomy. *Am J Ophthalmol.* 1961;51:514-17.
4. Picó G. A modified technique of external dacryocystorhinostomy. *Am J Ophthalmol.* 1971;72:679-90.
5. Hurwitz J. Failed dacryocystorhinostomy in Paget's disease. *Can J Ophthalmol.* 1979;291-3.
6. Weingarten R, Goodman E. Late failure of a dacryocystorhinostomy from sarcoidosis. *Ophthalmic Surg.* 1981;12:343-6.
7. Costa M, Sakano E. O valor da endoscopia nasal na semiologia lacrimal. *Arq Brás Oftalmol.* 1989;52:140.
8. Bosshard C. Endoskopie der nase als hilfe furdie Tranenwegs chirurgie. *Klin Monatsbl Augenheilkd.* 1982;180:303-7.
9. Vergez A, Herbert F. A propos de la dacryocystorhinostomie. *Bull Soc Ophtalmol.* 1978;273-6.
10. Welham R, Henderson P. Results of dacryocystorhinostomy analysis of causes for failure. *Trans Ophthalmol.* 1973;93:601-9.
11. Huggert A, Sundmark E. Treatment of lacrimal obstruction. *Am J Ophthalmol.* 1965;60:603-10.
12. Mirabile T, Tucker C. Dacryocystorhinostomy with silicone sponge. *Arch Ophthalmol.* 1979;74:235.
13. Leone C. Gelfoam-thrombin dacryocystorhinostomy stent. *Am J Ophthalmol.* 1982;94:412.
14. Blumenkranz M, Clafin A. Selection of therapeutic agents for intraocular proliferative disease: cell culture evaluation. *Arch Ophthalmol.* 1984;102:598-604.
15. The Fluorouracil Filtering Surgery Study Group. Fluorouracil filtering surgery study one-year follow-up. *Am J Ophthalmol.* 1989;108:625-35.
16. Fluorouracil Filtering Surgery Study Group. Five year follow-up of the Fluorouracil Filtering Surgery Study Group. 1996;121:349-66.
17. Broadway C, Jones N, Bunce C, Thiagarajan M, Khan T. Needle revision of failing and failed trabeculectomy blebs with adjunctive 5-fluorouracil: survival analysis. 2004;111:664-73.
18. Linberg J, Anderson R, Bumsted R. Study of intranasal ostium external dacryocystorhinostomy. 1982;100:1758-62.
19. Ross R. Wound healing. *Sci Am.* 1969;220:40-50.
20. Blumenkranz M, Ophir A, Clafin A, Hajek A. Fluorouracil for the treatment of massive periretinal proliferation. *Am J Ophthalmol.* 1982;94:458-67.
21. Jampel H. Trabeculectomy with 5-fluorouracil for adult inflammatory glaucoma. *Am J Ophthalmol.* 1990;109:168-73.
22. Krug J, Melamed S. Adjunctive use of delayed and adjustable low dose 5-fluorouracil in refractory glaucoma. *Am J Ophthalmol.* 1990;109:412-18.
23. Kao C, Liao L, Tseng H, Chen S, Houk K. Dacryocystorhinostomy with intra-operative mitomycin. 1997;104:86-91.
24. Gonzalvo J, Fuertes I, Fernandez J, Hernandez G, Rabinal F, Honrubia M. External DCR with mitomycin: clinical and anatomical evaluation with helical computed tomography. *Arch Soc Esp Oftalmol.* 2000;75:611-7.
25. Piaton J, Keller P, Limon S, Quenot S. Revision of failed dacryocystorhinostomy using the transcanalicular approach. Results of 118 procedures. *J Fr Ophtalmol.* 2000;24:265-73.
26. Bakri K, Jones N, Downes R, Sadiq S. Intraocular fluorouracil in endonasal laser dacryocystorhinostomy. *Arch Otolaryngol Head Neck Surg.* 2003;127:233-5.