

## CYSTICIDAL THERAPY

### IMPACT ON SEIZURE CONTROL IN EPILEPSY ASSOCIATED WITH NEUROCYSTICERCOSIS

ISABEL CRISTINA DOS SANTOS, ELIANE KOBAYASHI, TÂNIA MARCHIORI CARDOSO,  
CARLOS ALBERTO MANTOVANI GUERREIRO, FERNANDO CENDES

**ABSTRACT - Objective:** To evaluate the clinical features and seizure control of epilepsy related to neurocysticercosis. **Method:** 18 patients with partial epilepsy and neurocysticercosis were treated with albendazol or praziquantel and followed from 3 months to 12 years. We analyzed results from the CSF exam, interictal electroencephalogram (EEG), head computerized tomography and/or magnetic resonance imaging. **Results:** The patients' mean age was 36.4 years. The mean duration of epilepsy was 16 years. 83% patients had simple partial seizures; 17% had complex partial seizures. All patients underwent routine EEGs: 62% had abnormalities and 38% were normal. A relationship was observed between focal EEG abnormality and the location of cyst in 28% of the patients. The CSF exams showed pleocytosis in 33% of the patients, and 28% had elevated protein levels. Only 22% of patients had positive titer for cysticercosis in the CSF. In all patients who had somatosensory and special sensory seizures there was a relationship between location of the cysts and seizure semiology (n=11). After cysticidal therapy, 83% patients had a significant improvement in controlling seizures. **Conclusion:** In this group, we found a predominance of simple partial seizures and a relationship between somatosensory and special sensory seizures and the location of the cysts. Cysticidal therapy was effective in controlling seizures in these patients and should be considered for patients with partial seizures and semiology related to cyst location.

**KEY WORDS:** neurocysticercosis, albendazol, praziquantel, epilepsy, partial seizures, computerized tomography, EEG.

#### Impacto do tratamento cisticida no controle das crises epilépticas relacionadas a neurocisticercose

**RESUMO - Objetivo:** Avaliar as características e o controle das crises em pacientes com epilepsia associada à neurocisticercose. **Método:** Foram avaliados 18 pacientes tratados com albendazol ou praziquantel, com seguimento após tratamento variando de 3 meses a 12 anos. Todos pacientes tinham LCR, EEG interictal, tomografia computadorizada e/ou ressonância magnética de crânio. **Resultados:** A idade média foi de 36,4 anos. O tempo de epilepsia foi em média 16,2 anos; 83% dos pacientes apresentavam crises parciais simples e 17%; crises parciais complexas. O EEG foi normal em 38%. Em apenas 28% dos pacientes houve relação entre alterações focais do EEG e a localização do cisto. Em relação ao LCR; 33% apresentavam pleiocitose, 28% hiperproteínoorraquia e apenas 22% apresentavam imunologia positiva para cisticercose. Foi observada relação entre localização do cisto e semiologia das crises em todos os pacientes com crises de início sensitivo-motor e sensorial especial (n=11). Após tratamento cisticida, 83% tiveram redução de pelo menos 50% das crises. **Conclusão:** Na epilepsia relacionada a neurocisticercose predominam crises parciais simples e observa-se relação entre crises sensitivo-motoras ou sensoriais especiais e localização do cisto. O tratamento cisticida deve ser considerado nos pacientes com crises parciais com semiologia relacionada à localização do cisto.

**PALAVRAS-CHAVE:** neurocisticercose, albendazol, praziquantel, crises parciais, tomografia computadorizada, EEG.

Department of Neurology, Faculty of Medical Sciences, State University of Campinas (UNICAMP).  
Aceite: 12-julho-2000.

Dr. Fernando Cendes - Department of Neurology, FCM, UNICAMP - Caixa Postal 6111 - 13083-970 Campinas  
SP - Brasil. FAX 19 289 0880.

The public health system in developing countries<sup>1</sup> has been unable to control neurocysticercosis. In Brazil, the disease prevalence is between 1 to 2%<sup>2</sup> and its main symptoms are: headaches, meningitis, focal neurological deficits, epileptic seizures and cognitive disorders. It is an important cause of morbidity in young adults<sup>3-6</sup>. Epileptic seizures are most common symptoms<sup>1,7-11</sup>. Although most of the seizures can be controlled with anticonvulsant medication, there are some patients with seizures that are difficult to control.

Seizures related to acute intraparenchymal cysticercosis are usually associated with other neurological signs and tend to disappear when edema and acute inflammation subside. In this situation, seizures can be considered as acute symptomatic and not necessarily fulfil the criteria for diagnosis of epilepsy.

Chronic intraparenchymatous lesions of neurocysticercosis consists of viable cysts or, more frequently, the cicatricial form of small nodular calcifications. The epilepsies associated with calcifications of neurocysticercosis are in general easy to control and many patients present with remission of seizures after a few years. However, due to the high incidence of neurocysticercosis in underdeveloped countries, it is common the finding of microcalcifications in computerized tomography (CT) of asymptomatic individuals and in patients with other forms of epilepsies, such as temporal lobe epilepsy associated with mesial temporal sclerosis or primary generalized epilepsies. In these situations, the role of calcifications of neurocysticercosis in epileptogenesis is still unclear. On the other hand, patients with chronic viable cystic lesions of neurocysticercosis, often present with partial seizures, and there are some indications that these are related to the location of the cysts. It is impossible to predict how long these cysts can stay "viable" in the cerebral parenchyma, but some suggest that they should not be treated<sup>1-3</sup>.

The purpose of this study was to evaluate the clinical features of one particular form of neurocysticercosis related seizures, the chronic viable cortical cysts, as well as the effect of cysticidal therapy on cystic regression and seizure control.

## METHOD

*Criteria for selection* - We included 18 patients followed at the epilepsy clinic at the Hospital das Clínicas, UNICAMP, with the diagnose of epilepsy and intraparenchymatous cysts of cysticercosis. Although all patients were on antiepileptic medication, they were not seizure free (a minimum of 3 seizures / year). All patients underwent at least 2 head CT previous to cysticidal therapy, and follow up imaging after treatment with CT or magnetic resonance imaging (MRI).

*Exclusion criteria were* - Patients with less than 3 seizures per year; and those who did not complete the cysticidal therapy; or underwent only one CT during follow up period.

*Seizure classification* followed the criteria of the International League Against Epilepsy (ILAE)<sup>12</sup>.

*Cerebrospinal fluid (CSF) analysis* - All the patients underwent cytology, biochemistry analysis and immunological test for cysticercosis (indirect immunofluorescence in 3 and ELISA in 15).

*Electroencephalogram (EEG)* - An interictal EEG was performed on all patients using equipment with 16 channels and the 10-20 electrode system for electrodes placement.

All patients had at least 2 CTs with and without contrast at different times during follow up. Nine patients had also MRI with gadolinium. Images were obtained using T1 and T2 weighted sequences in axial, sagittal and coronal planes.

*Cysticidal therapy* - 16 patients were given a dose of 15-20 mg/kg of albendazol for 7 to 30 days (median =21 days; mean = 18 days) and 2 patients were treated with 50 mg/kg of praziquantel for 15 days. Five days before the cysticidal treatment began they received 1 mg/kg of prednisone. Prednisone was maintained during the cysticidal treatment and tapered down afterwards. Follow up after the treatment varied from 5 months to 12 years (mean = 33 months).

Table 1. Classification of seizures - 18 patients\*.

Seizure semiology	Nº of Patients	%
SPS somatosensory	6	33,4
SPS special sensory	5	27,8
SPS autonomic	1	5,5
SPS psychic	2	11,1
SPS versive	1	5,5
CPS	3	16,7
Total	18	100

SPS, simple partial seizures; CPS, complex partial seizures. \*All patients had presented secondary generalized tonic-clonic seizures

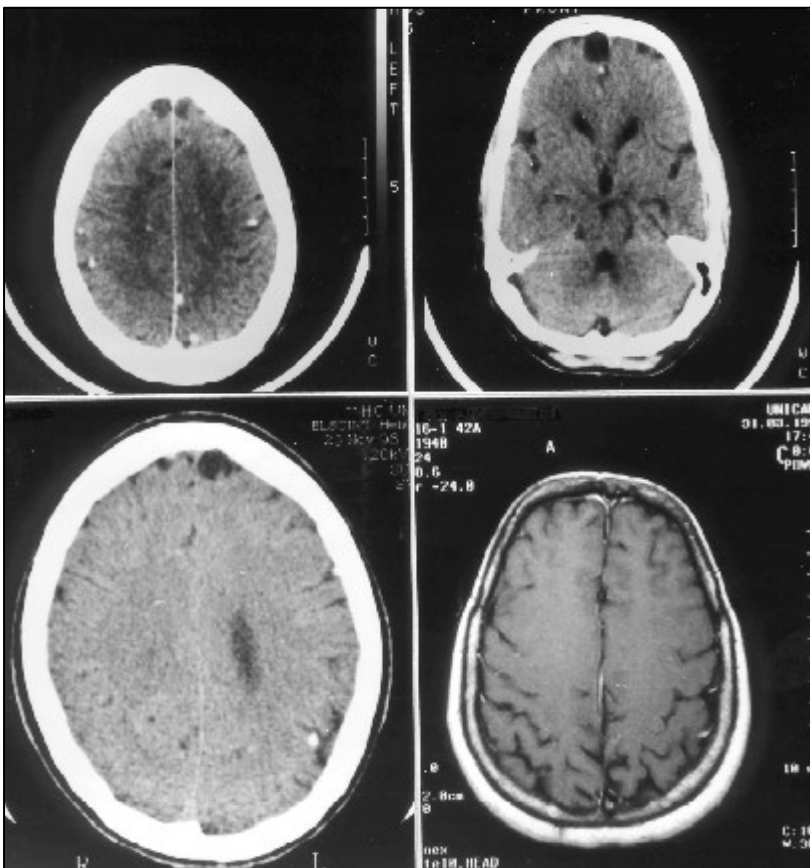


Fig 1. Persistence of frontal cysts in CT series taken over a period of 77 months and cyst resolution after cysticidal therapy: 1A: CT of the cranium performed in June, 1992, showed frontal cystic lesions and multiple calcifications. 1B: CT performed in August, 1993, showed a right frontal cyst (a left frontal cyst was observed in a section above). 1C: CT performed in November, 1998, showed that the left frontal cyst persisted (the right frontal cyst was observed in a section below). 1D: Cysticidal therapy terminated in February, 1999. The MRI done in March, 1999, showed that the cysts had disappeared.

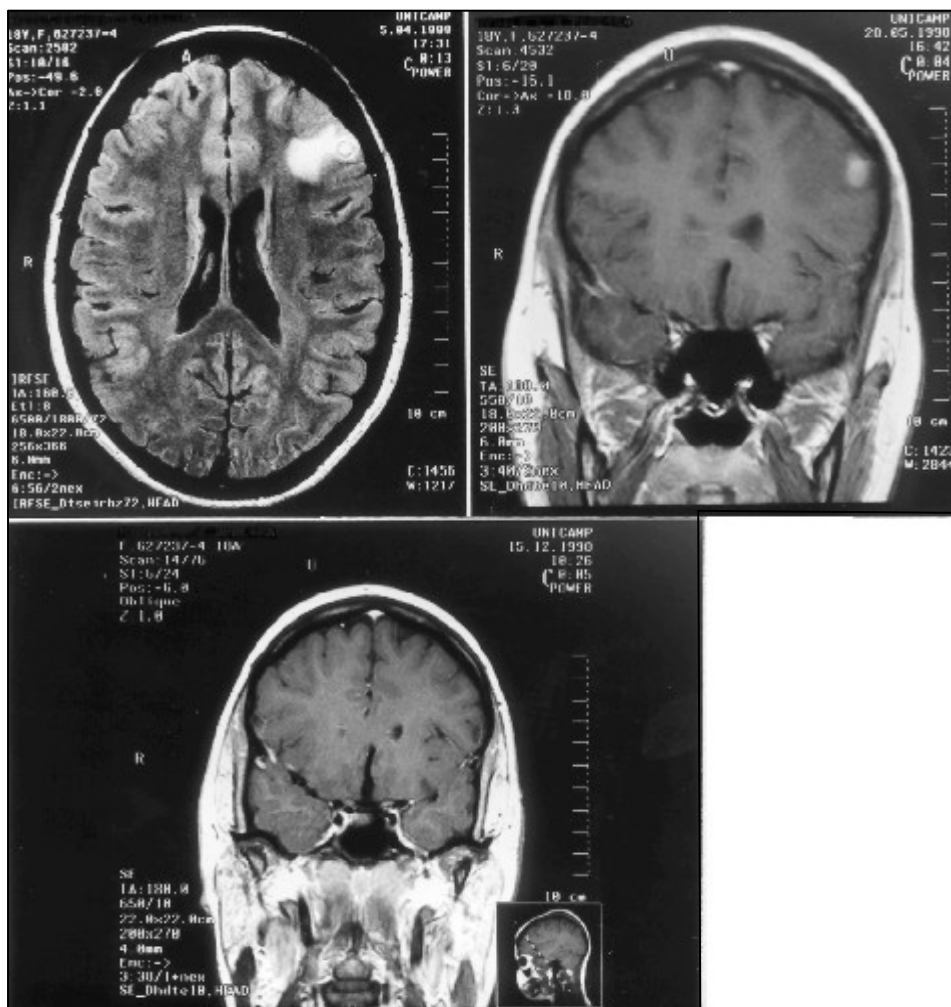

Fig 2. Cyst resolution in a patient who was immediately put on cysticidal therapy: 2A: MRI performed in April, 1998, showed a cystic lesion in the left frontal region, the patient was immediately put on cysticidal therapy. 2B: MRI from May, 1998, - 3 weeks after terminating the cysticidal therapy the left frontal cyst had decreased in size. 2C: MRI from December, 1998, - 8 months after terminating the cysticidal treatment the cyst had disappeared completely.

## RESULTS

**Clinical features** - The follow-up period varied from 3 months to 12 years. The patients' ages ranged from 19 to 70 years (mean = 36.4 years). Seizure onset varied from 2 years to 62 years (mean = 21 years). The duration of epilepsy varied from 3 months to 36 years (mean = 16 years). Fifteen patients (83%) had simple partial seizures (SPS); 11 (61%) had somatosensory and special sensory manifestations; 3 (17%) had complex partial seizures (CPS). All 18 patients had secondary generalizations (Table 1).

Six (33%) patients had pleocytosis on the CSF exam; 5 (28%) had elevated protein levels and only 4 (22%) had positive immunology for cysticercosis.

EEG showed focal epileptiform abnormality in 5 patients (28%); focal slow wave abnormalities in 5 (28%); generalized slow wave abnormalities in one (5%), and it was normal in 7 patients (39%). A relationship between focal changes and cyst location was observed in only 5 patients (28%).

CT or MRI or both showed a single cystic lesion in 2 patients (11%) and multiple cysts in 16 patients (89%). Additional micro-calcifications were present in 14 patients (78%).

In 11 patients we were able to document with repeated CTs the persistence of cystic lesions for an average of 4.2 years (ranging from 8 to 86 months) prior to the cysticidal treatment. Cyst persistence with *contrast* uptake was observed in 50% of the cases for an average period of 36.4 months (Fig 1). It was not possible to estimate for how long the cysts were present in 8 patients because they opted for immediate treatment (Fig 2).

After treatment, the cysts disappeared in 13 patients (72%), and reduced significantly in size or number in the remaining 5 patients (28%).

There was a relationship between the location cysts and seizure semiology in all patients who had somatosensory and special sensory seizures.

*Seizure control after cysticidal treatment* - Total seizure control was obtained in 5 patients (28%), a partial control (at least 50% reduction in the number of seizures) in 10 patients (55%), and in the remaining 3 patients (17%) seizure frequency remained unchanged. During follow up, the same antiepileptic medication was maintained in 13 patients (72%).

## DISCUSSION

Although the methodology used in studies that evaluate efficacy praziquantel and albendazol for treatment of cysticercosis has received criticisms<sup>1,2,14-16</sup>, their use in the cysticidal treatment of neurocysticercosis has proved efficacious<sup>10,13</sup>. Although neurocysticercosis is widespread in underdeveloped countries with an important socioeconomic impact, there is a lack of information about its natural history, treatment and prognosis<sup>1,17</sup>.

The controversies concerning epilepsy related to neurocysticercosis are even greater, partly because of different forms of pathological manifestations of the infection (parenchymal and extraparenchymal; active and inactive; meningeal and intraventricular). The coexistence of other pathologies creates methodological difficulties in studying these patients<sup>1,18</sup>.

This study did not aim to clarify the controversies about epilepsy related to neurocysticercosis but to report the seizure outcome after cysticidal therapy in a group of these patients. There are obvious constraints that prevent a sizeable prospective placebo controlled study to investigate the real efficacy of albendazol or praziquantel for treating patients with active neurocysticercosis. First, given the complex variability of the individual immunologic response to the parasite, and sites of infection (parenchyma, ventricles, subarachnoid space), it would be necessary a quite large number of patients for a valid conclusion. In addition, it would be necessary follow-up of imaging and CSF evaluation to prove the efficacy of treatment. Such a study would be prohibitively expensive. Furthermore, common sense indicates that investing in education and improvement of sanitary conditions in order to prevent or even eradicate this disease would be more productive. Given the difficulties mentioned above, we believe that there could not be a more appropriate control group than the study group itself, despite of all the methodological limitations.

It has been observed that epilepsy related to neurocysticercosis usually occurs in young economically active individuals<sup>7,10</sup> and therefore, causes a tremendous social impact in developing countries. Conventional antiepileptic drugs besides being expensive do not always satisfactorily control their seizures. Various factors that have been present prior to treatment like multiple cysts, calcification and recurring seizures seem to have a negative influence on seizure control<sup>6</sup>.

We evaluated the average duration of epilepsy, type and frequency of seizures, and how long the active cysts were present before treatment. In this study we observed that seizure control improved significantly in 83% of the patients after cysticidal treatment, even though they had a longstanding seizure disorder (mean duration of epilepsy of 16.2 years). Despite the small number of patients, these results support the indication for cysticidal treatment for patients with cortical active cysts, even in those with a long history of epilepsy.

In this study partial seizures were predominant, especially simple somatosensory and special sensory seizures, in agreement with previous studies<sup>10,20-22</sup>. We also observed a direct relationship between seizure symptoms and the location of cysts, which strengthens the cause-effect relationship between cysts and epilepsy in these patients.

The most sensitive diagnostic methods are the CT and MR - MR being superior to the CT except in detecting associated multiple punctiform calcifications<sup>1,18,22-26</sup>. In most of these patients with parenchymatous cysticercosis, the CSF was normal<sup>27</sup>. The EEG did not show specific abnormalities and in some of the patients the results were normal<sup>2,6,18</sup>.

In those patients with repeated CTs, the average period of persistence of parenchymal cysts was 50.6 months. This demonstrates the difficulty in defining how long would be necessary for the spontaneous resolution of cysts on an individual basis, even when there is contrast enhancement. This can take weeks or years<sup>1, 5,20,28-30</sup> but can be shortened by a few days or weeks with cysticidal therapy<sup>20,31,32</sup>, with the additional improvement of seizure control in many of these patients as demonstrated here.

## Conclusion

Cysticidal treatment can help in controlling seizures in partial epilepsies related to the presence of active neurocysticercosis in the cerebral cortex, independent of the results of CSF exam and the pattern of contrast uptake on CT or MRI. Treatment with albendazol, and alternatively praziquantel, should be considered in patients with epilepsy related to active cerebral cysticercosis, particularly when the site of seizure onset coincides with the location of the cysts.

## REFERENCES

1. Carpio A, Escobar A, Hauser WA. Cysticercosis and epilepsy: a critical review. *Epilepsia* 1998;39:1025-1040.
2. Pal DK, Carpio A, Sander JW. Neurocysticercosis and epilepsy in developing countries. *J Neurol Neurosurg Psychiatry* 2000;68:137-143.
3. Del Brutto OH. Prognostic factors for seizure recurrence after withdrawal of antiepileptic drugs in patients with neurocysticercosis. *Neurology* 1994;44:1706-1709.
4. Spina-França, A, Livramento JA, Machado LR. Cysticercosis of the central nervous system and cerebrospinal fluid: immunodiagnosis of 1573 patients in 63 years. *Arq Neuropsiquiatr* 1993;51:16-20.
5. Monteiro L, Nunes B, Mendonça D, Lopes J. Spectrum of epilepsy in neurocysticercosis: a long-term follow-up of 143 patients. *Acta Neurol Scand* 1995;92: 33-40.
6. Carpio A, Santillán F, León P. Aspectos clínicos de la cisticercosis. *Rev Inst Cienc Salud (Ecuador)* 1990;5:1-40
7. Palacio LG, Jiménez I, García HH, et al. Neurocysticercosis in persons with epilepsy in Medellín, Colombia. *Epilepsia* 1998;39:1334-1339.
8. García HH, Gilman R, Martínez M, et al. Cysticercosis as a major cause of epilepsy in Peru. *Lancet* 1993;341:197-200.
9. Medina MT, Rosas E, Rubio-Donnadieu F, Sotelo J. Neurocysticercosis as the main cause of late-onset epilepsy in Mexico. *Arch Intern Med* 1990;150:323-325.
10. Sotelo J, Escobedo F, Rodríguez-Carbajal J, Rubio-Donnadieu F. Therapy of parenchymal brain cysticercosis with praziquantel. *N Engl J Med*. 1984;310:1001-1007.
11. Shawhney IMS, Lekhra, OP, Shashi JS, et al. Evaluation of epilepsy management in a developing country: a prospective study of 407 patients. *Acta Neurol Scand* 1996; 94:19-23.
12. Commission on Classification and Terminology of the International League Against Epilepsy. Proposal for revised classification of epilepsies and epileptic seizures. *Epilepsia* 1989;30:389-399.
13. Takayanagui OM, Jardim E. Therapy for neurocysticercosis: comparison between albendazole and praziquantel. *Arch Neurol* 1992;49:290-294.
14. Carpio A, Santillán F, León P, et al. Is the course of neurocysticercosis modified by treatment with antihelminthic agents? *Arch Intern Med* 1995;155:1982-1988.
15. Kramer LD. Medical Treatment of cysticercosis-ineffective. *Arch Neurol* 1995;52:101-102.

16. Hachinski V. Medical treatment of cysticercosis. *Arch Neurol* 1995;52:104.
17. Krammer LD, Locke GE, Byrd SE, Daryabagi J. Cerebral cysticercosis: documentation of natural history with CT. *Radiology* 1989;171:459-462.
18. Cukiert A, Pugli P, Scapolan HB, et al. Congruence of the topography of intracranial calcifications and epileptic foci. *Arq Neuropsiquiatr* 1994;52:289-294.
19. Escobedo F, Penagos P, Rodríguez J, Sotelo J. Albendazole therapy for neurocysticercosis. *Arch Intern Med* 1987;147:738-741.
20. Murthy JMK, Reddy YVS. Prognosis of epilepsy associated with single CT enhancing lesion: a long term follow up study. *J Neurol Sci* 1998;159:151-155.
21. Bittencourt PRM, Adamolekun B, Bharucha N, et al. Epilepsy in the tropics: II. Clinical presentations, pathophysiology, immunologic diagnosis, economics and therapy. *Epilepsia* 1996;37:1121-1127.
22. Del Brutto OH, Santibañez R, Noboa CA, et al. Epilepsy due to neurocysticercosis: analysis of 203 patients. *Neurology* 1992;42: 389-392.
23. Narata AP, Arruda WO, Uemura E, et al. Neurocisticercose: diagnóstico tomográfico em pacientes neurológicos. *Arq Neuropsiquiatr* 1998;56(2):245-249.
24. Minguetti G, Ferreira M. Computed tomography in neurocysticercosis. *J Neurol Neurosurg Psychiatry* 1983;46:926-942.
25. Chequer RS, Vieira VL. Neurocisticercose no Estado do Espírito Santo. *Arq Neuropsiquiatr* 1990;48:431-440.
26. Daras M, Tuchman AJ, Strobos RJ. Computed tomography in adult onset epileptic seizures in a city hospital population. *Epilepsia* 1987;28:519-522.
27. Singh G. Neurocysticercosis in South-Central America and the Indian Subcontinent: a comparative evaluation. *Arq Neuropsiquiatr* 1997;55:349-356.
28. Sethi PK, Kuar BR, Madan VS, et al. Appearing and disappearing CT scan abnormalities and seizures. *J Neurol Neurosurg Psychiatry* 1985;48:866-869.
29. Chandy MJ, Rajshekhar V, Ghosh S, et al. Single small enhancing CT lesions in Indian patients with epilepsy: clinical, radiological and pathological considerations. *J Neurol Neurosurg Psychiatry* 1991;54:702-705.
30. Rajshekhar V. Albendazole therapy for persistent solitary cysticercus granuloma in patient with seizures. *Neurology* 1993;43:1238-1240.
31. Vazquez V, Sotelo J. The course of seizures after treatment for cerebral cysticercosis. *N Engl J Med* 1992;327:696-701.
32. Alarcón F, Escalante L, Dueñas G, et al. Neurocysticercosis: short course of treatment with albendazole. *Arch Neurol* 1989;46:1231-1236.