

Original Article

Facial features of patients with sickle cell anemia

Naiara Gonçalves Maia^a; Luís Antônio dos Santos^b; Ricardo D. Coletta^c; Patrícia Helena Mendes^d; Paulo Rogério Bonan^e; Leonardo Batista Maia^f; Hercílio Martelli Junior^g

ABSTRACT

Objective: To characterize the craniofacial features of patients with sickle cell anemia (SCA).

Materials and Methods: Fifty patients with SCA in the north of Minas Gerais, Brazil, were evaluated using standardized photographs (front and profile) for a subjective facial analysis and digital radiographs for a computerized cephalometric analysis. To obtain linear and angular measurements, cephalometric points were marked on the digital images by a single examiner, using the program Radiocef 6.0, and facial analyses were performed by four different orthodontists.

Results: Of the population studied, 28 patients were female with a mean age of 27.7 years. Most of the patients (64%) had their faces classified as esthetically acceptable, although results showed a predominance of convex profiles (72%). The mean of the SNA angle was 84.56°, diagnosing proper positioning of the maxilla from the base of the skull. The prevalence of pattern II was 32%, and 31% showed maxillary protrusion; the effective length of the maxilla was reduced in 64%. Retrusion of the mandible was observed in 30%, and 76% had reduced mandibular length. Four measurements (mandibular length, maxillary length, anterior face height, and maxillomandibular difference) showed statistically significant differences between genders, where these measurements were higher for males than for females.

Conclusion: Most patients did not show compensatory maxillary expansion, which was determined by the prevalence of decreased maxillary length (64%) and by the absence of maxillary protrusion in 69% of the SCA patients evaluated. (*Angle Orthod.* 2011;81:115–120.)

KEY WORDS: Sickle cell anemia; Facial features; Orthodontics

INTRODUCTION

Sickle cell anemia (SCA) is the most prevalent genetic disease in Brazil.¹ This disease is caused by a homozygous point mutation in the beta chain of the hemoglobin gene, resulting in a physically and

chemically abnormal hemoglobin called hemoglobin S (HbS), which leads to somatic alterations including oral manifestations.^{2,3} In situations of low oxygen levels, HbS molecules become deoxygenated, and the presence of valine in the HbS sequence results in hydrophobic aggregations that cause an increase in blood viscosity.⁴ Furthermore, the sickle-shaped red cells lose their deformability, which is required for passing through the microcirculation, obstructing capillaries, restricting blood flow to organs, and resulting in ischemia, pain, and often tissue damage.⁵

The most frequent oral manifestations of SCA include paleness of the oral mucosa, delays in tooth eruption, atrophy of the tongue papillae, impaired dentine mineralization, mandibular osteomyelitis, and orofacial pain.^{6,7} Craniofacial alterations in SCA patients occur as the result of hyperplasia and compensatory expansion of the bone marrow, resulting in exaggerated growth/protrusion of the midface, maxillary expansion, a predominance of vertical growth, mandibular retrusion, a convex profile, and maxillary protrusion.^{8–17} Cephalometric analysis cannot fully express the esthetics and harmony of the face; however, in association with facial

^a Professor, Pediatric area, Dental School, University of Montes Claros, Montes Claros, Minas Gerais, Brazil.

^b Professor, Department of Radiology, Dental School, University of Montes Claros, Montes Claros, Minas Gerais, Brazil.

^c Professor, Department of Oral Diagnosis, State University of Campinas, São Paulo, Brazil.

^d MSc Student, Dental School, University of Montes Claros, Montes Claros, Minas Gerais, Brazil.

^e Professor, Department of Oral Pathology, Dental School, University of Montes Claros, Montes Claros, Minas Gerais, Brazil.

^f Academic of 12^o period, Medical School, University of Montes Claros, Montes Claros, Minas Gerais, Brazil.

Corresponding author: Dr Paulo Rogério Ferreti Bonan, State University of Montes Claros, Av Cula Mangabeira, 562, Sto Expedito, Montes Claros, MG, Brazil 39400-000 (e-mail: pbonan@yahoo.com)

Accepted: July 2010. Submitted: January 2010.

© 2011 by The EH Angle Education and Research Foundation, Inc.

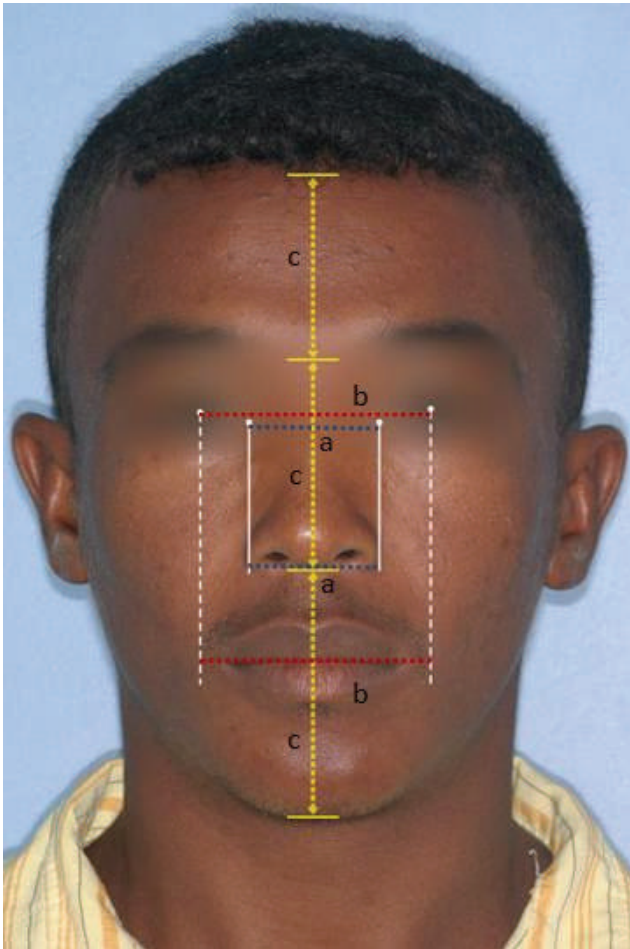


Figure 1. Front view showing similarities between measurements of nasal width and intercanthal distance (a) and mouth width and interpupillary distance (b). The symmetry and proportionality between the facial thirds (c) are also evident.

analysis, the diagnostic possibilities of cephalometric analysis are increased, allowing greater accuracy of results.^{18–22} The aim of this study was to characterize the craniofacial features of SCA patients using cephalometric and facial analyses—the two main existing methods in orthodontics for the diagnosis of skeletal alterations.

MATERIALS AND METHODS

We conducted a descriptive and cross-sectional study that evaluated 50 patients with SCA registered in the Regional Blood Center of Montes Claros, Minas Gerais, Brazil. A total of 28 females and 22 males, 18 to 43 years old (mean, 27.7 years), were included. Patients with a current or previous history of orthodontic/orthopedic treatment who had already undergone facial surgery (orthognathic or plastic), or who were carriers of a congenital syndrome or craniofacial abnormality, or who were fully edentulous, were not included. Data collection consisted of standardized

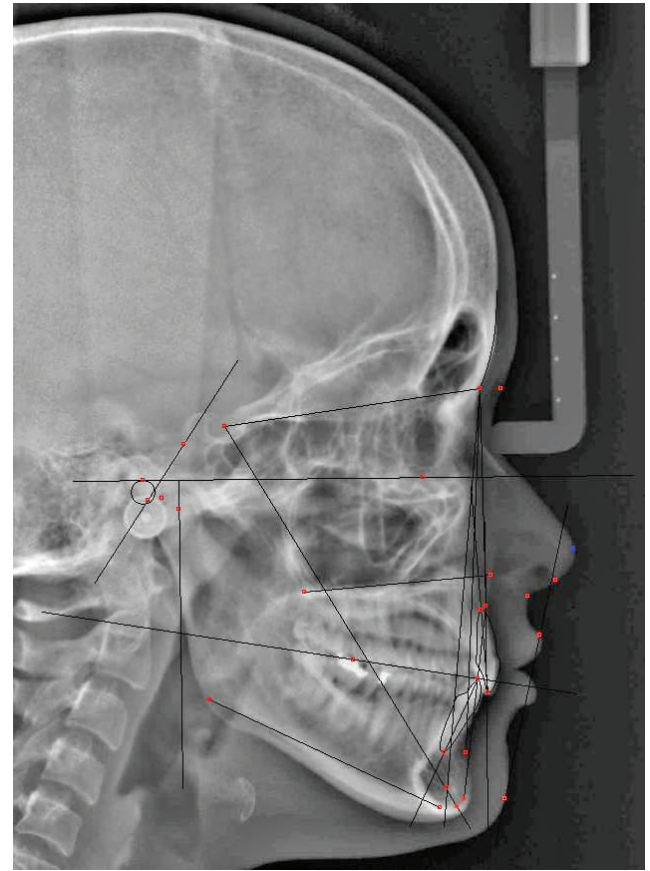


Figure 2. Reference points, planes, and lines used in cephalometric analysis.

frontal and lateral photographs (digital capture, 105/35 mm macro lens and flash) and digital lateral radiographs of each patient. All photographic equipment was previously calibrated, and all photographs were taken by the same examiner, always using the same position of the machine in relation to its height and distance from the patient. Photographs of the face (profile and frontal) were analyzed by subjective facial analysis of esthetic and morphologic parameters,^{19,20} by four different orthodontists who had no knowledge of the research objectives. Parameters used for the morphologic analysis included assessment of facial profile, nasolabial angle, chin-neck line, proportionality between facial thirds, symmetry, correlation between measurements of intercanthal eye distance and nasal width, and measurements of interpupillary distance and mouth width (Figure 1). After assessing the parameters described, the four evaluators established a diagnosis of the facial pattern (eg, pattern I is identified by facial normality, patterns II and III are characterized by positive and negative sagittal relationships between the maxilla and the mandible, respectively) (Figure 2). The classification of facial pattern was used because it is one evaluation that

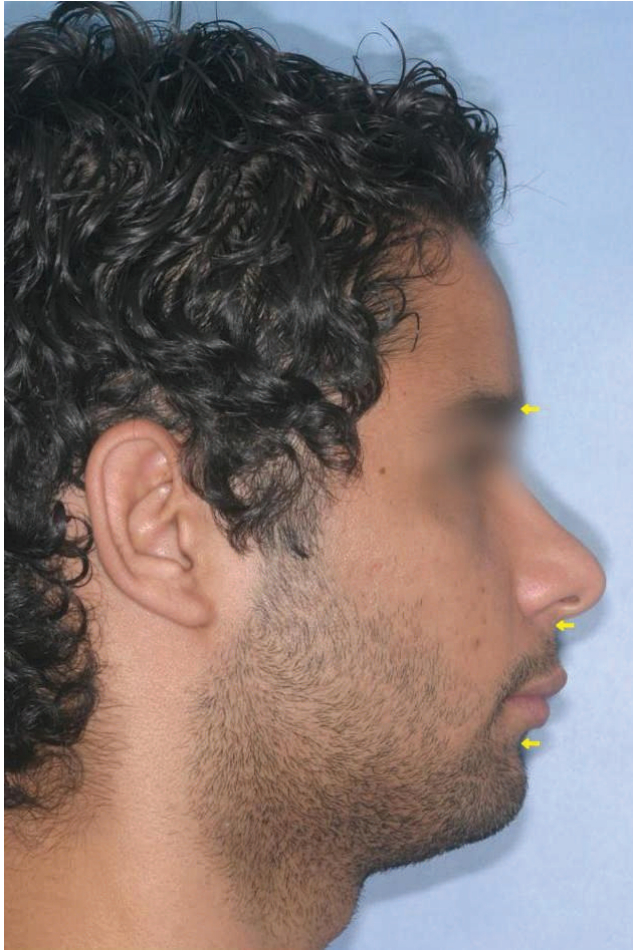

Figure 3. Photographs of a patient classified as pattern II. The arrows show the positions of the craniometric points of the glabella, subnasale, and menton. The convex profile is evident from the anterior position of the subnasale for the other two points.

takes into consideration the skeletal facial growth of patients, other than the Angle classification, which is based on the dental relationship.¹⁹

Radiographs were obtained using the apparatus X-ray Kodak 8000c (Carestream Health, Rochester, NY), and kilovolts and milliamperage were determined according to the height of the patient. Radiographs were taken by a single technician in radiology, and images were acquired with a filter sharpness of 1.5 and optimized contrast, and were saved as DICOM 3 and JPEG images. Cephalometric analysis was performed using Radiocef 6.0 software (Radio Memory Ltda, Belo Horizonte, MG, Brazil), in accordance with the manufacturer's recommendations. To obtain linear and angular measurements, cephalometric points were marked on the digital images by a single examiner. Reference points, planes, and angles used in the cephalometric analysis are shown in Figure 3. After completion of the cephalometric analysis, the cephalometric diagnosis for each patient was analyzed to

Table 1. Parameters Used for Completion of the Diagnostic Summary of Cephalometric Analysis

Variations of 1°/mm = normal
Variations from 1.1 to 2°/mm = low
Variations from 2.1 to 3.5°/mm = no adjective
Variations greater than 3.6°/mm = markedly

characterize the face in relation to the cephalometric data, while the patient's SCA value was compared with normative values. The parameters used for cephalometric diagnosis are shown in Table 1.

For verification of the systematic method error of cephalometric measurements, 10 radiographs were randomly selected and were reviewed by the same operator at an interval of 30 days. Verification of the systematic error was made using the paired Student's *t*-test, except for four variables that were not normally distributed. Calculation of the systematic method error for these variables was done using the Wilcoxon test. None of the variables showed statistically significant systematic errors. The data were subjected to statistical analysis using the Statistical Package for the Social Sciences (SPSS), version 17.0 (SPSS Inc, Chicago, Ill). Student's *t*-tests and Mann-Whitney tests were performed. This study was approved by the Ethics Committee.

RESULTS

Subjective facial esthetic analysis demonstrated that 10% of SCA patients were classified as esthetically pleasing, 64% as esthetically acceptable, and 26% as unpleasant. Results of the morphologic analysis determined predominance of a convex profile in 68%, absence of facial asymmetries in 84%, and proportionality between facial thirds in 60%. Regarding the diagnosis of facial pattern, 50% were classified as pattern I, 32% as pattern II, 6% as pattern III, 10% as having a long face, and 2% as having a short face. The balance between proportions of the nose and mouth and evaluation of the nasolabial angle and chin-neck line with the diagnosis of mandible and maxilla positioning are shown in Table 2.

The faces of these patients were also evaluated by cephalometric analysis. Descriptive analysis of these data, mean values for all variables analyzed, and minimum and maximum values and standard deviations are presented in Tables 3 and 4. Results of the data from the cephalometric diagnosis summary are shown in Table 5. All cephalometric measurements were subjected to statistical analysis to determine gender differences; only four variables showed sexual dimorphism: the effective lengths of the maxilla and mandible, the maxillary/mandibular difference, and anterior face height, where the measurements for

Table 2. Frequency of Proportionality Between Nasal Width and Inter-canthal Distance and Mouth Width and Interpupillary Distance, Classification of Nasolabial Angle, and Classification of Chin-Neck Line in SCA patients (n = 50)

Variable	Proportion/Classification
Mouth width	40% (Yes)
	60% (No)
Nasal width	73% (Yes)
	27% (No)
Nasolabial angle	51% (Adequate)
	45% (Closed)
	4% (Open)
Chin-neck line	56% (Adequate)
	33% (Shortened)
	11% (Elongated)

males were significantly larger than for females (Table 6).

DISCUSSION

From classical studies of cephalometric analyses²¹⁻²³ to current ones,^{20,24-27} much has been discussed about the influence of factors such as skin color and ethnicity in determining facial, tegumentary, and tooth features. A consensus seems evident in the scientific literature^{18,19,24-27} that no single cephalometric analysis is applicable to all populations, and that many of the differences noted in studies are due to this wide variance in the characteristics of a given population, especially the Brazilian population.²⁸

In this sense, cephalometric data that assess the positioning of the maxilla in relation to the cranial base should be interpreted with care. A protrusion of the maxilla was found in 34% of patients, but the normative value for the SNA angle ($82^\circ \pm 2.9^\circ$) does not reflect the wide variation found in the Brazilian population. The average value found for this angle in our study was 84.56° , which is within the standard deviation for this variable. A similar result was observed by Altemus and Epps,⁹ who found this angle to be 86° , which also showed the proper positioning of the maxilla. Another similar Brazilian study¹⁵ reported an average of 85.42° for this angle. In these three studies, the average value for the SNA was similar;

Table 3. Relationship Between Apical Bases and Effective Length of the Maxilla and Mandible

Variables Analyzed	Average	Minimum	Maximum	DP
SNA angle, °	84.56	73.70	100.45	5.32
SNB angle, °	80.12	69.03	98.81	5.53
ANB angle, °	4.44	-1.96	9.87	2.64
Maxillary length, CoA	88.24 mm	78.37 mm	101.78 mm	5.78
Mandibular length, CoGn	113.87 mm	96.55 mm	132.88 mm	8.31
Anterior face height	66.36 mm	53.20 mm	81.49 mm	6.57

Table 4. Dental Arches and Apical Bases

Variables Analyzed	Average	Minimum	Maximum	DP
1.NA	20.09°	4.34°	40.80°	8.57
1-NA	5.68 mm	-4.62 mm	20.16 mm	4.21
1.NB	31.91°	19.8°	44.45°	5.59
1-NB	9.11 mm	1.4 mm	33.96 mm	5.27
1.1	123.74°	102.54°	151.90°	10.45

this strengthens the conclusions of the data in the present study.

These results are contrary to the results of other previous studies, which associated protrusion of the maxilla with bone marrow hyperplasia due to SCA.^{7,8,12,15,29} However, other authors^{9,14} found results similar to our study regarding maxillary position. They concluded that SCA is a disease in which clinical manifestations are modulated by several genetic and environmental factors,^{14,30} although no consensus can be found in the literature about the mechanisms responsible for these clinical and radiographic findings.

When the average values of the present study are compared with the average values found by Fortes²⁸ for black Brazilian people with normal occlusion (SNA = 88.2°), this average was lower, which again reinforces the possibility that protrusion of the maxilla may not be related only to SCA. Our interpretation of these findings led to the conclusion that maxillary

Table 5. Summary of Cephalometric Analysis Results

	Percent
Skeleton profile	
Straight	16
Convex	72
Concave	12
Maxillary position	
Properly placed	56
Protruded	34
Retruded	10
Mandibular position	
Properly placed	46
Retruded	30
Protruded	24
Maxillary length	
Appropriate	30
Reduced	64
Increased	6
Mandibular length	
Appropriate	18
Reduced	76
Increased	6
Anterior face height	
Appropriate	30
Reduced	52
Increased	18

Table 6. Cephalometric Linear Measurements and Their Association Between Genders

Gender	CoA	CoGn	CoGn-CoA	Anterior Face Height
Male	91.39	120.06	28.67	66.59
Female	83.58	109.79	26.21	61.12
<i>P</i> value ^a	0.001	0.000	0.038	0.006

^a Statistical tests: Wilcoxon and Mann-Whitney *U*-tests.

protrusion may not be considered a consequence of SCA, but the experimental design did not allow a cause-and-effect relationship to be checked. Therefore, we emphasize the need for additional studies to check the validity of this statement.

Bandeen¹⁷ found craniofacial dimensions reduced in all ages of patients with SCD. These findings contradict the hypothesis that compensatory bone marrow hyperplasia could be responsible for the excessive length of the maxilla and its consequent expansion, and go against the findings of our study, which identified 64% of patients with reduced maxillary length and 76% with reduced mandibular length. Despite the longitudinal study carried out by Bandeen,²¹ which described progressive hyperdivergence of the face with age, we found reduced values of anterior face height in 52% of patients. These differences may be related to design differences in the two studies.

Although a few studies suggested alterations in the positioning of the mandible in SCA patients,^{9,14,15} our results showed abnormal positioning of the mandible in 42% of patients. In most of the variables analyzed, no differences between gender were noted, but four linear measurements showed sexual dimorphism: CoA, CoGn, DifMxMd, and AFH, where the variables measured for females were significantly lower than for males. Our results are consistent with the results of other studies in healthy populations, which found these same measurements to be significantly higher in males.³¹

When the results of various different studies are compared, differences in the characteristics of different populations should be taken into account. In relation to SCD, the present study surveyed only homozygous (HbSS) patients, whereas several other studies associated different genotypes within the same study.^{9,14,17} Age is another factor that complicates comparisons because some studies evaluated individuals who were still growing,^{9,12,29} unlike the individuals in this study, who had reached skeletal maturity. The origin of the population also complicates the comparison; data show that the soft tissue profile of Brazilians is almost completely different from that of Americans, with a less protrusive face, a shorter chin projection, and a more convex profile.³²

Data from facial analyses performed for these SCA patients do not allow for discussion because no

other study used this diagnostic tool to determine the facial features of individuals with SCA. However, when we compared our findings to others arising from studies on Brazilian patients without SCA, some interesting conclusions were reached. The study conducted by Reis and collaborators²⁰ to evaluate the distribution of Brazilian adults in the facial pleasantness pyramid found, by subjective facial esthetics analysis, that 89% of subjects were classified as esthetically acceptable, 3% were pleasant, and 8% were unpleasant. Our study also found an advantage of using the esthetically acceptable classification to evaluate patients with SCA (64%); however, a larger percentage was scored as esthetically unpleasant (26%) in the present study compared with results reported by Reis²⁴ for normal Brazilian adults (8%). It is notable that the number of patients classified as esthetically pleasing in this study (10%) was higher than that reported by Reis and colleagues (3%). Unfortunately, it was not possible to determine whether SCA was responsible for aspects that determined the classification of these patients. Even so, this result is important from a scientific point of view as being the result of a new study that evaluated the facial esthetics of these patients and found a significant percentage of patients who were classified as unpleasant.

The diagnosis of facial pattern performed in this study by subjective facial morphologic analysis identified 32% of patients with pattern II, which is a smaller percentage than that found by Reis,³³ who assessed 50 Brazilian adults and diagnosed 41% with pattern II. Our results show that 50% of the patients had pattern I, which is exactly the same value as reported by Reis in healthy subjects.³³ These results are different from those expected, considering the fact that previous studies described maxillary protrusion as a characteristic of patients with SCA.¹⁵⁻¹⁷

CONCLUSIONS

- The facial features of SCA patients are similar to those characteristics of patients without SCA.
- No facial features were characteristic of SCA patients.
- Most of the patients showed no compensatory maxillary expansion, which was determined by the prevalence of reduced maxillary length (64%) and the absence of maxillary protrusion in 69%. However, the mechanisms involved in this process are poorly understood and require further study.

ACKNOWLEDGMENT

We thank FAPEMIG for financial support.

REFERENCES

- Loureiro MM, Rozenfeld S. Epidemiologia de internações por doença falciforme no Brasil. *Rev Saúde Publica*. 2005; 39:943–949.
- Weatherall DJ, Clegg JB. Inherited haemoglobin disorders: an increasing global health problem. *Bull World Health Org*. 2001;79:704–712.
- Ramakrishna Y. Dental considerations in the management of children suffering from sickle cell disease: a case report. *J Indian Soc Pedod Prev Dent*. 2007;25:140–143.
- Bunn HF. Pathogenesis and treatment of sickle cell disease. *N Engl J Med*. 1997;337:762–769.
- Galacteros F. Physiopathological basis of sickle cell disease, management and current therapeutics. *Bull Soc Pathol Exot*. 2001;94:77–79.
- Brasil, Ministério da Saúde, Secretaria de Atenção à Saúde, Departamento de Atenção Especializada. *Manual de Saúde Bucal na Doença Falciforme*. Brasília: Ministério da Saúde; 2007.
- Mourshed F, Tuckson CR. A study of the radiographic features of the jaws in sickle-cell anaemia. *Oral Surg Oral Med Oral Pathol*. 1974;37:812–819.
- Brown DL, Sebes JL. Sickle cell gnathopathy: radiologic assessment. *Oral Surg Oral Med Oral Pathol*. 1986;61: 653–656.
- Altemus LA, Epps CW. Cephalofacial characteristics of North American black individuals with sickle cell disease. *Q Natl Dent Assoc*. 1974;32:80–88.
- Taylor LB, Nowak AJ, Giller RH, Casamassimo PS. Sickle cell anaemia: a review of dental concerns and a retrospective study of dental and bony changes. *Spec Care Dentist*. 1995;15:38–42.
- Saint Clair de Velasquez Y, Rivera H. Sickle cell anaemia oral manifestations in a Venezuelan population. *Acta Odontol Latinoam*. 1997;10:101–110.
- Oredugba FA, Savage KO. Anthropometric finding in Nigerian children with sickle cell disease. *Pediatr Dent*. 2002;24:321–325.
- Faber TD, Yoon DC, White SC. Fourier analysis reveals increased trabecular spacing in sickle cell anaemia. *J Dent Res*. 2002;81:214–218.
- Licciardello V, Bertuna G, Samperi P. Craniofacial morphology in patients with sickle cell disease: a cephalometric analysis. *Eur J Orthod*. 2007;29:238–242.
- Souza PHG, Oliveira RSF, Rocha JM, Gravina MA, Vitral RWF. Alterações esqueléticas craniofaciais em portadores de anaemia falciforme na cidade de Juiz de Fora. *HU Revista*. 2008;34:85–91.
- Onyeaso CO, da Costa OO. Dental aesthetics assessed against orthodontic treatment complexity and need in Nigerian patients with sickle-cell anaemia. *Spec Care Dentist*. 2009;29:249–253.
- Jacobson, Alex., Bandeen TC. Effects of sickle cell disease on growth of the craniofacial complexes. *Am J Orthod Dentofacial Orthop*. 2006;129:448.
- Ferreira NS, Mazzeiro ET, Manzi FR. Uso da cefalometria em Ortodontia: o valor diagnóstico, científico e os erros mais comuns. *Rev Dental Press Ortodon Ortop Facial*. 2009;7:67–74.
- Capelozza Filho L. *Diagnóstico em Ortodontia: Normas para Diagnóstico*. Maringá: Dental Press; 2004:47–76.
- Reis SAB, Abrão J, Capelozza Filho L, Claro CAA. Análise facial subjetiva. *R Dental Press Ortodon Ortop Facial*. 2006; 11:159–172.
- Downs WB. The role of cephalometrics in orthodontic case analysis and diagnosis. *Am J Orthod*. 1952;38:162–182.
- Steiner CC. Cephalometrics in clinical practice. *Angle Orthodontist*. 1959;29:8–27.
- Ackerman JL, Proffit WR, Sarver DM. The emerging soft tissue paradigms in orthodontic diagnosis and treatment planning. *Clin Orthod Res*. 1999;2:49–52.
- Jacobson R, Sarver DM. The predictability of maxillary repositioning in Le Fort I orthognathic surgery. *Am J Orthod Dentofacial Orthop*. 2002;122:142–154.
- Lopes KB, Paiva JB, Neto JR, Queiroz GV, Bozzini MF, Farias B. Avaliações tegumentares, esqueléticas e dentárias do perfil facial. *Rev Clin Ortodon*. 2007;5:95–105.
- Silva FPL, Gil CTLA, Siqueira DF, Scanavini MA. Estudo cefalométrico individualizado do posicionamento da maxila em indivíduos com equilíbrio facial e oclusão normal. *Rev Dental Press Ortodon Ortop Facial*. 2008;13:77–88.
- Araújo MC, Nahás ACR, Cotrim-Ferreira FA, Carvalho PEG. Estudo cefalométrico da correlação da anatomia da base craniana com o padrão facial e as bases apicais. *Rev Dental Press Ortodon Ortop Facial*. 2008;13:67–76.
- Fortes LAP. *Avaliação de Medidas Cefalométricas de Indivíduos Negros, Brasileiros, Portadores de Oclusão Excelente* [dissertação]. Rio de Janeiro: Universidade Federal do Rio de Janeiro, Faculdade de Odontologia; 2000.
- Shnorhokian HI, Chapman DC, Nazif MM, Zullo TG. Cephalometric study of American black children with sickle-cell disease. *J Dent Child*. 1984;6:431–433.
- Alves PVM, Alves DKM, Souza MMG, Torres SR. Orthodontic treatment of patients with sickle-cell anaemia. *Angle Orthod*. 2006;76:269–273.
- Reis SAB, Capelozza Filho L, Cardoso MA, Scanavini MA. Características cefalométricas dos indivíduos Padrão I. *R Dental Press Ortodon Ortop Facial*. 2005;10:67–77.
- Scavone H Jr, Zahn-Silva W, Valle-Corotti KM, Nahás ACR. Soft tissue profile in White Brazilian adults with normal occlusion and well-balanced faces. *Angle Orthod*. 2008;78: 58–63.
- Reis SAB, Abrão J, Capelozza Filho L, Claro CAA. Estudo comparativo do perfil facial de indivíduos Padrões I, II e III portadores de selamento labial passivo. *R Dental Press Ortodon Ortop Facial*. 2006;11:36–45.