

HIV-ASSOCIATED NEUROMUSCULAR WEAKNESS SYNDROME IN BRAZIL

Report of the two first cases

José E. Vidal^{1,2}, David Clifford³, Cláudio Meilman Ferreira⁴, Augusto C. Penalva de Oliveira^{1,4}

ABSTRACT - We describe two Brazilian patients with HIV-associated neuromuscular weakness syndrome (HANWS), a unique clinical toxic syndrome that was recently reported in developed countries. Both patients were women, used stavudine and had hyperlactatemia, one of them with lactic acidosis. Electrophysiological studies were consistent with axonal neuropathy. After discontinuation of antiretroviral therapy the patients had significant improvement in neurologic manifestations, and normalization of lactate levels. To our knowledge, this is the first report of HANWS in developing countries. Growing use of antiretroviral therapy in this setting, particularly stavudine, make it likely that similar cases will be observed.

KEY WORDS: neuromuscular diseases, peripheral neuropathies, antiretroviral agents, human immunodeficiency virus.

Síndrome da fraqueza neuromuscular associada ao HIV no Brasil: relato dos dois primeiros casos

RESUMO - Os autores descrevem dois pacientes brasileiros com a síndrome da fraqueza neuromuscular associada ao HIV, uma síndrome tóxica, clinicamente particular, que foi recentemente relatada em países desenvolvidos. Ambas pacientes eram do sexo feminino, usavam estavudina e apresentaram hiperlactatemia, uma delas com acidose láctica. Os exames electrofisiológicos foram consistentes com neuropatia axonal. As pacientes melhoraram significativamente das alterações neurológicas, assim como normalizaram os níveis de lactato, após descontinuar o uso dos antiretrovirais. Até onde sabemos, este é o primeiro relato da síndrome de fraqueza neuromuscular associada ao HIV em países em desenvolvimento. Nesse contexto, o uso crescente de antiretrovirais, particularmente a estavudina, possibilitarão que casos similares sejam observados.

PALAVRAS-CHAVE: doenças neuromusculares, neuropatia periférica, terapia antiretroviral, vírus da imunodeficiência humana.

The introduction of highly active antiretroviral therapy (HAART) has improved survival and quality of life of human immunodeficiency virus (HIV)-infected patients in developed countries. Similar results were observed in Brazil, the first developing country with a policy of universal free access to HAART¹. Antiretroviral therapy has also decreased the incidence of central nervous system (CNS) opportunistic diseases², which vary geographically³. However, toxic events secondary to use of HAART can be observed globally. Recently, Simpson et al., reported a heterogeneous syndrome termed the HIV-associated neuromuscular weakness syndrome (HANWS)⁴, which seems to be

related to hyperlactatemia and stavudine and/or didanosine exposure^{4,5}. While these drugs are routinely part of therapy in developing nations, there has been no case reports of HANWS in resource-limited settings.

Here, we present two Brazilian patients with HANWS.

CASES

Case 1 – A 25 year-old HIV-infected woman with a previous history of cerebral toxoplasmosis, esophageal candidiasis, and a high blood pressure, presented to an out-patient clinic care with malaise, nausea and vomiting. She has used

¹MD, PhD, Departamento de Neurologia, Instituto de Infectologia Emilio Ribas, São Paulo SP, Brazil; ²Casa da AIDS, Divisão de Clínica de Moléstias Infecciosas e Parasitárias do Hospital das Clínicas da Faculdade de Medicina da Universidade de São Paulo, São Paulo SP, Brazil; ³MD, Department of Neurology, Washington University School of Medicine, St Louis, Missouri, USA; ⁴MD, PhD, Unidade de Pesquisa Clínica em Retrovirologia Humana, Universidade Estadual de Campinas, São Paulo, Brazil.

Received 14 February 2007, received in final form 16 April 2007. Accepted 5 June 2007.

Dr. José E. Vidal - Rua Capote Valente 668 / 78 - 05409-002 São Paulo SP - Brasil. E-mail: josevibe@gmail.com

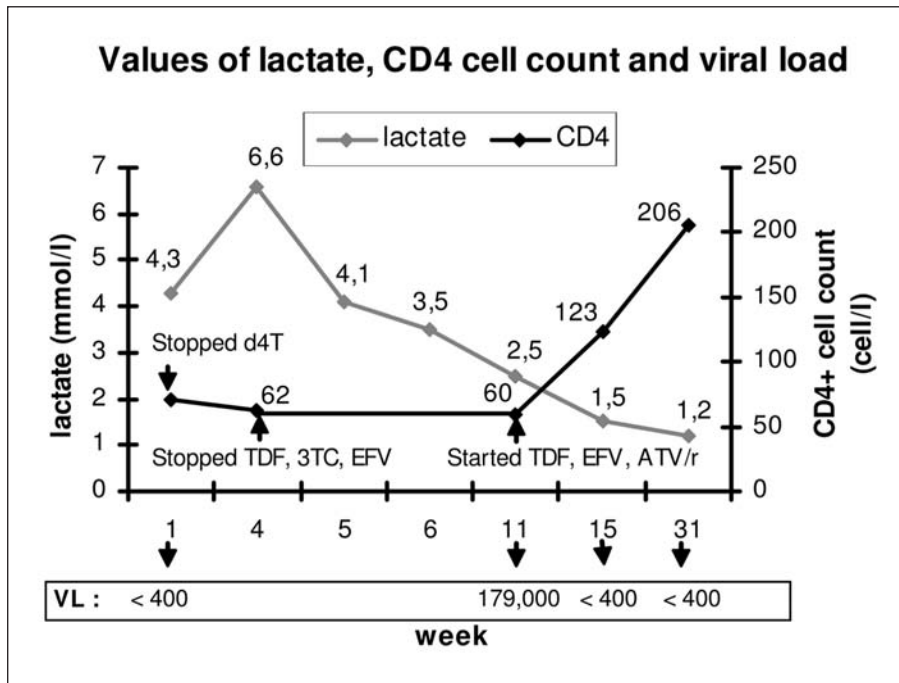


Fig 1. Case 1: Laboratorial information and correlation with highly active antiretroviral therapy. d4T, stavudine; 3TC, lamivudine; TDF, tenofovir; EFV, efavirenz; ATV/r, atazanavir/ritonavir; VL, viral load.

stavudine, lamivudine and efavirenz for 11 months. One week later of the prior evaluation, she complained of additional numbness in her feet. Two weeks after, stavudine was switched to tenofovir. At this point, her lactate levels were 4.4 mmol/L. One week later, she complained of weakness in lower limbs, "pin and needles" sensation, and worsening of numbness in her feet. This progressed over two weeks, despite the use of amitriptyline 25 mg/day, when she presented to our facility. At admission, she was mildly dehydrated. Neurological examination disclosed severe weakness in lower limbs (grade 2) and she was unable to walk without help. Decreased distal pinprick and vibration was noted, and deep tendon reflexes were lost at the knees and ankles. Plantar reflex were absent. She denied any urinary or bowel dysfunction. Abnormal admission labs included: Hb=11.9 mg/dL, AST=208 U/L, ALT=252 U/L, CPK=247 U/L, GGT=178 U/L and K=3.0 mEq/L. A blood gas exchange showed pH 7.33, pO₂ 93.2, pCO₂ 32.1, HCO₃ 13.5, BE -8, and Sat O₂ 96%. Serum lactate was 6.6 mmol/L. CD4 cell count was 62/mm³ and HIV RNA levels <400 copies/mL. Nerve conduction studies of lower limbs revealed evidence of severe axonal sensory motor polyneuropathy, with signs of denervation affecting distal and proximal segments. Brain and lumbar spinal cord computed tomography and cerebrospinal fluid were normal. HAART was withdrawn and she was treated with intravenous fluids and vitamin B complex supplement. Over the following week, she had progressive relief of the complaints with mild weakness (grade 4) and decreasing paresthesias, and lactate level falling to 4.1 mmol/L. She was discharged with secondary prophylaxis for cerebral toxoplasmosis, amitriptyline 25 mg/day, and vitamin B complex supplement. Two months after discharge, she had improved further having only mild weakness in lower limbs without paresthesias. Muscular strength in the lower limbs was grade 4, she continued to have absent an-

kle reflexes, and diminished vibratory sensitivity. At this point, her lactate levels were 2.5 mmol/L, CD4 cell count 60/mm³, and HIV RNA levels=179,000 copies/mL (5.25 log₁₀). Tenofovir, efavirenz atazanavir and ritonavir were started. Three months after discharge, she was walking without difficulty, presented normal muscular strength in the lower limbs, and had normal lactate levels (1.5 mmol/L), CD4 cell count=123/mm³, and HIV RNA levels <400 copies/mL. Seven months after discharge, she was asymptomatic and maintained normal levels of lactate (1.2 mmol/L) along with CD4 cell count=206/mm³ and HIV RNA levels <400 copies/mL. Figure 1 shows the main laboratory results and their temporal association with the use of HAART.

Case 2 – A 47 year-old HIV-infected women with a history of previous intravenous drug use and pulmonary tuberculosis, presented to the emergency room unable to walk, and reporting numbness, tingling, and burning pain on her toes for two weeks. These symptoms rapidly ascended to her lower limbs, chest, and also involving upper limbs within two days. She experienced progressive leg weakness, and was bed bound for the last four days due to extreme difficulty walking, but had no urinary dysfunction. Besides hyporexia and weight loss, she had no other complaints. She had been on stavudine, lamivudine and efavirenz three years ago. At admission, neurological examination revealed weakness of her right arm, and both legs (grade 3), with generalized areflexia. She had decreased light touch and pain sensation on her legs and trunk. Vibratory sensitivity was diminished in the legs. Plantar reflexes were absent. CD4 cell count was 450/mm³, and HIV RNA levels=12,457 copies/mL (4.0 log₁₀). Admission labs included: AST=64 U/L, ALT=55 U/L, GGT=600 U/L, and DHL=645 U/L. A blood gas exchange evaluation showed pH 7.42, pO₂ 97.1, pCO₂ 28.5, HCO₃ 13.5, BE -4, Sat O₂ 98.5%. Serum lactate was 6.6

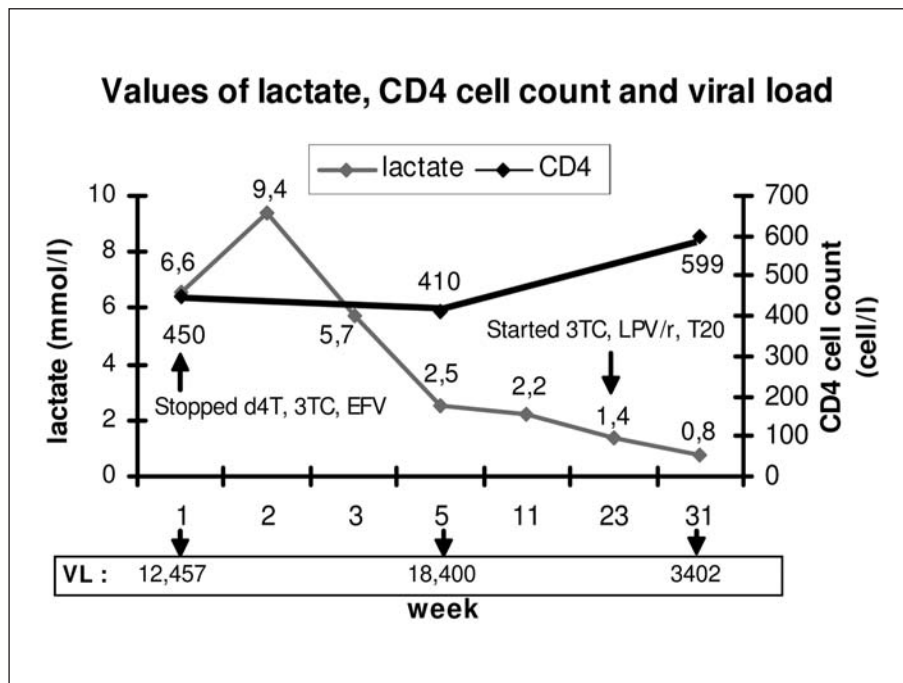


Fig 2. Case 2: Laboratorial information and correlation with highly active antiretroviral therapy. d4T, stavudine; 3TC, lamivudine; TDF, tenofovir; EFV, efavirenz; LPV/r, lopinavir/ritonavir; T20, enfuvirtide; VL, viral load.

mmol/L, and CPK was normal. Thyroid hormones, serum folic and vitamin B12 levels were normal. Magnetic resonance imaging of the brain, thoracic and lumbar spine cord were normal. Lumbar puncture was performed and results were normal. Nerve conduction studies revealed evidence of axonal sensory-motor polyradiculopathy, mild in upper limbs, and severe in lower limbs. HAART was withdrawn and she received vitamin B complex supplement and folic acid. Her symptoms improved slightly, and she reported few disabling paresthesias. After a transitory increase of venous lactate (up to 9.4 mmol/L), the levels declined progressively to 5.7 mmol/L. After three weeks of hospitalization, she was discharged home taking folic acid, vitamin B complex supplement, and amitriptyline 50 mg/day. No antiretroviral therapy was prescribed. Two weeks later, she was walking short distances with help, but reported persistent burning pain in legs, and continued to have leg weakness (grade 3), generalized areflexia, and diminished light touch and pain sensation in a stocking-glove pattern. At this point, her lactate value was 2.5 mmol/L. Two months after discharge, the patient presented with leg strength grade 5, but continued to experience paresthesias, partially controlled with amitriptyline 100 mg/day. At this point, her lactate value was 2.2 mmol/L. Four months after discharge, HAART based on viral resistance genotyping was started using lamivudine, lopinavir / ritonavir and enfuvirtide (T20). One month later, her CD4 cell count was 599/mm³ and HIV RNA levels=3,402 (3.5 log₁₀) with a lactate value of 1.4 mmol/L. Seven months after discharge, the patient presented with mild paresthesias but lactate was 0.8 mmol/L. Figure 2 shows the main laboratorial information and its temporal association with the use of HAART.

The patients have formally given authorization for the publication of this report.

DISCUSSION

To our knowledge, these patients represent the first reported Brazilian HIV-patients with HANWS. At present, the available data are insufficient to estimate the incidence of HANWS in this population. However, considering that there are about 170,000 individuals in Brazil receiving antiretroviral therapy⁶, we would expect more similar cases. In recent years, a spectrum of metabolic and morphologic alterations has emerged among HIV-infected patients receiving HAART. Additionally, neurological syndromes, such as antiretroviral toxic neuropathy, have been clinically well characterized^{7,8}. The HANWS is a unique toxic syndrome, more recently reported, and to date incompletely characterized⁴.

The pathogenesis of neuromuscular syndrome in HIV-infected patients is probably multifactorial, and may result from a combination of mitochondrial and immunological mechanisms due to HIV and HAART⁹. In the initial description of HANWS, Simpson et al., reported 69 HIV-infected patients with HANWS, and approximately 75% of them with electrophysiological or pathological evidence of nerve or muscle disease had hyperlactatemia. Neurophysiological studies generally suggest axonal neuropathy, but may include some evidence of demyelination as well. A majority of patients presented axonal alterations, but if demyelinating findings are present, this might have therapeutic implications, suggesting that intravenous immunoglobulin or plasmapheresis could be used¹⁰.

Our two patients presented can be classified as definitive HANWS, using the criteria of Simpson et al.⁴ Both were females, and presented hyperlactatemia, however, only one presented lactic acidosis. As was observed in this report, the antiretroviral most often associated with HANWS was stavudine. Interestingly, the immunological status was very different in our patients (CD4 cell count=62 / mm³ in Case 1, and CD4 cell count=450/mm³ in Case 2), suggesting that risk for this condition may occur at variable stages.

The treatment of HANWS is controversial, and important since this is potentially a fatal syndrome. Our experience reinforces the recommendation that early interruption of HAART and clinical support is beneficial.

Re-introduction of HAART after interruption due to mitochondrial toxicity is a challenge and no evidence-based guidelines are available. Options for patients with HANWS could include double-boosted protease inhibitor (PI)¹¹, combination of non-nucleoside reverse transcriptase inhibitor (NNRTI) and boosted PI¹², or a combination of a nucleotide analogues, NNRTI, and a boosted PI (Case 1). Other therapeutic associations, such as PI with novel groups of antiretrovirals (p.e inhibitors of entry) can represent alternative options, especially in patients with high level of resistance (Case 2). Alternatively, avoiding stavudine or didanosine, the nucleosides with the highest association with mitochondrial toxicity, may be a satisfactory alternative in the long run.

In developing countries, it is feared that widespread use of stavudine, increased prevalence of

HIV in women, and difficulty in monitoring therapy closely might lead to widespread HANWS with attendant morbidity and mortality. A further challenge is that the possibility of other etiologies including nutritional deficits, and co-infections such as cytomegalovirus, tuberculosis, and syphilitic polyradiculomyelitis should be included in the differential diagnosis. These may be prominent issues in developing nations. Optimal care will include both early recognition of this syndrome with discontinuation of the nucleosides, supportive care, and appropriate exclusion of alternative treatable causes.

REFERENCES

1. Marins JR, Jamal LF, Chen SY, et al. Dramatic improvement in survival among adult Brazilian AIDS patients. *AIDS* 2003;17:1675-1682.
2. d'Arminio Monforte A, Cinque P, Mocroft A, et al. EuroSIDA Study Group. Changing incidence of central nervous system in the EuroSIDA cohort. *Ann Neurol* 2004;55:320-328.
3. Trujillo JR, Jaramillo-Rangel G, Ortega-Martinez M, et al. Internacional NeuroAIDS: prospects of HIV-1 associated neurological complications. *Cell Research* 2005;15:962-969.
4. Simpson D, Estanislao L, Evans S, et al. HIV-associated neuromuscular weakness syndrome. *AIDS* 2004;18:1403-1412.
5. Ferrari S, Vento S, Monaco S, et al. Human immunodeficiency virus - associated peripheral neuropathies. *Mayo Clin Proc* 2006;81:213-219.
6. Okie S. Fighting HIV - Lessons from Brazil. *N Engl J Med* 2006;354:1977-1980.
7. Höke A, Cornblath DR. Peripheral neuropathies in human immunodeficiency virus infection. *Clin Neurophysiol* 2004;57(Suppl):S195-S210.
8. Keswani SC, Pardo CA, Cherry CL, Höke A, McArthur JC. HIV-associated sensory neuropathies. *AIDS* 2002;16:2105-2117.
9. Estanislao L, Thomas D, Simpson D. HIV neuromuscular disease and mitochondrial function. *Mitochondrion* 2004;4:131-139.
10. Luciano CA, Pardo CA, McArthur JC. Recent developments in the HIV neuropathies. *Curr Opin Neurol* 2003;16:403-409.
11. Boffito M, Maitland D, Samarasinghe Y, Pozniak A. The pharmacokinetics of HIV protease inhibitor combinations. *Curr Opin Infect Dis* 2005;18:1-7.
12. Joly V, Descamps D, Yeni O. NNRTI plus PI combinations in the perspective of nucleoside-sparing or nucleoside-failing antiretroviral regimens. *AIDS Rev* 2002;4:128-139.