

## Nanoparticles in treatment of thermal injured rats: Is it safe?

This content has been downloaded from IOPscience. Please scroll down to see the full text.

2011 J. Phys.: Conf. Ser. 304 012027

(<http://iopscience.iop.org/1742-6596/304/1/012027>)

View [the table of contents for this issue](#), or go to the [journal homepage](#) for more

### Download details:

IP Address: 143.106.108.146

This content was downloaded on 19/06/2015 at 18:33

Please note that [terms and conditions apply](#).

## Nanoparticles in treatment of thermal injured rats: Is it safe?

P S Melo<sup>1,2</sup>, P D Marcato<sup>3</sup>, S C Huber<sup>2,3</sup>, I R Ferreira<sup>1,2</sup>, L B de Paula<sup>3</sup>,  
A B A Almeida<sup>4</sup>, N Durán<sup>3,5</sup>, S Torsoni<sup>6</sup>, A B Seabra<sup>7</sup> and O L Alves<sup>3</sup>

<sup>1</sup>Biochemistry Department, Universidade Estadual de Campinas (UNICAMP), SP, Brazil

<sup>2</sup>VERIS, Campinas, SP, Brazil

<sup>3</sup> Chemistry Institute, UNICAMP, SP, Brazil

<sup>4</sup>SOBRAPAR, Campinas, SP, Brazil

<sup>5</sup> Universidade Federal do ABC (UFABC), Santo André, SP, Brazil,

<sup>6</sup>FCA, UNICAMP, SP, Brazil

<sup>7</sup> Universidade Federal de São Paulo, SP (UNIFESP), Diadema, SP, Brazil

E-mail: pmelo@unicamp.br

**Abstract.** The aim of this study was to assess whether thermal trauma induced oxidative stress altered the balance between oxidant and antioxidant systems in the blood of burn wound rats in the absence and presence of silver nanoparticles and S-nitrosoglutathione, GSNO. Free silver nanoparticles, free GSNO and silver nanoparticles + GSNO had no cytotoxic effects. Under anesthesia, the shaved dorsum of the rats was exposed to 90°C (burn group) water bath. Studied compounds were administered topically immediately and at 28 days after the burn injury, four times a day. Silver nanoparticles and silver nanoparticles + GSNO were no toxic *in vitro* and *in vivo*. There were no significant differences in the levels of urea, creatinine, aminotransferases and hematological parameters, in control-burn groups (free silver nanoparticles) and treated-burn groups (free GSNO or silver nanoparticles + GSNO). There were no differences in lipid peroxidation and in the levels of protein carbonyls and glutathione, used as oxidative stress markers. A little inflammatory cell response, papillary dermis vascularization, fibroblasts differentiated into contractile myofibroblasts and the presence of a large amount of extracellular matrix were evidenced in treated groups following skin injury. These results indicate that silver nanoparticles and GSNO may provide an effective action on wound healing.

### 1. Introduction

The aim of wound healing is a speedy recovery with minimal scarring and maximal function. Wound healing proceeds through an overlapping pattern of events including coagulation, inflammation, proliferation, matrix and tissue remodelling. For this efficient and highly controlled repair process to take place, numerous cell-signalling events are required [1]. Silver has been used for centuries to

prevent and treat a variety of diseases including pleurodesis, cauterisation, and healing of skin wound [1]. The use of silver in the past has been restrained by the need to produce silver as a compound, thereby increasing the potential side effects. It has been reported [1] that the overall decrease in the inflammatory response at local wound sites in the silver nanoparticles group mimic the events observed in the further confirming the detrimental effects of inflammation on healing. They conclude that silver nanoparticles can modulate local and systemic inflammatory response following burn injury by cytokine modulation.

Nanotechnology includes the production of nanoparticles, defined as particles with three dimensions of less than 100 nm. Due to their small size, nanoparticles exhibit greater specific surface areas and surface energies, and generally increased surface reactivity than those of the conventional (larger) forms, leading to vastly different properties. For these reasons nanoparticles are being increasingly employed in a variety of consumer products, including paints, cosmetics, medicines, food and sun block lotions [2].

Silver ions have been used for centuries to prevent and treat a variety of diseases including pleurodesis, cauterization, and healing of skin wounds. The antibacterial property is important to prevent bacteria growth in the wound. Furthermore, some authors have reported possible pro-healing properties of silver [3]. For example, Tian and collaborators [1] verified that silver nanoparticles can promote wound healing and reduce scar appearance in a dose-dependent manner. Furthermore, the authors showed that silver nanoparticles act by decreasing inflammation through cytokine modulation. GSNO is an endogenous found nitric oxide (NO) donor that exhibit NO-like activities such as the inhibition of platelet adhesion, vasodilation, microbicidal actions, and wound healing [4-8]. Thus, combination of GSNO and silver nanoparticles has a great potential to promote wound healing.

The central role of liver and kidney in drug metabolism predisposes them to toxic injury. Hepatic metabolism is a mechanism that converts drugs and other compounds into products that are more easily excreted. A metabolite may have higher activity and/or greater toxicity than the original drug. Metabolites of the drugs that are excreted from kidneys may also cause cellular damage leading to kidney dysfunction.

The aim of this study was to assess whether thermal trauma induced oxidative stress altered the balance between oxidant and antioxidant systems in the blood of burn wound rats in the absence and presence of compounds (silver nanoparticles and GSNO). Previously, it was evaluated the cytotoxic effects of these substances in fibroblast V79 cell culture. Moreover, it was evaluated if these substances induce toxic effects in kidneys (urea and creatinine measurements), in liver (alanine and aspartate aminotransferases) and in hematological parameters.

## 2. Methods

### 2.1. Silver nanoparticles production

The fungal inoculates were prepared in a malt extract 2% and yeast extract 0.5% at 28°C in Petri plates. Silver reduction was carried out as described: approximately 10 g of *F. oxysporum* biomass was taken in a conical flask containing 100 mL of distilled water, kept for 72 h at 28°C and then the aqueous solution components were separated by filtration. To this solution, AgNO<sub>3</sub> (10-3M) was added and kept for several hours at 28°C [7,8].

### 2.2. Transmission Electron Microscopy (TEM) analysis

The silver nanoparticles were characterized by Transmission Electron Microscopy (TEM) (Carl Zeiss CEM-902 transmission electron microscope, 80 KeV). For the examination of the silver particle, one drop of the particle dispersion was deposited on carbon-coated parlodion films supported in 300 mesh copper grids (Ted Pella).

### 2.3. GSNO synthesis

GSNO was synthesised as previously reported [9, 10]. In brief, glutathione (GSH) was nitrosated by adding equimolar amount of sodium nitrite ( $\text{NaNO}_2$ ) in acidified aqueous solution.

### 2.4. Gel preparation

Carbopol 940® gel (0.1%) with propyleneglycol (5%) was prepared. Silver nanoparticles or GSNO (10-50% w/w) was added to the Carbopol gel.

### 2.5. Cytotoxicity of silver nanoparticles and silver nanoparticles + GSNO

The cytotoxicity of silver nanoparticles and silver nanoparticles + GSNO was assessed in a permanent lung fibroblast cell line (V79) culture derived from Chinese hamster [11]. These cells are commonly used for cytotoxicity studies [10]. V79 fibroblasts were grown as monolayers in Dulbecco's modified Eagle's medium (DMEM) supplemented with 10% fetal bovine serum, 100 IU of penicillin/ml and 100 Ag of streptomycin/ml in a humidified incubator with 5%  $\text{CO}_2$  in air at 37 °C. The cells were plated at a density of  $3 \times 10^4$  cells/ml in 96-well plates. Forty-eight hours after cell seeding, semiconfluent cultures were exposed to silver nanoparticles and silver nanoparticles + GSNO, at different concentrations (0 - 22  $\mu\text{M}$  of silver nanoparticles). The maximum concentration of silver nanoparticles + GSNO was 22  $\mu\text{M}$  of silver nanoparticles + 8  $\mu\text{M}$  of GSNO. The cells were exposed for 24h to the test medium with or without the compounds studied (control). Each concentration was tested in six replicates in each of three separate experiments. At the end of the incubation, two independent endpoints for cytotoxicity (MTT reduction and neutral red uptake) were evaluated.

### 2.6. Endpoint tests for cytotoxicity

**2.6.1. Neutral red uptake (NRU):** The NRU was measured by the method of Borefreund and Puerner [11]. Briefly, cells were washed once with PBS after removal of the culture medium. After 4 h of incubation with serum-free medium containing neutral red (50  $\mu\text{mol/L}$ ), the cells were washed in PBS, followed by the addition of 0.1 ml of a solution of 1% acetic acid and ethanol (50%) to each well to fix the cells and to remove the neutral red from the solution. The plates were shaken gently for 20 min on a plate shaker, and the absorbance of the solution was read at 540 nm (VersaMaxk, Tunable Microplate Reader).

**2.6.2. Methylthiazoletetrazolium (MTT) reduction:** The MTT reduction assay was performed as described by Denizot and Lang [14]. Briefly, cells were washed once with PBS before adding 0.1 ml of serum-free medium containing 0.05% of MTT salt to each well. After incubation for 5h, the culture medium was removed and 0.1 ml of ethanol was added to each well to solubilize the formazan formed. The plates were shaken gently for 10 min and the absorbance was measured at 570 nm (VersaMaxk, Tunable Microplate Reader, Molecular Devices, Co., Sunnyvale, CA, USA).

### 2.7. Thermal injury animal and treatment

Male Wistar rats (250-300g; CEMIB/UNICAMP, Brazil) were used. Throughout the experiment, animals were housed in the same care facility with food and water available during a 12 hour light/dark cycle. Animal care was carried out in accordance with guidelines approved by the Ethical Animal Committee (Unicamp). Major thermal injury model has been previously described as a suitable model demonstrating the response associated with thermal injury [1]. Briefly, rats were anesthetized with ketamine/xylazine intraperitoneal 2% 20 mg/Kg; their dorsal body surface hair shaved off, and placed in an appropriately sized template device such that the shaved area of the skin on the animals' back was exposed. The template device was then lowered into a hot water bath (90°C) to immerse the exposed skin area in hot water for 10 seconds. With this technique, full thickness third degree thermal injury comprising 30% of the total body surface were obtained. Sham rats were

subjected to identical anesthesia and other treatments, except that they were immersed in 37°C water. After the thermal injury, five treatments were used on the dorsal skin: free Carbopol gel (positive control group, n=7, and negative control group, n=7); silver nanoparticles (1% m/v) (Ag group, n=7); free GSNO (GSNO group, n=7) (2 mM); silver nanoparticles + GSNO (1% m/v) (Ag-GSNO group, n=7) and silver sulfadiazine (1% m/v) (sulfadiazine group, n=7), four time a day. After 28 days, the animals were euthanized and its blood was collected for the biochemistry analyses and hematological parameters (toxic effects *in vivo*) and oxidative stress analysis. The burned dorsal skin was carefully removed for the histological analysis.

## 2.8. Toxic effects *in vivo*

2.8.1. *Biochemistry analyses*: Urea, creatinine, aspartate aminotransferase (AST) and alanine aminotransferase (ALT) values were analyzed in blood serum, using a Bioplus biochemical analyzer and LabTest reagents.

2.8.2. *Hematological parameters*: Leukocyte, erythrocyte and platelet counts and hemoglobin concentration were analyzed using KX21 system.

## 2.9. Oxidative stress analysis

Thiobarbituric acid reactive substances (TBARS), protein carbonyls and reduced glutathione (GSH) were measured as previously described [15].

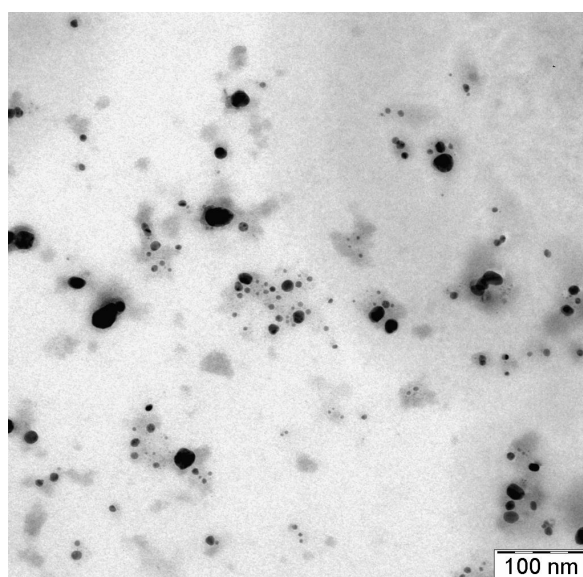
## 2.10. Histological analysis

After 28 days of thermal injury and treatment the damaged skins were removed, fixed in 4% phosphate-buffered formalin, and embedded in paraffin. From the paraffin embedded tissue-blocks, 5 µm sections were serially cut and stained with hematoxylin-eosin (H&E). The sections were examined by light microscopy using a Leica FW 4500 B microscope.

## 3. Results and Discussion

### 3.1. Silver nanoparticles production

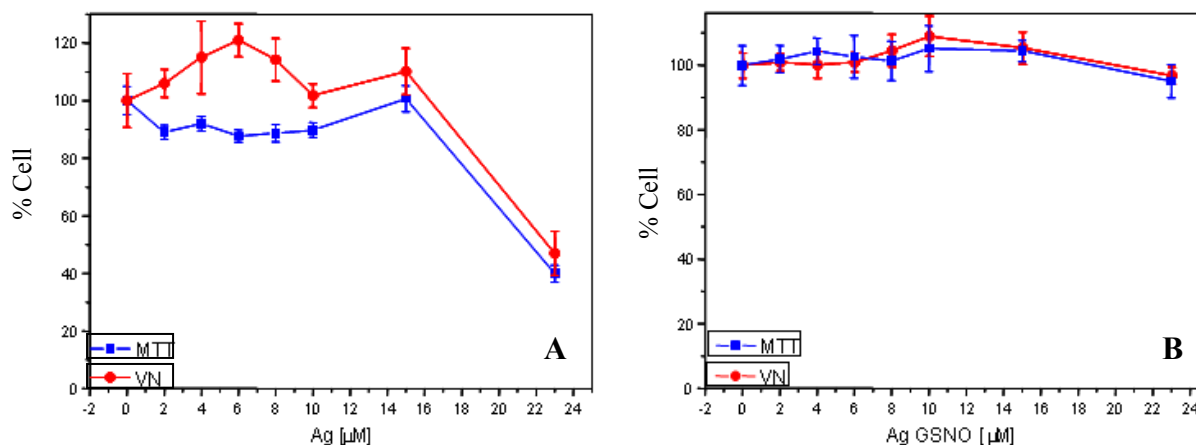
Spherical nanoparticles with size between 10-30 nm were observed by TEM analysis as shown the Figure 1.



**Figure 1.** TEM micrograph of silver nanoparticles

### 3.2. Cytotoxicity of silver nanoparticles and silver nanoparticles + GSNO

Free glutathione (GSH) has shown to be no cytotoxic to fibroblast V79 cells in the lysosomal (NRU) assay and slightly cytotoxic to mitochondrial (MTT) assay (15-20% around to 10  $\mu\text{M}$  – data not shown). Silver nanoparticles have shown to be no cytotoxic until 16  $\mu\text{M}$ , evaluated by NRU and MTT assays (Figure 2A). Silver nanoparticles + GSNO also have shown to be no cytotoxic in the same assays (100% of viability until 22  $\mu\text{M}$  concentration of silver nanoparticles and 8  $\mu\text{M}$  of GSNO) (Figure 2B).



**Figure 2.** Cytotoxicity in V79 fibroblast cell culture in the presence of silver nanoparticles (Figure 2A) and silver nanoparticles + GSNO (Figure 2B). Concentration of silver nanoparticles 0-22  $\mu\text{M}$ .

### 3.3. Toxic effects *in vivo*

The effects of silver nanoparticles and silver nanoparticles + GSNO on selected renal and liver function biochemistry tests (urea and creatinine concentrations, AST and ALT activities) in the animals submitted to thermal injury were presented in Table 1.

**Table 1.** Effects of thermal injury and/or treatment with silver nanoparticles and silver nanoparticles + GSNO *in vivo*

	Sham	Negative Control	Positive Control	Ag	GSNO	Ag-GSNO	Sulfadiazine	p*
<b>Urea (mg/dL)</b>	3.85 $\pm$ 0.50	4.14 $\pm$ 0.67	4.00 $\pm$ 0.37	3.83 $\pm$ 0.30	3.17 $\pm$ 0.48	5.28 $\pm$ 0.68	4.14 $\pm$ 0.45	p>0.05
<b>Creatinine (mg/dL)</b>	0.56 $\pm$ 0.03	0.55 $\pm$ 0.01	0.54 $\pm$ 0.02	0.45 $\pm$ 0.02	0.63 $\pm$ 0.02	0.54 $\pm$ 0.04	0.49 $\pm$ 0.01	p>0.05
<b>AST (U/L)</b>	60.43 $\pm$ 16.99	62.43 $\pm$ 15.82	75.71 $\pm$ 27.15	81.67 $\pm$ 25.93	96.83 $\pm$ 15.82	89.57 $\pm$ 8.24	81.57 $\pm$ 5.54	p>0.05
<b>ALT (U/L)</b>	38.29 $\pm$ 15.72	32.57 $\pm$ 9.40	30.86 $\pm$ 6.44	34.00 $\pm$ 16.02	42.50 $\pm$ 14.52	35.00 $\pm$ 6.51	44.71 $\pm$ 1.12	p>0.05
<b>Leukocyte (cells)</b>	6128.5 $\pm$ 344.8	5971.4 $\pm$ 353.7	7442.8 $\pm$ 481.0	7457.1 $\pm$ 642.4	7414.2 $\pm$ 953.3	6771.4 $\pm$ 437.9	7357.1 $\pm$ 427.5	p>0.05
<b>Erythrocyte (cells)</b>	7.75 $\pm$ 0.22	7.94 $\pm$ 0.12	6.98 $\pm$ 0.17	7.06 $\pm$ 0.21	7.12 $\pm$ 0.16	7.26 $\pm$ 0.25	7.70 $\pm$ 0.13	p>0.05
<b>Platelet (cells)</b>	779.28 $\pm$ 70.67	783.00 $\pm$ 50.12	894.14 $\pm$ 29.17	689.14 $\pm$ 92.17	744.28 $\pm$ 88.14	934.00 $\pm$ 58.04	870.71 $\pm$ 42.37	p>0.05
<b>Hb (g/dL)</b>	13.72 $\pm$ 0.32	14.07 $\pm$ 0.21	12.37 $\pm$ 0.22	12.55 $\pm$ 0.22	12.61 $\pm$ 0.27	12.90 $\pm$ 0.28	13.82 $\pm$ 0.17	p>0.05

\*Compared to the Positive Control Group. One-Way ANOVA + Tukey Test at OriginPro 8.

Kidneys and liver are considered to be the most susceptible organs in the case of exposure and absorption of silver. The toxicity in kidneys can be evaluated by urea and creatinine measurements. The damaging effect of hepatotoxic substances on the liver is manifested by an increase of aspartate aminotransferase (AST) and alanine aminotransferase (ALT). There were no differences between the groups in relation to these tests ( $p > 0.05$ ), meaning that the thermal injury and/or the treatment have not shown toxicity in these biomarkers. The effects of silver nanoparticles and silver nanoparticles + GSNO on the hematological parameters were also presented in Table 1. There were no differences between the groups in relation to these parameters.

#### 3.4. Oxidative stress

The thiobarbituric acid reactive substances (TBARS), protein carbonyls and reduced glutathione (GSH) measurements have not shown any significant changes. These results indicate that the studied substances (silver nanoparticles and GSNO) have not induced an unbalance between oxidant and antioxidant systems.

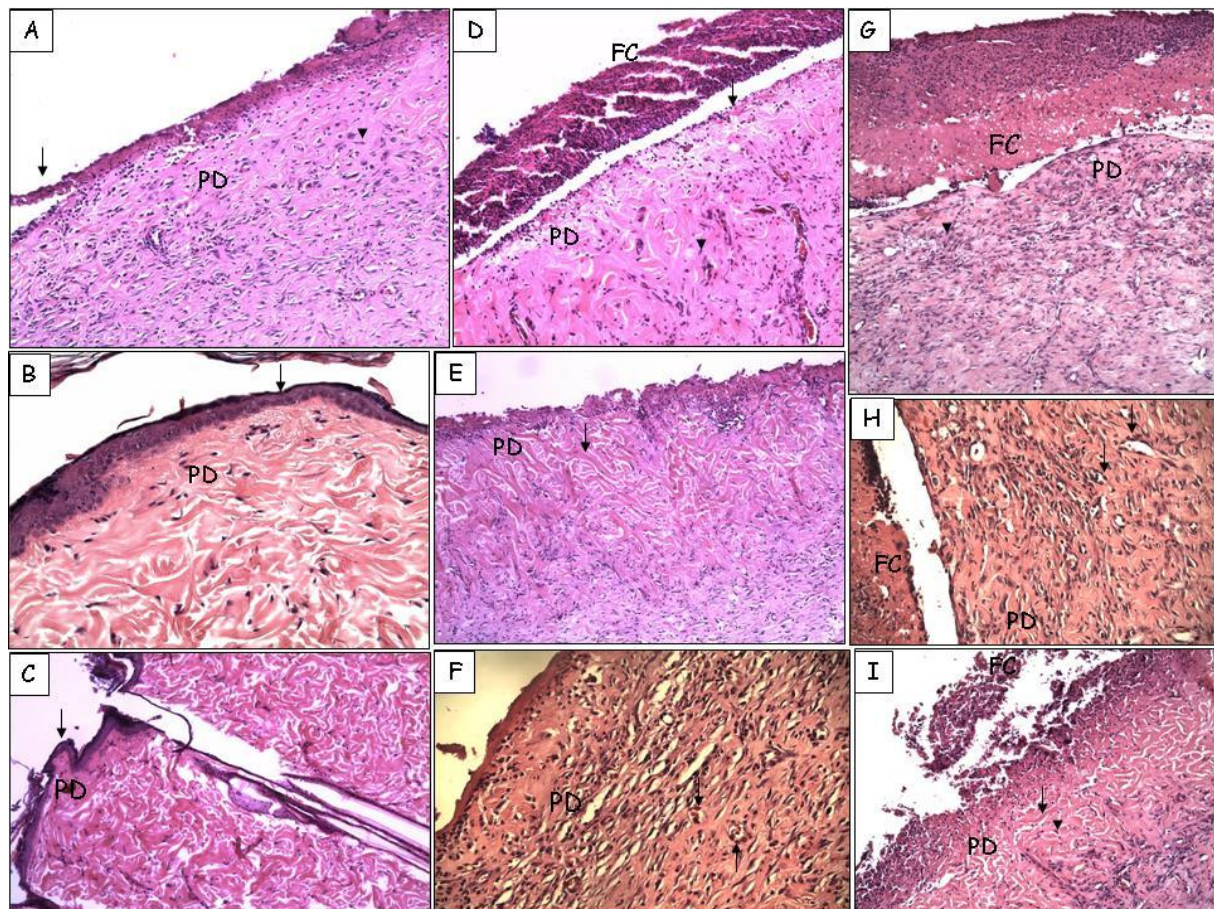
#### 3.5. Histological analysis

Animals exposed to thermal injury, treated only with Carbopol gel, presented inflammatory cells in higher amounts, few neovascularization and the extracellular matrix was poorly deposited. In Ag, GSNO, Ag-GSNO and Sulfadiazine groups, the histological analysis showed an extended area of connective tissue, where collagen and other extracellular matrix molecules were laid down. Moreover it was possible to observe a presence of myofibroblasts, cells involved with the generation of contractile force into the wound, in papillary dermis, but only a few leukocytes infiltration. A neovascularization in papillary dermis was evident. The negative control and sham groups have shown preserved epithelium and dermis, without morphological changes (Figure 3).

The ultimate goal for wound healing is a speedy recovery with minimal scarring and maximal function. Wound healing is a complex biological process that integrates the function of a variety of cell types and repair phases, including inflammation, proliferation, reepithelialization, remodeling, and maturation [8]. Rapid wound closure involves the migration of fibroblasts/keratinocytes to the wound site, where extracellular matrix (ECM) molecules are deposited. Histological analysis of tissue in MRL/MpJ mice lesions showed a delay in critical wound-healing events that culminated in a impairment of wound contraction [16]. Silver nanoparticles can modulate local and systemic inflammatory response following burn injury by cytokine modulation, that may be important in providing a permissive environment for scarless wound repair to proceed [1]. For many years, silver sulfadiazine has been the standard treatment for burns, but some of the benefits of pure silver appear to be lost. In the present study, we observed that silver nanoparticles could improve the healing of burn wounds by accelerating the process. Histologically, a delay in main events of healing was observed when wound was not treated. However a similar healing wound response in groups treated with Ag, Ag-GSNO, GSNO and those treated with sulfadiazine could be observed.

#### 4. Conclusions

Our results demonstrated that silver nanoparticles and silver nanoparticles + GSNO were no toxic *in vitro* and *in vivo*. There were no significant differences in urea, creatinine and aminotransferases levels and in the hematological parameters between the control-burn groups (silver nanoparticles) and treated-burn groups (free GSNO or silver nanoparticles + GSNO forms). Moreover, there were no significant differences in lipid peroxidation (TBARS), protein carbonyls and reduced glutathione (GSH) between the groups. A little inflammatory cell response, papillary dermis vascularization, fibroblasts differentiated into contractile myofibroblasts and the presence of a large amount of extracellular matrix could be evidenced in treated groups following skin injury.



**Figure 3.** Photomicrography of dorsal skin from rats 28 days after thermal injury. **A:** Burned region was treated only with Carbopol gel after thermal injury (positive control). Arrowhead indicates presence of fibroblasts in hyperactive state in the papillary dermis (PD). Arrow indicates necrosis area (fibrin cap). H&E 100X; **B:** Healthy skin was treated only with Carbopol gel (negative control). It is possible to observe stratified epithelium preserved (arrow) and unchanged papillary dermis. H&E 100X; **C:** Sham. Epithelium and dermis similar to negative control. H&E 100X; **D:** Burned region was treated with silver nanoparticles after thermal injury. Arrowhead indicates presence of extracellular matrix with few fibroblasts in hyperactive state in the papillary dermis (PD) and basal cells (arrow). Tick area of fibrin cap (FC). H&E 100X; **E:** Burned region was treated with GSNO after thermal injury. Arrows indicates a large amount of extracellular matrix in papillary dermis and some myofibroblasts. H&E 100X; **F:** Burned region was treated with GSNO after thermal injury. It is possible to observe increases in dermis vascularity and some leukocyte migration (arrow). H&E 200X; **G:** Burned region was treated with silver nanoparticles + GSNO after thermal injury. Arrowhead indicates the presence of miofibroblasts in papillary dermis. Fibrin cap can be observed (FC). H&E 100X; **H:** Burned region was treated with silver nanoparticles + GSNO after thermal injury. Arrow shows increases in dermis vascularity and some leukocyte migration. Fibrin cap (FC) evident. H&E 200X; **I:** Burned region was treated with silver sulfadiazine after thermal injury. Presence of extracellular matrix (arrow) and miofibroblasts (arrowhead). H&E 100X.

### Acknowledgements

Support from Brazilian Network of Nanocosmetics (MCT/CNPq), FAPESP (process number 2010/14949-4) and CNPq are acknowledged.



## References

- [1] Tian J, Wong K K Y, Ho C M, Lok C N, Yu W Y, Che C M, Chiu J F and Tam P K H 2007 *J. Chem. Med. Chem.* **2**, 129
- [2] Teli M K, Mutalik S and Rajanikant G K 2010 *Cur. Pharm. Design.* **16**, 1882
- [3] Schaller M, Laude J, Bodewaldt H, Hamm G and Korting H C 2004 *Skin Pharmacol. Physiol.* **17**, 31
- [4] Seabra A B, da Silva R, de Souza G F P and de Oliveira M G 2008 *Artif. Organs* **32**, 262
- [5] Seabra A B, Pankotai E, Fehér M, Somlai A, Kiss L, Bíró L, Szabó C, Kollai M, de Oliveira M G and Lacza Z 2007 *Br. J. Dermatol.* **156**, 814
- [6] Seabra A B, Martins D, Simões M M S G, da Silva R, Brocchi M and de Oliveira M G 2010 *Artif. Organs* **34**, E204
- [7] Durán N, Marcato P D, Alves O L, De Souza G I H, Esposito E 2005. *J. Nanobiotechnol.* **3**, 1.
- [8] Durán N, Marcato P D, De Souza G I H, Alves OL, Esposito E 2007. *J. Biomed. Nanotechnol.* **3**, 203.
- [9] Amadeu T P, Seabra A B, de Oliveira M G and Costa A M A 2007 *J. Eur. Acad. Dermatol. Venereol.* **21**, 629
- [10] Amadeu T P, Seabra A B, de Oliveira M G and Costa A M A 2008 *J. Surg Res.* **149**, 84
- [11] [Correa D H A, Melo P S, de Carvalho C A A, de Azevedo M B M, Durán N and Haun M 2005 *Eur. J. Pharmacol.* **510**, 17
- [12] de Conti R, Oliveira D A, Fernandes A M A P, Melo P S, Rodriguez J A, Haun M, Castro S L, Souza-Brito A R M and Durán N 1998 *In vitro Mol. Toxicol* **11**, 153
- [13] Borefreund E and Puerner J A 1984 *J. Tissue Cult. Methods* **9**, 7
- [14] Denizot F and Lang R 1986 *J. Immunol. Methods*, **89**, 271
- [15] Michailidis Y, Jamurta A Z, Nikolaidis M G, Fatouros I G, Koutedakis Y and Papassotiriou I 2007 *Med. Sci. Sport Exerc.* **39**, 1107
- [16] Davis T A, Amare M, Naik S, Kovalchuk A L and Tadaki D 2007 *Wound Repair Regen.* **15**, 577