

# SCHWANNOMA OF THE CRANIOCERVICAL JUNCTION

## Surgical approach of two cases

*Manoel Baldoino Leal Filho<sup>1</sup>, Guilherme Borges<sup>2</sup>, Arnaldo Ferreira<sup>1</sup>, Daniel França<sup>3</sup>, Patricia Mello<sup>4</sup>*

**ABSTRACT** - We report two cases of craniocervical junction schwannomas with a special focus on the surgical approach. The patients underwent a far-lateral approach in the sitting position that facilitated the lesion removal. This report is meant to improve the understanding of this surgical technique as well as improve awareness of its usefulness for similar cases.

**KEY WORDS:** craniocervical junction, far-lateral approach, schwannoma.

### **Schwannoma da transição craniocervical: nota técnica de dois casos**

**RESUMO** - Relatamos dois casos de schwannoma da transição craniocervical e chamamos a atenção para alguns detalhes da técnica cirúrgica. Os pacientes foram submetidos ao acesso cirúrgico tipo extremo lateral, em posição sentada, o que facilitou a remoção da lesão. O presente relato é contribuição para melhor entendimento da técnica cirúrgica a ser empregada em casos semelhantes.

**PALAVRAS-CHAVE:** transição craniocervical, acesso cirúrgico extremo lateral, schwannoma.

The craniocervical junction is the possible site of several pathological processes, such as degenerative disease, tumors, aneurysms, vascular malformations and traumatic lesions<sup>1,2</sup>. Salas et al., 1999<sup>3</sup> reported 51 patients with tumors of this region. There were 24 meningiomas, 10 chordomas, 7 paragangliomas, 3 schwannomas, 2 chondrosarcomas, 2 neurofibromas, and one each of hemangiopericytoma, osteochondroma, and metastatic carcinoma. The schwannomas are benign tumors of the spinal and cranial nerves<sup>4-6</sup> and represent about 8% of all intracranial tumors<sup>7</sup>. Schwannomas located at the craniocervical region are rare<sup>3</sup>. The clinical presentation is variable, depending on its location and can be associated with neurofibromatosis<sup>4</sup>. The structures that must be considered when planning the surgical approach to the craniocervical junction are the medulla and the spinal cord, the lower cranial and upper spinal nerves, the vertebral artery and its branches, the veins and dural sinuses, and the ligaments and muscles uniting the atlas, axis and occipital bone<sup>2,8</sup>.

A number of surgical access routes to this region

are currently in use, including the transoral, trans-cervical, bifrontal transbasal, infratemporal, trans-petrosal, retromastoid, the far-lateral approach and its transcondylar, supracondylar, and paracondylar extensions and combined supra- and infratentorial approaches<sup>1,8,9</sup>. Lateral, far-lateral or extreme lateral approaches are most widely used to remove tumors anterior or lateral to the brain stem. Bony resection is important to gain free exposure of the area and to limit manipulation of the vascular and neural structures<sup>9,10</sup>. Samii et al., 1996<sup>10</sup> pointed out that the far-lateral or extreme lateral approaches are a variant of the lateral suboccipital approach with opening of the foramen magnum. They explained that the angle of approach and the working space for the surgeon are sufficient when a standard lateral suboccipital craniotomy is combined with drilling the posterior third of the occipital condyle.

We report the sequential steps of the far-lateral approach and the details of the microsurgical technique used in two cases of schwannoma of the craniocervical junction.

<sup>1</sup>Neurosurgeon, Getúlio Vargas Hospital, Teresina PI, Brazil; <sup>2</sup>Neurosurgeon, State University of Campinas (UNICAMP), Campinas SP, Brasil; <sup>3</sup>Medical Student of the Federal University of Piauí, Teresina PI, Brazil. <sup>4</sup>Intensivist, Getulio Vargas Hospital, Teresina PI, Brazil.

Received 11 November 2002, received in final form 20 February 2003. Accepted 13 March 2003.

*Dr. Manoel Baldoino Leal Filho - Rua Thomaz Tajra 1222, Ed. Excalibur/300 - 64048-380 Teresina PI - Brasil. E-mail: manaelbaldoino@uol.com.br*

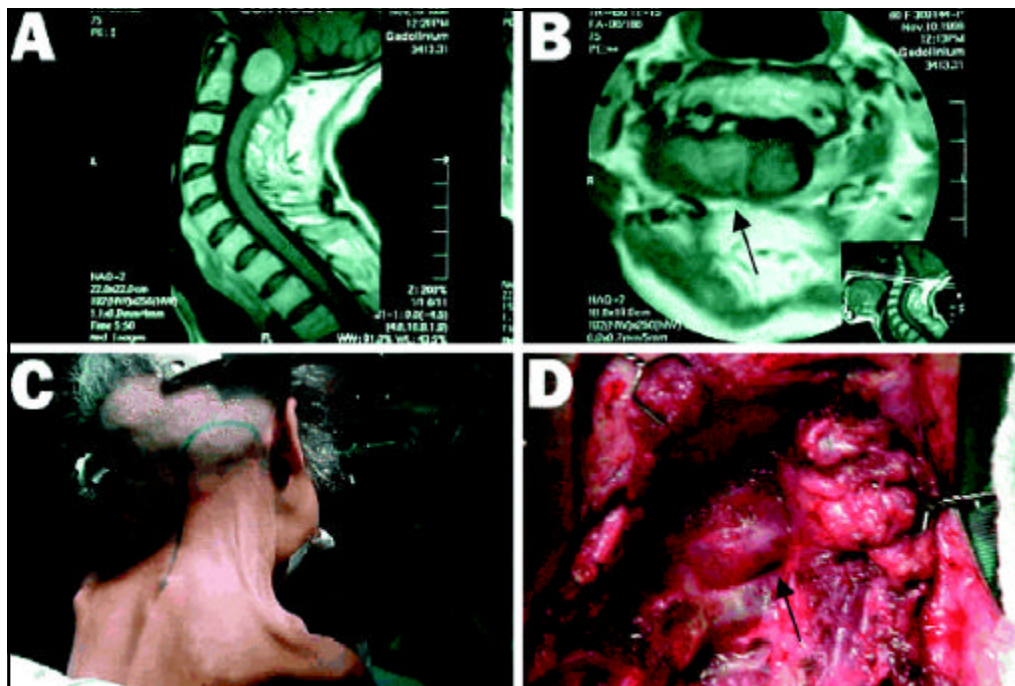


Fig 1. T1-weighted gadolinium-enhanced MRI (A- sagittal view, and B- axial view) reveals a mass lesion extending from the craniocervical junction to the vertebral artery. (C) The exposure was done using a hockey stick incision in the right side with the patient in the sitting position. (D) The lesion was seen after the removal of the ipsilateral posterior arc of the C1 vertebrae.

## CASES

**Case 1.** A 43-year-old man developed a four-month history of progressive quadriparesis. There was a more recent history of headache. When he was admitted, he had been walking with difficulty and had weakness and dysesthesias of the upper extremities. He was submitted to a Gadolinium-enhanced, T1-weighted magnetic resonance imaging (MRI) which revealed a 2.2 X 3.8 cm lesion, located at the craniocervical junction, extending from the anterior portion of the foramen magnum to the right side up to the limit of the posterior arc and lateral mass of C1. There was no signal alteration in the brain stem, which would suggest anatomical lesion.

**Case 2.** A 59-year-old woman developed a six-month history of progressive quadriparesis and increasing difficulty in breathing and swallowing. When she was admitted she was no longer able to walk and had an episode of aspiration pneumonia thought to be secondary to a IX and X cranial nerves paresis. She was submitted to a Gadolinium-enhanced, T1-weighted MRI that showed a 3.5 X 1.7 cm lesion, located at the craniocervical junction, extending from the anterior portion of the foramen magnum to the right side over to the vertebral artery (Fig 1-A and B). The lesion was leading to compression of the upper cervical cord and lower medulla.

Both patients were submitted to the same procedure described here. The illustrations shown below were recorded from Case 2. Under general anesthesia the head was fixed with a Mayfield device. In the sitting position, using

a hockey stick incision extending from the mastoid process and through the superior nuchal line as far as the midline, continuing inferiorly down to C4 vertebral level, a far-lateral approach was performed (Fig 1-C). The myocutaneous flap was elevated to expose the posterior craniovertebral junction, deviating laterally on the subocciput toward the right side. Ipsilateral posterior arc of the C1 vertebrae was removed (Fig 1-D). The lesion originating from the right C1 root was totally removed (Fig 2-A). The C1 root ipsilateral to the tumor was cut in both cases because of the great extension of the lesion originated from that root.

The patients had a prompt recovery upon total removal of the tumor with marked improvement of their neurological status. Post-operatively they were submitted to rehabilitation and at a six-month follow up visit both patients were able to walk, talk, swallow and breathe without any difficulties. Pathology analysis reported the tumors to be a schwannoma (Fig 2-B) in both cases. Postoperative Gadolinium-enhanced, T1-weighted MRI showed no residual tumor (Figs 2-C and 2-D).

## DISCUSSION

This report describes a surgical approach to an anterolateral placed schwannoma of the craniocervical junction. In our two cases the patients were operated on from the sitting position.

Some authors prefer to place the patient in the supine position<sup>1,3,9,11</sup> with the body rotated 45° to the opposite side<sup>11</sup>. Others prefer the sitting position,

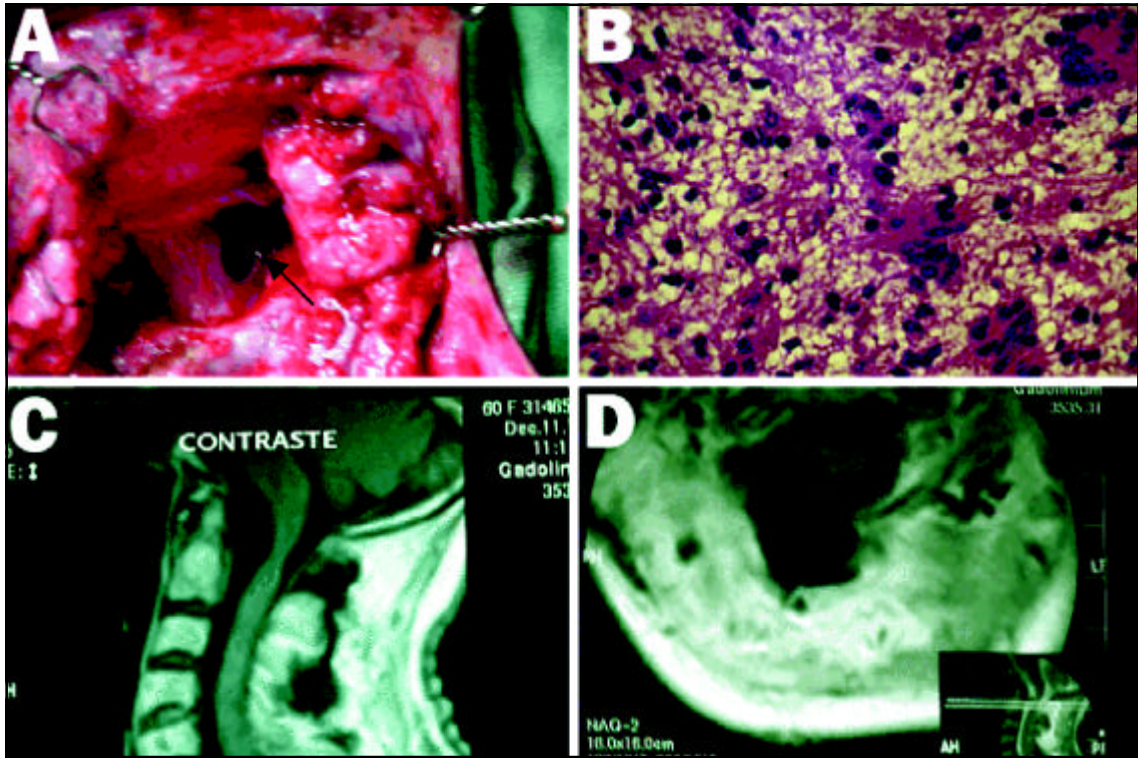


Fig 2. (A) Operation site after total removal of the lesion. (B) Photomicrograph of the lesion (hematoxylin and eosin; original magnification, X 40) showing a schwannoma. (C and D) Postoperative gadolinium-enhanced T1-weighted MRI showed no residual tumor (sagittal and axial view respectively).

with the head flexed ventrally and rotated approximately 30° ipsilaterally and tilted slightly to the contralateral site of the surgical approach<sup>12</sup>. The extreme-lateral craniocervical technique developed progressively as a more lateral approach to lesions in the midline on the anterior aspects of the foramen magnum<sup>3,9</sup>.

The surgical anatomy determines the access gained through lateral approaches and the intradural structures are visualized through windows between 9<sup>th</sup> and 12<sup>th</sup> cranial nerves and C2<sup>8</sup>. Lateral, far-lateral or extreme lateral approaches are most widely used to remove tumors anterior or lateral to the brain stem. Bony resection is important to gain free exposure of the area and to limit manipulation of the vascular and neural structures<sup>9,10</sup>.

Samii et al., 1996<sup>10</sup>, reported that the far-lateral or extreme lateral approach is a variant of the lateral suboccipital approach with opening of the foramen magnum. They demonstrated that the angle of approach and the working space for the surgeon are sufficient once a standard lateral suboccipital craniotomy is combined with drilling the posterior third of the occipital condyle.

Regarding the neural structures, the C1 root can be cut without any apparent adverse effects<sup>3</sup>, as in these case reports.

The far-lateral approach with the patients in the sitting position was markedly important and facilitated the total removal of the schwannoma. This report is meant to increase awareness of the usefulness of this surgical technique when approaching these cases.

## REFERENCES

- Baldwin H, Christopher G. The far lateral/combined supra- and infratentorial approach. *J Neurosurg* 1994;81:60-68.
- Oliveira E, Rhoton AL Jr, Peace D. Microsurgical anatomy of the region of the foramen magnum. *Surg Neurol* 1985;24:293-352.
- Salas E, Sekhar LN, Ziyal IM, Caputy AJ, Wright DC. Variations of the extreme-lateral craniocervical approach: anatomical study and clinical analysis of 69 patients. *J Neurosurg* 1999;90(Spine 2):206-219.
- Martins RS, Suzuki SH, Sanematsu P Jr, Plese JPP. Acoustic neuroma in children without association with neurofibromatosis: report of two cases. *Arq Neuropsiquiatr* 1999;57:96-100.
- Paiva MA Neto, Stamm AC, Braga FM. Mandibular trigeminal schwannoma: case report. *Arq Neuropsiquiatr* 2001; 59:959-963.
- Siqueira MG, Jennings E, Moraes OJS, et al. Naso-ethmoid schwannoma with intracranial extension: case report. *Arq Neuropsiquiatr* 2001;59:421-423.
- Andrade GC, Paiva MA Neto, Braga FM. Thalamic intracerebral schwannoma: case report. *Arq Neuropsiquiatr* 2002;60:308-313.
- Rhoton AL Jr. The far-lateral approach and its transcondylar, supracondylar, and paracondylar extensions. *Neurosurgery* 2000;47:195-210.
- Spetzler RF, Graham TW. The far-lateral approach to the inferior clivus and the upper cervical region technical note. *BNI Quarterly* 1990;6:35-38.
- Samii M, Klekamp J, Carvalho G. Surgical results for meningiomas of the craniocervical junction. *Neurosurgery* 1996;39:1086-1095.
- Al-Mefty O, Borba LAB, Aoki N, Angtuaco E, Pait TG. The transcondylar approach to extradural nonneoplastic lesions of the craniocervical junction. *J Neurosurg* 1996;84:1-6.
- Bertalanffy H, Seeger W. The dorsolateral, suboccipital, transcondylar approach to the lower clivus and anterior portion of the craniocervical junction. *Neurosurgery* 1991;29:815-821.