

Eduardo Arantes Nogueira, Osvaldo Massaioshi Ueti,  
Wallasse Rocha Vieira

## The apical ventricular lesion in Chagas' heart disease

*Discipline of Cardiology, Department of Internal Medicine,  
Universidade Estadual de Campinas - São Paulo, Brazil*

Apical lesions of the left ventricle, ranging from endocardial thickening to aneurysms, are commonly found in Chagas' heart disease. These abnormalities can be identified by ventriculography, two-dimensional echocardiography and radioisotopic studies. Generally, clinical manifestations are limited to arrhythmias and thromboembolic. The lesions are usually small and apparently do not play a role in ventricular dysfunction.

**UNITERMS:** Chagas' heart disease.

### INTRODUCTION

Normally, the left ventricular apex has a shape of a shell and is formed by the interweaving of epicardial and endocardial fibers creating an internal double vortex, and external. When cut of the ventricle is cut longitudinally, shows a progressive thinning of the perivortical ventricular walls. Thus, the center of the vortex of the normal left ventricular measures only 1 to 2 mm thick, being formed almost only by the attachment of the endocardial and epicardial layers. The apical lesion or apical aneurysm in Chagas' heart disease is a very peculiar abnormality of the left ventricular apex; less frequently, it can also be found in the right ventricular

apex. This lesion was first observed in necropsies and was detected clinically much later by cineventriculography (12,24). A very characteristic lesion with high prevalence among patients with Chagas' heart disease, it turned out to be a cardinal sign of the disease and, by some, a pathognomonic lesion. Its pathogenesis is very disputed and it has deserved numerous studies represented by an extensive literature.

#### *Pathological Anatomy*

Characteristically, there is a thinning of the apical region with formation of an aneurysm, that is, a dilatation of the endocardial and epicardial walls (24). Sometimes the area is so thin that can be identified in necropsy studies by transillumination of the left ventricle. However other cases, though, present only a small internal dilatation of the apex, involving the perivortical musculature or only an endocardial thickening; thus the term apical lesion encompass a wider concept (6).

Oliveira et al. (24) noted that this lesion was present in 52 % of 1153 necropsies of patients with Chagas' Heart Disease; of these, 82 % were present in the left ventricle, in 9 % in the right ventricle, and in 9 % in both chambers.

#### **Address for correspondence:**

Eduardo Arantes Nogueira  
Disciplina de Cardiologia, Faculdade de Ciências Médicas  
Universidade Estadual de Campinas - Caixa Postal 6142 -  
Campinas - São Paulo - Brasil - CEP 13084-100

The presence of apical lesion did not correlate with age (10 to 89 years) neither with heart weight. Its frequency in patients with sudden death was similar to those who died in congestive heart failure. Apical thrombus was found in 25% of cases. In some cases a similar abnormality was found in the left ventricular base.

This lesion is different from myocardial infarction due to coronary occlusion, which leaves a more thick fibrous scar. Sometimes there is only an endocardial thickening but these cases are difficult to differentiate from endocardial thickening found in large and hypokinetic hearts as it can be seen in dilated cardiomyopathy.

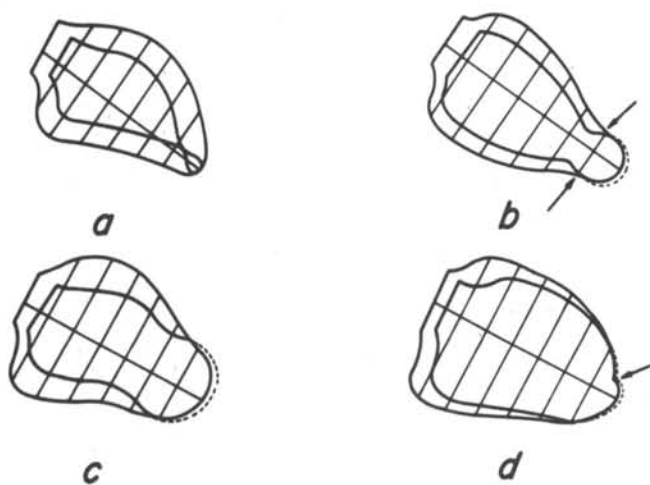
#### Ventriculographic studies

Contrasted ventriculography is still the most sensitive method for apical lesion identification but it has the disadvantage of being an invasive procedure. With this technique one can evaluate the lesion size, form and kinetic and identify the presence of thrombus. The lesion appears as an apical akinesia/dyskinesia, best seen in left anterior oblique view. In several series it appears with a mean frequency of 50%, but there is some variation according to the clinical setting and method of analysis. Garzon et al.(4) observed that 49.1% of 479 chagasic patients had apical akinesia or dyskinesia, with this distribution: in

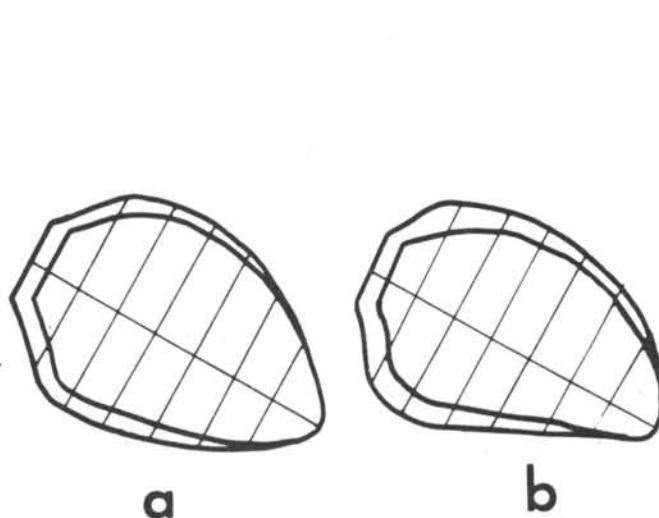
31.6% of the indeterminate form, in 43.1% of patients with abnormal electrocardiogram, in 63.9% of patients with abnormal electrocardiogram and moderate increase of cardiac size and in 62.5% of patients with electrocardiographic abnormalities and very dilated hearts. Contraction abnormalities were also observed in other regions but in small number. In one study, using wall motion analysis of the left ventricle (21). Apical akinesia/dyskinesia was found in 80% of cases with this distribution: in 50% of cases with normal ejection fraction (EF), in 80% of cases with reduced EF but above 50%, and in 100% of patients with EF below 50%.

Generally, these are small abnormalities; in our material 6 we note left ventricular volumes smaller than 5 ml/m<sup>2</sup> in 75% of cases and there was no correlation between ventricular volume and EF.

These contraction abnormalities assume several forms described as "nipple", "glove's finger", "tennis racquet", etc. In patients with EF above 50%, the transition between the apical segment and the body of the ventricle is well delimited since segmental shortening from base to apex is uniform (21). These necklike images correspond clearly to the apical lesion of Chagas' heart disease, characteristically thinned and well delimited from the body of the chamber when seen in necropsy (Figure 1 a, b, c). On the other hand, when EF is very depressed, segmental



**Figure 1.** Illustration of ventriculographic silhouettes in diastole and systole depicting the transition zone between the apical akinetic/dyskinetic segment and the ventricular body. Arrows indicate notches observed even in diastole.



**Figure 2.** Ventriculographic contours in diastole and systole of 2 cases with congestive heart failure: a, patient with dilated cardiomyopathy; b, patient with Chagas' heart disease.

shortening from base to apex is progressively decreased until zero (akinesia) without a demarcatory zone as a transition (Figure 2 b). This raises the question whether these apical akinesias correspond or not to the apical lesion of Chagas' heart disease. Wall motion analysis of cineventriculograms, as depicted in figure 1 d, demonstrate that 2 different processes can lead to apical akinesia/dyskinesia: in this silhouette the apical segment is diskinetetic and is divided in 2 parts by notches observed even in diastole; the more distal portion should correspond to the apical lesion of Chagas' heart disease but the other part, still part of the apical shell and also diskinetetic, should be consequence of ventricular dilatation that, increasing the angle of the apical shell, should turn its normally helix shaped fibers more circular (23).

It should be said that apical akinesia/dyskinesia are also found in dilated and hypokinetic ventricles with dilated cardiomyopathy (30), and its differentiation from Chagas' heart disease can be unfeasible if based only on angiographic features. This point can be illustrated in Figure 2 where cineventriculograms of a patient with dilated cardiomyopathy and another with Chagas' heart disease are depicted: in both there are diffuse hypokinesia and apical akinesia.

### ***Bidimensional Echocardiography***

This method can identify the apical lesion non-invasively and plays an important role in the study of asymptomatic patients with the inaparent form. It is important in the follow up of all forms of the disease (1,15,25). Its sensibility to detect the apical lesion is in the order of 80% (15). Diagnostic images can be obtained in long axis view, in apical four-chamber and two-chamber views and in subcostal view, the latter appearing as the more sensitive.

Chagasic apical lesion is well recognized by its wall thinning and abnormal motion, making evident the abrupt transition with the ventricular body. This aspect is clearly different from ischemic aneurysms. When there is dilatation and diffuse hypokinesia this pattern may not be recognized and the image can be undistinguished from dilated cardiomyopathy. On the other hand, very small lesion can go unrecognized.

It has been demonstrated that the apical lesion occurs in all clinical forms (1,25), appearing in 25% of cases of the inaparent form. Right ventricular apical lesion is sometimes also observed. Apical thrombi are observed more frequently in cases with congestive heart failure.

### ***Electrocardiogram***

Electrocardiographic abnormalities are not associated to an specific pattern. According to Garzon et al. (9), patients can have premature ventricular contractions (60%), left anterior hemiblock (47.5%), right bundle branch block (37.4%), Q-wave pattern (23%) and repolarization abnormalities (26.4%).

### ***Nuclear Cardiology***

In a group of 23 patients with chronic Chagas' heart disease with atypical chest pain, Marin Neto et al. (16) studied thallium-201 myocardial scintigraphy after maximal effort, contrasted cineventriculography and coronary arteriography. All patients had at least one segmental perfusion defect, that was permanent in 65% and transitory in 35% of the cases. Permanent defects predominated in apical segments (88%) in agreement with cineventriculography and radioisotopic ventriculography. Fixed defects were present in 14 of 23 patients (60.87%) and ventricular akinesia/dyskinesia in 11 of 16 patients (68%). Transitory defects were observed in normal or hypokinetic segments.

## **CLINICAL SIGNIFICANCE**

### ***Ventricular function***

The apical akinetic/diskinetetic segments of Chagas' heart disease are usually small and its volumes do not correlate with ventricular volume or with EF. Thus, these abnormalities do not compromise ventricular function. Apical akinesias/dyskinesias occur generally in ventricles already dilated and hypokinetic and so are part of global functional deterioration. Sometimes, nonetheless, there are cases with large apical abnormalities whose ventricles present only little or moderate dysfunction (Figure 1c). In this setting, the apical abnormalities are responsible for a certain degree of mechanical systolic dysfunction. It should be noted that when dyskinesia is present it does not have a true systolic expansion, like in acute myocardial infarction, but a movement of translation of the whole chamber in longitudinal direction (22).

### **Thromboembolism**

Local thrombus formation is not rare and its frequency depends on ventricular dysfunction. When there is ventricular dilatation and congestive heart failure apical thrombi can be found in 50% of cases (4) and embolism is common. In less serious clinical presentations embolism is less frequent but it can be the first manifestation of the disease. Clinical management include anticoagulation and even aneurysmectomy.

### **Arrhythmias**

Complex ventricular arrhythmias are common in Chagas' heart disease and can be related to ventricular dysfunction or apical lesion; as these two situations can coexist, cases with sustained ventricular tachycardia difficult to manage with drugs need a precise definition of the arrhythmogenic site. Electrophysiological studies has demonstrated that arrhythmias can be induced and terminated by programmed stimuli (17,19), suggesting a reentry mechanism. In selected cases aneurysmectomy has been performed with good results; electrophysiological mapping during surgery has implicated the regions adjacent to the aneurysm as the source of arrhythmia.

## **PATHOGENESIS**

Because there is no agreement on the cause of this so peculiar lesion of Chagas' heart disease many hypothesis had been formulated. All take into account the anatomic singularities of the left ventricular vortex, a region normally very thin.

### **Autonomic imbalance**

According to Köberle (14), the cardiac parasympathetic depopulation of Chagas' disease would lead to a relative sympathetic hyperactivity, potent enough to cause myocardial lesions. Experimentally, apical aneurysms can be produced in rats injecting beta-sympathomimetic drugs, and they look very similar to chagasic aneurysms. However, analysis of ventriculograms of 16 symptomatic patients did not disclose a relation between chagasic aneurysms and parasympathetic depression, observed with pharmacological blocking agents (11).

### **Mechanical factor**

By careful anatomic dissections, Raso (28) noted a separation of the vortical fibers and protrusion of the endocardial and epicardial layers, a situation resembling a hernia. Then, over this myocardial weak spot, systolic pressure would act as a expanding force, stretching out the vortical fibers and producing the aneurysm.

### **Conduction disturbances**

Based on an observation of a statistical correlation between the presence of apical lesion and left anterior hemiblock, Carvalhal (5,6) postulated a causal relationship. Local delay of periapical contraction would also put forth systolic expansion of the apex, leading to apical aneurysm formation. This correlation was not found by others (2) but this mechanism would still be implicated if one considers local conduction disturbances in the same way found by Anselmi et al. (3) with epicardial electrocardiograms taken over apical aneurysms of canine heart with experimental Chagas' heart disease. In one study focusing the sequence of segmental contraction of the left ventricle of chagasic patients, with and without left anterior hemiblock, we did not observe a delay of apical segment contraction (22).

### **Myocarditis**

Several investigators (18,27,28) established conceptions that ultimately would implicate acute and chronic myocarditis plus the mechanical factor (systolic pressure): thinning of the apex would be produced by inflammatory lesions of the internal layer of the vortex, with disarray of its special architecture and progressive separation of the muscle fibers, submitted to intraventricular pressures.

### **The role played by acute myocarditis**

Although division of chagasic patients in clinical forms is somewhat artificial, it make evident the large spectrum of abnormalities, from almost normal hearts up to those with all types of alterations. The apical lesion occurs in all forms of the disease and its presence and size do not correlate with age, size of the heart, global cardiac function, electrocardiographic abnormalities or autonomic imbalance. It is, thus, independent of the natural process of the disease and it seems reasonable to be linked to the acute phase, also common to all clinical forms. Myocarditis

would do more harm in the more fragile segments of the heart, namely the apical region, allowing systolic pressures to stretch out the perivortical muscle bundles and to aneurysm formation. Obviously, aneurysms would be evident only in patients who survive the acute phase. This reasoning implies that a similar lesion should also have been observed in other acute myocarditis, an idea not shared by the majority of investigators. However, in our opinion, some reasoning would help explain why apical lesions are not found in other types of myocarditis with the frequency and exuberance of Chagas' heart disease.

There are reports of local contraction abnormalities in acute viral myocarditis (10,26,29). Also, it is possible to produce experimentally ventricular aneurysms with viral infections (7).

Prevalence of other acute myocarditis, like viral, is lesser than in Chagas' heart disease. For instance, in 5,715 necropsies performed in the Department of Pathology of Ribeirão Preto, between 1954 and 1968, 20% had Chagas' disease (24). In one Japanese series, of 377,841 necropsies only 0.1% had viral or inespecific myocarditis (31). By the same token, biological variability should be much greater in Chagas' heart disease.

Chagasic patients are easily identified by specific serologic reaction any time in their evolution. On the contrary, it is difficult to establish a specific etiologic diagnosis of acute viral myocarditis. Even more difficult

it is to establish what individuals had an acute viral myocarditis in the past. That is reason why it has been difficult to prove a causal relationship between viral myocarditis and dilated cardiomyopathy.

In countries where Chagas' disease is endemic the apical lesion is actively sought, in clinical investigations or at the necropsy table, because it represents a diagnostic aspect of a common disease. Therefore, a very small apical aneurysm can be only found at necropsy if a section is made through the left ventricular vortex. This is not the practice in other countries, where myocarditis are not common. Whether viral (or other) myocarditis produce or not a left ventricular apical lesion is, in our opinion, still an open question.

As the acute phase of Chagas' heart disease occurs in children, we believe that this special circumstance could be favorable for apical lesion formation. Infantile myocardial tissue has much less elastic rigidity because of its smaller fibers and less collagen content, and so the ventricular walls are less resistant to dyskinesia, particularly the apex and subannular regions. In some reports this point is made evident: experimental production of ventricular aneurysms in mice with Coxsackie virus infection was only possible in the suckling animals (7). In another study, Kelly et al. (13) were able to produce ventricular aneurysms in suckling rats by pharmacological inhibition of elastic and collagen fibers development.

## RESUMO

Na doença de Chagas é comum que a ponta do ventrículo esquerdo apresente lesões que vão desde um espessamento endocárdico até um aneurisma de paredes finas. Esta anormalidade pode ser identificada por ventriculografia contrastada, ecocardiografia bidimensional e estudos com radioisótopos. As manifestações clínicas em geral são limitadas a arritmias e tromboembolismo. As lesões são em geral pequenas e parecem não ter importância na mecânica ventricular.

## REFERENCES

1. ACQUATELLA, H.; SCHILLER, N.B.; PUIGBO, J.J. et al. - M-Mode and two-dimensional echocardiography in chronic Chagas' heart disease. A clinical and pathologic study. *Circulation* **62**:787-799, 1980.
2. ALMEIDA, H.O.; MIZIARA, L.J.; FRANGE, P.J. et al. - Hemibloqueio anterior esquerdo e lesão vorticilar esquerda na cardiopatia chagásica crônica. *Arq Bras Cardiol* **28**:293-297, 1975.
3. ANSELMINI, A.; PIFANO, F.; SUAREZ, J.A. et al. - Myocardopathy in Chagas' disease. *Am Heart J* **72**:469-481, 1966.
4. ARTEAGA-FERNANDES, E.; BARRETO, A.C.P.; IANNI, B.M. et al. - Trombose cardíaca e embolia em pacientes falecidos de cardiopatia chagásica crônica. *Arq Bras Cardiol* **52**:189-192, 1989.
5. CARVALHAL, S.S. - A lesão apical na cardiopatia chagásica. *Arq Bras Cardiol* **25**:257-262, 1972.
6. CARVALHAL, S.S.; NOGUEIRA, E.A.; CURTI, H.V. et al. - A lesão apical na cardiopatia chagásica. Mem Inst O Cruz, *Anais do Congresso Internacional sobre Doença de Chagas* 1979; G 13-G 17
7. EL-KHATIB, M.R.; CHASONS, J.L. & LERNER, A.M. - Ventricular aneurysms complicating Coxsackievirus Group B, Types 1 and 4 murine myocarditis. *Circulation* **59**:412-416, 1979.
8. GARZON, S.A.C.; LORGA, A.M.; JACOB, J.L.B. et al. - A cineangiografia do ventrículo esquerdo na doença de Chagas crônica. Parte I: Apreciação morfológica do V.E. e correlação com ECG e Raio-X em 479 indivíduos. Mem Inst O Cruz, *Anais do Congresso Internacional sobre Doença de Chagas* 1979; 104
9. GARZON, S.A.C.; LORGA, A.M.; JACOB, J.L.B. et al. - A cineangiografia do ventrículo esquerdo na doença de Chagas crônica. Parte III: Apreciação morfológica e aspectos clínicos e evolutivos da assinergia apical do V.E. Mem Inst O Cruz, *Anais do Congresso Internacional sobre Doença de Chagas* 1979; 106.
10. GOUDEVENOS, J.; PARRY, G. & GOLD, R. - Coxsackie B4 viral myocarditis causing ventricular aneurysm. *Int J Cardiol* **27**:122-124, 1990.
11. GRANZOTTI, J.A. - Contribuição ao estudo do "aneurisma" da ponta na cardiopatia chagásica crônica. 1973 [Tese - Faculdade de Medicina de Ribeirão Preto, USP].
12. JORGE, P.A.R. - Importância da área de acinesia apical na contratilidade do coração chagásico crônico. Perspectiva cirúrgica. *Arq Bras Cardiol* **24**:31-35, 1971.
13. KELLY, W.A.; KESTERSON, J.W. & CARLTON, W.W. - Myocardial lesions in the offspring of females rats fed a copper deficient diet. *Exp Molec Pathol* **20**:40-56, 1974.
14. KOBERLE, F. - Cardiopatia chagásica. *Hospital* **53**:9-50, 1958.
15. LOPES, N.M.P.; FILHO, J.M.; ALBANESI, F.F.M. et al. - Correlação entre os achados da ecocardiografia bidimensional e a cineventriculografia esquerda na lesão apical do ventrículo esquerdo na cardiopatia chagásica crônica. *Arq Bras Cardiol* **46**:105-113, 1986.
16. MARIN-NETO, J.A.; MARZULLO, P.; MARCASSA, C.; GALLO JR, L.; MACIEL, B.C.; BELLINA, R. & L'ABBATE, A. - Myocardial Perfusion Abnormalities in Chronic Chagas' Disease as Detected by Thallium-201 Scintigraphy. *Am J Cardiol* **69**:780-784, 1992.
17. MENDOZA, I.; JOSEPH, C.; FEDERICO, M. et al. - Sustained ventricular tachycardia in chronic chagasic myocarditis: Electrophysiologic and Pharmacologic characteristics. *Am J Cardiol* **57**:423-427, 1986.
18. MIGNONE, C. - **Alguns aspectos da cardite chagásica crônica**. São Paulo, 1958 [Tese - Faculdade de Medicina da Universidade de São Paulo].
19. MILEI, J.; PESCE, R.; VALERO, E. et al. - Electrophysiologic-structural correlations in chagasic aneurysms causing malignant arrhythmias. *Int J Cardiol* **32**:65-74, 1991.
20. NOGUEIRA, E.A. - Avaliação da cavidade ventricular esquerda de pacientes com cardiopatia chagásica crônica pela cineventriculografia. I-Tamanho, forma e movimentação global. *Arq Bras Cardiol* **50**:33-42, 1988.
21. NOGUEIRA, E.A. - Avaliação da cavidade ventricular esquerda de pacientes com cardiopatia chagásica crônica pela cineventriculografia. II-Movimentação segmentar entre diástole final e sístole final. *Arq Bras Cardiol* **50**:369-376, 1988.
22. NOGUEIRA, E.A. - Avaliação da cavidade ventricular esquerda de pacientes com cardiopatia chagásica crônica pela cineventriculografia. III- Movimentação segmentar durante o período sistólico. *Arq Bras Cardiol* **51**:135-141, 1988.
23. NOGUEIRA, E.A.; CARVALHAL, S.S.; MCMILLAN, R.M. & MARANHÃO, V. - Analysis of the position of the base and apex of the left ventricle during systole. *Cathet Cardiovasc Diagn* **13**:253-261, 1987.
24. OLIVEIRA, J.S.M.; OLIVEIRA, J.A.M.; FREDERIGUE JR., U. et al. - Apical Aneurysm of Chaga's heart disease. *Br Heart J* **46**:432-437, 1981.
25. ORTIZ, J.; BARRETO, A.C.P.; MATSUMOTO, A.Y. et al. - Alteração contrátil segmentar na forma indeterminada da doença de Chagas. Estudo ecocardiográfico. *Arq Bras Cardiol* **49**:217-220, 1987.
26. PINAMONTI, B.; ALBERTI, E.; CIGALOTTO, A. et al. - Echocardiographic findings in Myocarditis. *Am J Cardiol* **62**:285-291, 1988.
27. PUPO JR., A.P. - **Contribuição ao estudo da patogenia da lesão fibrótica apical no coração de chagásicos crônicos**. São Paulo, 1969 [Tese - Escola Paulista de Medicina].
28. RASO, P. - **Contribuição ao estudo da lesão vorticilar (especialmente do vórtice esquerdo) na cardite chagásica crônica**. 1964 [Tese - Faculdade de Medicina da Universidade de Minas Gerais].
29. SATO, Y.; OSAKU, A.; KOYAMA, S. et al. - Complete atrioventricular block associated with regional myocardial scarring in a patient with coxsackie B2 myocarditis. *Jpn Heart J* **30**:935-941, 1989.
30. TERZIS, M.A.H. - Análise da movimentação segmentar do ventrículo esquerdo em pacientes com miocardiopatia dilatada, pela cineventriculografia. No prelo.
31. WAKAFUJI, S. & OKADA, R. - Twenty year autopsy statistics of myocarditis in Japan. *Jap Circ J* **50**:1288-1293, 1986.