



The Brazilian Journal of INFECTIOUS DISEASES

www.elsevier.com/locate/bjid



Case Report

Autoimmune features caused by dengue fever: a case report

Denis Leonardo Fontes Jardim*, Daniela Miti Lemos Tsukumo, Rodrigo N. Angerami, Marco Antonio de Carvalho Filho, Mário José Abdalla Saad

Department of Internal Medicine, Universidade Estadual de Campinas, Campinas, SP, Brazil

ARTICLE INFO

Article history:

Received 26 June 2011

Accepted 24 July 2011

Keywords:

Dengue

Autoimmunity

Hematologic diseases

A B S T R A C T

Dengue virus is the most important mosquito-borne viral disease in the world. Co-circulation of the four types of dengue viruses and expansion of dengue epidemic gave rise to infection enhancement and a big expansion of clinical aspects of the disease. Herein we report a case of a 25-year-old white woman with dengue fever and numerous associated autoimmune features. Our patient had proteinuria, an extensive right pleural effusion, a thin pericardial effusion and ascites. She had a low C3 level and positive antinuclear antibody; cryoglobulins were also positive. The numerous autoimmune features of this patient were a diagnostic challenge, since she was a young woman and could be easily mistaken for a rheumatologic patient in a newly open disease. Dengue infection probably was a triggering event causing an abnormal immune response. Therefore, dengue should be suspected in patients with hematological disorders and autoimmune features in endemic regions or those who have travelled to those regions.

© 2012 Elsevier Editora Ltda. All rights reserved.

Introduction

The dengue virus is a RNA virus belonging to the Flaviviridae family¹ and is the most important mosquito-borne viral disease in the world. There are four dengue viruses transmitted mainly in tropical countries and virulence seems to be quite variable among them.² Classically, infection may be clinically asymptomatic or results in undifferentiated fever, dengue fever (DF), dengue hemorrhagic fever (DHF) or dengue shock syndrome (DSS). However, the co-circulation of the four types of dengue viruses and expansion of dengue epidemic gave rise to infection enhancement and, consequently, not only significant number of severe forms – including dengue hemorrhagic fever (DHF) and dengue shock syndrome

(DSS) – but also an increasing number of “unusual complications”.

The major pathophysiological hallmark that distinguishes DHF/DSS from DF is plasma leakage as a result of increased vascular permeability. That feature is observed instead of hemorrhagic events with secondary hypoalbuminemia or hypoproteinemia, accompanied by thrombocytopenia, altered haemostasis, and, usually, evidence of liver damage (indicated by increased aspartate aminotransferase and alanine aminotransferase). In DHF, but not in DF, there is an enhanced immune response in a host, most of them with a secondary infection, resulting in the formation of circulating immune complexes, complement activation, increased histamine release and massive release of cytokines into the blood,³ which can give origin to many unusual clinical features.

* Corresponding author at: Rua Tessália Vieira de Camargo, 126, Cidade Universitária “Zeferino Vaz”, 13083-887, Campinas, SP, Brazil
E-mail address: jardimde@gmail.com (Denis Leonardo Fontes Jardim)

Case presentation

A 25-year-old white woman was admitted to our hospital in May 2007 with a two-week history of fever, myalgia, headache and a few petechial lesions on the lower extremities. She took acetaminophen at standard doses as instructed in another service. On the seventh day of symptoms she developed disabsortive diarrhea, nausea, painful enlargement of the abdomen, edema in the legs, dyspnea and orthopnea. She had given birth five months before. She reported the occurrence of many cases of dengue infection in the area where she lived and State of São Paulo Department of Health data showed a dengue outbreak caused by dengue 3 serotype virus (DENV 3) in many regions, including that specific area.

At admission, fourteen days after the beginning of her first symptoms, she presented high temperature,

tachycardia (120 bpm), tachypnea and blood pressure of 100 x 70 mmHg. Clinical examination revealed right prominent pleural effusion, ascites, epigastric discomfort, tender hepatomegaly and splenomegaly, soft edema and a few petechiae on the legs. There were no signs of active bleeding and the tourniquet test was negative. Her history of previous infectious diseases and recent trips was also negative. Laboratory results at admission showed leucopenia, thrombocytopenia, elevated aspartate aminotransferase, alanine aminotransferase levels and γ -glutamyltransferase levels, hypoalbuminemia, proteinuria, and elevated C-reactive protein (7.62 mg/dL, [normal range < 0.5mg/dL]) and lactate dehydrogenase (Table 1). Extensive right pleural effusion was observed by chest X-ray (Fig. 1) and computed tomography also showed a thin pericardial effusion, which was subsequently confirmed by

Table 1 - Evolution of laboratory results

Variable / (unit) / [normal range]	Admission	Day 4	Discharge	Follow-up
Hematocrit (%) [37-47]	37.6	28.8	30	33.2
White cells (per mm ³) [4,000-10,000]	3,750	3,340	5,130	7,670
Neutrophils (per mm ³) [2,000-8,000]	2,150	1,560	2,110	4,540
Lymphocytes (per mm ³) [1,000-4,000]	840	1,000	2,240	2,320
Platelet count (per mm ³) [150-400,103]	95,000	94,000	325,000	299,000
Alanine aminotransferase (U/L) [\leq 34]	353	170	49	21
Aspartate aminotransferase (U/L) [\leq 27]	370	209	53	29
Alkaline phosphatase (U/L) [\leq 104]	206	162	-	117
γ -glutamyltransferase (U/L) [\leq 42]	177	134	-	93
Prothrombin time (sec)	20.2	36.4	13.0	12.6
Activated partial thromboplastin time (sec)	39.5	50.7	28.6	30.2
Albumin (g/dL) [3.4-4.8]	2.6	1.8	-	3.9
Cryoglobulin	Positive	-	-	Negative
C3 (g/L) [0.9-1.8]	-	0.39	-	1.89
C4 (g/L) [0.1-0.4]	-	0.33	-	0.46
ANA titers	-	1/320	-	Negative

ANA, antinuclear antibodies.

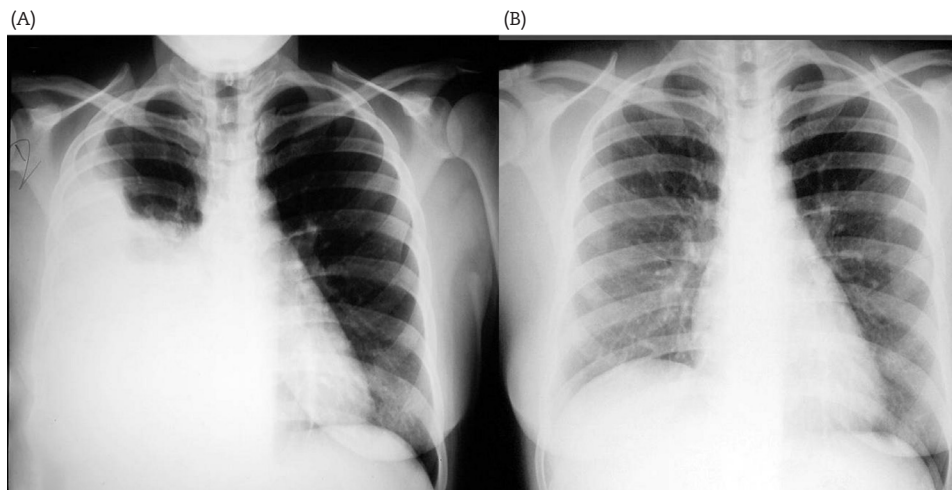


Fig. 1 - Chest X-ray at admission (A) and 2 weeks after hospital discharge (B).

echocardiography. Abdominal ultrasound and computed tomography revealed hepatomegaly, splenomegaly, and ascites but no lymphadenopathy was seen. Analyses of ascites and pleural effusion performed two days following admission revealed a lymphomonocytic exudate with elevated levels of adenosine deaminase (ADA) of 39.8 and 49.6 U/L, respectively (normal range ≤ 40 U/L). Microbiological studies (for bacterial, mycobacterial, and fungal infections) were negative. Cytological analyses of the pleural effusion showed cells suggestive of "LE cells". Bacterial and parasitological examination of feces showed no pathological findings. A 0.55 g/day proteinuria was quantified.

At admission, low C3 (0.39 g/L) and normal C4 levels were observed. A positive detection of antinuclear antibody showed a "mitotic spindle" fluoroscopic pattern. Cryoglobulins were also positive while antibodies to native DNA were negative. Serologic tests for Epstein-Barr virus, toxoplasmosis, syphilis, cytomegalovirus, HIV, and hepatitis B and C were negative. Dengue serological tests were performed and included dengue IgM capture enzyme-linked immunosorbent assay (Panbio – Queensland, Australia) positive and dengue virus IgM- and IgG specific tests (Dengue DuoCassette, PanBio), both IgM and IgG positives. These serological findings were strongly suggestive of recent dengue virus infection. Due to the advanced time of acute infection, a detection of dengue non-structural protein 1 (NS1) was not indicated.

Treatment was symptomatic with administration of crystalloids, fresh frozen plasma and vitamin K. Because a secondary bacterial infection could not be ruled out she also received antibiotics. During the first week of hospitalization patient had fever, impaired respiration and one episode of vaginal bleeding. At that time, she developed prolonged thrombin time, a drop in hemoglobin levels, and fibrinogen consumption (85.5 mg%; [normal range 220-495 mg%]) (Table 1).

Her clinical condition and laboratory tests improved during the second week and on discharge her clinical symptoms had almost disappeared. A relative lymphocytosis and reticulocytosis were observed during the recovering phase. At the first follow-up visit, she presented complete recovery and laboratory tests had normalized, including negative antinuclear antibodies.

Discussion

We have reported the case of a patient presenting with autoimmune features as an unusual complication of dengue virus infection. The severity of dengue infection is usually correlated with the size of the dengue-infected cell mass as shown many times by high titers of circulating virus in early illness blood samples or by persisting high concentrations in blood of dengue viral RNA and dengue non-structural protein 1 (NS1).⁴ This protein also parallels cellular dengue infection. High levels of markers of immune activation and severity of dengue infection have led to the hypothesis of an autoimmune response, mainly as a result of cross-reactivity between anti-NS1 to host proteins, endothelial cells and platelets,^{5,6} mediating complement activation³ and triggering plasma leakage. Molecular mimicry could be involved in the pathogenesis of this autoimmune activation.

Dengue infection may also lead to a wide range of hematological disorders, including thrombocytopenia, bone marrow suppression, platelet dysfunction, activation of fibrinolysis and disseminated intravascular coagulation (DIC).^{7,8} Our patient met the WHO criteria for DHF and showed abnormalities compatible with bone marrow suppression, and DIC, although major hemorrhagic manifestations were not observed. The probable immunological mechanism was suggested by the wide spectrum of laboratorial abnormalities: a low level of C3 complement, positive antinuclear antibodies, positive cryoglobulins and elevated ADA in serositis. Prolonged symptoms from dengue infections, such as we observed, are not common and could lead to diagnostic difficulties. Plasma leakage is the hallmark of DHF and occurs late during the acute infection at or near defervescence and is coincident with the clearance of virus,⁹ It could be demonstrated by hypoalbuminemia and cavity effusions. We were able to detect specific antibody production against dengue virus during the phase of DHF, probably also coincident with lowering of virus titers.

The numerous autoimmune features of this patient were a diagnostic challenge, since she was a young woman and could be easily confounded with a rheumatologic patient in a newly open disease. Dengue infections can be a triggering event causing abnormal immune response leading to atypical symptoms or autoimmune diseases, such as systemic lupus erythematosus.¹⁰ Therefore, this infection should be included in differential diagnosis of patients with hematological disorders and autoimmune features in endemic regions or with those who have traveled to them.

Conclusion

Our patient demonstrated anemia, thrombocytopenia, leucopenia and abnormal coagulation studies (prolonged activated partial thromboplastin time and thrombin time and low fibrinogen levels) in combination with features of autoimmune disorders such as elevation of C-reactive protein, low complement levels, positive cryoglobulins, and positive antinuclear antibodies. The description of the case that at first resembled a systemic autoimmune disease, including systemic lupus erythematosus and cryoglobulinemia, was subsequently confirmed as part of dengue hemorrhagic fever manifestations. Due to the high frequency of these features in the clinical practice and the increasing incidence of dengue fever, we think that clinicians should include dengue infection in the differential diagnosis of patients with hematological disorders and autoimmune features. Besides, to our knowledge, this is the first report of such autoimmune features in dengue infection.

Acknowledgements

The authors thank Dr. Carol H. Collins for helpful discussions and suggestions.

Conflict of interest

All the authors declare to have no conflict of interest.

R E F E R E N C E S

1. Guzman MG, Kouri G. Dengue: an update. *Lancet Infect Dis.* 2002;2:33-42.
2. Halstead SB. Dengue. *Lancet.* 2007;370:1644-52.
3. Green S, Rothman A. Immunopathological mechanisms in dengue and dengue hemorrhagic fever. *Curr Opin Infect Dis.* 2006;19:429-36.
4. Vaughn DW, Green S, Kalayanaraj S, et al. Dengue viremia titer, antibody response pattern, and virus serotype correlate with disease severity. *J Infect Dis.* 2000;181:2-9.
5. Lin CF, Lei HY, Shiao AL, et al. Antibodies from dengue patient sera cross-react with endothelial cells and induce damage. *J Med Virol.* 2003;69:82-90.
6. Lin CF, Wan SW, Cheng HJ, et al. Autoimmune pathogenesis in dengue virus infection. *Viral Immunol.* 2006;19:127-32.
7. Srichaikul T, Nimmannitya S. Haematology in dengue and dengue haemorrhagic fever. *Baillieres Best Pract Res Clin Haematol.* 2000;13:261-76.
8. Wills BA, Oragui EE, Stephens AC, et al. Coagulation abnormalities in dengue hemorrhagic fever: serial investigations in 167 Vietnamese children with dengue shock syndrome. *Clin Infect Dis.* 2002;35:277-85.
9. Mathew A, Rothman AL. Understanding the contribution of cellular immunity to dengue disease pathogenesis. *Immunol Rev.* 2008;225:300-13.
10. Harris VK, Danda D, Murali NS, et al. Unusual association of Kikuchis disease and dengue virus infection evolving into systemic lupus erythematosus. *J Indian Med Assoc.* 2000;98:391-3.