

Tricuspid valve repair using the proportion between segments of normal tricuspid annulus as a parameter for annuloplasty

Plastia tricúspide utilizando anuloplastia baseada na proporção entre os segmentos do anel da valva tricúspide normal

Fernando ANTONIALI¹, Domingo Marcolino BRAILE², Glória Maria Braga POTÉRIO³, Gustavo Calado de Aguiar RIBEIRO⁴, Cledicyon Eloy da COSTA¹, Maurício Marson LOPES⁵

RBCCV 44205-920

Abstract

Objective: To determine the proportion between the segments of the normal human tricuspid valve (TV) annulus and its use as a parameter for ring annuloplasty “in vitro” and “in vivo”.

Methods: Digital images of the tricuspid ring of 30 human cadaveric hearts, without fixation and without tricuspid regurgitation (TR), were analyzed and the proportion between the antero-posterior and septal segments was determined. This proportion was used for TV annuloplasty with bovine pericardium (BP) flexible rings on 15 hearts from adult cadavers with TR and ring dilatation. The same proportion and technique were used for TV repair on 11

patients with functional TR. Preoperatively, seven patients had severe and four moderate TR; five patients were class IV and six class III (NYHA).

Results: The mean ratio between the antero-posterior and septal segments was 2.43 ± 0.212 in the 30 hearts without TR. The mean size of the BP flexible ring used for “in vitro” surgical procedure was 71.5 ± 5.2 mm, median 70 mm, and there was no TR after that in all 15 hearts. The mean size of the orthesis used on the patients was 73.4 ± 6.5 mm, median 72 mm. There was 1 hospital death. Six months after surgery, 7 patients had no TR and 3 had mild TR; 6 patients were in NYHA class I, 3 in class II and 1 in class III.

Conclusion: The use of the ratio 2.43:1 between the

1. Specialist Member of Brazilian Society of Cardiovascular Surgery; Staff Heart Surgeon at Clínica Cardio Cirúrgica Campinas****.
2. Ph.D. FAMERP – UNICAMP*; Head of the Postgraduation Programme- FAMERP*; Brazilian Journal of Cardiovascular Surgery – Editor
3. Ph.D. – UNICAMP*; Head of Anesthesiology Department – FCM** UNICAMP*.
4. Membro titular da Sociedade Brasileira de Cirurgia Cardiovascular; Cirurgião cardíaco na equipe da Clínica Cardio Cirúrgica Campinas****.
5. Membro Especialista da Sociedade Brasileira de Cardiologia; Cardiologista na equipe da Clínica Cardio Cirúrgica Campinas****.

This study was carried out at Faculty of Medical Sciences, State University of Campinas – UNICAMP/ Clínica Cardio Cirúrgica Campinas, Campinas, SP, Brazil.

*State University of Campinas

**Faculty of Medical Sciences

*** São José do Rio Preto Medical School

****Clinic of Cardio-Surgery at Campinas

Correspondence Address:

Fernando Antoniali. Rua José Lins do Rego, 665 casa 34 Pq. Taquaral, Campinas - SP CEP: 13087-080 Fone: (19) 3241-3659 / 9790-5667 Fax: (19) 3232-3856.

E-mail address: ferantoni@uol.com.br

Article received in March 3rd, 2007
Article accepted in September 14th, 2007

anterior-posterior and septal segments as a parameter in tricuspid valve annuloplasty with a bovine pericardium flexible ring leads to satisfactory results.

Descriptors: Heart, anatomy & histology. Tricuspid valve. Heart valve diseases. Cardiac surgical procedures.

Resumo

Objetivo: Determinar a proporção existente entre os segmentos do anel da valva tricúspide (VT) normal e aplicá-la na realização da anuloplastia tricúspideia “*in vitro*” e “*in vivo*”.

Métodos: Imagens digitais do anel tricúspideo de 30 corações de cadáveres humanos, sem formolização e sem insuficiência tricúspide (IT), foram analisadas e a proporção entre os segmentos ântero-posterior e septal foi determinada. Esta proporção foi utilizada na anuloplastia da VT com anel maleável de pericárdio bovino (PB), em 15 corações de cadáveres com IT e dilatação do anel valvar. A mesma proporção e técnica foi utilizada na realização de anuloplastia tricúspideia, em 11 pacientes com IT funcional,

entre os quais, sete possuíam IT importante e quatro, moderada; cinco apresentavam insuficiência cardíaca (IC) classe IV (NYHA) e seis, classe III.

Resultados: Nas valvas continentais de cadáveres, a razão média entre o segmento ântero-posterior e septal foi $2,43 \pm 0,212$. O tamanho médio dos anéis maleáveis PB utilizados “*in vitro*” foi $71,5 \pm 5,2$ mm e mediana 70mm. Todas as valvas ficaram continentais após a anuloplastia tricúspideia “*in vitro*”. O tamanho médio do anel maleável PB utilizado “*in vivo*” foi $73,4 \pm 6,5$ mm e mediana 72mm. Ocorreu um (9,1%) óbito. Na avaliação com 6 meses de pós-operatório, sete pacientes não possuíam IT e três possuíam IT leve; seis pacientes apresentavam IC classe I, três, classe II e um, classe III.

Conclusão: O uso da proporção de 2,43:1 entre os segmentos ântero-posterior e septal, como um parâmetro na anuloplastia da VT, utilizando anel maleável de pericárdio bovino, demonstrou resultados iniciais favoráveis.

Descritores: Coração, anatomia & histologia. Valva tricúspide. Doenças das valvas cardíacas. Procedimentos cirúrgicos cardíacos.

INTRODUCTION

Although the recommendations for management of functional tricuspid insufficiency have become more emphatic [1,2], few studies have recently been published regarding this significant matter. King *et al.* [3], more than 20 years ago, demonstrated that the tricuspid insufficiency late repair is related to high rates of morbimortality.

In 2005, Dreyfus *et al.* [4] also reported that the management of the dilated tricuspid annulus regardless tricuspid insufficiency level implies in a better improvement of the patients' New York Heart Association (NYHA) functional class in the late postoperative period.

The main techniques for tricuspid valve disease repair include the bicuspidization advocated by Kay *et al.* [5], the anterior-posterior segment without orthesis showed by De Vega [6], and the annuloplasty using orthesis, the so called prosthetic rings, which can be rigid [7], semi-rigid [8], and flexible [9].

Moreover, there is no agreement regarding the best technique to be used, with the authors advocating since the use of orthesis with three-dimensional shape [10] to other advocating the tricuspid valve bicuspidization as an inexpensive and effective procedure [11].

McCarthy *et al.* [12] studying approximately 800 patients undergoing tricuspid valve annuloplasty demonstrated that the use of ortheses to shape the tricuspid annulus involves a lower rate of residual regurgitation and greater durability. However, even in this large study, the authors did not explain which the best way to measure tricuspid valve would

be in order to choose the orthesis size to be used in the repair.

Two studies regarding tricuspid valve anatomy have recently been published reporting the proportions between normal tricuspid ring segments [13,14]. Both studies suggest using these measurements as parameters for tricuspid valve annuloplasty.

This study aims at evaluating the tricuspid annuloplasty outcomes both *in vitro* and *in vivo* using as measure parameter the proportion found between anteroposterior and septal segments of the normal tricuspid annulus.

METHODS

This study was divided into three stages:

- 1) Determination of the proportions between the anterior posterior and septal segments of the normal tricuspid ring;
- 2) Usage of this proportion in tricuspid valve annuloplasties with *in vitro* procedures;
- 3) Usage of this proportion in annuloplasties in patients with functional tricuspid insufficiency.

Method to determinate the proportion between the anterior posterior and septal segments of the normal tricuspid annulus

This determination has occurred through a descriptive study with 30 hearts of adult cadavers without fixation and which met the inclusion criteria:

Maximum six hour-period postmortem;

No congenital or acquired lesions;
Tricuspid valve without leaflet, chordae tendinae, and papillary muscle deformities;
Continent tricuspid valves.

Tricuspid valve insufficiency was confirmed by the infusion of pressurized water in the right ventricle with the pulmonary valve closed. Digital images of the tricuspid valve with intact tricuspid ring were made. Image computerized analysis were made using UTHSCSA Image Toll for Windows, version 1.28.

Antero-septal and postero-septal commissures were marked with waterproof ink according to Silver *et al.* standardization [15]. Anteroposterior and septal segments were measured using these markings and computer software. Each computerized measure was performed five times and after ruling out the highest and the lowest values, the mean size of each segment for each heart was calculated. The mean values were used to calculate the ratio between the segments.

This methodology is more detailed in a newly published study by the same group of researchers [14].

Method for performance and assessment of procedure of the in vitro tricuspid annuloplasty

This study stage was carried out with 15 hearts of adult cadavers without fixation which have met the same previous inclusion criteria, but the patients had tricuspid valve insufficiency with dilated annulus.

Antero-septal and postero-septal commissure markings also followed the standardization according to Silver *et al.* [15]. The septal segment measurement was manually performed using a metric ruler with subdivisions of 1 mm. Annuloplasty prostheses were manufactured using the previously calculated proportion between anteroposterior and septal segments.

These prostheses were manufactured with bovine pericardium flexible rings manufactured by Braile Biomédica with a 90 mm-standardized extension. The prosthesis section was carried out in the adequate size for each insufficient valve once this value was determined multiplying the septal segment size by 2.43. The prostheses were fixed in the anteroposterior segment of the dilated tricuspid annulus reducing it proportionally to the septal segment. The fixation was performed with polyester sutures and separated U-shaped sutures.

Once the annuloplasty was performed, a new assessment of the tricuspid valve insufficiency was carried out following the same standardized method employed in the first stage of the study.

Ethical aspects of the study with cadaver organs

The first two stages of the study were carried out at the Division of Postmortem Inspection (Serviço de Verificação

de Óbito – SVO) and authorized by the Ethics Committee and the General Technical Services (SETEC – Serviços Técnicos Gerais) of the Municipal City Hall of Campinas

Reconstructive surgical method for tricuspid annuloplasty in patients with functional tricuspid insufficiency

Casuistic

From May 2005 to June 2006, 11 patients with functional tricuspid insufficiency, classified as moderate-to-severe by the postoperative echocardiogram, underwent tricuspid annuloplasty using glutaraldehyde preserved bovine pericardium (BP) flexible rings. These patients had other surgical heart diseases, but did not undergo previous tricuspid valve interventions.

Patients' preoperative characteristics are shown in Table 1.

Table 1. Patients' preoperative characteristics

Preoperative Characteristics	N (%)
Female	9 (81.8)
Mean age (years)	52.7 ±10.9 [45-82]
NYHA Functional	
Class III	6 (54.5)
Class IV	5 (45.5)
Tricuspid Insufficiency	
Moderate	4 (36.4)
Important	7 (63.6)
Atrial fibrillation	8 (72.7)
Pulmonary hypertension	9 (81.8)
Reoperation	5 (45.5)

NYHA: New York Heart Association

Surgical technique

All surgical procedures were carried out by the Clinic of Cardio-Surgery staff at Campinas following the same pattern: cardiopulmonary bypass (CPB) with centrifugal pump, membrane oxygenator, bicaval cannulation, and antegrade and retrograde intermittent blood cardioplegia. After cardiopulmonary bypass support was established, the right atrium was opened and the tricuspid valve analyzed being ruled out those cases with valve leaflet degenerative changes. At first, all the other necessary procedures were performed, such as coronary artery bypass grafting, MAZE procedure, and mitral and aortic valve repair. Tricuspid annuloplasty is the last procedure to be performed. Table 2 shows the other procedures concomitant to the tricuspid annuloplasty.

Table 2. Procedures concomitant to tricuspid valve annuloplasty

Concomitant procedures	N (%)
Mitral valve repair	3 (27.3)
Mitral valve replacement	8 (72.7)
Aortic valve replacement	2 (18.2)
Myocardial revascularization	2 (18.2)
MAZE procedure	5 (45.5)
Others	1 (9.1)

NYHA: New York Heart Association

In order to perform the tricuspid annuloplasty, antero-septal and postero-septal commissures were localized following the Silver *et al.* standardization [15] and the septal segment was measured with a surgical suture fragment and a metric ruler with subdivisions of 1 mm. This was performed similarly to the in vitro procedure stage; the flexible ring was sectioned in the appropriate size, using the studied proportion and the septal segment size. The prosthesis was fixed with polyester sutures and separated U-shaped sutures, thus, proportionally reducing it to the septal segment size. The tricuspid valve test was performed with a saline solution infusion in the right ventricle through the right atrioventricular orifice itself keeping the pulmonary trunk compressed and using a 60 mL-syringe connected to a flexible PVC tube (1/4").

Postoperative assessment

Patients' follow-up was performed along with the cardiologists and after six months postoperatively. All of them underwent a transthoracic echocardiography and clinical assessment as for the New York Heart Association (NYHA) functional class.

Ethics Committee and Informed Consent

The institutional review boards of the participating hospital approved the study design and the clinical staff performance, and written informed consent was obtained from all the patients.

Statistical analysis

For statistical analysis, tricuspid insufficiency was graded in crosses as follows: mild = 1+; moderate = 2+; and important = 3+. Fractioned mean values were admitted to compare pre- and postoperative period for both tricuspid insufficiency and NYHA functional class.

Continuous variables are presented as mean \pm standard deviation (SD) and median, as appropriate. Categorical variables descriptive analysis was calculated as absolute (n) and relative (%) frequencies. Student *t* test was performed to evaluate pre- and postoperative period comparisons. The α error was set at 5%.

RESULTS

Proportions between anteroposterior and septal segments of normal tricuspid annulus

Septal and anteroposterior segment mean values were 30.6 ± 3.7 (median 31.3) and 74 ± 9.4 mm (median 72.1), respectively. The mean ratio between anteroposterior and septal segments was 2.43 ± 0.212 (median 2.44).

In humans, the proportion between anteroposterior and septal segments of normal tricuspid ring was considered to be 2.43:1.

In vitro annuloplasty outcomes

The bovine pericardium (BP) flexible ring mean size used in vitro was 71.5 ± 5.2 mm (median 70). The mean number of U-shape sutures used to fix the prosthesis was 10.13 ± 1.05 (median 10).

All the valves were continent after in vitro tricuspid annuloplasty was performed.

Outcomes related to surgical management of functional tricuspid insufficiency

Technical data

The bovine pericardium (BP) flexible ring mean size used in the 11 patients undergoing tricuspid annuloplasty was 73.4 ± 6.5 mm (median 72). The mean number of U-shape sutures used to fix the prosthesis was 10.9 ± 1.11 (median 11).

Mortality and Morbidity

There was one death (9.1%) at postoperative day 1 related to systemic inflammatory response syndrome (SIRS) and liver failure. This patient was in NYHA functional class IV, had hepatitis C, pulmonary hypertension, atrial fibrillation, and 2 previous heart surgeries for mitral valve repair and biological prosthesis replacement.

There has been another episode of SIRS developing simultaneously with acute renal and respiratory insufficiency, which were reverted afterwards. Two episodes of cardiogenic shock were reverted using intra-aortic balloon (IAB). There have been 2 episodes of profound surgical site infections, which were resolved. There were no episodes requiring the use of pacemaker.

Post-operative follow-up

At 3 months postoperatively, during clinical examination of the patients who were in NYHA functional class IV preoperatively, one patient was in NYHA functional class III, 2 were in NYHA functional class II and one in NYHA functional class I. Among the patients in NYHA functional class III postoperatively, only one evolved to NYHA functional class II and the remaining to NYHA functional class I (Figure 1). There was a statistical difference between

the patients' functional class preoperatively (2.4 ± 0.52) and postoperatively (1.5 ± 0.71), $p < 0.001$. There were no other deaths, except for one in-hospital death.

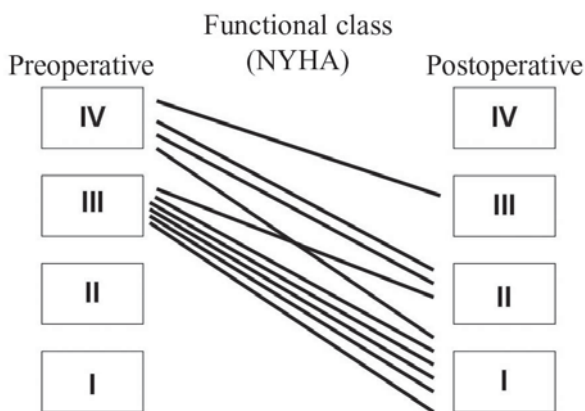


Fig. 1 – Improvement of NYHA functional class after surgery - NYHA: New York Heart Association

Echocardiographic assessment

Postoperative echocardiographic assessment prior to patients' discharge showed 8 patients without tricuspid insufficiency and 2 with mild tricuspid insufficiency. On the evaluation undertaken within 6 months postoperatively, only one patient presented a mild tricuspid insufficiency and the other seven patients were uneventfully (Figure 2). There was a statistical difference between pre- and postoperative tricuspid insufficiency (2.6 ± 0.52 vs 0.3 ± 0.48 ; $p < 0.001$).

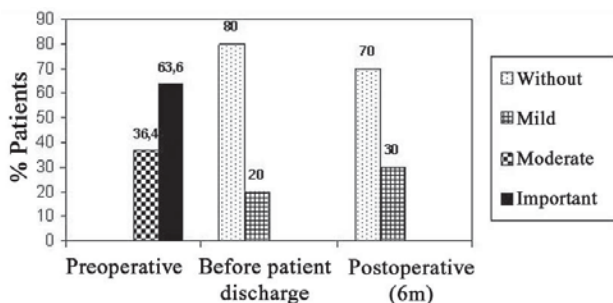


Fig. 2 – Tricuspid insufficiency echocardiographic assessments

DISCUSSION

Functional tricuspid insufficiency is the most frequent cause of tricuspid insufficiency [16,17] due to the dilatation of the tricuspid valve annulus, and it is often related to heart valve diseases involving the mitral valve and/or the aortic valve. The correction of left-sided valve diseases without concomitant repair of tricuspid insufficiency through surgical approach of the tricuspid valve has shown

to be responsible for the highest late morbimortality. This occurs on account of progressive right ventricular dysfunction and high levels of reoperation [3].

Another important aspect is that the functional tricuspid insufficiency echocardiographic diagnosis is not always correctly performed in preoperative examinations and the correction of this heart valve disease implies in the progression of tricuspid valve insufficiency and the worsening of the patients' functional capacity [18]. Deyfus et al. [4] showed that annuloplasty of the tricuspid valve based on tricuspid ring dilation improves functional NYHA class in the late postoperative period irrespective of the grade of tricuspid insufficiency. In this study, the authors considered as an indication to annuloplasty if the tricuspid annular diameter was equal or greater than 70 mm – measured obtained linearly between the antero-septal and postero-septal commissures – and compared two groups: one group underwent only mitral valve repair (MVR) and the other one received MVR plus tricuspid annuloplasty. After a mean 5-year follow-up there was a statistical difference between both groups regarding the degree of both tricuspid insufficiency and NYHA functional class.

In this sense, the management of functional tricuspid insufficiency imposes itself as a mandatory procedure when there is an indication to surgical repair [19]. In these cases the tricuspid valve replacement is an exceptional procedure and cardiovascular surgeons should pay more attention to the valve repair techniques. Although the bicuspidization technique is still accepted [5,11], there is a trend in the literature to confirm the antero-posterior segment reduction with or without prostheses as the technique presenting the best outcome. The proportion of the tricuspid annulus size reduction should be based on anatomic studies of normal valves, but both the classic study by Silver et al. [15] and the Brazilian study by Jatene et al. [20], were carried out with the hearts immersion in formalinfixation which changes the correct relationship between the tricuspid annulus segments [21]. Unfortunately, there are only a few scientific studies regarding the tricuspid valve without the formalinfixation effects that could provide information on which would be the proportions of the accurate antero-posterior segment reduction.

Two studies have been recently published in this journal. They have studied hearts without formalinfixation immersion [13, 14]. Searching for a more closely stage to the physiologic status, the study measures developed by our group were carried out in hearts with RV distention and continent tricuspid valve [14]. The proportion found between both anteroposterior and septal segments in hearts with normal tricuspid valve was 2.43:1.

The concern with the practical use of these measures and proportions between the segments of tricuspid valve annulus has been the major motivation of this line of

research in our group. In this way, the first stage of the present study was carried out as a part of the data found in a previous study [14], which defined the proportion to be used in the tricuspid annuloplasty as 2.43:1.

In the second stage of the study, the annuloplasty was performed in 15 hearts of human cadavers which presented tricuspid valve insufficiency with annulus dilation. As all the valves became continent, by reducing the antero-posterior segment using the ratio of 2.43:1 in relation to the septal segment, one can state that the main cause of insufficiency in these valves was the dilation of the tricuspid annulus. In this way, an annuloplasty technique feasible for functional tricuspid insufficiency was reproduced in an *in vitro* procedure.

The choice of bovine pericardium flexible ring as the prosthesis to be used is related to its practicality and previous use in mitral valve repair in Brazil [22]. The previous manufacture of a 90 mm-diameter ring has allowed to multiply the value obtained by 2.43 and to cut the ring in a suitable size to be used. This was carried out once the septal segment was measured.

It is worth emphasizing, at this point, two precautions taken to perform the annuloplasty in all patients. The first one is related to the accurate location of antero-septal and postero-septal commissures in order to take the correct measure of the septal segment. Silver et al. [15] showed the most found characteristics in these commissures, and in the present study these recommendations were strictly followed. Second, care must be taken regarding the U-shape sutures. In order to reduce the tricuspid valve annulus, the sutures must be more extensive and close to the native tissue and narrower and more far away in the prosthesis used.

The third stage of the present study was carried out using a ratio of 2.43:1 between antero-posterior and septal segments in the tricuspid valve annuloplasty performed in 11 patients. All the patients had functional tricuspid insufficiency associated to other surgical heart diseases, being in NYHA functional class III or IV and reoperations were held responsible for 45% of the cases. This high surgical risk casuistry is similar to that in other studies about tricuspid annuloplasty. All studies have demonstrated increased rates of morbimortality [3,10-12,19,23,24].

Despite the small number of patients in our study, there has been a significant reduction of both tricuspid insufficiency and NYHA functional class. Undoubtedly, the NYHA functional class improvement is not related to tricuspid insufficiency management alone, but rather to the complete surgical management. It must be observed that in all procedures there has been concomitant mitral valve surgery, which is closely related to the NYHA functional class improvement. The small follow-up period and the small

number of patients did not allow further conclusion in this study. Nevertheless, it was decided to present these data as initial outcomes. Further studies will be needed to evaluate the durability of this technique and the factors which can influence the late outcomes.

Although other larger studies have demonstrated good outcomes regarding tricuspid valve annuloplasty – without using prostheses – such as in the technique of De Vega and its variations [6,25] – or with rigid and flexible prostheses [7,9] – all of them have reported to have specific meters for each technique and only a few reported which is the proportion of the annulus reduction. The proportion studied and used in the present study can also be useful to other techniques aiming at reducing the antero-posterior segment of the tricuspid valve annulus. Undoubtedly, there is no more space to evaluate tricuspid valve annuloplasty with digital pulps or with mitral valve meters.

CONCLUSION

In conclusion, the use of a proportion of 2.43:1 between antero-posterior and septal segments as a parameter for tricuspid valve annuloplasty using bovine pericardium flexible rings have shown early favorable outcomes.

REFERENCES

1. Revuelta, JM. The forgotten functional tricuspid insufficiency: is valve repair necessary? In My Opinion. CTSNet 2003 Jun [acesso em 16 de junho de 2003]; Disponível em: URL: <http://www.ctsnet.org/sections/innovation/valvetechnology/articles/article-9.html>.
2. Frater R. Tricuspid insufficiency. J Thorac Cardiovasc Surg. 2001;122(3):427-9.
3. King RM, Schaff HV, Danielson GK, Gersh BJ, Orzulak TA, Piehler JM, et al. Surgery for tricuspid regurgitation late after mitral valve replacement. Circulation. 1984;70(3 Pt 2):I193-7.
4. Dreyfus GD, Corbi PJ, Chan KM, Bahrami T. Secondary tricuspid regurgitation or dilatation: which should be the criteria for surgical repair? Ann Thorac Surg. 2005;79(1):127-32.
5. Kay JH, Maselli-Campagna G, Tsuji KK. Surgical treatment of tricuspid insufficiency. Ann Surg. 1965;162(1):53-8.
6. De Vega NG. La anuloplastia selectiva, regulable y permanente. Rev Esp Cardiol. 1972;6:555-7.
7. Carpentier A, Deloche A, Dauptain J, Soyfer R, Blondeau P, Piwnica A, et al. A new reconstructive operation for correction of mitral and tricuspid insufficiency. J Thorac Cardiovasc Surg. 1971;61(1):1-13.

8. Duran CG, Ubago JL. Clinical and hemodynamic performance of a totally flexible prosthetic ring for atrioventricular valve reconstruction. *Ann Thorac Surg.* 1976;22(5):458-63.
9. McCarthy JF, Cosgrove DM 3rd. Tricuspid valve repair with the Cosgrove-Edwards Annuloplasty System. *Ann Thorac Surg.* 1997;64(1):267-8.
10. Filsoofi F, Salzberg SP, Coutu M, Adams DH. A three-dimensional ring annuloplasty for the treatment of tricuspid regurgitation. *Ann Thorac Surg.* 2006;81(6):2273-7.
11. Ghanta RK, Chen R, Narayanasamy N, McGurk S, Lipsitz S, Chen FY, et al. Suture bicuspidization of the tricuspid valve versus ring annuloplasty for repair of functional tricuspid regurgitation: midterm results of 237 consecutive patients. *J Thorac Cardiovasc Surg.* 2007;133(1):117-26.
12. McCarthy PM, Bhudia SK, Rajeswaran J, Hoercher KJ, Lytle BW, Cosgrove DM, et al. Tricuspid valve repair: durability and risk factors for failure. *J Thorac Cardiovasc Surg.* 2004;127(3):674-85.
13. Andrade NMM, Tinois E, Vieira RW, Braile DM, Petrucci Jr O, Oliveira PPM, et al. Coeficientes de proporcionalidade nas valvas atrioventriculares: estudo anatômico dos segmentos valvares em indivíduos normais. *Rev Bras Cir Cardiovasc.* 2005;20(3):255-60.
14. Antoniali F, Braile DM, Poterio GMB, Costa CE, Lopes MM, Ribeiro GCA, et al. Proporção entre os segmentos do anel da valva tricúspide normal: um parâmetro para realização da anuloplastia valvar. *Rev Bras Cir Cardiovasc.* 2006; 21(3):262-71.
15. Silver MD, Lam JH, Ranganathan N, Wigle ED. Morphology of the human tricuspid valve. *Circulation.* 1971;43(3):333-48.
16. Waller BF, Howard J, Fess S. Pathology of tricuspid valve stenosis and pure tricuspid regurgitation: Part III. *Clin Cardiol.* 1995;18(4):225-30.
17. Tei C, Pilgrim JP, Shah PM, Ormiston JA, Wong M. The tricuspid valve annulus: study of size and motion in normal subjects and in patients with tricuspid regurgitation. *Circulation.* 1982;66(3):665-71.
18. Groves PH, Lewis NP, Ikram S, Maire R, Hall RJ. Reduced exercise capacity in patients with tricuspid regurgitation after successful mitral valve replacement for rheumatic mitral valve disease. *Br Heart J.* 1991;66(4):295-301.
19. Fukuda S, Song JM, Gillinov AM, McCarthy PM, Daimon M, Kongsarepong V, et al. Tricuspid valve tethering predicts residual tricuspid regurgitation after tricuspid annuloplasty. *Circulation.* 2005; 111(8):975-9.
20. Jatene FB, Koike MK, Monteiro R, Veronezi SC, Magalhães MHG, Jatene AD. Avaliação anatômica da valva tricúspide. *Rev Bras Cir Cardiovasc.* 1992;7(1):22-7.
21. Eckner FA, Brown BW, Overll E, Glagov S. Alteration of the gross dimensions of the heart and its structures by formalin fixation. A quantitative study. *Virchows Arch A Pathol Pathol Anat.* 1969;346(4):318-29.
22. Braile DM, Ardito RV, Pinto GH, Santos JLV, Zaiantchick M, Souza DRS, et al. Plástica mitral. *Rev Bras Cir Cardiovasc.* 1990;2(2):86-98.
23. Kuwaki K, Morishita K, Tsukamoto M, Abe T. Tricuspid valve surgery for functional tricuspid valve regurgitation associated with left-sided valvular disease. *Eur J Cardiothorac Surg.* 2001;20(3):577-82.
24. Matsunaga A, Duran CM. Progression of tricuspid regurgitation after repaired functional ischemic mitral regurgitation. *Circulation.* 2005;112(9 Suppl):I453-7.
25. Yiwu L, Yingchun C, Jianqun Z, Bin Y, Ping B. Exact quantitative selective annuloplasty of the tricuspid valve. *J Thorac Cardiovasc Surg.* 2001;122(3):611-4.