

# C5 AND C6 HUMAN DERMATOMES

## A clinical, electromyographical, imaging and surgical findings

Antonio Tadeu de Souza Faleiros<sup>1</sup>, Luiz Antonio de Lima Resende<sup>1</sup>,  
Marco Antonio Zanini<sup>1</sup>, Heloisa Amélia de Lima Castro<sup>2</sup>, Roberto Colichio Gabarra<sup>1</sup>

**Abstract** – There is substantial controversy in literature about human dermatomes. In this work, C5 and C6 superior limb dermatomes were studied. The method consisted of comparing clinical signs and symptoms with conduction studies, electromyographical data, neurosurgical findings, and imaging findings obtained by computerized tomography (CT) or magnetic resonance imaging (MRI), for each patient. Data analysis from superior members in 18 patients suggests that C5 is located in the lateral aspect of the shoulder and arm, and C6 in the lateral aspect of the forearm and 1<sup>st</sup>, 2<sup>nd</sup>, and 3<sup>rd</sup> fingers. To our knowledge this is the first time that C5 and C6 human dermatomes have been studied by all the following methods together: clinical, electromyographical, CT and MR imaging, and surgical findings.

KEY WORDS: eletromyography, human dermatome, imaging, superior member.

### Dermátomos humanos C5 e C6: estudo clínico, eletromiográfico, de imagem e cirúrgico

**Resumo** – Há controvérsias na literatura sobre os dermatômos humanos. Neste estudo os dermatômos do membro superior C5 e C6 foram analisados. O método consistiu em comparar os sinais e sintomas com achados eletromiográficos, de imagem e achados cirúrgicos. Análise dos dados do membro superior de 18 pacientes sugere que o dermatômo C5 esteja localizado na região lateral do ombro e braço, e o dermatômo C6 na região lateral do antebraço e 1º, 2º e 3º dedos da mão. Este é o primeiro estudo em que os dermatômos C5 e C6 foram avaliados pelos dados clínicos, eletromiográficos, de imagem e achados cirúrgicos.

PALAVRAS-CHAVE: dermatômo humano, eletromiografia, imagem, membro superior.

The C5 and C6 human anatomical territories are frequently found to be compromised in neurology clinic, mainly after traumas, but several controversies exist about C5 and C6 human dermatomes. For Bing<sup>1</sup>, Platzer<sup>2</sup> Duss<sup>3</sup>, and Carpenter<sup>4</sup> C5 is represented in a small restricted area of the lateral aspect of the proximal arm, but for Testut<sup>5</sup> Déjérine<sup>6</sup>, Brain<sup>7</sup>, Bickerstaff<sup>8</sup>, Patten<sup>9</sup>, Spalteholz<sup>10</sup>, Adams<sup>11</sup>, and Noback<sup>12</sup>, it is represented in a more extensive area, the whole lateral aspect of the arm; for Barraquer, an extensive area of the lateral aspect of the arm and forearm, including the thumb<sup>13</sup>; for Elliot<sup>14</sup> and Gardner<sup>15</sup> it is similar but the thumb is not included; for Yokochi<sup>16</sup>, Brodal<sup>17</sup>, Keegan-Garret<sup>18</sup>, DeJong<sup>19</sup>, and Curtis<sup>20</sup> it is represented in a more extensive anterior area of arm and forearm, but there is no superposition between the maps of DeJong<sup>19</sup>, Brodal<sup>17</sup>, and Yokochi<sup>16</sup>.

First year students in our medical school are completely confused by this because these two dermatomes are presented differently in all our clinical and anatomical text books. We believe that several of these text book interpretations were not based on the modern techniques that allow comparison of clinical symptoms with electromyographical data, neurosurgery findings, and CT and MRI images.

Our objective is to furnish probable C5 and C6 human dermatome maps obtained by comparing clinical, electromyographical, neurosurgical, and CT and MRI data.

### METHOD

This study includes patients with a clinical diagnosis of cervical radiculopathy seen between 1992 and 2005 at our university hospital. After approval from the Ethics Committee on Hu-

<sup>1</sup>Department of Neurology, Psychology and Psychiatry, Botucatu Medical School, São Paulo State University (UNESP), Botucatu SP, Brazil; <sup>2</sup>Department of Morphology, Piracicaba Dental School, UNICAMP, Campinas SP, Brazil.

Received 18 August 2008, received in final form 12 November 2008. Accepted 2 February 2009.

Dr. Marco Antonio Zanini – Departamento de Neurologia e Psiquiatria / Faculdade de Medicina de Botucatu / UNESP / Rubião Jr S/N - Caixa Postal: 540 - 18618-970 Botucatu SP - Brasil. E-mail: mzanini@fmb.unesp.br

man Research, patients with clinical diagnosis of C5 and/or C6 cervical radiculopathy were included in accordance to the following criteria:

I - Conduction studies and electromyographical diagnosis of C5 and/or C6 radiculopathy were in accordance with electromyography text-books<sup>21,22</sup> and included: A) normal latencies, amplitudes, and conduction velocities of the ulnar, median, and radial nerves in the symptomatic arm coexisting with neurogenic electromyographical findings in the deltoideus and supraspinatus muscle for C5 diagnosis, or in the biceps brachialis and coracobrachialis muscle for C6 diagnosis. B) Neurogenic findings were: spontaneous activity, with positive sharp waves or fibrillations and/or muscle at rest fasciculation; increased duration and amplitude neurogenic motor unit potentials with mild effort; reduced recruitment and incomplete interference pattern at maximum muscle contraction. C) Clinical romboideus muscular weakness was an additional criterion for C5 diagnosis.

II - Surgical findings: Several patients with unsuccessful clinical treatment required surgery for cervical root decompression. These surgical anatomical data were analyzed.

III - Imaging diagnosis of C5 and/or C6 radiculopathy: All patients had imaging diagnosis of compressive radiculopathy by CT or MRI.

## RESULTS

A total of 18 patients were analyzed.

**Group 1** - Ten patients with associated C5 and C6 cervical root compression (6 with successful clinical treatment - without surgery; 4 with unsuccessful clinical treatment, submitted to surgery). The combined C5 and C6 clinical symptoms territory for these 10 patients was on the lateral aspect of shoulder, arm, forearm, and I, II, and III fingers (Fig 1).

**Group 2** - Six patients with isolated C5 compression (3 with successful clinical treatment, 3 with unsuccessful clinical treatment, submitted to surgery). The C5 clinical symptoms territory for these 6 patients was on the lateral aspect of shoulder and arm (Fig 2).

**Group 3** - Two with isolated C6 compression (1 submitted to clinical treatment, 1 with unsuccessful clinical treatment, submitted to surgery). The C6 clinical symptoms territory for these 2 patients was on the lateral aspect of the forearm and I, II, and III fingers (Fig 3).

## DISCUSSION

There are several theory problems for dermatome definitions in humans. The pioneer study on dermatomes was by Sherrington<sup>23</sup> and, more recently, by Kirk and Denny-Brown<sup>24</sup>, both with monkeys. However, it is difficult to rely on animal dermatome data when dealing with man.

For classical anatomic authors like Testut and Latarjet<sup>5</sup>, the main limitation was defining dermatomes from post-mortem studies. In classical neurologic semiology, at the

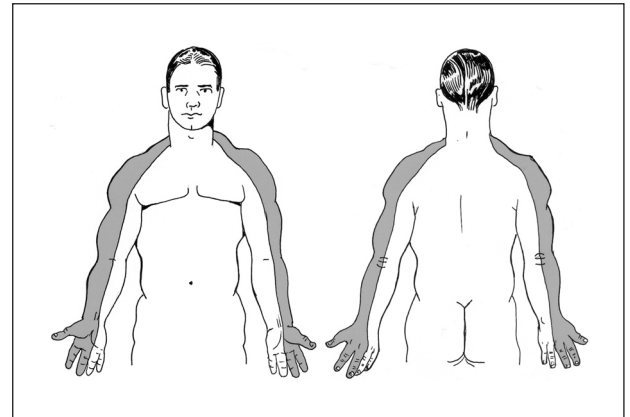


Fig 1. Topography of the symptoms of patients with combined C5 and C6 cervical root compression.

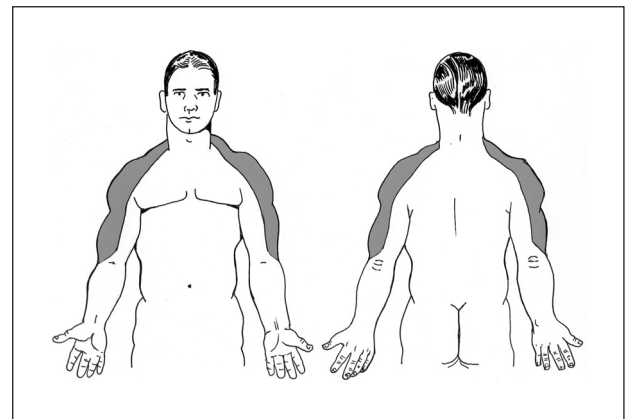


Fig 2. Topography of the symptoms of patients with isolated C5 cervical root compression.

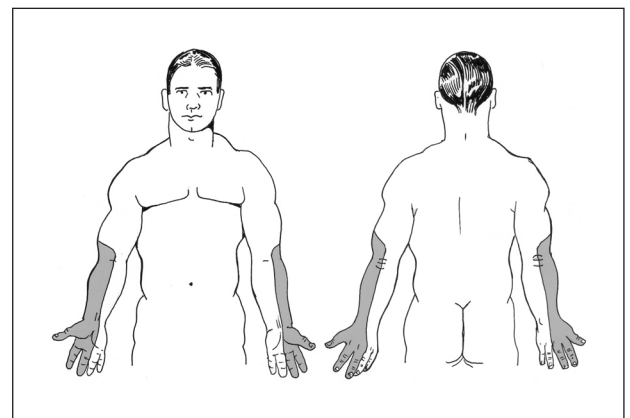


Fig 3. Topography of the symptoms of patients with isolated C6 cervical root compression.

time of Déjérine<sup>6</sup>, the main limitation was the lack of conduction studies, electromyography, and imaging.

The first human dermatomes were postulated by clinical data from patients with *Herpes zoster*<sup>25</sup>, but in most patients herpetic infection is not restricted, involving more cranial or distal spinal segments<sup>26,27</sup> making defini-

tion of a specific dermatome impossible. There are published *Herpes zoster* cases showing impairment of 2 or 3 adjacent dermatomes in 7 distinct regions of the human body<sup>28</sup>. New paravertebral anesthetic block techniques have recently been developed but defining an isolated dermatome was still not possible because the anesthetic drugs were diffused in the cerebrospinal fluid<sup>29-32</sup>.

Our study is simple: comparison of clinical symptoms, electromyography, imaging, and surgical findings enabling us to deduce the probable location for human C5 and C6 dermatomes. We concluded that the C5 human dermatome is probably on lateral aspect of the shoulder and arm; and the C6 human dermatome is probably on the lateral aspect of the forearm, and I, II, and III fingers.

## REFERENCES

1. Bing R. Tratado de las enfermedades nerviosas. 3<sup>rd</sup> ed. Barcelona: Modesto Usón, 1955:274.
2. Platzer W. Perkopf anatomy. Atlas of topographic and applied human anatomy. 3<sup>rd</sup> ed. Munich: Urban and Schwarzenberg, 1989:123-318.
3. Duus, P. Diagnóstico topográfico em neurologia. 4<sup>th</sup> ed. Rio de Janeiro: Cultura Médica, 1989:24.
4. Carpenter, MB. Neuroanatomia humana. 7<sup>th</sup> ed. Rio de Janeiro: Interamericana, 1978:157-161.
5. Testut L, Latarjet A. Tratado de anatomia humana. Barcelona: Salvat, 1902:225.
6. Déjérine J. Sémiologie des affections du système nerveux. Paris: Masson, 1914.
7. Brain, R. Enfermedades del sistema nervioso. 5<sup>th</sup> ed. Buenos Aires: El Ateneo, 1958:27-28.
8. Bickerstaff ER. Exame neurológico na prática médica. Rio de Janeiro: Livraria Atheneu, 1975:182-183.
9. Patten J. Diagnóstico diferencial em neurologia. São Paulo: Livraria Roca, 1985:204-217.
10. Spalteholz N. Atlas de anatomia humana. 3<sup>rd</sup> ed. São Paulo: Roca, 1988:371.
11. Adams RD, Victor M, Ropper AH. Principles of neurology. 6<sup>th</sup> ed. New York: McGraw - Hill, 1997:149-153.
12. Noback CR, Strominger NL, Demarest RJ. Neuroanatomia: estrutura e função do sistema nervoso humano. São Paulo: Editorial Premier, 1999:106.
13. Barraquer Bordas L. Neurología fundamental. 3<sup>rd</sup> ed. Barcelona: Toray, 1976:40.
14. Elliot FA. Clinical neurology. Philadelphia: W.B. Sauder Co, 1964:2.
15. Gardner E, Gray DJ, Rahilly RO. Anatomia. 4<sup>th</sup> ed. Rio de Janeiro: Guanabara Koogan, 1998.
16. Yokochi C, Rohen JW. Anatomia humana: atlas fotográfico de anatomia sistêmica e regional. 3<sup>rd</sup> ed. São Paulo: Editora Malone Ltda, 1993:378.
17. Brodal, A. Anatomia neurológica com correlações clínicas. 3<sup>a</sup> ed. São Paulo: Livraria Roca, 1984:57-58.
18. Keegan JJ, Garrett FD. The segmental distribution of the cutaneous nerves in the limbs of man. Anat Rec 1948;102:409-437.
19. DeJong RN. The Neurological examination. 4<sup>th</sup> ed. Hagerstown: Harper and Row Publishers, 1979:60.
20. Curtis, BA. Neurosciences: The Basics. 4<sup>th</sup> ed. Philadelphia: Lea and Febiger, 1990:32-33.
21. Kimura J. Electrodiagnosis in diseases of nerve and muscle: principles and practice. Philadelphia: F.A. Davis, 1983.
22. Dumitru D. Electrodiagnostic medicine. Philadelphia: Hanley and Belfus-Mosby, 1995.
23. Sherrington CS. Experiments in examination of the peripheral distribution of the fibers of the posterior roots of some spinal nerves. Philos Trans R Soc Lond B 1893;184:641-764.
24. Kirk EJ, Denny-Brown D. Functional variation in dermatomes in the macaque monkey following dorsal root lesions. J Comp Neurol 1970;139:307-320.
25. Head H, Campbell AW. The pathology of herpes zoster and its bearing on sensory localisation. Brain 1900;23:353.
26. Sachs GM. Segmental zoster paresis: an electrophysiological study. Muscle & Nerve 1996;19:784-786.
27. Haanpaa M, Hakkinen V, Nurmikko T. Motor involvement in acute herpes zoster. Muscle Nerve 1997;20:1433-1438.
28. Vu AQ, Radonich MA, Heald PW. Herpes zoster in seven disparate dermatomes (zoster multiplex): report of a case and review of the literature. J Am Acad Dermatol 1999;40:868-869.
29. Hopf HB, Weissbach B, Peters J. High thoracic segmental epidural anesthesia diminishes sympathetic outflow to the legs, despite restriction of sensory blockade to the upper thorax. Anesthesiology 1990;73:882-889.
30. Saito T, Gallagher ET, Cutler S, et al. Extended unilateral anesthesia: new technique of paravertebral anesthesia? Reg Anesth 1996;21:304-307.
31. Saito T, Den S, Cheema SPS, et al. A single-injection, multi-segmentary paravertebral block: extension of somatosensory and sympathetic block in volunteers. Acta Anaesthesiol Scand 2001;45:30-33.
32. Richardson J, Lonnqvist PA. Thoracic paravertebral block. Br J Anaesth 1998;81:230-238.