

Brazilian Journal of Medical and Biological Research (2009) 42: 582-587
ISSN 0100-879X Short Communication

EEG spike source localization before and after surgery for temporal lobe epilepsy: a BOLD EEG-fMRI and independent component analysis study

M.S. Sercheli¹, E. Bilevicius², A. Alessio², H. Ozelo¹, F.R.S. Pereira², J.M. Rondina², F. Cendes² and R.J.M. Covolan¹

¹Instituto de Física “Gleb Wataghin”, ²Faculdade de Ciências Médicas, Universidade Estadual de Campinas, Campinas, SP, Brasil

Correspondence to: M.S. Sercheli, DRCC, IFGW, UNICAMP, Caixa Postal 6165, 13083-970 Campinas, SP, Brasil
Fax: +55-19-3521-5512. E-mail: mauricio.sercheli@gmail.com

Simultaneous measurements of EEG-functional magnetic resonance imaging (fMRI) combine the high temporal resolution of EEG with the distinctive spatial resolution of fMRI. The purpose of this EEG-fMRI study was to search for hemodynamic responses (blood oxygen level-dependent - BOLD responses) associated with interictal activity in a case of right mesial temporal lobe epilepsy before and after a successful selective amygdalohippocampectomy. Therefore, the study found the epileptogenic source by this noninvasive imaging technique and compared the results after removing the atrophied hippocampus. Additionally, the present study investigated the effectiveness of two different ways of localizing epileptiform spike sources, i.e., BOLD contrast and independent component analysis dipole model, by comparing their respective outcomes to the resected epileptogenic region. Our findings suggested a right hippocampus induction of the large interictal activity in the left hemisphere. Although almost a quarter of the dipoles were found near the right hippocampus region, dipole modeling resulted in a widespread distribution, making EEG analysis too weak to precisely determine by itself the source localization even by a sophisticated method of analysis such as independent component analysis. On the other hand, the combined EEG-fMRI technique made it possible to highlight the epileptogenic foci quite efficiently.

Key words: Interictal epileptiform spike; Epilepsy surgery; EEG-fMRI; Temporal lobe epilepsy; ICA; Dipole model

Research supported by FAPESP (#2004/15805-5 and #2005/56578-4).

Received November 2, 2008. Accepted April 7, 2009

Introduction

Mesial temporal lobe epilepsy (MTLE) is the most common type of epilepsy in adults and surgical treatment is an option in refractory cases (1). Simultaneous EEG-functional magnetic resonance imaging (fMRI) measurement is a multimodal noninvasive technique (2-4) that tries to combine the high temporal resolution of EEG with the distinctive spatial resolution of fMRI. This technique has been applied in the context of epilepsy studies to help

preoperative evaluation by localizing the activity of the epileptiform source (5). Previous studies (6,7) have looked for spatial agreement between fMRI statistical maps and dipoles but have found large average distances between their respective localization (23 mm in the case of Ref. 7).

We have studied a patient with MTLE who underwent EEG-fMRI investigation before and after a successful selective amygdalohippocampectomy (SAH), by comparing the source localization findings obtained via blood oxygen level-dependent (BOLD) contrast (8,9) and dipole model-

ing by independent component analysis (ICA) (10, 11) with the resected hippocampal region. Although ICA has been already applied to short epochs centered in the maximum amplitudes of epileptic activities (12), this approach combined with EEG-fMRI analysis in a pre- and postoperative MTLE patient is novel and was the objective of the present study.

Material and Methods

We report here a 39-year-old left-handed woman with bilateral epileptogenic zones previously investigated and detected by ictal and interictal single-photon emission computed tomography (SPECT), video EEG and neuropsychological evaluation. The patient experienced her first seizure at 8 years of age characterized by an ascending epigastric discomfort followed by verbal and manual automatisms and, rarely, by tonic clonic seizures. Although she has tried phenobarbital, valproate, oxcarbazepine, topiramate, carbamazepine, and clobazam up to maximum tolerated doses in mono- and polytherapy, she has never experienced total control of seizures. The patient had an average of 6 to 7 complex partial seizures per month preoperatively. During the preoperative investigation she was submitted to several routine EEGs, 11 of them showing unilateral mesial temporal lobe epileptiform discharges (5 on the right, 6 on the left). Her neuropsychological evaluation indicated dominance of the left hemisphere for language as well as dysfunction of verbal memory. She was submitted to two video EEGs and two ictal SPECTs within a 5-year interval. Her first video EEG and ictal SPECT were not conclusive, whereas the second video EEG showed eight seizures starting on the right mesial temporal lobe and the ictal SPECT indicated hyperperfusion of the same region. She finally underwent right SAH and presently is on 1200 mg/day carbamazepine and 40 mg/day clobazam, having been seizure free since the surgical procedure (Engel IA scale).

Simultaneous EEG-fMRI measurements of this patient were performed before and after the successful right SAH. This study was approved by the Ethics Committee of our institution, and written informed consent was obtained from the participant for both exams. The EEG-fMRI sessions were carried out using a 2T Elscint Prestige MR scanner (Elscint, Israel) with echo-planar images acquired in an interleaved mode (TR = 2000 ms, TE = 45 ms, 20 slices, in-plane resolution = 3 x 3 mm with width = 6 mm) in 6-min runs (ten runs before and six runs after surgery), using a cap with 32 MRI-compatible scalp electrodes and a BrainAmp 32 MR amplifier (Brain Products, Germany). The EEGs were submitted to off-line MRI artifact removal

and filtering with the Vision Analyzer software (Brain Products). Epileptiform spikes were identified and marked by an experienced neurophysiologist. By using the EEG timing of the interictal epileptiform discharges (IEDs), the echo-planar images were analyzed with the SPM2 software package (<http://www.fil.ion.ucl.ac.uk/spm/>) in order to search for corresponding BOLD responses. A gamma function was used as a hemodynamic response function model. All images were submitted to the same preprocessing steps (slice-time correction, motion correction, coregistration, and normalization using the patient brain 3-D MRI volume: 1 x 1 x 1 mm³, and spatial smoothing: Gaussian kernel of 6 mm of full-width at half maximum). Statistical analysis was performed using the *t*-test with a *t*-value threshold of 3.1 (uncorrected *P* = 0.001). Additionally, a cluster size of ten contiguous voxels was also applied as a threshold to enhance the results.

The EEG dipole modeling analysis to ICA components was performed using the EEGLAB toolbox v6.01b with the DIPFIT2 plug-in (<http://www.sccn.ucsd.edu/eeglab/>). We performed equivalent dipole source localization of independent components within a three-shell boundary element model of the Montreal Neurological Institute (MNI) standard brain. EEG data were segmented in one-second epochs centered on every detected spike (segmented between -500 and 500 ms in relation to spike onset). This means that the maximum amplitude of the spike is in the center of its respective epoch. These epochs were selected from the same MRI corrected data mentioned above. In each dipole study, the epochs of each spike were concatenated for all 30 EEG scalp channels in order to compute the same number of independent components. Before computing the dipoles, scalp maps were used to exclude spurious components such as eye movement artifacts.

Results

Before the right SAH, EEG-fMRI examination showed 63 IEDs originating in the left, in the right or in both hemispheres, corresponding to an average of 1 spike/min. There were greater numbers of left-hemisphere spikes with 37 single discharges (sharp waves followed by low waves) and three episodes of temporal intermittent rhythmic delta activity. There were 3 and 28 right- and bilateral-hemisphere spikes, respectively. After surgery, a considerable decrease in the epileptiform activity was observed. The EEG-fMRI data presented only 10 IEDs, corresponding to an average of 1 spike/3.6 min. Furthermore, the spike distribution was almost symmetrical, with 6 on the left hemisphere and 4 on the right. All pre- and postoperative

spikes had their maximum amplitudes in electrodes T7, TP9, F7, T8 TP10, and F8 in the 10-20 system of electrode placement.

Since a given scalp EEG activity can be generated by single or multiple sources located in either hemisphere or in both, we searched for the BOLD responses by taking all IEDs at once, irrespective of their location in the scalp. Using all IEDs as a condition to search for positive BOLD responses implies a more stringent statistical condition to retrieve the activation areas corresponding to all discharges simultaneously. Therefore, the activation maps were established with all the pre-surgical EEG events, i.e., 63 IEDs, which showed both left and right temporofrontal positive BOLD responses with larger activated area on the left. Even though the patient presented pronounced atrophy of the right hippocampus, the bilateral BOLD responses

were in agreement with the preoperative investigation that showed bi-temporal interictal spikes with no-sided predominance. Deactivation responses were not statistically significant.

Figure 1 shows BOLD activation responses before SAH by taking into account all 63 epileptiform events. These results were particularly interesting for comparison with the outcomes of the postoperative condition, which showed epileptiform activities in the left and in the right hemispheres separately. The dipoles obtained by analyzing the EEG via ICA are also shown in the same figure. In this last case, the MNI standard brain was used for dipole co-registration instead of the patient's brain.

We also analyzed the data with a different approach by using only bilateral IEDs to generate the BOLD activation maps (Figure 2). BOLD responses were noted in both

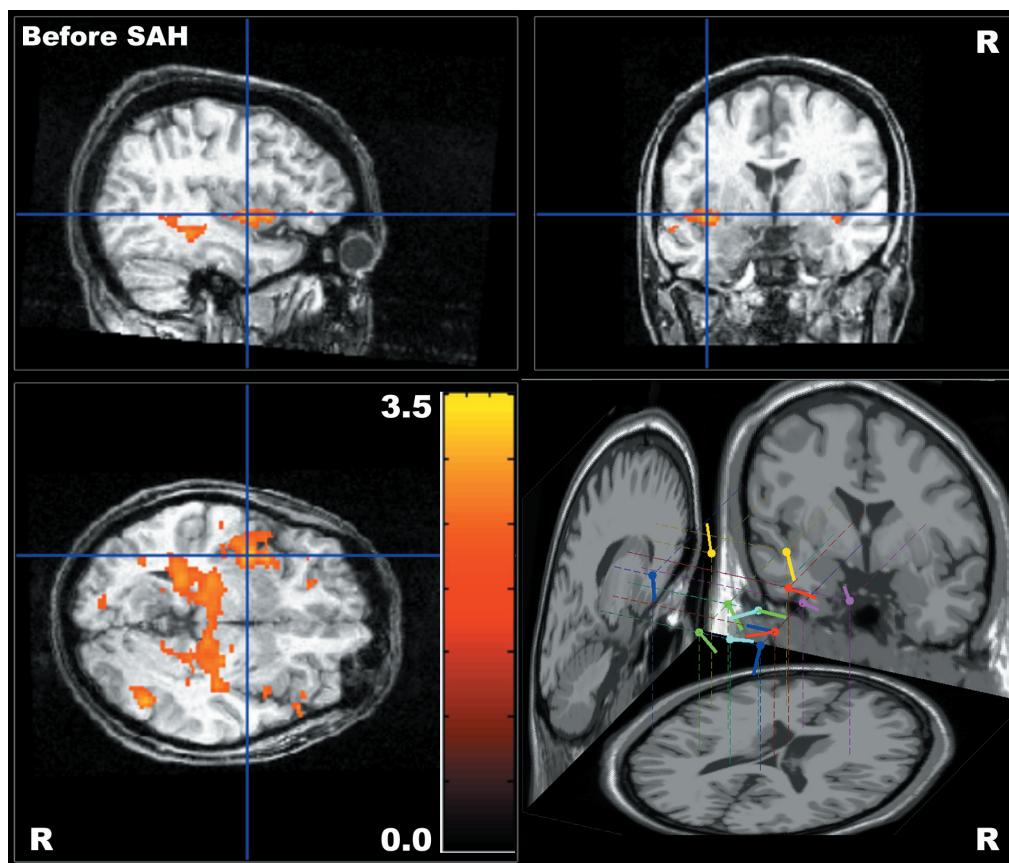


Figure 1. Blood oxygen level-dependent (BOLD) contrast activation responses associated with all interictal epileptiform discharges recorded before selective amygdalohippocampectomy (SAH) and coregistered to the patient's brain structural magnetic resonance imaging. The color bar indicates T-values for positive BOLD responses. In the right lower view of this figure, dipoles to independent component analysis (ICA) are shown in the Montreal Neurological Institute standard brain, with left-sided predominance. Each dipole color indicates an individual ICA component.

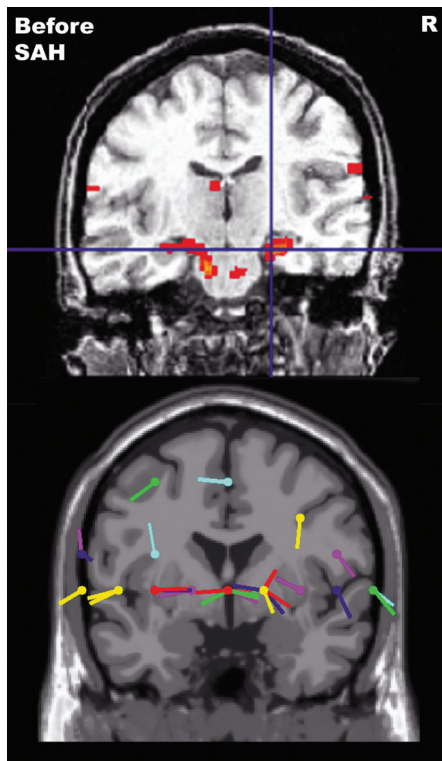


Figure 2. Coronal view of blood oxygen level-dependent (BOLD) activation responses (upper part) and dipole distribution (lower part). BOLD responses are localized in both hippocampi with a right-sided predominance when using only bilateral interictal epileptiform discharges (IEDs) to create the activation map. The same bilateral IEDs give rise to a spread distribution of dipoles to independent component analysis (inferior view), with six dipoles (~22%) located near the right hippocampus region. Each dipole color indicates an individual independent component analysis. SAH = selective amygdalohippocampectomy.

hippocampi with a right-sided predominance. In fact, in this case the right hippocampus was completely filled with a positive BOLD activated area. This figure also shows a widespread distribution of dipoles, consistent with this kind of bilateral activity and with the outcomes of a previous study (11), although six dipoles (~22%) were found near the right hippocampus region.

After right SAH, positive BOLD responses were restricted to the left temporofrontal region, as can be seen in Figure 3, even using both left and right spikes. In this analysis, all registered IEDs were also taken into account in order to allow comparison with the preoperative findings shown in Figure 1. Figure 3 also shows the respective dipoles within the MNI standard brain.

Regarding the results as a whole, it should be noted that areas of both temporal and extratemporal activations associated with temporal lobe spikes have also been reported elsewhere (13).

Discussion

Scalp EEG is the most traditional way of evaluating patients with epilepsy, in spite of its limited power to precisely determine epileptogenic foci. EEG-fMRI, on the

other hand, is a technique that, since its inception, holds promise to significantly improve the epilepsy diagnosis and source localization.

In the case reported here, we detected preoperative bilateral positive BOLD responses with left-sided predominance associated with all IEDs registered during examination (Figure 1). This result is consistent with the predominance of left IEDs and presented 1320 activated voxels in a volume of 10.56 cm³. A more restrictive analysis taking into account only bilateral IEDs showed BOLD activation localized in both hippocampal regions, with a larger BOLD spot in the right hippocampus (Figure 2), in agreement with atrophy of the right hippocampus. These findings are suggestive of right hippocampus induction of the numerous interictal activities registered in the left hemisphere. After right SAH, the patient still presented spikes registered on both hemispheres, although much less frequently. The fMRI analysis taking these EEG events as an input led to a mild BOLD activation only on the left side and presented 65 activated voxels in a volume of 0.52 cm³ (Figure 3). Certainly, resection of the right hippocampus contributed to decreasing the epileptiform activity in the left hemisphere. Taken together, these results strongly suggest that most of the left activity was generated by the right hippocampus

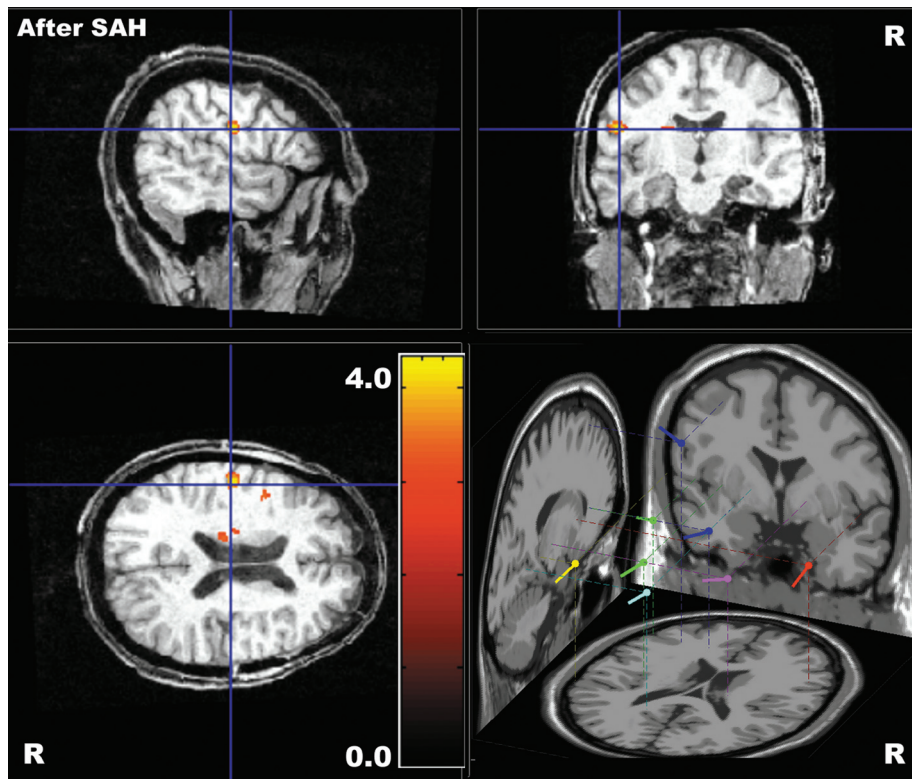


Figure 3. Blood oxygen level-dependent (BOLD) contrast activation responses associated with all interictal epileptiform discharges recorded after selective amygdalohippocampectomy (SAH) and coregistered to the patient's brain structural magnetic resonance imaging. The color bar indicates T-values for positive BOLD responses. In the right lower view of this figure, dipoles to independent component analysis (ICA) are shown in the Montreal Neurological Institute standard brain, with left-sided predominance. Each dipole color indicates an individual ICA.

(14). Throughout the study, dipoles to ICA components presented some agreement with the source localization by BOLD contrast. However, dipole modeling resulted in a widespread distribution, making EEG analysis too weak to precisely determine by itself the source localization even by a sophisticated method of analysis such as ICA.

The results obtained by the combined EEG-fMRI technique applied to a case of right MTLE revealed good agreement with the preoperative evaluation of the patient. They also revealed a less significant contra-lateral spike source after surgery (Engel IA scale), with the epileptiform activity reduced by a factor of four. Particularly interesting was obtaining a BOLD response that completely filled the right hippocampus region, in agreement with the observa-

tion of right hippocampus atrophy. Thus, the combined EEG-fMRI technique made it possible to localize quite efficiently the epileptogenic foci in a noninvasive way, just by taking the timings of EEG activities as inputs in the search for BOLD activation. Regarding the large left/right ratio observed for the EEG spikes before surgery, this finding may indicate right-hippocampus induction. The dramatic decrease of the IED rate after SAH is an additional indication of such a hypothesis. Therefore, we can infer that simultaneous EEG-fMRI measurements may provide crucial information for clinical EEG investigation, and can be in the near future a good candidate to enhance the clinical investigative techniques employed in epilepsy assessment.

References

1. Engel J Jr. Introduction to temporal lobe epilepsy. *Epilepsy Res* 1996; 26: 141-150.
2. Ives JR, Warach S, Schmitt F, Edelman RR, Schomer DL. Monitoring the patient's EEG during echo planar MRI. *Electroencephalogr Clin Neurophysiol* 1993; 87: 417-420.
3. Allen PJ, Josephs O, Turner R. A method for removing imaging artifact from continuous EEG recorded during functional MRI. *Neuroimage* 2000; 12: 230-239.
4. Ritter P, Villringer A. Simultaneous EEG-fMRI. *Neurosci Biobehav Rev* 2006; 30: 823-838.
5. Zijlmans M, Huiskamp G, Hersevoort M, Seppenwoolde JH, van Huffelen AC, Leijten FS. EEG-fMRI in the preoperative work-up for epilepsy surgery. *Brain* 2007; 130: 2343-2353.
6. Lemieux L, Krakow K, Fish DR. Comparison of spike-triggered

- gered functional MRI BOLD activation and EEG dipole model localization. *Neuroimage* 2001; 14: 1097-1104.
7. Bagshaw AP, Kobayashi E, Dubeau F, Pike GB, Gotman J. Correspondence between EEG-fMRI and EEG dipole localisation of interictal discharges in focal epilepsy. *Neuroimage* 2006; 30: 417-425.
 8. Belliveau JW, Rosen BR, Kantor HL, Rzedzian RR, Kennedy DN, McKinstry RC, et al. Functional cerebral imaging by susceptibility-contrast NMR. *Magn Reson Med* 1990; 14: 538-546.
 9. Ogawa S, Lee TM, Kay AR, Tank DW. Brain magnetic resonance imaging with contrast dependent on blood oxygenation. *Proc Natl Acad Sci U S A* 1990; 87: 9868-9872.
 10. Delorme A, Makeig S. EEGLAB: an open source toolbox for analysis of single-trial EEG dynamics including independent component analysis. *J Neurosci Methods* 2004; 134: 9-21.
 11. Plummer C, Harvey AS, Cook M. EEG source localization in focal epilepsy: where are we now? *Epilepsia* 2008; 49: 201-218.
 12. Leal AJ, Dias AI, Vieira JP. Analysis of the EEG dynamics of epileptic activity in gelastic seizures using decomposition in independent components. *Clin Neurophysiol* 2006; 117: 1595-1601.
 13. Kobayashi E, Bagshaw AP, Benar CG, Aghakhani Y, Andermann F, Dubeau F, et al. Temporal and extratemporal BOLD responses to temporal lobe interictal spikes. *Epilepsia* 2006; 47: 343-354.
 14. Mintzer S, Cendes F, Soss J, Andermann F, Engel J Jr, Dubeau F, et al. Unilateral hippocampal sclerosis with contralateral temporal scalp ictal onset. *Epilepsia* 2004; 45: 792-802.