

# Enteral antioxidants in ischemia/reperfusion injuries in rats

## *Antioxidantes enterais em lesões de isquemia e reperfusão em ratos*

HUGO FONTAN KÖHLER<sup>1</sup>; IARA MARIA SILVA DELUCCA<sup>2</sup>; LOURENÇO SBRAGIA NETO<sup>3</sup>

### A B S T R A C T

**Objective:** To evaluate the role of pre-treatment with dietary antioxidants in an experimental model of intestinal injury of ischemia-reperfusion (I/R) in rats. **Methods:** Ninety adult male Wistar rats were used. An intestinal segment was isolated based on its vascular pedicle. A control biopsy was performed and the pedicle was sectioned and sutured again, ensuring a time of 60 minutes of ischemia followed by reperfusion. Sequential biopsies were performed at the end of the ischemic period and every 15 minutes during reperfusion. The treatment consisted of saline, vitamin C, vitamin E or a combination of the latter two. Quantitative and qualitative assessments of the biopsies were performed. **Results:** The groups treated with vitamin E alone or vitamin E combined with vitamin C showed a statistically significant attenuation of ischemia-reperfusion, with reduced loss of height of the villi and lower neutrophilic infiltration at the end of the study when compared to the control and vitamin C-exclusive groups. **Conclusion:** In this experimental model of ischemia-reperfusion, pre-treatment with vitamin E attenuated the I/R injury in the small intestine of Rats, demonstrated by reduced loss of height of the villi and the attenuation of neutrophil infiltration.

**Key words:** Ischemia. Reperfusion. Reperfusion injury. Microsurgery. Antioxidants.

### INTRODUCTION

The restoration of blood flow to an ischemic tissue can lead to greater harm than that originally caused by ischemia. This event is called ischemia and reperfusion (I/R) injury. The small intestine is particularly susceptible to injury from I/R<sup>1</sup> and its occurrence is associated with high morbidity and mortality<sup>2</sup>. Although the mechanisms involved are not fully elucidated, it is believed that oxidative stress mediators, such as reactive oxygen species (ROS), polymorphonuclear neutrophils (PMN) and nitric oxide (NO) play an important role<sup>3</sup>. Due to the involvement of ROS in I/R injury, various antioxidants have been tested, among them vitamin C (ascorbic acid) and vitamin E. Ascorbic acid is a water-soluble antioxidant with chelating and reducing properties and it is used to prevent I/R injury<sup>4</sup>. Vitamin E (α-tocopherol) is a non-enzymatic, lipid soluble antioxidant that acts against oxidative stress by stabilizing membrane unsaturated fatty acids. Thus, tissues treated with vitamin E have an increased capacity to reduce ROS and be protected against membrane lipid peroxidation<sup>5</sup>. Vitamins C and E can act synergistically because ascorbic acid is unable to reduce the peroxy radical, but it can regenerate α-

tocopherol from the tocoferoxil radical, recycling the α-tocopherol<sup>6</sup>.

I/R can occur in a variety of clinical situations, one being the microsurgical transfer of jejunal segments. The jejunal flap was first described in 1957, and has been used for reconstruction of the pharynx and esophagus. During the transfer, an isolated segment of jejunum is removed from the abdomen and transferred to the neck<sup>7</sup>. In the clinical setting, I/R injury can be seen ten minutes after reperfusion, with gradual recovery until the 28th day<sup>8</sup>.

The objective of this study is to evaluate the impact of pre-treatment with vitamins C and E in an experimental model of jejunal flap using morphometric criteria to assess I/R injury.

### METHODS

#### Model of jejunal ischemia-reperfusion

Was used 90 adult male Wistar rats between 224 and 261 grams of weight (average of 237.5g and standard deviation (SD) of 12.3g) in the experiment. After anesthesia with intraperitoneal ketamine and xylazine, the animals were placed in the supine position on a warm table and

Work conducted at the Department of Histology and Embryology of the Institute of Biology, Universidade Estadual de Campinas – UNICAMP, São Paulo – SP, Brazil.

1. Assistant Physician, Department of Otolaryngology and Head and Neck Surgery, Faculty of Medical Sciences, Universidade Estadual de Campinas-SP-BR; 2. Assistant Professor, Department of Histology and Embryology, Institute of Biology, Universidade Estadual de Campinas-SP-BR; 3. PhD, Assistant Professor, Department of Surgery, Faculty of Medicine, Universidade de Sao Paulo - Ribeirão Preto-SP-BR.

underwent laparotomy. Body temperature was monitored with a rectal probe to avoid hypothermia. The superior mesenteric artery and vein were dissected and isolated from their sources in sufficient length to allow placement of vascular clamps and performance of sutures. The study area was then selected according to the arterial supply to the intestine. The first choice for biopsy was the sixth loop from the ileocecal valve, the subsequent seventh loop being an alternative. One fragment with a total thickness of the intestinal wall was removed and sent for biopsy control (BC). In order to avoid variations in height of villi throughout the intestine, a 3cm jejunal segment was dissected based on its vascular pedicle and isolated by sectioning of any collateral circulation to it. All the biopsy fragments were obtained from this segment. In order to simulate a microsurgical flap, a microvascular clamp was placed in the mesenteric vessels that, soon after, were sectioned. A microvascular anastomosis was then performed between the stumps by using magnification Zeiss microscope and 10-0 nylon suture. After one hour of ischemia, during which vascular anastomosis was performed, a second fragment (ischemic biopsy - BI) was extracted and the clamps removed, restoring blood flow. After removing the clamps, there were four successive tissue removals: at 15 minutes of reperfusion (RB15); at 30 minutes of reperfusion (RB30); at 45 minutes of reperfusion (RB45); and at 60 minutes of reperfusion (RB60). Each sample had a length of approximately 0.4 cm and included the entire circumference of the jejunal segment. To simulate the conditions of a microvascular transfer, the segment chosen for the study was kept outside the abdominal cavity, at room temperature (24°C). All animals were euthanized after the procedure.

This experiment was approved by the Ethics Committee on Animal Research of the Institute of Biology, Universidade Estadual de Campinas.

### Treatment groups

The animals were randomly divided into the following groups, each with fifteen animals: Group T underwent laparotomy with preparation of the flap without ischemia and reperfusion; Control Group underwent laparotomy, preparation of the flap, ischemia and reperfusion, with collection of samples in predetermined intervals, but received no treatment; Group C was submitted to the same surgical procedure of the Control Group, associated with the intake of ascorbic acid, 250mg/kg, via enteral feeding for four days before the operation; Group E underwent the same surgical procedure of the Control Group, but received vitamin E at a dose of 60mg/kg in the four days preceding the operation; Group C + E underwent the same surgical procedure of the control group and received both drugs, the same dose and Groups C and E (250mg/kg of vitamin C and 60mg/kg vitamin E) for four days; Validation Group C – Same as Group C, except that during preparation of the drug, the active principle (ascorbic acid) was removed; Validation Group E – Same as Group

E, with the active principle (a-tocopherol) removed during preparation of the drug.

The purpose of Group T is to validate the model and show that intestinal injury is not due to surgical manipulation, but due to ischemia-reperfusion. Validation Groups C and E are intended to demonstrate that the effect of vitamins C and E was due to their active principles and not to other components of the formula, which were kept in the drugs administered to these animals as well as the diluents.

### Parameters of injury

Both qualitative and quantitative analyses were used in the assessment of I/R injury. The height of the villi and neutrophilic infiltration were evaluated in histological sections of intestinal biopsies. All samples were evaluated by the same histologist who was blinded to which group or time of biopsy the animal belonged. The sections were stained with routine histological techniques using hematoxylin and eosin. The classification proposed by Chiu *et al.*<sup>9</sup> was used for qualitative assessment. The height of villi was determined in ten random fields using an optical system that allowed the measurement of height of the villus in micrometers (mm). The neutrophil infiltration was assessed by counting cells in 20 random fields.

### Statistical analysis

Data are presented as mean and standard deviation (SD). Spearman and Pearson tests were used to evaluate the correlation between variables. A comparison of multiple means was performed using analysis of variance (ANOVA). If variances were equal, the Tukey test was used, while the Dunnett test was applied to different variances. A p value <0.05 was considered statistically significant. The distribution of continuous variables was compared with the normal one.

## RESULTS

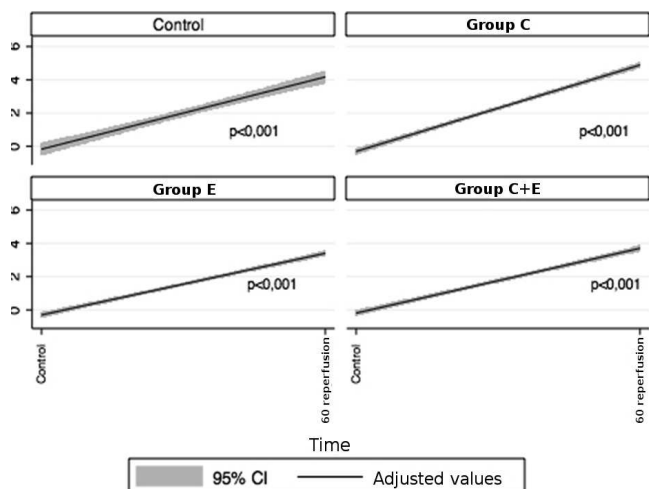
### Qualitative analysis

A progressive increase of I/R injury was observed in all groups, with a significant migration from degree zero to five over time, a statistically significant correlation between time and Chiu score being demonstrated (Figure 1).

### Height of villi

The height of the villi showed a progressive decrease over the study period (Figure 2). A statistically significant correlation was found between the biopsy intervals and height of villi in all groups. The correlation coefficient and p values are shown in table 1.

Comparisons of height of the villi were performed within each group at different intervals and also between different groups within the same time interval. Initially, the



**Figure 1** - Correlation between time of reperfusion (horizontal axis) and Chiu score (vertical axis).

Control Group was compared with those of validation. There was no statistically significant difference between them at any interval (Table 2). In the Control Group, the height of villi decreased from 363.55 +/- 35.89 in BC to 129.16 +/- 27.17 in RB60, and this decrease was statistically significant (p < 0.001). The first statistically significant difference was observed in comparison with RB15, which showed height of 296.87 +/- 46.13, p = 0.004 (Figure 2).

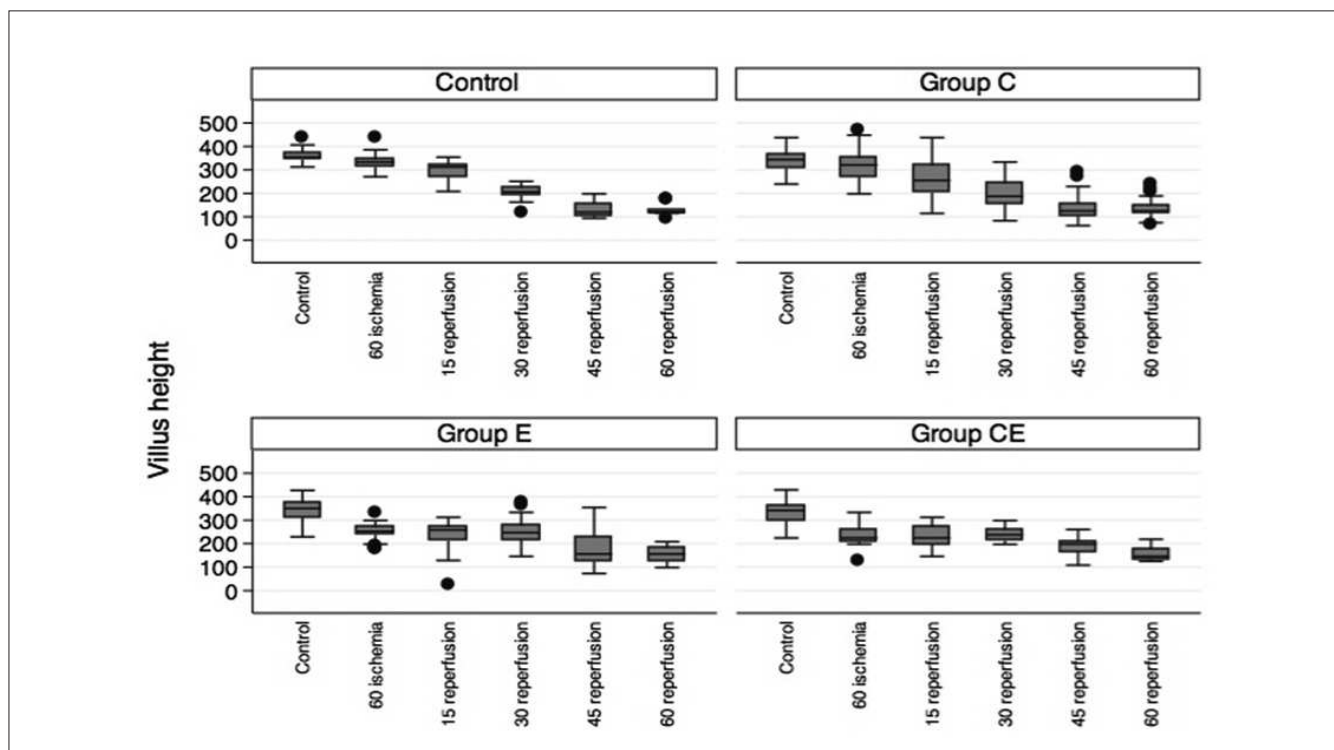
For Group C, a similar pattern was observed, with the height of villi ranging from 336.61 +/- 44.63 in BC and 134.05 +/- 36.22 in RB60 (p < 0.001), the RB15 being the first biopsy presenting a significant difference, p < 0.001 (Figure 2).

The animals treated with vitamin E had average vilar height of 343.93 +/- 46.79 in CB and 154.12 +/- 31.88 in RB60 (p < 0.001), but unlike the other, the first significant difference was with BI, p < 0.001 (Figure 2).

Animals treated with vitamins C + E repeated the pattern observed in Group E. The average height of villi

**Table 1** - Correlation between the time of biopsy and the height of villi and the number of infiltrating neutrophils in the study groups.

Group	Height of villi		Infiltrating Neutrophils	
	Spearman rho	Significance	Spearman rho	Significance
Control	0.894	p<0.001	0.831	p<0.001
Vitamin C	0.807	p<0.001	0.786	p<0.001
Vitamin E	0.730	p<0.001	0.701	p<0.001
Vitamins C+E	0.728	p<0.001	0.686	p<0.001



**Figure 2** - Average height of villi in the different treatment groups and time intervals.

**Table 2 -** Analysis of variance comparing the height of villi between the Control Group and the Validation Groups C and E in different time intervals.

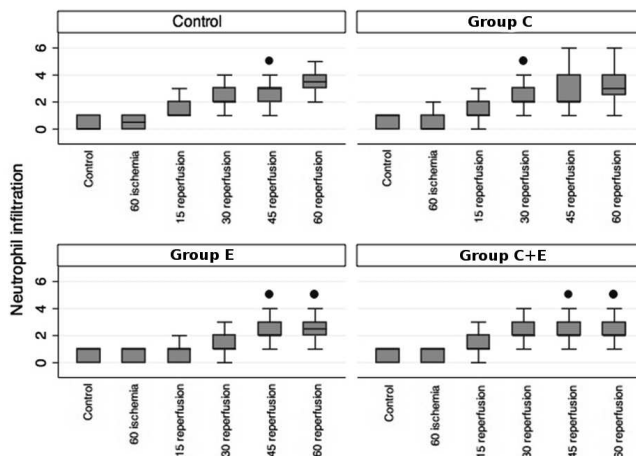
Time	Villi				Neutrophils			
	Control	Valid C	Valid E	p	Control	Valid C	Valid E	p
CB	363.5	346.6	341.9	0.236	0.4	0.5	0.5	0.989
BI	338.5	335.7	330.8	0.990	0.5	0.5	0.5	1.000
RB15	296.9	278.2	290.2	0.997	1.4	1.0	1.2	0.867
RB30	199.6	176.2	179.4	0.642	2.2	2.5	1.8	0.923
RB45	129.6	128.3	144.5	0.674	2.6	3.0	2.5	0.638
RB60	129.1	126.7	130.4	0.988	3.5	4.0	3.8	0.912

ranged from 332.37 +/- 48.96 in CB to 156.23 +/- 29.63 in RB60 (p <0.001) and the first statistically significant difference occurred in BI, p <0.001 (Figure 2).

In the control biopsy, there was no statistically significant difference between groups, with average height of the villi ranging from 363.55 +/- 35.89 in the Control Group and 332.37 +/- 42.00 in Group E+C (p = 0.235, Figure 2). In BI, significant differences could be observed in groups E (249.00 +/- 35.34, p <0.001) and C + E (240.07 +/- 44.26) when compared to the Control Group (338.53 +/- 45.08), p <0.001. In RB15, the only significant difference occurred between the control group (296.87 +/- 46.13) and Group C + E (230.99 +/- 46.38), p = 0.029. In RB30, the animals in Groups C + E and E showed statistically significant difference when compared to the Control Group (p <0.001), and this difference remained significant in RB45 (p = 0.020) for Group C + E and for Group E (p = 0.037), and in RB60 for Group E (p = 0.032) and for Group C + E (p = 0.025). These data are displayed in figure 2.

**Neutrophilic infiltration**

The number of infiltrating neutrophils showed a progressive increase during the reperfusion period, with no statistically significant difference between the Control



**Figure 3 -** Comparison of the number of infiltrating neutrophils in the different treatment groups and time intervals.

and Validation Groups (Table 2). The number of infiltrating neutrophils in the mucosa and submucosa was compared for different time intervals and treatment. We found a statistically significant correlation between the times of the samples and neutrophilic infiltration. The correlation coefficient and p values for each group are shown in table 1.

**Table 3 -** Comparison of the number of infiltrating neutrophils among the different groups in different time intervals during reperfusion.

		Control		Group C		Group E	
15 minutes	Group C	0.25	(1.000)				
	Group E	-0.6	(0.114)	-0.625	(0.001)		
	Group CE	-0.1	(0.984)	-0.125	(0.904)	0.5	(0.033)
30 minutes	Group C	0.2	(0.941)				
	Group E	-0.6	(0.320)	-0.8	(0.002)		
	Group CE	0.033	(1.000)	-0.167	(0.899)	0.63	(0.042)
60 minutes	Group C	0	(1.000)				
	Group E	-0.85	(0.270)	-0.85	(0.023)		
	Group CE	-0.93	(0.220)	-0.93	(0.020)	-0.83	(0.994)

\* p values are in parentheses.

In all groups there was a progressive increase in the number of infiltrating neutrophils. In groups Control and E this increase was statistically significant when compared to the control biopsy from RB30, while in Groups C and C + E, this difference occurred from RB15 on (Figure 2).

In BI and BC there was no statistically significant difference between groups. There was a significant difference between Groups C and C + E when compared to Groups E and Control in RB15 and RB30 (Table 3). In RB45, there was no significant difference between groups ( $p = 0.2087$ ). In RB60, a significant difference was observed between Groups C, E and C + E (Table 3).

## DISCUSSION

Vitamin C has been extensively studied in I/R injury due to its antioxidant capacity. A study using an experimental model in rabbits with vitamin C, mannitol and N-acetylcysteine has been shown that the superior mesenteric artery flow was improved by the three drugs, but only vitamin C and mannitol had direct protective action on gut mucosa at the histopathological exam of the small intestine, with significant reduction of ischemia and reperfusion injury<sup>10</sup>. These results were confirmed by another article that showed morphological improvement of the lesion after administration of ascorbic acid<sup>11</sup>. Another study evaluated the role of non-enzymatic antioxidants using the measurement of levels of malondialdehyde (MDA) and glutathione in the intestinal mucosa, as well as a qualitative histopathologic score. It demonstrated a significant protective effect of vitamin C and mannitol, a decrease of mucosal damage and accumulation of MDA. However, the use of vitamin E showed no difference in these parameters. The authors suggested that vitamin C and mannitol may be useful in the prevention of intestinal I/R injury due to its effectiveness and ease of use<sup>12</sup>. Both articles used vitamin C intravenously and demonstrated an appropriate protective effect. A key difference is how the injury was evaluated, because both used qualitative rather than quantitative measurements. We can also point a significant difference in the doses used in this work and in Byrka-Owczarek's study<sup>10</sup> (250mg/kg) from that used by Günel<sup>12</sup> (10mg/kg). This difference in dosage may explain the contrasting results. Nevertheless, glycine has the same protective profile of action when used in different doses<sup>13</sup>.

Security in the administration of vitamin C has also been questioned by its contradictory role in I/R injury. In a model of liver damage by I/R, ascorbic acid was shown to have anti- and pro-oxidant properties. After cold I/R injury, a decreased ratio of reduced glutathione oxidation and increased levels of lipid peroxidation and mitochondrial swelling can be prevented by exposure to ascorbic acid at a dose of 0.5mM, whereas a dose of 2.0mM increases tissue injury<sup>14</sup>.

In a study of patients undergoing surgical repair of abdominal aortic aneurysm ou infrainguinal grafts, the preoperative administration of sodium ascorbate increased the arteriovenous difference of lipid hydroperoxides (LH), interleukin 6 and vascular endothelial growth factor during ischemia. This was reflected in an increase of LH, vascular endothelial growth factor and creatine phosphokinase during reperfusion. The findings of these authors suggest that sodium ascorbate can promote lipid oxidative damage induced by iron during the ischemic phase of the operation<sup>15</sup>. Perhaps the ascorbic acid may, at therapeutic doses, have a negative effect on ischemia-reperfusion injury by increasing inflammatory activity, being then indicated in smaller quantities. The use of ascorbic acid proved to be ineffective in preventing lipid peroxidation in serum and intestinal mucosa<sup>16</sup>.

The administration of  $\alpha$ -tocopherol prior to ischemia showed both biochemical and histopathological protective effects against I/R injury in rat livers<sup>17</sup>.

The preoperative administration of drugs has also been demonstrated as an effective method for reducing I/R injury. Selenium, taurine and  $\alpha$ -tocopherol were administered for four days before the occlusion and reperfusion of visceral arteries in rats. The animals treated with selenium or a combination of the three drugs showed better mean arterial pressure of the visceral arteries and reperfusion than the control group or other treatments<sup>18</sup>. Oral supplementation of glutamine for a period of 48 hours before I/R injury rendered prevention of intestinal damage and recovery improvement<sup>19</sup>. In a clinical study<sup>20</sup> the preoperative use of vitamin E administered intravenously significantly reduced liver I/R injury, with a good safety profile, and reduction in liver enzyme concentration and time of intensive care unit stay<sup>20</sup>. The natural antioxidant resveratrol, administered preoperatively, also displayed efficacy in the treatment of intestinal I/R injury in an experimental model<sup>21</sup>.

In humans, both vitamins C and E reduce oxidative stress situations. In patients with myocardial infarction there is a significant decrease in the levels of vitamin E after reperfusion, which does not occur in failures of reperfusion. The serum level of vitamin C, however, has shown no difference between these two situations. This provides evidence for the consumption of vitamin E during the reperfusion phase after myocardial infarction, this being a sign of reperfusion<sup>22</sup>.

The number of infiltrating neutrophils in the mucosa increases during the reperfusion period. Polymorphonuclear neutrophils have been implicated in I/R injury and their depletion has been tested in order to improve intestinal damage<sup>3</sup>. Their simple counting using optical microscopy can be an indicator of I/R injury. Both vitamins C and E were shown to decrease lung I/R injury, but not prevent it, because they inhibit the activation of PMN, but not the production of reactive oxygen species from other sources<sup>23</sup>. The association of vitamins C and E showed a

beneficial effect on I/R injury in rat epigastric flaps, increasing significantly the viability of the flap<sup>24</sup>. The role of neutrophil infiltration was also demonstrated by the improvement in I/R injury with ventilation with 100% oxygen<sup>25</sup>. In this study, groups E and C + E had higher villi height and less neutrophil infiltration, pointing thus to a correlation between mucosal damage and neutrophil infiltration.

Administration of drugs before the onset of the episode of ischemia also showed good results. Pretreatment with oral vitamin C showed attenuation of I/R injury in an experimental model. Its use for five days improved the ability of muscle contraction, reduced neutrophil infiltration, tissue edema and the burst of the neutrophils' respiratory cycle<sup>26</sup>. The preoperative use for a long period (five days) of L-arginine and methyl nitro-L-arginine attenuated ischemia and reperfusion in an experimental model in rats, with reduced leukocyte infiltration, as assessed by biochemical markers, such as the serum level of nitric oxide<sup>27</sup>, this effect being observed with their use in the immediate pre-ischemic period<sup>28</sup>.

In the present study, there was a progressive decrease in height of villi and an increase in neutrophil infiltration during reperfusion, as well as a significant

reduction of mucosal damage in animals treated with vitamin E or C + E. This benefit could not be demonstrated in animals treated with vitamin C alone. This improvement in the height of villi was not previously demonstrated in other works and may be due to the form of administration of vitamin E. In most studies vitamin E is administered during the ischemic period by subcutaneous injection. In this work, we used the enteral route, which may have allowed an increase in deposits of vitamin E in tissues and its more effective action during reperfusion as retainer of ROS. Regarding vitamin C, the experiment showed no significant benefit of its administration alone. In this study, a significant increase in neutrophil infiltration was observed in all groups, but again with different responses to treatment. The groups treated with vitamin E or C + E showed significantly fewer neutrophils infiltrating the mucosa at the end of the study period.

It is inferred, therefore, that preoperative nutrition with vitamin E decreases I/R injury of the small intestine of rats submitted to an experimental model of microvascular flap of jejunum. Its administration is easy and safe. No benefit could be demonstrated in this model for the use of vitamin C.

## R E S U M O

**Objetivo:** Avaliar o papel do pré-tratamento com antioxidantes dietéticos em um modelo experimental de lesão intestinal de isquemia-reperfusão (I/R) em ratos. **Métodos:** Noventa ratos Wistar adultos machos foram utilizados. Um segmento intestinal foi isolado baseado em seu pedículo vascular. Uma biópsia controle foi realizada e o pedículo foi seccionado e anastomosado novamente, garantindo um tempo de isquemia de 60 minutos, seguido por reperfusão. Biópsias sequenciais foram realizadas ao término do período isquêmico e a cada 15 minutos, durante a reperfusão. O tratamento consistiu de solução salina ou vitamina C ou vitamina E ou a associação destas. Avaliações quantitativa e qualitativa das biópsias foram realizadas. **Resultados:** Os grupos tratados com vitamina E isolada ou associada com vitamina C apresentaram uma atenuação estatisticamente significativa da lesão de isquemia-reperfusão, com diminuição da perda de altura dos vilos e menor infiltração neutrofílica ao final do estudo quando comparados ao grupo controle e vitamina C exclusiva. **Conclusão:** Neste modelo experimental de isquemia-reperfusão, o pré-tratamento com vitamina E atenuou a lesão de I/R no intestino delgado, demonstrado pela diminuição da perda de altura dos vilos e pela atenuação da infiltração neutrofílica.

**Descritores:** Isquemia. Reperfusão. Traumatismo por reperfusão. Microcirurgia. Antioxidantes.

## REFERÊNCIAS

- Granger DN, Korthuis RJ. Physiologic mechanisms of postischemic tissue injury. *Annu Rev Physiol* 1995;57:311-32.
- Brandt JL. Mesenteric vascular disease. In: Friedland SL, editor: *Current diagnosis and treatment in gastroenterology*. New York: McGraw-Hill; 2003. section 1.9.
- Mallik IH, Yang W, Winslet MC, Seifalian AM. Ischemia-reperfusion injury of the intestine and protective strategies against injury. *Dig Dis Sci* 2004;49(9):1359-77.
- Nakamura M, Ozaki M, Fuchinoue S, Teraoka S, Ota K. Ascorbic acid prevents ischemia-reperfusion injury in the rat small intestine. *Transpl Int* 1997;10(2): 89-95.
- Kotegawa M, Sugiyama M, Shoji T, Haramaki N, Ogura R. Effect of alpha-tocopherol on high energy phosphate metabolite levels in rat heart by 31P-NMR using a Langendorff perfusion technique. *J Mol Cell Cardiol* 1993;25(9):1067-74.
- Das DK, Maulik N. Antioxidant effectiveness in ischemia-reperfusion tissue injury. *Methods Enzymol* 1994;233:601-10.
- Seidenberg B, Rosenak SS, Hurwitt ES, Som ML. Immediate reconstruction of the cervical esophagus by a revascularized isolated jejunal segment. *Ann Surg* 1959; 149(2):162-71.
- Feng GM, Yang WG, Huang-Tang Chen S, Chu YM, Tsai LM, Chang TM, et al. Periodic alterations of jejunal mucosa morphology following free microvascular transfer for pharyngoesophageal reconstruction. *J Plast Reconstr Aesthet Surg* 2006;59(12): 1312-7.
- Chiu CJ, McArdle AH, Brown R, Scott HJ, Gurd FN. Intestinal mucosal lesion in low-flow states. I. A morphological, hemodynamic, and metabolic reappraisal. *Arch Surg* 1970;101(4):478-83.
- Byrka-Owczarek K, Steplewska-Mazur K, Krasoń M, Bohosiewicz J, Koszutski T, Wojtynek G. The evaluation of the protective action

- of antioxidants on small intestine of rabbits experimentally injured by ischemia and reperfusion. *J Pediatr Surg* 2004;39(8): 1226-9.
11. Higa OH, Parra ER, Ab'Saber AM, Farhat C, Higa R, Capelozzi VL. Protective effects of ascorbic acid pretreatment in a rat model of intestinal ischemia-reperfusion injury: a histomorphometric study. *Clinics* 2007;62(3):315-20.
  12. Günel E, Cağlayan F, Cağlayan O, Dilsiz A, Duman S, Aktan M. Treatment of intestinal reperfusion injury using antioxidative agents. *J Pediatr Surg* 1998;33(10):1536-9.
  13. Petra F, Drowatzky J, Boengler K, Finckh B, Schmitz KJ, de Groot H. Protection from glycine at low doses in ischemia-reperfusion injury of the rat small intestine. *Eur Surg Res* 2011;46(4):180-7.
  14. Park SW, Lee SM. Antioxidant and prooxidant properties of ascorbic acid on hepatic dysfunction induced by cold ischemia/reperfusion. *Eur J Pharmacol* 2008;580(3):401-6.
  15. Bailey DM, Raman S, McEneny J, Young IS, Parham KL, Hullin DA, et al. Vitamin C prophylaxis promotes oxidative lipid damage during surgical ischemia-reperfusion. *Free Radic Biol Med* 2006;40(4):591-600.
  16. Cizova H, Papezikova I, Kubala L, Lojek A, Ciz M. Increased antioxidant capacity of serum did not prevent lipid peroxidation in the intermittent ischemia-reperfusion of rat small intestine. *Dig Dis Sci* 2006;51(4):657-61.
  17. Polat KY, Aydinli B, Polat O, Aydin U, Yazici P, Ozturk G, et al. The protective effect of aprotinin and alpha-tocopherol on ischemia-reperfusion injury of the rat liver. *Transplant Proc* 2008;40(1):63-8.
  18. Yoshida WB, Alasio T, Mazziotta R, Qin F, Kashani M, Lee S, et al. Effect of alpha-tocopherol, taurine and selenium on the attenuation of ischemia/reperfusion injury of splanchnic organs. *Cardiovasc Surg* 1998;6(2):178-87. Erratum in: *Cardiovasc Surg* 1998;6(6):682.
  19. Sukhotnik I, Khateeb K, Mogilner JG, Helou H, Lurie H, Coran AG, et al. Dietary glutamine supplementation prevents mucosal injury and modulates intestinal epithelial restitution following ischemia-reperfusion injury in the rat. *Dig Dis Sci* 2007;52(6):1497-504.
  20. Bartels M, Biesalski HK, Engelhart K, Sendlhofer G, Rehak P, Nagel E. Pilot study on the effect of parenteral vitamin E on ischemia and reperfusion induced liver injury: a double blind, randomized, placebo-controlled trial. *Clin Nutr* 2004;23(6):1360-70.
  21. Ozkan OV, Yuzbasioglu MF, Ciralik H, Kurutas EB, Yonden Z, Aydin M, et al. Resveratrol, a natural antioxidant, attenuates intestinal ischemia/reperfusion injury in rats. *Tohoku J Exp Med* 2009;218(3):251-8.
  22. Sood R, Narang AP, Abraham R, Arora U, Calton R, Sood N. Changes in vitamin C and vitamin E during oxidative stress in myocardial reperfusion. *Indian J Physiol Pharmacol* 2007;51(2):165-9.
  23. Wagner FM, Weber AT, Ploetze K, Schubert F, Pfeiffer S, Albrecht S, et al. Do vitamins C and E attenuate the effects of reactive oxygen species during pulmonary reperfusion and thereby prevent injury? *Ann Thorac Surg* 2002;74(3):811-7; discussion 817-8.
  24. Tomur A, Etlik O, Gundogan NU. Hyperbaric oxygenation and antioxidant vitamin combination reduces ischemia-reperfusion injury in a rat epigastric island skin-flap model. *J Basic Clin Physiol Pharmacol* 2005;16(4):275-85.
  25. Sukhotnik I, Coran AG, Greenblatt R, Brod V, Mogilner J, Shiloni E, et al. Effect of 100% oxygen on E-selectin expression, recruitment of neutrophils and enterocyte apoptosis following intestinal ischemia-reperfusion in a rat. *Pediatr Surg Int* 2008;24(1): 29-35.
  26. Kearns SR, Moneley D, Murray P, Kelly C, Daly AF. Oral vitamin C attenuates acute ischaemia-reperfusion injury in skeletal muscle. *J Bone Joint Surg Br* 2001;83(8):1202-6.
  27. Krauss H, Sosnowski P, Biczysko M, Biczysko W, Majewski P, Jablecka A, et al. Effects of L-arginine and NG-nitro L-arginine methyl ester (L-NAME) on ischemia/ reperfusion injury of skeletal muscle, small and large intestines. *Chin J Physiol* 2011; 54(1):7-18. Erratum in: *Chin J Physiol* 2011;54 (2):143.
  28. Taha MO, Miranda-Ferreira R, Fagundes AL, Fagundes DJ, Simões RS, Santos JM, et al. Effects of L-nitro-arginine methyl ester, an inhibitor of nitric oxide biosynthesis, on intestinal ischemia/reperfusion injury in rabbits. *Transplant Proc* 2010;42(2):457-60. Erratum in: *Transplant Proc* 2010;42(4):1385. Oliveira IS Jr [corrected to Oliveira-Júnior IS].
- Received on 11/02/2011  
Accepted for publication 04/05/2011  
Conflict of interest: none  
Source of funding: none
- How to cite this article:**  
Köhler HF, DeLucca IMS, Snraglia Neto L. Enteral antioxidants in ischemia/ reperfusion injury in rats. *Rev Col Bras Cir.* [periódico na Internet] 2011; 38(6). Disponível em URL: <http://www.scielo.br/rcbc>
- Correspondence address:**  
Hugo Kohler Fontan  
E-mail: [hkohler75@uol.com.br](mailto:hkohler75@uol.com.br)