

CORTICAL BONE SEGMENTATION USING WATERSHED AND REGION MERGING BASED ON STATISTICAL FEATURES

Mamluatul Hani'ah, Christian Sri kusuma Aditya, Aryo Harto, and Agus Zainal Arifin

Department of Informatics Engineering, Faculty of Information Technology, Sepuluh Nopember Institute of Technology, Jl. Arief Rahman Hakim, Surabaya 60111, East Java, Indonesia

E-mail: mamluatul14@mhs.if.its.ac.id, christian_ozora@yahoo.com, aryo14@mhs.if.its.ac.id

Abstract

Research on medical images becomes one of the studies that attracted many researchers, because it can help medical field to analyse the disease. One of the existing research in medical image is using dental panoramic radiographs image to detect osteoporosis. The analysed area is the width of cortical bone. Determination of the cortical bone width requires proper segmentation on the dental panoramic radiographs image. This study proposed the integration of watershed and region merging method based on statistical features for cortical bone segmentation on dental panoramic radiographs. Watershed segmentation process perform using gradient magnitude value from the input image. The watershed image that has excess segmentation can be solved by region merging based on statistical features. Statistical features used in this study is mean, standard deviation, and variance. The similarity of adjacent regions measure with weighted Euclidean distance from the statistical feature of the regions. Merging process will run by incorporating the background regions as many as possible, while keeping the object regions from being merged. Results of segmentation has succeeded in forming contour of the cortical bone. The average value of accuracy is 93.211%, the average value of sensitivity is 93.858%, and the average value of specificity is 93.071%.

Keywords: *dental panoramic radiographs, cortical bone, segmentation, watershed, region merging*

Abstrak

Penelitian terhadap citra medis menjadi salah satu penelitian yang banyak diminati karena dapat membantu dokter untuk menganalisa penyakit. Salah satu penelitian yang ada dalam citra medis adalah menggunakan citra *dental panoramic radiographs* untuk mendeteksi *osteoporosis*. Daerah yang dianalisis adalah lebar dari *cortical bone*. Segmentasi yang tepat sangat dibutuhkan untuk menentukan lebar *cortical bone* pada *dental panoramic radiographs*. Pada penelitian ini diusulkan integrasi metode *watershed* dan metode *region merging* berbasis fitur statistik untuk segmentasi *cortical bone* pada *dental panoramic radiographs*. Citra masukan berupa *cortical bone* dilakukan proses *gradient magnitude* kemudian dilanjutkan dengan proses segmentasi menggunakan *watershed*. Citra hasil proses *watershed* yang masih memiliki segmentasi berlebih dilakukan proses *region merging* berbasis fitur statistik. Selanjutnya kemiripan antar *region* dihitung dengan menggunakan *weighted Euclidean distance* dari fitur statistik setiap *region*. Fitur statistik yang digunakan adalah *mean, variance*, dan standar deviasi. Proses merging akan berjalan dengan melakukan penggabungan pada daerah *background* terlebih dahulu selanjutnya sisa *region* yang dihasilkan akan digabungkan sebagai daerah objek. Hasil segmentasi yang dilakukan telah berhasil membentuk *contour* dari *cortical bone*. Dari hasil uji coba didapatkan rata-rata akurasi 93,211%, rata-rata sensitifitas 93,858%, dan rata-rata spesifisitas 92,071%.

Kata Kunci: *dental panoramic radiographs, cortical bone, segmentasi, watershed, region merging*

1. Introduction

Patients with osteoporosis always increase every year. In 2000 the number of people with osteoporosis reached 9 million and is estimated to increase to 50 million people [1]. Osteoporosis is a skeletal disorder characterized by decrease in bone mass and micro-architectural damage to the

bone tissue causing bone fragility and susceptibility to fracture [2]. Diagnosis of osteoporosis is largely based on the measurement of Bone Mineral Density (BMD) using Dual Energy X-ray Absorptiometry (DXA) scanner on the spine or thighs [3]. However, the availability of DXA equipment is still limited to identify a large segment of individuals with undetected osteoporosis [4].

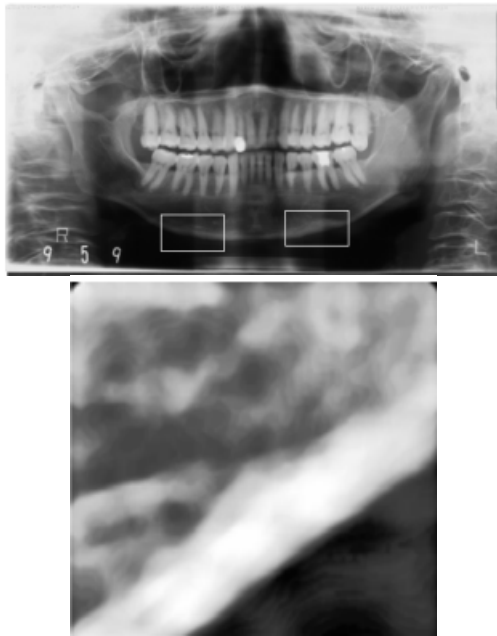


Figure 1. Sample of Cortical bone.

Besides using DXA, the other osteoporosis disease detection can be performed using dental panoramic radiographs. Arifin et al. [5] conducted research by using dental panoramic radiographs to diagnose osteoporosis. That study develop a computer-aided system to automatically measure the width of the mandibular inferior cortex and then look for correlation to BMD which is measured by DXA on the spine and thigh.

Areas that are used in dental panoramic radiographs to detect osteoporosis is on the cortical bone. The detection is done by measuring the width of the cortical bone area. Cortical bone width measurements can be performed using segmentation method, one of the mathematical morphology methods are very popular for grayscale image segmentation is the watershed. Research on dental panoramic radiographs by Wahyudi et al. [6] and Indriyani et al. [7] were done by using a watershed method. In those studies a segmentation is performed on the cortical bone using watershed that integrate with the active contour. Research by Wahyudi et al. [6] using the active contour GGVF snake while research by Indriyani et al. using the level set based active contour. Watershed has advantages can generate a closed contour with a thickness of one pixel. While on active contour can detect the boundary of the object and move dynamically from an initial position towards the expected object.

Segmentation on the cortical bone by using watershed method is still producing region that cannot directly represent the shape of object and the background. This weakness for over segmen-

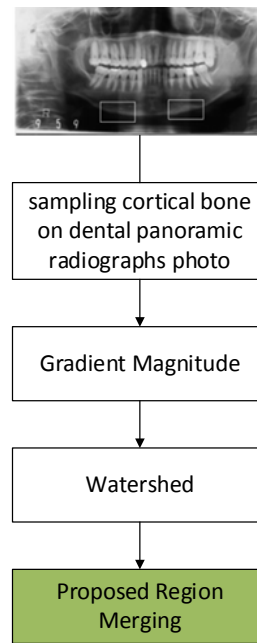


Figure 2. Schematic diagram for system

tation, causing the result cannot be maximal. Because of that weakness, previous research used region merging method which still produce a lot of regions, at least more than one region. Ning et al. [8] proposed a method of region merging called MRSM. This method can produce a region that directly represent the shape of the object and the background. MRSM combining the region by using the color histogram similarities of each region. User only need some strokes as input to identify initial object regions and background regions.

The image of dental panoramic radiographs are a result from X-ray is a grayscale image so the MRSM method cannot be applied with dental panoramic radiographs because region merging on the MRSM is performed on color histogram. Therefore we need a new method of region merging which can directly represent the object and the background and can be used for grayscale images.

This study proposed the integration of watershed and region merging method based on statistical features for segmentation of cortical bone on dental panoramic radiographs. The proposed region merging method based on statistical features. Furthermore, the similarity between regions will be calculated by using weighted Euclidean distance. Merging process will be run by incorporating the background regions as many as possible while keep the object regions from being merged. The rest of this paper is organized as follows: Section 2 presents details of the materials and methods. Section 3 presents the results and discussion. Section 4 concludes the paper.




Figure 3. Gradient magnitude.




Figure 4. Watershed results

2. Methods

In this section we first describe the materials that we used. Details of the method will be described afterward.

Materials

The data used in this study is a sample image on cortical bone with resolution 256 x 256 pixels. The sample of cortical bone image is used with the assumption that the image has been taken in good condition, so it does not require image enhancement. The image used in this research is the X-Ray image of the teeth from 10 Japanese women. Data is taken randomly from patients undergoing DXA imaging in 1996 to 2001. From that 10 images, 10 cortical bone images on the left side and 10 cortical bone images on the right side will be obtained. The area which is taken as the sample can be seen in Figure 1.

Methods

In this paper, we proposed integration of watershed and region merging method based on statistical features for cortical bone segmentation on dental panoramic radiographs. Schematic diagram of this study is including (i) cortical bone sampling on dental panoramic radiographs image (ii) the calculation of gradient magnitude (iii) watershed (iv) proposed region merging method. These steps can be seen in Figure 2.

Gradient Magnitude

The process of gradient magnitude requires the input of cortical bone image. Calculation of gradient magnitude aims to provide better results for watershed process. It is because in the gradient image the boundaries of objects could be located on the ridges and taken as watershed pixels [9]. Gradient magnitude used in this study by using prewitt operator and morphological filtering. The pr-

ewitt operator is one of method that frequently used for edge detection and an appropriate way to estimate the magnitude [10]. Results from the gradient magnitude can be seen in Figure 3.

Watershed

Watershed is the mathematical morphology based image segmentation. Watershed frequently constructed on gradient magnitude image [11]. The watershed process use result image from gradient magnitude process that have been calculated before. Segmentation results performed by the watershed have a lot of regions and can be seen in Figure 4. A region can be described in many aspects, such as the color, edge [12], texture [13], shape, and size of the region.

Proposed Region Merging

After watershed process produce regions, the regions must be merged because watershed segmentation often lead over segmentation. The merging needed to produce one region of object. In this step we enlarge the area of the regions by finding the similarity between the adjacent regions.

The similarity of adjacent regions measure with weighted Euclidean distance from the statistical feature of the regions. Statistical features used in this study is mean, standard deviation, and variance.

$$d_{R,Q} = \sqrt{w_1(\Delta\mu)^2 + w_2(\Delta\sigma)^2 + w_3(\Delta\delta)^2} \quad (1)$$

$d_{R,Q}$ from equation(1) denotes the distance between the regions R to region Q , whereas $\Delta\mu$ is the difference between the average of region R and the region Q . $\Delta\sigma$ is the difference between the variance of region R and the region Q and then the difference between standard deviation is represented by $\Delta\delta$. The value w which we used in this study was obtained from the experimental results. Optimal weights for $w_1=0.3$, $w_2=0.7$, and $w_3=0.1$

The merging process on the proposed method uses the idea of the MSRM algorithm. User

Algorithm 1 : Proposed region merging

Input : segmentation result from watershed process

Output : the final segmentation

For each region calculate the statistical features (mean, standard deviation, and variance).

While there is region merging in the last loop

First Stage :

Merging region marker background regions with their adjacent regions.

- 1.a. For the similarity calculate the distance between the adjacent regions using equation(1).
- 1.b. Merge adjacent region that have smallest distance.
- 1.c. Update the region list
- 1.d. If the new region do not find new merging regions, the first stage end.
- 1.e. Otherwise calculate statistical feature on new region and go back to 1.a.

Second Stage :

Merging non marker regions

Input: the merging result from the first stage.

- 2.a. For all regions do not belong to marker object regions and marker background regions
- 2.b. Calculate distance between the adjacent regions using equation (1).
- 2.c. Merge adjacent region that have smallest distance
- 2.d. Update region list
- 2.e. If the new region do not find new merging regions, the second stage end.
- 2.f. Otherwise calculate statistical feature on new region and go back to 2.a.

only need some strokes as input to identify initial object regions and background regions. It takes two strokes to the edges of objects and two strokes for background initialization area.

Merging process starts on combining the background regions as many as possible while keeping object regions from being merged. For detail the merging process has two stages, it will be repeated until there is no region that need to merge. First stage is merge marker background with their adjacent regions. Adjacent regions that has the smallest distance will be combined first and then the new region will be combined with their adjacent region which has the smallest distance. The iteration stops when the whole marker background regions will not find a new merging regions.

The non-marker regions that remained from the first stage will be merge in the second stage. The non-marker object regions will be fused each other with the same rule as first stage. Regions will be merge with their adjacent that has the smallest distance will be combined first and then the new region will be combined with their adjacent regions which has the smallest distance. The first and the second stage will be executed repeatedly until there is no new merger occurs. The whole algorithm can be described in algorithm 1.

The result of this algorithm is the image that has labelled one of two classes: the object or the background. Object and background initialization




Figure 5. (a) marker initialization on the right cortical bone (b) marker initialization on the left cortical bone.




Figure 6. (a) merging process on the right cortical bone (b) merging process on the left cortical bone.

can be seen in Figure 5 (a) and 5 (b) and the merging process can be seen in Figure 6 (a) and 6 (b).

3. Results and Analysis

Cortical bone of 10 Japanese women were used to confirm the effectiveness of proposed method. Each subject consists a sample of cortical bone on the right and left side. Examples of image segmentation results can be seen in Figure 7 and Figure 8.

To evaluate performance quantitatively of the proposed method, we are using accuracy, sensitivity, and specificity. Accuracy is the ratio of pixels that are correctly classified for the entire area of cortical bone. Sensitivity is the probability that the segmented pixels are the cortical bone. Specificity is the probability that the non-segmented pixels are detected as non-cortical bone. To calculate the accuracy, sensitivity, and specificity is presented by equation(2), equation(3), and equation (4).

$$Accuracy = \frac{TP+FN}{TP+TN+FP+FN}, \quad (2)$$

$$Sensitivity = \frac{TP}{TP+FN}, \quad (3)$$

$$Spesificity = \frac{TN}{FP+TN}, \quad (4)$$

In this study, the ground truth data is obtained from research by Wahyudi et al. [6]. True Posi-




Figure 7. Results of cortical bone segmentation in the left.

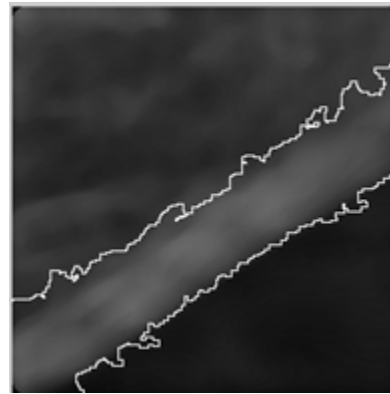


Figure 8. Results of cortical bone segmentation in the right side.

TABLE 1
THE ACCURACY, SENSITIVITY, SPECIFICITY IN THE RIGHT SIDE OF CORTICAL BONE

No	Sample	Accuracy (%)	Sensitivity (%)	Specificity (%)
1	Right sample 1	94.31	92.00	95.03
2	Right sample 2	91.80	99.35	90.26
3	Right sample 3	91.70	94.63	90.97
4	Right sample 4	90.66	87.87	91.32
5	Right sample 5	93.03	96.40	92.34
6	Right sample 6	92.76	92.86	92.74
7	Right sample 7	91.52	85.50	92.75
8	Right sample 8	91.58	97.30	90.28
9	Right sample 9	94.05	91.09	94.78
10	Right sample 10	95.26	96.00	95.07

TABLE 2
THE ACCURACY, SENSITIVITY, SPECIFICITY IN THE LEFT SIDE OF CORTICAL BONE

No	Sample	Accuracy (%)	Sensitivity (%)	Specificity (%)
1	Left sample 1	90.34	96.28	89.09
2	Left sample 2	95.00	89.66	96.05
3	Left sample 3	94.82	85.66	97.44
4	Left sample 4	93.61	99.48	92.03
5	Left sample 5	95.04	89.72	96.05
6	Left sample 6	94.41	98.94	93.42
7	Left sample 7	94.27	93.82	94.41
8	Left sample 8	94.74	93.65	95.00
9	Left sample 9	95.04	96.97	94.51
10	Left sample 10	90.28	99.98	87.89

tive (TP) is a condition where the computer detection results are positive and match with the ground truth value that pixel of cortical bone is detected as cortical bone. False Positive (FP) is a condition where the computer detection results are positive but not match with the ground truth value that pixel of non-cortical bone is detected as cortical bone. False Negative (FN) is a condition where the computer detection results are negative but not match with the ground truth value that pixel of cortical bone is detected as non-cortical bone. True Negative (TN) is a condition where the computer detection results are negative and match with the ground truth value that pixel of non-cortical bone is detected as non-cortical bone.

Experiments showed the segmentation that we have successfully formed cortical bone as expected without any form other regions. Table 1 contains the data from the right side of cortical bone and it can be seen that the highest accuracy on the right sample is 95.26% on the sample number 10 while the lowest accuracy is 90.66% on the sample number 4. The highest sensitivity is 99.35% on the sample number 2 and the lowest is 85.50% on the sample number 7. The highest spe-

cificity is 95.07% on the sample number 10 while the lowest is 90.26% on the sample number 2.

Table 2 contains the value of accuracy, sensitivity, and specificity from the left side of cortical bone. It can be seen that the highest accuracy is 95.04% possessed by samples number 5 and 9 while the lowest accuracy is 90.28% on the sample number 10. The best sensitivity is 99.98% on sample number 10 while the lowest sensitivity is 85.66% on the sample number 3. The highest specificity is 97.44% produced by the sample number 3 while the lowest is 87.89% on the samples number 10.

Comparison of accuracy, sensitivity and specificity with Wahyudi et al. [6] and Indriyani et al. [7] can be seen in Table 3 and 4. From the tables it can be seen that the value of accuracy and specificity of the proposed method has a lower value when compared to the other methods, but the sensitivity value of the proposed method has a better value than the method from Wahyudi et al. [6]. Accuracy and specificity is lower than previous method because some of the non-cortical bone pixel are detected as segmented cortical bone. Borders of cortical bone on dental panoramic radio-

TABLE 3
THE COMPARISON OF ACCURACY, SENSITIVITY, SPECIFICITY CORTICAL BONE RIGHT SIDE OF PROPOSED METHOD WITH WAHYUDI ET AL.[6] AND INDRIYANI ET.AL [7]

No	Sample	Accuracy (%)			Sensitivity (%)			Specificity (%)		
		Proposed method	Wahyudi et al. [6]	Indriyani et al. [7]	Proposed method	Wahyudi et al. [6]	Indriyani et al. [7]	Proposed method	Wahyudi et al. [6]	Indriyani et al. [7]
1	Right sample 1	94.31	94.3	98.7	92	81.1	99	95.03	98.4	98.6
2	Right sample 2	91.8	94.6	98.9	99.35	75.3	99.1	90.26	98.5	98.8
3	Right sample 3	91.7	96	98.8	94.63	87.9	99.1	90.97	98.1	98.6
4	Right sample 4	90.66	92.8	99.1	87.87	69.9	99.9	91.32	98.2	98.3
5	Right sample 5	93.03	95.5	98.9	96.4	76.1	99.1	92.34	99.5	98.7
6	Right sample 6	92.76	96	96.3	92.86	85.4	99.1	92.74	98.9	93.7
7	Right sample 7	91.52	95.4	99	85.5	78.4	99.1	92.75	98.9	99
8	Right sample 8	91.58	96.3	99.1	97.3	83.7	99	90.28	99.2	99.1
9	Right sample 9	94.05	95.4	98.4	91.09	80.5	99.1	94.78	99.1	97.8
10	Right sample 10	95.26	95.6	98.8	96	80.2	99	95.07	99.5	98.6

TABLE 4
THE COMPARISON OF ACCURACY, SENSITIVITY, SPECIFICITY CORTICAL BONE LEFT SIDE OF PROPOSED METHOD WITH WAHYUDI ET AL. [6] AND INDRIYANI ET.AL [7]

No	Sample	Accuracy (%)			Sensitivity (%)			Specificity (%)		
		Proposed method	Wahyudi et al. [6]	Indriyani et al. [7]	Proposed method	Wahyudi et al. [6]	Indriyani et al. [7]	Proposed method	Wahyudi et al. [6]	Indriyani et al. [7]
1	Left sample 1	90.34	93.9	98.8	96.28	69	99	89.09	99.1	98.6
2	Left sample 2	95	95.8	98.8	89.66	82.3	99	96.05	98.5	98.6
3	Left sample 3	94.82	92.7	98.9	85.66	68.4	99.1	97.44	99.7	98.7
4	Left sample 4	93.61	92.5	99	99.48	71.2	99.1	92.03	98.2	98.9
5	Left sample 5	95.04	95	98.9	89.72	72.5	99.1	96.05	99.3	98.8
6	Left sample 6	94.41	95.5	98.8	98.94	88	99.1	93.42	97.2	98.6
7	Left sample 7	94.27	94.9	98.9	93.82	86.8	99	94.41	97.3	98.8
8	Left sample 8	94.74	95.6	99	93.65	79.6	99.1	95	99.5	98.9
9	Left sample 9	95.04	95.5	99.2	96.97	82.4	100	94.51	99.1	98.5
10	Left sample 10	90.28	95.2	99	99.98	86.1	99.1	87.89	97.5	98.9

TABLE 5
THE COMPARISON OF AVERAGE RUNNING TIME OF PROPOSED METHOD WITH WAHYUDI ET AL. [6] AND INDRIYANI ET.AL [7]

Parameters	Proposed Method	Wahyudi et.al [6]	Indriyani et.al [7]
Running time left sample (s)	123.64	176.96	195.26
Running time right sample (s)	112.32	146.97	186.35

graphs are not clear (blurred). Therefore, the statistical feature of blurred regions more similar to the object region rather than the background region so the blurred regions merged to object region. In the proposed method the formation of segmentation strongly influenced by the marker which is used for object and background initialization. This is because the similarity measurement between features used always choose the regions that have minimal similarities of statistical feature in the regions. So it is possible for the object regions mer-

ged with the background regions otherwise the background regions possible to merged with object regions.

Table 5 gives the detail of average running time of proposed method compared with Wahyudi et al. and Indriyani et al., which are performed on a PC with i5-3230 M 2.60 GHz CPU and 4GB RAM. Seen from Table 5 the integration of watershed and region merging method based on statistical features has less running time than Wahyudi et al. [6] and Indriyani et al. [7]. The proposed method will further reduce complexity because there is no need for other methods such as active contour for improve the segmentation.

4. Conclusion

In this study the integration of watershed and region merging method based on statistical features for cortical bone segmentation on dental panoramic radiographs has been carried out. Statistical features that we used is mean, variance, and standard deviation. These features will be calculated

for each region and then the similarity between regions will be calculated using weighted Euclidean distance. Based on experiments, segmentation results obtained have been successfully formed contour of the cortical bone. The average value of the accuracy is 93.211%, the average value of sensitivity is 93.858%, and the average value of specificity is 93.071%.

In the future there should be further research using more statistical features and calculating similarities with other methods. Future development on this method also can be done by improving the weight. It can be improved by using evolutionary algorithm to determine the weight automatically.

References

- [1] O. Johnell and J. A. Kanis, "An estimate of the worldwide prevalence and disability associated with osteoporotic fractures," *Osteoporosis international*, vol. 17, no. 12, pp. 1726-1733, 2006.
- [2] R. Bartl and B. Frisch, "Definition of osteoporosis," *Osteoporosis*, pp. 24-32, 2004.
- [3] J.-Y. Reginster and N. Burlet, "Osteoporosis: a still increasing prevalence," *Bone*, vol. 38, no. 2, pp. 4-9, 2006.
- [4] J. A. Kanis and O. Johnell, "Requirements for DXA for the management of osteoporosis in Europe," *Osteoporosis International*, vol. 16, no. 3, pp. 229-238, 2005.
- [5] A. Z. Arifin, A. Asano, A. Taguchi, T. Nakamoto, M. Ohtsuka, M. Tsuda, Y. Kudo and K. Tanimoto, "Computer-aided system for measuring the mandibular cortical width on dental panoramic radiographs in identifying postmenopausal women with low bone mineral density," *Osteoporosis international*, vol. 17, no. 5, pp. 753-759, 2006.
- [6] D. Wahyudi, A. Z. Arifin and R. Soelaiman, "Segmentasi Cortical bone pada Citra Dental Panoramic Radiograph Menggunakan Watershed dan Active Contour GGVF Snake," *Teknik Informatika Institut Teknologi Sepuluh Nopember*, Surabaya, 2008.
- [7] T. Indriyani, A. Z. Arifin and R. Soelaiman, "Segmentasi Cortical bone pada Citra Dental Panoramic Radiograph Menggunakan Watershed berintegrasi dengan Active Contour berbasis Level Set," *Teknik Informatika Institut Teknologi Sepuluh Nopember*, Surabaya, 2009.
- [8] J. Ning, L. Zhang, D. Zhang and C. Wu, "Interactive image segmentation by maximal similarity based region merging," *Pattern Recognition*, vol. 43, no. 2, pp. 445-456, 2010.
- [9] H. Sun, J. Yang and M. Ren, "A fast watershed algorithm based on chain code and its application in image segmentation," *Pattern Recognition Letters*, vol. 26, no. 9, pp. 1266-1274, 2005.
- [10] N. Senthilkumaran and R. Rajesh, "Edge detection techniques for image segmentation: a survey of soft computing approaches," *International journal of recent trends in engineering*, vol. 1, no. 2, pp. 250-254, 2009.
- [11] F. Meyer, "Topographic distance and watershed lines," *Signal processing*, vol. 38, no. 1, pp. 113-125, 1994.
- [12] S. Birchfield, "Elliptical head tracking using intensity gradients and color histograms," in *Computer Vision and Pattern Recognition, 1998. Proceedings. 1998 IEEE Computer Society Conference on*, 1998.
- [13] T. Ojala, M. Pietikäinen and T. Mäenpää, "Multiresolution gray-scale and rotation invariant texture classification with local binary patterns," *Pattern Analysis and Machine Intelligence, IEEE Transactions on*, vol. 24, no. 7, pp. 971-987, 2002.