

Functional assessments and histopathology of hepatorenal tissues of rats treated with raw and processed herbs

Okey A. Ojiako¹, Paul C. Chikezie^{2*}, Doris I. Ukairo¹, Chiedozi O. Ibegbulem¹,
Reginald N. Nwaoguikpe¹

¹ Department of Biochemistry, Federal University of Technology, Owerri, Nigeria

² Department of Biochemistry, Imo State University, Owerri, Nigeria

*Corresponding author: Paul C. Chikezie; E-mail: p_chikezie@yahoo.com; Phone: +2348038935327

Received: 09 May 2017; Revised submission: 30 June 2017; Accepted: 05 July 2017

Copyright: © The Author(s) 2017. European Journal of Biological Research © T.M.Karpiński 2017. This is an open access article licensed under the terms of the Creative Commons Attribution Non-Commercial 4.0 International License, which permits unrestricted, non-commercial use, distribution and reproduction in any medium, provided the work is properly cited.

DOI: <http://dx.doi.org/10.5281/zenodo.823220>

ABSTRACT

The present study ascertained the functional integrity of hepatic and renal tissues, concurrently with blood lipid patterns, of Wistar rats infused with CCl₄ and treated with raw and hydrothermal processed herbs, namely, *Monodora myristica*, *Chromolaena odorata*, *Bucchozia coriacea* and *Sphenostylis stenocarpa*. Measurement of phytochemical contents of the herbs was according to standard methods. The rats were randomly designated on the bases of diets and treatments received for 28 consecutive days. Fibrosis was induced in the Wistar rats by single dose intraperitoneal injection of CCl₄ for 2 consecutive days. Liver and kidney function tests and serum lipid profile were measured using spectrophotometric methods. Renal and hepatic tissues were subjected to histopathological examinations. The concentrations of alkaloids in the four herbal extracts were within the range of 4.83±0.03 - 31.33±0.29 mg/100 g sample, whereas the concentrations of saponins varied within a relatively narrow range: 0.33±0.09 - 4.33±0.02 mg/100 g dry sample; $p > 0.05$. The activity ratios of AST to ALT of the rat groups were generally less than 1.0 unit. Atherogenic indices of fibrotic rats were within the following ranges:

TAG/HDL-C ratio (3.59±0.03 - 6.76±0.06), TC/HDL-C ratio (3.72±0.02 - 6.94±0.05) and LDL-C/HDL-C ratio (2.00±0.01 - 4.59±0.02). Losses in phytochemical contents following hydrothermal processing of the herbs did not substantially affect their overall therapeutic scores against morphological and functional impairments of hepatic and renal tissues following CCl₄ intoxication of the rats.

Keywords: Carbon tetrachloride; Histopathology; Hydrothermal; Kidney; Liver.

1. INTRODUCTION

The metabolic concerns of hepatic tissues, among several physiologic functions, ensure the detoxification of endogenously formed toxic molecules and xenobiotics through concerted processes of functional enzyme systems and facilitated by adaptable anatomical architecture [1, 2]. Additionally, administered drugs and metabolic waste products are eliminated by a combination of hepatic metabolism and renal excretion [3]. The kidneys, which are located in the posterior abdominal wall, are the principal organs for osmoregulation, electrolytes balance and regulation of blood pH levels as well as elimination of detoxified xeno-

biotics from the vascularsystem [4].

Biochemical investigations using hepatic and renal functional indices, the so-called liver function test (LFT) and kidney function test (KFT), coupled with histopathological studies have revealed that dysfunctional and morphological damage hepatic tissues predispose animal models to developing acute renal failure when exposed, in acute way, to chemical toxicants [5-9]. Carbon tetrachloride (CCl₄) is a chemical agent noted to be toxic to hepatorenal tissues in experimental animals and human subjects [5, 6, 8, 10-13]. Reports showed that CCl₄ toxicity is elicited by microsomal *CYP2E1*-induced formation of reactive trichloromethyl (CCl₃[•]) radical and the highly reactive oxygenated derivative, trichloromethylperoxyl (Cl₃COO[•]) radical, which initiates lipid peroxidation and accumulation of lipid peroxidation products, engendering inflammation and fibrotic changes to hepatic and renal tissues via activation of the macrophages [1, 9, 11-14].

Herbal extracts have been reported to ameliorate hepatic and renal disorders in humans and animal models [2, 9, 13, 15]. There are vast array of Nigerian indigenous medicinal plants that are used for the treatment and management of pathologic conditions linked with overwhelming levels of reactive metabolic radicals [16, 17]. *Monodora myristica*, also called calabash Nutmeg, is an edible plant of the Annonaceae family. Phytochemical screening showed that the plant is rich in flavonoids, saponins and sterols but with minimal anti-nutrients such as cyanogenic glycosides, tannins, oxalates and phytates [18]. The medicinal usefulness of *M. myristica* has been reported elsewhere [19-22]. *Chromolaena odorata* (Linn) is commonly referred to as Siam weed, 'Elizabeth', 'Independence leaf', whereas in South-Eastern Nigeria, it is called 'Enugu plantation weed' and 'Awolowo' [23]. The proximate composition and phytochemical contents as well as the medicinal usefulness of the herb have been reported elsewhere [23-26]. *Bucchozia coriacea*, commonly called 'Wonderful Kola', is frequently use in traditional medicine practice [27]. The phytochemical contents and proximate composition as well as the medicinal usefulness of *B. coriacea* have been reported elsewhere [27-31]. *Sphenostylis stenocarpa* is commonly referred to as African yam bean. The nutra-

ceutical usefulness of the African yam bean is associated with its antioxidant and low hepatotoxic properties [32, 33]. Furthermore, Ndidi et al. [34] reported the proximate, antinutrients and mineral composition of raw and processed African yam bean.

Studies have shown that CCl₄ infusion or inhalation elicits chemical-induced multiple organ lesions such as fibrosis, cirrhosis and hepatocarcinoma [12, 13, 35, 36], and by extension, renal dysfunction in animal models [5, 6, 12]. Organ lesion and ensuing pathology elicit wide variations in concentrations of metabolites and elevation of non-functional plasma enzymes in blood samples of experimental animals. Specifically, because plasma lipoproteins, for the most part, are biosynthesized in the hepatocytes, chemical and biotic agents that impact negatively on liver functional integrity distort plasma lipid patterns [2, 37, 38]. Serum lipid profile (SLP) describes the propensity to developing atherogenic plague [2, 39]. Accordingly, functional assessments of hepatic and renal tissues, using blood indicators in conjunction with inspection of tissue morphology and integrity tests using histopathological technique, describe the level of chemical-induced organ lesions and measure of success of therapeutic interventions.

There are growing interests in the quest for multi-dimensional applications of herbs; particularly those commonly used among traditional herbal medicine practitioners, for the alleviation of pathologic conditions [13, 17, 40]. Thus, ethno-botanical bio-prospecting offers another strategy for new herbal remedy discoveries, including those used for alleviation of co-existing liver and kidney pathologic conditions. Additionally, in ethno-medicinal practices, herbs are either administered raw or subjected to hydrothermal processing prior their application. The present study sought to ascertain the functional integrity of hepatic and renal tissues, concurrently with blood lipid patterns, of Wistar rats infused with CCl₄ and treated with raw and hydrothermal processed Nigerian indigenous herbs, namely, *M. myristica*, *C. odorata*, *B. coriacea* and *S. stenocarpa*.

2. MATERIALS AND METHODS

2.1. Collection and preparation of samples

High-grade raw seeds of *M. myristica*, *B. coriacea* and *S. stenocarpa* were purchased from Relief and Obazu-Mbieri Markets located in Owerri Capital Territory, Imo State, Nigeria. Fresh leaves of *C. odorata* were harvested from a private garden in Amakihia, Owerri-North Local Government Area, Imo State, Nigeria. The samples were transported to the laboratory, identified and authenticated by Dr. E.S. Willie at the Herbarium of the Department of Agronomy, Michael Okpara University of Agriculture, Umudike, Abia State, Nigeria. All samples were collected between the months of February and March, 2015. Voucher specimens were deposited at the Herbarium for reference purposes.

The various samples were washed separately in continuous flow of distilled water for 15 min and allowed to dry at laboratory ambient temperature ($T = 24 \pm 5^\circ\text{C}$). The samples were divided into two portions on equal weight basis and designated as follows:

Group R: Raw samples

Group H: Hydrothermal processed samples.

Appropriate separate quantities of Group R samples were pulverized using Thomas-Willey milling machine (ASTM D-3182, India). The ground samples were transferred into corresponding vacuum desiccators and allowed to dry at laboratory ambient temperature until a constant weight was achieved. Appropriate separate quantities of Group H samples were boiled in distilled water in corresponding conical flasks (sample/water ratio = 1:4 w/v). According to local traditional medicine practice, hydrothermal processing of the seed samples was in the following durations: *M. myristica* = 10 min, *B. coriacea* = 1 h and *S. stenocarpa* = 1.5 h, whereas leaves of *C. odorata* were subjected to hydrothermal processing for 5 min. Next, the Group H samples were dried separately in an oven (Gallenkamp Oven 300 plus series, England) at 50°C until a constant weight was achieved. Finally, Group H samples were ground using the Thomas-Willey milling machine (ASTM D-3182; India), after which the samples were stored in separate air-tight plastic bottles with screw caps

pending extraction.

2.2. Extraction of samples

Extraction of Group R and Group H samples was according to the methods previously described [15]. Portion of 10 g each of the ground and dried Group R and Group H samples were subjected to repeated soxhlet extraction cycles for 2 h using 96% CH_3OH (BDH, U.K) as solvent to obtain final volume of 250 ml of corresponding extracts. The volumes of the extracts were concentrated and recovered in a rotary evaporator (Büch Rotavapor R-200) for 12 h at 50°C under reduced pressure. The extracts were dried in vacuum desiccators for 24 h, wrapped in aluminum foil and stored in air-tight plastic bottles with screw caps at $\leq 4^\circ\text{C}$. The yields were calculated to be as follows:

- Extract R1; Raw seeds of *M. myristica* = 8.94% (w/w).
- Extract R2; Raw leaves of *C. odorata* = 6.22% (w/w).
- Extract R3; Raw seeds of *B. coriacea* = 8.07% (w/w).
- Extract R4; Raw seeds of *S. stenocarpa* = 14.02% (w/w).
- Extract H1; Hydrothermal processed seeds of *M. myristica* = 6.41% (w/w).
- Extract H2; Hydrothermal processed leaves of *C. odorata* = 4.39% (w/w).
- Extract H3; Hydrothermal processed seeds of *B. coriacea* = 7.12% (w/w).
- Extract H4; Hydrothermal processed seeds of *S. stenocarpa* = 13.51% (w/w).

Portion of the each extract was measured for phytochemical contents. Also, the each extract was reconstituted in phosphate buffered saline (PBS) solution that was osmotically equivalent to 100 g/l PBS (90.0 g NaCl, 17.0 $\text{Na}_2\text{HPO}_4 \cdot 2\text{H}_2\text{O}$ and 2.43 g $\text{NaH}_2\text{PO}_4 \cdot 2\text{H}_2\text{O}$) and appropriate dose was administered to corresponding experimental animals.

2.3. Phytochemicals

Quantitative compositions of some phytochemicals, namely, alkaloids, flavonoids, tannins and saponins were measured using standard methods. The concentration of alkaloids and saponins were measured using the methods of

Harborne [41]. The flavonoids content was according the methods of Boham and Kocipal [42]. The concentration of tannins was measured using the methods of Van-Burden and Robinson, [43] as reported by Belonwu et al. [44].

2.4. Experimental animals

Healthy male Wistar rats (90 days old) weighing between 150-260 g were maintained at laboratory ambient temperature of 30-55% relative humidity on a 12-h light/12-h dark cycle, with access to water and standard commercial feeds (SCF) (Ewu Feed Mill, Edo State, Nigeria) *ad libitum*, for 2 weeks acclimatization period. The Institutional Review Board of the Department of Biochemistry, Federal University of Technology, Owerri, Nigeria, granted approval for this study. The care and handling of the animals conformed to the standard principles of laboratory animal care of the United States National Institutes of Health (NIH, 1978).

2.5. Infusion of carbon tetrachloride/experimental design

A total of 72 male Wistar rats were allotted into 12 groups of 6 rats each. Fibrosis was induced in the Wistar rats by single dose intra-peritoneal (i.p) injection of CCl₄ in paraffin oil as vehicle [1:1 v/v; dose = 1.0 ml/kg body weight (b.wt.)] for 2 consecutive days [45]. The animals were deprived of feeds only for additional 16 h before commencement of treatment as described [1, 46]. The rats were randomly designated on the bases of diets and treatments (dose = 250 mg/kg b.wt.; i.p. of the extracts and silymarin or otherwise 1.0 ml/kg b.wt.; i.p. of PBS, paraffin oil and CCl₄/paraffin oil mixture) received for 28 consecutive days. Silymarin (Medical Union Pharmaceuticals Company) was used as the standard drug for reference treatment of fibrotic rats [1].

- Group 1: Normal rats received SCF + water *ad libitum* + PBS.
- Group 2: Normal rats received SCF + water *ad libitum* + paraffin oil.
- Group 3: Fibrotic rats received SCF + water *ad libitum* + CCl₄/paraffin oil mixture.
- Group 4: Fibrotic rats received SCF + water *ad*

libitum + silymarin.

- Group 5: Fibrotic rats received SCF + water *ad libitum* + Extract R1.
- Group 6: Fibrotic rats received SCF + water *ad libitum* + Extract R2.
- Group 7: Fibrotic rats received SCF + water *ad libitum* + Extract R3.
- Group 8: Fibrotic rats received SCF + water *ad libitum* + Extract R4.
- Group 9: Fibrotic rats received SCF + water *ad libitum* + Extract H1.
- Group 10: Fibrotic rats received SCF + water *ad libitum* + Extract H2.
- Group 11: Fibrotic rats received SCF + water *ad libitum* + Extract H3.
- Group 12: Fibrotic rats received SCF + water *ad libitum* + Extract H4.

At the end of the feeding and treatment period, the rats were subjected to fasting for 12 h, after which the animals were sacrificed and blood samples were drawn from the orbital sinus [47] and measured for serum biomolecules of interest. Autopsy samples of the renal and hepatic tissues were excised for histopathological examinations.

2.6. Liver function test (LFT)

2.6.1. Aspartate aminotransferase (AST) and alanine aminotransferase (ALT) activities

Measurement of serum AST and ALT activities were according to the methods of Reitman and Frankel [48].

2.6.2. Alkaline phosphatase (ALP) activity

Serum ALP activity was assayed by the methods described by Glogowski et al. [49], but with minor modifications according to Njoku et al. [50].

2.6.3. Bilirubin

Serum total bilirubin concentration (TBC) was measured using diazotized sulphanilic acid methods as previously described [51].

2.6.4. Total protein

Serum total protein concentration (TPC) was

measured using the biuret methods as described by Gornall et al. [52].

2.6.5. Albumin

Measurement of serum albumin concentration (AIC) was by the methods described by Doumas et al. [53].

2.7. Kidney function test (KFT)

2.7.1. Creatinine

Measurement of serum creatinine concentration (CrC) was according to the methods as described by Bonsnes and Tausky [54].

2.7.2. Urea

Estimation of serum urea concentration (UrC) was by the rapid methods as described by Fawcett and Scott [55].

2.8. Lipid profiling

2.8.1. Serum lipid profile

Blood samples were obtained from the various experimental animal groups and measured for SLP according to the methods previously described [56]. Serum total cholesterol (TC), triacylglycerol (TAG) and high-density lipoprotein cholesterol (HDL-C) concentrations were measured using commercial kits (Randox Laboratory Ltd., UK). Serum low-density lipoprotein cholesterol (LDL-C) concentration was estimated according to the formula of Friedewald et al. [57]: $LDL-C = TC - (HDL-C) - (TAG/5)$, as reported by Shaker et al. [1]. Atherogenic index (AI) was calculated as previously reported [58].

2.9. Hepatorenal tissue morphology

2.9.1. Histopathological examinations

Organ histology was according to the methods described by Bancroft et al. [59] as previously reported [15, 60]. Autopsy samples of the renal and hepatic tissues of the different animal

groups, fixed in 10% formol saline (pH = 7.2) for 24 h and washed with continuous flow of distilled water. The specimens were cleared in xylene embedded in paraffin in hot air oven at 56 °C for 24 h. Paraffin bees wax tissue blocks were prepared for sectioning at 4-mm thickness using a semi-automated rotatory microtome. The obtained tissue sections were collected on glass slides, dehydrated by immersing in serial dilutions of ethyl alcohol-water mixture, cleaned in xylene and embedded in paraffin wax. Next, the specimens were deparaffinized and stained with hematoxylin and eosin (H&E) dye for histopathological examinations. Photomicrographs of the tissue sections were captured using charge-couple device (CCD) camera under light microscope (Olympus BX51TF; Olympus Corporation, Tokyo, Japan) at $\times 400$ magnification power.

2.10. Statistical analysis

The data collected were analyzed by the analysis of variance procedure while treatment means were separated by the least significance difference (LSD) incorporated in the statistical analysis system (SAS) package of 9.1 version, (2006).

3. RESULTS

Table 1 showed that the concentrations of alkaloids in the four herbal extracts were within the range of $4.83 \pm 0.03 - 31.33 \pm 0.29$ mg/100 g sample, in which Extract R1 gave the highest concentration of alkaloids. The concentration of alkaloids in Extract R2 was approximately 1.9 fold lower than that of Extract R1; $p < 0.05$. Furthermore, the concentration of alkaloids in Extract R3 was 2.36 folds lower than that of Extract R2; $p < 0.05$. The Extract R4 gave the lowest concentration of alkaloids and was not significantly different ($p > 0.05$) from that of Extract R3.

The concentration of alkaloids in Extract H1 was significantly different ($p < 0.05$) from that of Extract H2. Conversely, the concentration of alkaloids in Extract H3 was not significantly different ($p > 0.05$) from that of Extract H4. The concentrations of alkaloids in Extract H3 and Extract H4 were significantly different ($p < 0.05$)

from those of Extract H1 and Extract H2. An overview of Table 1 showed that the concentrations of alkaloids in Extracts (R1-R4) were significantly

higher ($p < 0.05$) than those of Extracts (H1-H4), except the corresponding concentrations of alkaloids between Extract R4 and Extract H4; $p > 0.05$.

Table 1. Some phytochemical contents of raw and hydrothermal processed herbal extracts.

Extract	Concentration (mg/100 g dry sample)			
	Alkaloids	Flavonoids	Tannins	Saponins*
R1	31.33 ± 0.29 ^a	14.17 ± 0.10 ^b	13.28 ± 0.11 ^a	1.67 ± 0.04
R2	16.50 ± 0.10 ^{b,c}	21.00 ± 0.18 ^a	12.63 ± 0.09 ^{a,b}	2.23 ± 0.02
R3	7.00 ± 0.09 ^{d,e}	6.33 ± 0.08 ^{d,e}	7.39 ± 0.07 ^{c,d}	2.33 ± 0.03
R4	4.83 ± 0.03 ^{d,e,f}	6.23 ± 0.07 ^{d,e,f}	8.10 ± 0.12 ^c	2.83 ± 0.03
H1	20.01 ± 0.21 ^b	6.50 ± 0.07 ^d	0.62 ± 0.01 ^e	1.33 ± 0.09
H2	7.33 ± 0.07 ^d	12.33 ± 0.09 ^{b,c}	0.42 ± 0.01 ^{e,f,g,h}	1.00 ± 0.01
H3	1.50 ± 0.01 ^{e,f,g,h}	4.33 ± 0.03 ^{d,e,f,g}	0.46 ± 0.01 ^{e,f,g}	1.67 ± 0.02
H4	2.17 ± 0.03 ^{e,f,g}	3.17 ± 0.03 ^{d,e,f,g,h}	0.52 ± 0.01 ^{e,f}	2.33 ± 0.02

The mean (\bar{X}) ± S.D of six ($n = 6$) determinations. Means in the column with the same letter are not significantly different at $p > 0.05$ according to LSD. *Concentrations of saponins showed no significant difference $p > 0.05$ according to LSD.

Table 1 showed that Extract R2 gave the highest concentration of flavonoids, which was significantly different ($p < 0.05$) from that of Extract R1. The concentrations of flavonoids in Extract R3 and Extract R4 showed no significant difference ($p > 0.05$). In a corresponding manner, the concentration of flavonoids in Extract H2 was significantly higher ($p < 0.05$) than that of Extract H1. Likewise, the concentration of flavonoids in Extract H3 was not significantly different ($p > 0.05$) from that of Extract H4.

An overview of Table 1 showed that the concentrations of flavonoids in Extracts (R1-R4) were significantly higher ($p < 0.05$) than those of Extracts (H1-H4), except the corresponding concentrations of flavonoids in Extract R3 and Extract H3 as well as Extract R4 and Extract H4.

The concentration of tannins in Extract R1 was not significantly different ($p > 0.05$) from that of Extract R2. However, the concentration of tannins in Extract R3 was 1.79 fold lower than that of Extract R1; $p < 0.05$. The Extract R4 gave marginal higher concentration of tannins than that of Extract R3; $p > 0.05$. Table 1 showed that the concentrations of tannins in Extracts (H1-H4) were significantly lower ($p < 0.05$) than their corresponding Extracts (R1-R4). Additionally, the concentra-

tions of tannins in Extracts (H1-H4) was within a relatively narrow range of 0.42±0.01 - 0.62±0.01 mg/100 g dry sample; $p > 0.05$.

The concentrations of saponins in the herbal extracts varied within a relatively narrow range: 0.33±0.09 - 4.33±0.02 mg/100 g dry sample; $p > 0.05$. Although the concentrations of saponins in Extracts (R1-R4) were comparatively higher than those of Extracts (H1-H4), the values showed no corresponding significant difference ($p > 0.05$). Finally, a general survey of Table 1 showed that the concentrations of the phytochemicals analyzed in the raw and hydrothermal processed herbs were in the order: alkaloids > flavonoids > tannins > saponins.

Serum ALT activity of Group 1 was not significantly different ($p > 0.05$) from that of Group 2 (Figure 1). However, Group 3 exhibited comparatively raised level of serum ALT activity, which represented 4.44 folds increase in the enzyme activity compared with that of Group 1; $p < 0.05$. Conversely, serum ALT activities of Groups (4-12) were significantly lower ($p < 0.05$) than that of Group 3, but significantly higher ($p < 0.05$) than those of Group 1 and Group 2. Specifically, serum ALT activities of Group 6, Group 10, Group 11 and Group 12 were significantly higher ($p < 0.05$) than

that of group 4, whereas serum ALT activities of Group 5, Group 7, Group 8 and Group 9 were comparable with that of Group 4; $p > 0.05$. Serum AST activities of the various experimental rat groups followed the same pattern with their serum ALT activities (Figure 1). However, the activity ratios of AST to ALT of the various experimental rat groups were generally less than 1.0 unit.

Serum ALP activity of Group 1 was not significantly different ($p > 0.05$) from that of Group 2 (Figure 1). Serum ALP from Group 3 gave the highest activity, which was significantly different ($p < 0.05$) from other experimental rat groups. Additionally, serum ALP activity of Group 3 was comparable with those of group 5, Group 6 and Group 10 ($p > 0.05$), whereas serum ALP activities of Group 7, Group 8, Group 9, Group 11 and Group 12 were significantly higher ($p < 0.05$) than that of Group 3.

Figure 2 showed that serum TBCs of Group 1 and Group 2 were less than 1.0 mg/ml and showed no significant difference ($p > 0.05$). Contrary, serum TBCs of other experimental groups, except Group 11, were above 1.0 mg/dl. Specifically, Group 3 gave the highest serum TBC, which was signi-

ficantly different ($p < 0.05$) from other experimental rat groups. Furthermore, serum TBC of Group 11 was comparable with those of Group 4, Group 7, Group 9 and Group 12; $p > 0.05$.

Figure 3 showed that serum TPC of Group 1 was not significantly different ($p > 0.05$) from that of Group 2. Additionally, serum TPCs of Group 4, Group 5, Group 6, Group 7 and Group 10 were comparable; $p > 0.05$. Likewise, serum TPCs of Group 11 and Group 12 were comparable with that of Group 2; $p > 0.05$. However, serum TPC of Group 3 was significantly lower than other experimental rat groups; $p < 0.05$. A cursory look at Figure 3 showed that serum AICs of the various experimental rat groups exhibited similar pattern with serum TPCs, exemplified by the fairly strong correlation coefficient ($r = 0.651662$) between their serum TPCs and serum AICs.

Figure 4 showed that serum CrCs and serum UrCs of Group 1 and Group 2 did not show significant difference ($p > 0.05$). Conversely, serum CrC of Group 3 was significantly higher ($p < 0.05$) than those of Group 1 and Group 2. Additionally, serum CrC of Groups (4-12) varied within a narrow range of $0.61 \pm 0.03 - 0.66 \pm 0.05$ mg/dl; $p > 0.05$.

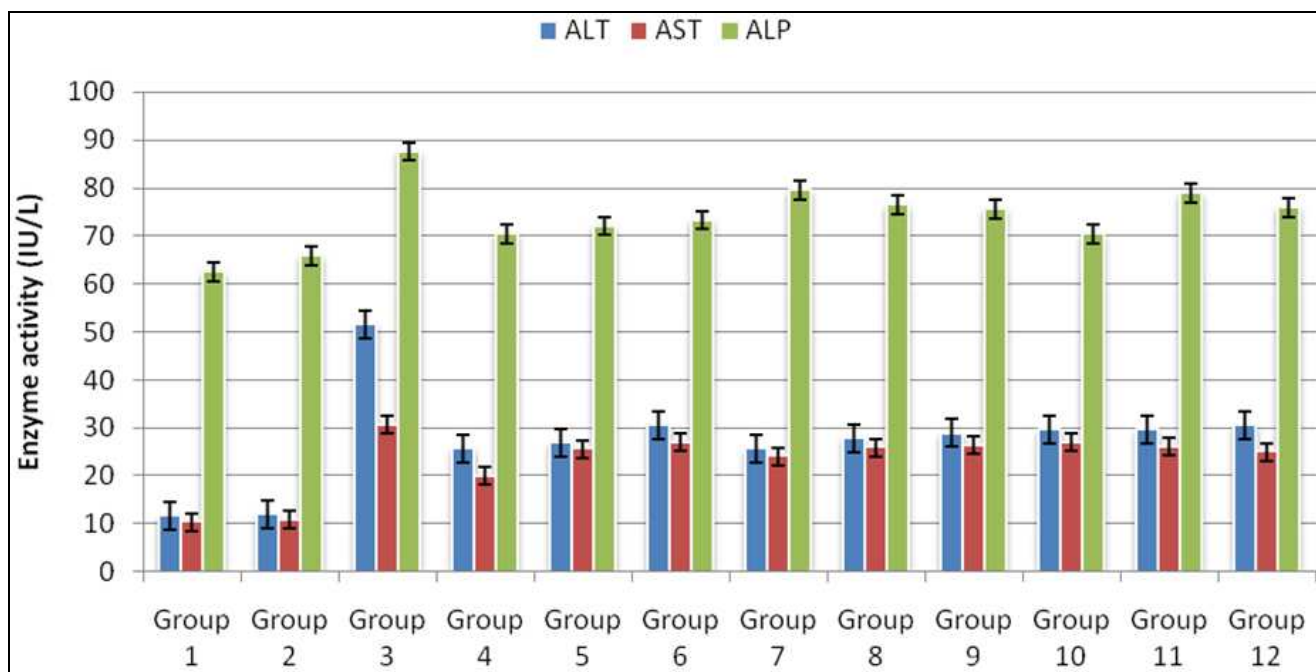


Figure 1. Serum aspartate aminotransferase, alanine aminotransferase and alkaline phosphatase activities of experimental rat groups.

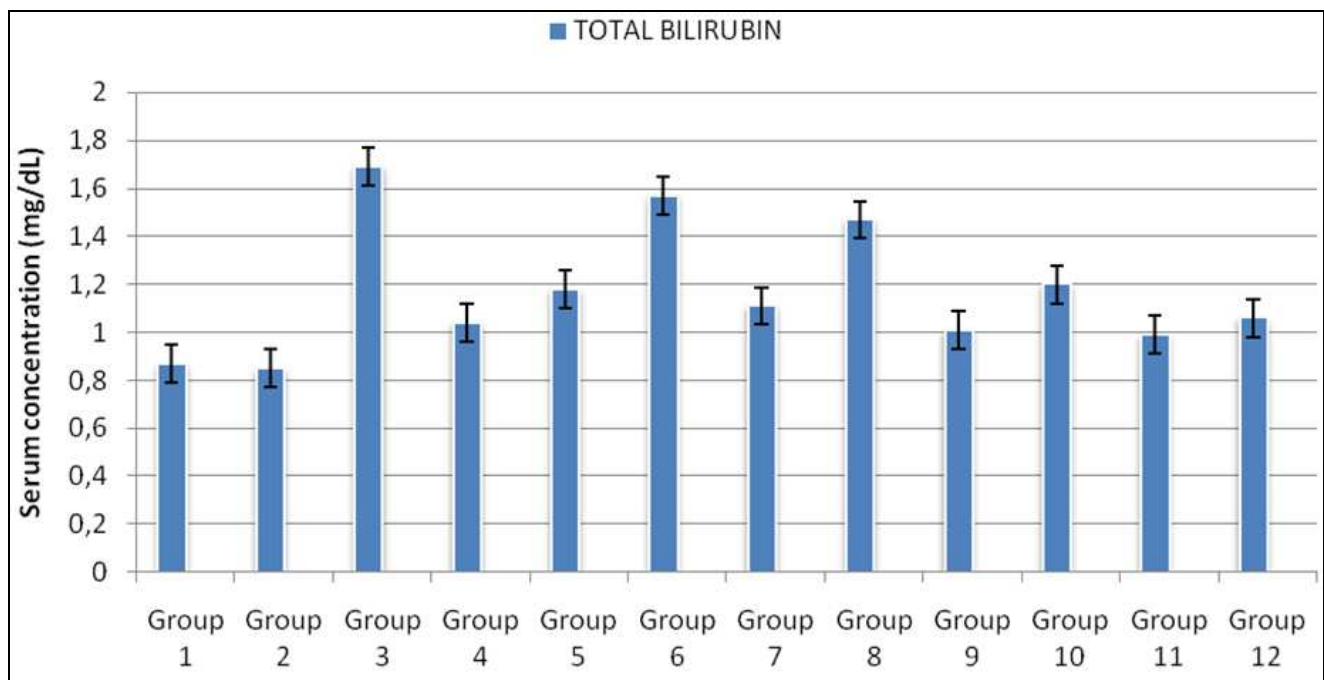


Figure 2. Serum total bilirubin concentration of experimental rat groups.

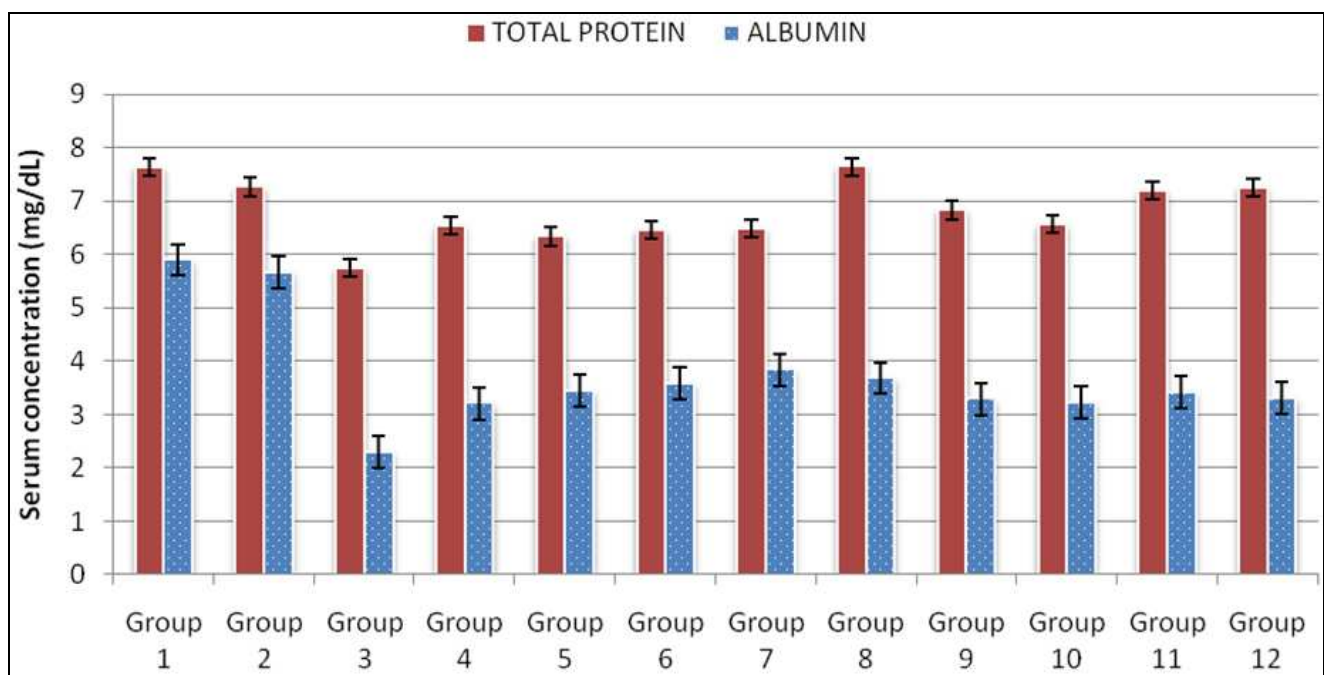


Figure 3. Serum total protein and albumin concentrations of experimental rat groups.

Serum UrC of Group 3 significantly higher ($p < 0.05$) than those of Group 1 and Group 2 as well as other experimental rat groups (5-12). The correlation coefficient ($r = 0.898134$) between serum CrC and serum UrC of the experimental rat groups indicated a strong positive correlation.

Figure 5 showed that SLP of Group 1 exhi-

bited comparable pattern with that of Group 2 as typified by their atherogenic indices (Table 2). Specifically, serum TC, TAG and LDL-C concentrations of Group 3 were significantly raised ($p < 0.05$) compared with Group 1 and Group 2. Conversely, Group 3 exhibited the lowest serum HDL-C concentration compared with other expe-

perimental rat groups. Generally, serum TC, TAG and LDL-C concentrations of Groups (5-12) were higher than that of Group 4, and in turn, those of Group 4 was higher than those of Group 1 and Group 2; $p < 0.05$.

An overview of Table 2 showed that athero-

genic indices of Group 1 and Group 2 were below the critical values, whereas those of Groups (3-12) were within the following ranges: TAG/HDL-C ratio (3.59 ± 0.03 - 6.76 ± 0.06), TC/HDL-C ratio (3.72 ± 0.02 - 6.94 ± 0.05) and LDL-C/HDL-C ratio (2.00 ± 0.01 - 4.59 ± 0.02).

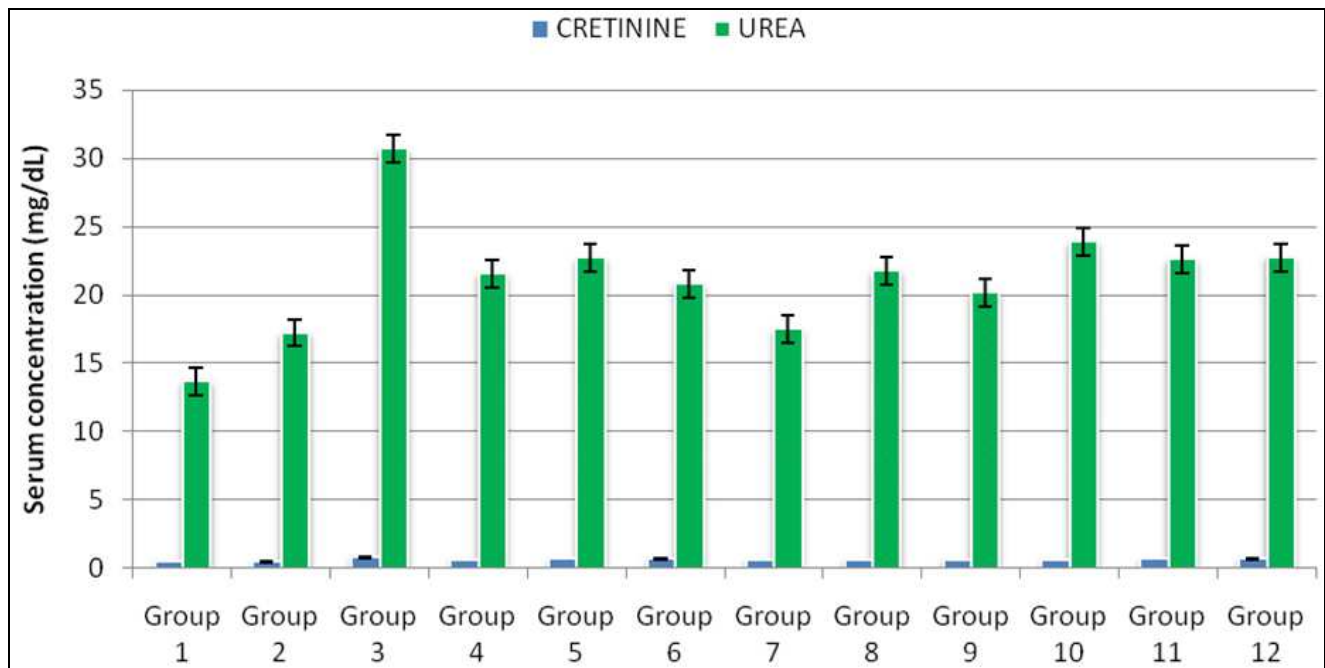


Figure 4. Serum creatinine and urea concentrations of experimental rat groups.

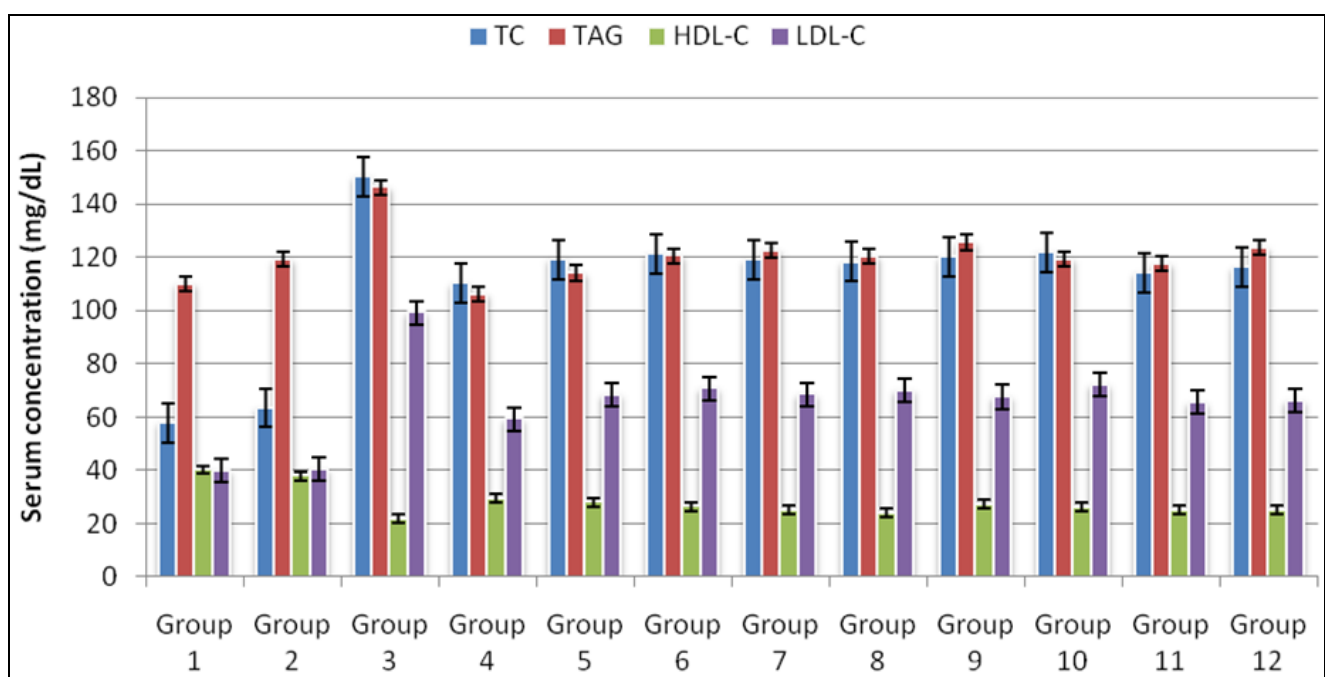
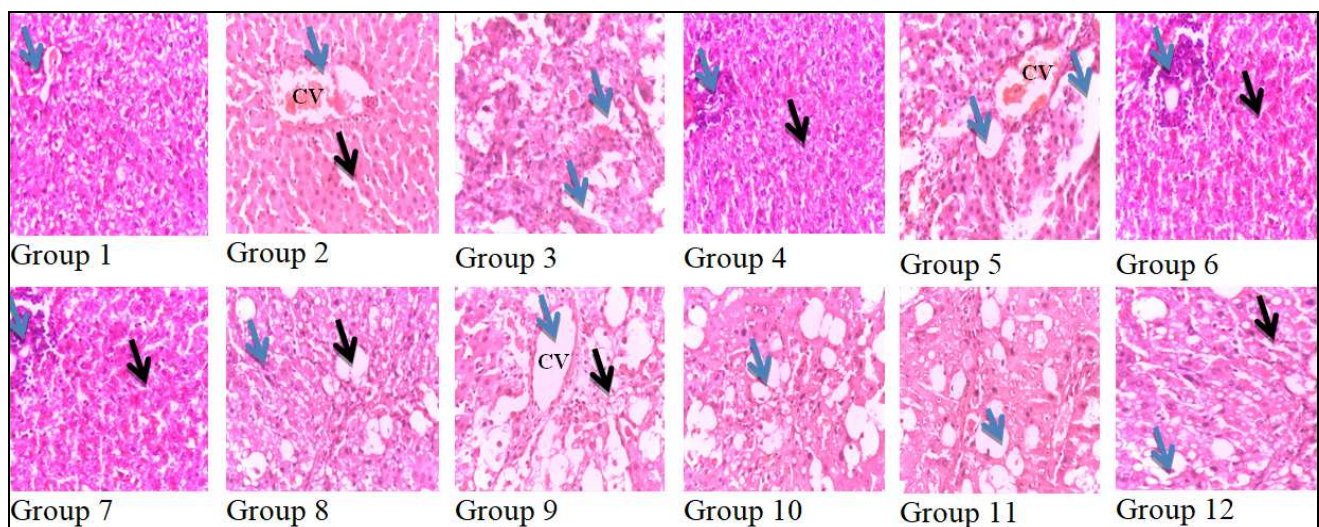


Figure 5. Serum lipid profile of experimental rat groups.

Table 2. Atherogenic indices of experimental rat groups.

Atherogenic indices			
Groups	TAG/HDL-C	TC/HDL-C	LDL-C/HDL-C
Group 1	2.74 ± 0.02	1.44 ± 0.01	0.99 ± 0.001
Group 2	2.99 ± 0.02	1.59 ± 0.01	1.01 ± 0.01
Group 3	6.76 ± 0.06	6.94 ± 0.05	4.59 ± 0.02
Group 4	3.59 ± 0.03	3.72 ± 0.02	2.00 ± 0.01
Group 5	4.07 ± 0.03	4.26 ± 0.02	2.44 ± 0.01
Group 6	4.56 ± 0.03	4.59 ± 0.02	2.68 ± 0.01
Group 7	4.91 ± 0.03	4.76 ± 0.02	2.78 ± 0.02
Group 8	5.40 ± 0.03	4.91 ± 0.02	2.91 ± 0.01
Group 9	4.59 ± 0.03	4.39 ± 0.02	2.47 ± 0.01
Group 10	4.59 ± 0.03	4.69 ± 0.02	2.77 ± 0.02
Group 11	4.69 ± 0.02	4.54 ± 0.02	2.61 ± 0.01
Group 12	4.96 ± 0.02	4.66 ± 0.02	2.65 ± 0.01

The mean (\bar{X}) ± S.D of six ($n = 6$) determinations. Reference values: TAG/HDL-C ratio [61, 62], TC/HDL-C ratio < 1.66 and LDL-C/HDL-C ratio < 1.06 [39]. Castelli risk indices I (TC/HDL-C) and II (LDL-C/HDL-C) [63].

**Figure 6.** Photomicrograph sections of hepatic tissues (H&E x 400).

Group 1: Normal histology showing normal central vein (blue arrow). Group 2: Normal histology showing pronounced normal central vein (CV) (blue arrow) and Kupffer cells along the sinusoids (black arrow). Group 3: Massive tissue necrosis and fibrotic changes of hepatic parenchyma with centrilobular vacuolization and extensive fatty deposits (blue arrows). Group 4: Localized minimal distortion of hepatic parenchyma architecture (blue arrow) with infiltration of mononuclear cells around portal area and adjoining hepatic tissues (black arrows). Group 5: Massive tissue necrosis and fibrotic changes of hepatic parenchyma with extensive fatty deposits (blue arrows). Group 6 and Group 7: Localized minimal distortion of tissue architecture (blue arrow) with massive number of apoptotic hepatocytes (black arrow). Group 8: Fibrotic changes (blue arrow) with fatty deposits (black arrow). Group 9: Fibrotic changes with fatty deposits (black arrow) as well as CV congestion (blue arrow). Group 10: Fibrotic changes with fatty deposits (blue arrow). Group 11: Fibrotic changes of hepatic parenchyma with fatty deposits (blue arrow). Group 12: Fibrotic changes with fatty deposits (blue arrow) with cytoplasmic vacuolization (black arrow).

The histopathological features of hepatic tissue sections of the experimental rat groups are presented in Figure 6. Photomicrograph section of hepatic tissues of Group 1 showed normal histology and was comparable with that of Group 4; except for slight localized distortion in hepatic parenchyma of Group 4. Additionally, hepatic section of Group 2 showed normal histology with minimal cytoplasmic vacuolization. Conversely, hepatic section of Group 3 showed evidence of massive disarrangement and distortions of tissue architecture, accompanied with infiltration of fatty deposits as well as centrilobular necrosis comparable with that of Group 5. Figure 6 showed that hepatic sections of Group 8, Group 9, Group 10, Group 11 and Group 12 showed evidence of fatty deposits and fibrotic changes of hepatic parenchyma. Specifically, hepatic tissues sections of Group 9 and Group 10 were also associated with

cytoplasmic vacuolization.

The histopathological features of renal tissue sections of the experimental rat groups are presented in Figure 7. Photomicrograph section of renal tissues of Group 1 showed normal histology, which was comparable with that of Group 2. The tubular and glomeruli configurations were absent in renal tissues of Group 3, whereas those of Group 4 and Group 5 were present but distorted. Renal tissue section of Group 6 showed evidence of parenchyma necrosis with distorted glomeruli architecture. The degenerated and distorted tubular morphology of renal tissues of Group 7 was comparable with that of Group 11. There were evidence of infiltrated mononuclear cells around the glomeruli (Group 8, Group 9 and Group 11) and dispersed in renal parenchyma (Group 10).

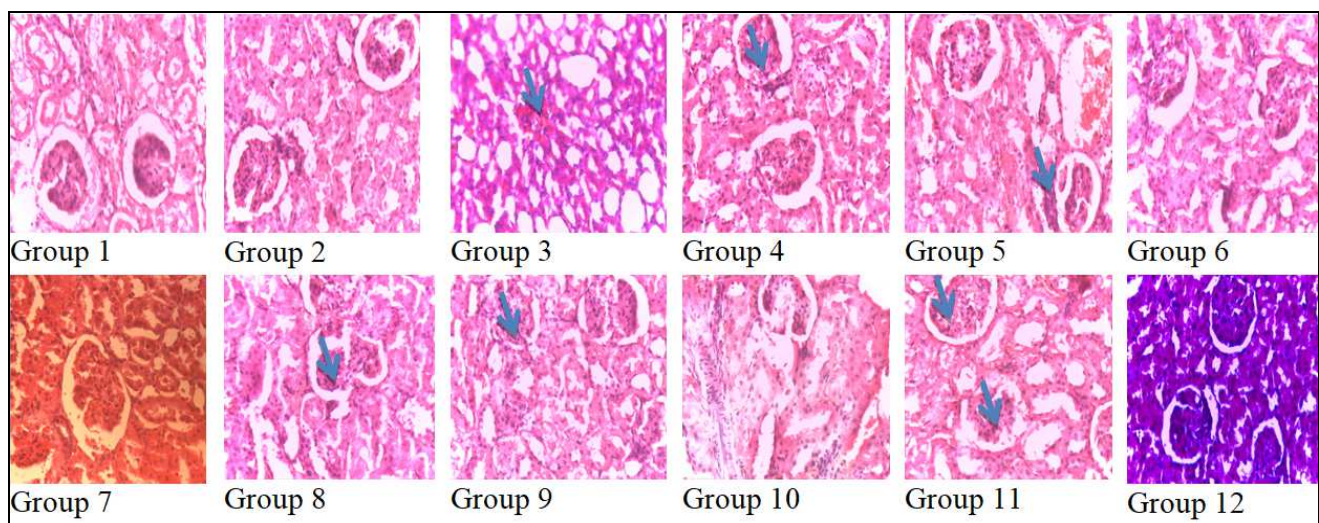


Figure 7. Photomicrograph sections of renal tissues (H&E x 400).

Group 1 and Group 2: Normal histology showing normal tubular and glomeruli architecture. Group 3: Pronounced degenerated and distorted tubular and glomeruli architecture as well as evidence of distorted renal parenchyma integrity (blue arrow). Group 4 and Group 5: Minor distorted glomeruli architecture and infiltrated mononuclear cells around the glomeruli (blue arrow). Group 6: Distorted tubular and glomeruli architecture as well as necrosis of renal parenchyma. Group 7: Minor distorted glomeruli architecture but degenerated and distorted tubular morphology. Group 8 and Group 9: Major distorted glomeruli architecture and infiltration of mononuclear cells around the glomeruli (blue arrow). Group 10: Dispersed mononuclear cells around the glomeruli and renal parenchyma. Group 11: Minor distorted glomeruli architecture and infiltrated mononuclear cells around the glomeruli (blue arrows). Group 12: Normal glomeruli architecture but degenerated and distorted tubular morphology.

4. DISCUSSION

Hydrothermal processing of herbs brings about changes in their physical characteristics and biochemical compositions [64, 65]. Expectedly, the present study showed evidence of losses in phytochemical contents following hydrothermal processing of the herbal samples. Most of these phytochemicals have been demonstrated to possess antioxidant properties using both *in vitro* and *in vivo* evaluation models [1, 9, 66-68]. However, the effects of hydrothermal processing on the antioxidant contents and activities of herbs are still controversially discussed [69-71]. Antioxidant phytochemicals function by modulation of nuclear factor- κ B (NF- κ B), p38 mitogen-activated protein kinase (MAPK), NH₂-terminal Jun kinases/stress-activated protein kinases (JNK/SAPK) and hexosamines mediated cellular stress-sensitive pathways [72-76] as well as transforming growth factor- β (TGF- β)-Smad3 signaling pathway [77]. Previous reports had associated the loss in phytochemical content of hydrothermal processed herbs to leaching and low thermal stability of most phytochemicals [78]. For instance, hydrothermal processing of broccoli, choy-sumand cabbage resulted to losses in their total phenolic contents [79]. Additionally, cooking methods and storage temperature of raw vegetables influenced their phytochemical contents and antioxidant capacities *in vitro* [64, 66]. Specifically, report showed that hydrothermal processing caused 19% loss in the phytochemical contents of cauliflower [80]. It is worthwhile to note that losses in phytochemical contents following hydrothermal processing of herbs may compromise their radical scavenging potential and the capacities of such products to exert health benefits [66, 81]. Nevertheless, hydrothermal processing serves as one of several measures for the elimination of inherent cytotoxic phytochemicals from raw medicinal herbs and vegetables [82-85].

Measurements of hepatic enzymes in serum of animal models have been used in previous studies as basis for ascertaining the capacities of herbal remedies to ameliorate chemically induced liver damage [8, 9, 86-88]. Elevated levels of serum AST, ALT and ALP activities are diagnostic of fibrotic changes of the liver, myocardial infarction, bone disorders and other related pathologic conditions

associated with organ necrosis [89]. Serum ALT activity is more specific for hepatic injury than an increase in serum AST activity and may reflect fatty changes in the liver as in the case of non-alcoholic fatty liver disease (NAFLD) [90-93]. Specifically, the raised level of serum ALT activity of Group 3 (Figure 1) was obvious indication of fibrotic changes of hepatic tissues of the experimental rats as corroborated in previous findings [12, 13, 94]. However, fibrotic rats treated with raw and hydrothermal processed herbs showed evidence of amelioration of CCl₄-induced liver injury as indicated by their comparatively lower serum ALT activities, which concurred with previous findings [13, 77, 94, 95]. The present findings showed that the capacities of the raw and hydrothermal processed herbs to reverse elevated levels of serum AST and ALT activities were comparable with that of silymarin, which was used as reference treatment of fibrotic rats. Furthermore, it appeared that the raw herbs exhibited greater capacities to lower serum ALT activities of fibrotic rats than those of corresponding hydrothermal processed herbs, which was an indication of greater capacities of the raw herbs to ameliorate CCl₄-induced liver injury than those of corresponding hydrothermal processed herbs. Likewise raised level of serum ALP activity of Group 3 was a reflection of hepatobiliary disorder and fibrosis [87], which paralleled the patterns of serum AST and ALT activities of other experimental rat groups and conformed with the outcome of related investigations [1, 12, 13, 45, 96]. Overall, serum AST, ALT and ALP activities of fibrotic rats treated with raw and hydrothermal processed herbs as well as the standard herbal drug-silymarin were profoundly higher those of normal rat groups (Group 1 and Group 2), which by implication showed that the various herbal remedies did not possess the capacities to offer full therapeutic benefits within the experimental 28 days of treatment.

The factors that elicit raised level of bilirubin in serum are multifaceted and serum bilirubin concentration greater than 1.0 mg/dl is diagnostic of hyperbilirubinemia [97, 98]. Hyperbilirubinemia occurs due to rapid haemolysis such that the production of bilirubin far exceeds the capacity of normal hepatocytes to conjugate and excrete bilirubin. In the event of hepatic damage, the capacities of the hepatocytes to conjugate and excrete bilirubin

are compromised, even when bilirubin is produced in normal quantities. Furthermore, hepatobiliary obstruction prevents the excretion of bilirubin engendering the accumulation of bilirubin in the liver, which eventually diffuses into the blood system.

Previous studies have noted that reactive $\text{CCl}_3^{\cdot-}$ and $\text{Cl}_3\text{COO}^{\cdot-}$ radicals generated from CCl_4 metabolism promoted membrane lipid peroxidation, in which the erythrocytes [99] and hepatorenal tissues were vulnerable [1, 9, 11-14] and consequently, prompted rapid haemolysis and hepatic necrosis with attendant hyperbilirubinemia in the experimental rats (Groups 3-12). The results of the present study (Figure 2) indicated that fibrotic rats, regardless of the type of herbal treatment administered, presented evidence of hyperbilirubinemia. However, the hydrothermal processed herbs appeared to exhibit relatively higher tendencies to lower the severity of hyperbilirubinemia than those of corresponding raw herbs. In that regard, the results appeared to suggest that hydrothermal processing of the herbs caused the elimination or reduction in the amount of cytotoxic components in the herbs that probably interfered with the capacity of the herbs to ameliorate hyperbilirubinemia.

The plasma proteins (e.g. albumin) are synthesized by the liver and therefore low circulating level of plasma proteins indicates hepatic dysfunction. Previous studies have shown that mild perturbation of hepatic tissues integrity did not profoundly affect the capacity of the liver to biosynthesize plasma proteins [58, 100]. The present study showed that serum total protein and albumin concentrations of Group 3 were lower than those of Group 1 and Group 2 (Figure 3), which confirmed compromised hepatic function. However, the administration of raw and hydrothermal processed herbs caused limited improvement in the capacity of hepatocytes of fibrotic rats to biosynthesize plasma proteins.

The renal tissues are primarily concerned with the clearance of nitrogenous waste products and other blood low threshold substances. Creatinine is mainly the catabolic waste product from tissue protein turnover, whereas urea is derived from oxidative deamination of dietary amino acids [1, 101, 102]. Elevated blood creatinine and urea concentrations are diagnostic of impaired renal

function. The present study showed evidence of renal dysfunction following infusion of the experimental rats with CCl_4 , exemplified by comparatively raised serum creatinine and urea concentrations of Group 3 (Figure 4). The present findings confirmed previous research outcomes, which noted that acute chemical intoxication that caused morphological and functional damages to hepatic tissues predisposed animal models to developing acute renal dysfunction [1, 5, 6, 8, 9]. Fibrotic rats treated with raw and hydrothermal processed herbs showed evidence of limited amelioration of impaired renal function, typified by their lowered serum creatinine and urea concentrations compared to that of Group 3. In a related study, Elgazar and AboRaya [103], using serum urea and creatinine concentrations as biomarkers, noted that single and combinatorial formulations of *Petroselinum sativum*, *Eruca sativa* and *Curcuma longa* ameliorated gentamicin-induced renal tubular necrosis in adult male Sprague Dawley rats.

The metabolic concerns of the liver, amongst other functions, are to regulate the mobilization, biosynthesis and catabolism of lipoproteins in vertebrates. Previous reports showed that CCl_4 interferes with the metabolism of lipoproteins in hepatic smooth endoplasmic reticulum, engendering alterations in SLP patterns and associated dyslipidemia [12, 104, 105], whereby blood lipid concentrations are elevated as typified by raised levels of serum LDL-C and TC of Group 3 compared to that of Group 1 (Figure 5). Additionally, the SLP patterns of fibrotic rats administered with raw and hydrothermal processed herbs were identical and therapeutic scores of the herbs were not profoundly different from that of the standard herbal drug - silymarin. Overall, the present study showed that the herbs did not offer full therapeutic benefits to the fibrotic rats, in terms of their capacities to ameliorate dyslipidemia. The predisposition of the experimental rat groups to arteriosclerosis and associated cardiovascular morbidity and mortality were defined by their atherogenic indices (Table 2). According to the TAG/HDL-C and LDL-C/HDL-C ratios of the present study, adjustments of SLP patterns in the fibrotic rats, irrespective of the type of herbal treatment they received, indicated incidences of atherogenicity as defined elsewhere [39, 58, 61-63].

The massive disarrangement of hepatic tissues architecture of untreated fibrotic rats (Group 3) correlated with the levels of alterations of serum indicators, namely, serum ALT, AST and ALP activities as well as serum TBC as previously described [12, 13, 98, 99]. Additionally, photomicrograph section of hepatic tissues of fibrotic rats (Figure 6) revealed and confirmed CCl₄-induced necrosis and steatosis as previously described [12, 13, 88, 106]. The localized distortions in hepatic architecture, persistence of hepatic steatosis and hydropic degenerations in fibrotic rats following treatment with raw and hydrothermal processed herbs were indications, which confirmed limited capacities of the herbs to ameliorate CCl₄-induced morphological and functional impairments of hepatic tissues within the experimental period of 28 days. According to Sokol et al. [107], manifestation of hepatic steatosis was as a result of low availability of tissue α -tocopherol and ascorbic acid, rather than glutathione (GSH), which also predisposed the liver to oxidative injuries as exemplified by the presence of hepatic necrosis in tissue sections of the present report.

Rincón et al. [5] suggested that the effect of CCl₄ on kidney tissue morphology and function depended on the functional state of the liver. Similar to the histopathological status of the liver, photomicrograph sections of renal tissues (Figure 7) showed that the distortions in renal tissue architecture correlated with the levels of alterations in their blood indicators; serum creatinine and urea concentrations as previously described [60]. Furthermore, the tissue architecture of fibrotic rats administered with raw and hydrothermal processed herbs confirmed the limited capacities of the herbs to ameliorate renal dysfunction within the experimental period of 28 days.

5. CONCLUSION

The losses in phytochemical contents following hydrothermal processing of the herbs did not substantially affect their overall therapeutic scores against morphological and functional impairments of hepatic and renal tissues following CCl₄ intoxication of the experimental rats. However, herbal intervention against CCl₄-induced hyperbilirubinemia showed that hydrothermal processed

herbs possessed greater capacity to lower the severity of hyperbilirubinemia than their corresponding raw herbs. Nevertheless, a more rewarding bio-prospecting exercise for the alleviation of CCl₄-induced hepatorenal impairment could be achieved by subjecting the herbs to sequential multi-solvent extraction process, which perhaps, will provide improved and better therapeutic benefits than the present outcomes.

ACKNOWLEDGEMENT

The authors are grateful for the technical assistance offered by Dr. E.S. Willie of the Department of Agronomy, Michael Okpara University of Agriculture, Umudike, Abia State, Nigeria.

AUTHORS' CONTRIBUTIONS

OAO: conceptualized and supervised the study, edited the manuscript. PCC: wrote the manuscript and analyzed the experimental data. DIU: performed the experiments and analyzed the experimental data. COI: supervised the study, edited the manuscript. RNN: supervised the study, edited the manuscript. The final manuscript has been read and approved by all authors.

TRANSPARENCY DECLARATION

The authors declare that there is no conflict of interest regarding the publication of this article.

REFERENCES

1. Shaker E, Mahmoud H, Mnaa S. Silymarin, the antioxidant component and *Silybum marianum* extracts prevent liver damage. *Food Chem Toxicol.* 2010; 48: 803-806.
2. Chikezie PC, Uwakwe AA. Protective effect of *Allium sativa* extract against carbon tetrachloride-induced hepatic oxidative stress and hyperlipidemia in rats. *Afr J Biotechnol.* 2014; 13: 1671-1678.
3. Katzung BG. Basic and clinical pharmacology. Appleton and Lange. 7th edn, Stamford CT. 1998: 372-375.
4. Manahan S. Toxicological chemistry and biochemistry. 3rd edn, CRC Press, Boca Raton, FL., USA. 2003.

5. Rincón AR, Covarrubias A, Pedraza-Chaverrí J, Poo JL, Armendáriz-Borunda J, Panduro A. Differential effect of CCl₄ on renal function in cirrhotic and non-cirrhotic rats. *Exp Toxicol Pathol.* 1999; 51: 199-205.
6. Jaramillo-Juárez F, Rodríguez-Vázquez ML, Rincón-Sánchez AR, Martínez MC, Ortiz GG, Llamas J. Acute renal failure induced by carbon tetrachloride in rats with hepatic cirrhosis. *Ann Hepatol.* 2008; 7: 331-338.
7. Slack A, Yeoman A, Wendon J. Renal dysfunction in chronic liver disease. *Crit Care.* 2010; 14: 214.
8. Alqasoumi S. Carbon tetrachloride-induced hepatotoxicity: protective effect of 'Rocket' *Eruca sativa* L. in rats. *Am J Chinese Med.* 2010; 38: 75-88.
9. Khan RA, Khan MR, Sahreen S. Protective effect of *Sonchus asper* extracts against experimentally induced lung injuries in rats: a novel study. *Exp Toxicol Pathol.* 2012; 64: 725-731.
10. Ruprah H, Mant TGK, Flanagan RJ. Acute carbon tetrachloride poisoning in 19 patients: implications for diagnosis and treatment. *Lancet.* 1985; 1: 1027-1029.
11. Adewole SO, Salako AA, Doherty OW, Naicker T. Effect of melatonin on carbon tetrachloride-induced kidney injury in Wistar rats. *Afr J Biomed Res.* 2007; 10: 153-164.
12. Althnaian T, Albokhadaim I, El-Bahr SM. Biochemical and histopathological study in rats intoxicated with carbon tetrachloride and treated with camel milk. *Spring Open J Res.* 2013; 2: 57.
13. Gonçalves RV, da Matta SLP, Novaes RD, Leite JPV, Peluzio MCG, Vilela EF. Bark extract of *Bathys acuspidata* in the treatment of liver injury induced by carbon tetrachloride in rats. *Braz Arch Biol Technol.* 2014; 57: 504-513.
14. Saile B, Ramadori G. Inflammation, damage repair and liver fibrosis-role of cytokines and different cell types. *Zeitschr Gastroenterol.* 2007; 45: 77-86.
15. Ojiako AO, Chikezie PC, Ogbuji CA. Histopathological studies of renal and hepatic tissues of hyperglycemic rats administered with traditional herbal formulations. *Int J Green Pharm.* 2015; 9: 184-191.
16. Mensah J, Okoli R, Ohaju-Obodo J, Eifediyi K. Phytochemical, nutritional and medical properties of some leafy vegetables consumed by Edo people of Nigeria. *Afr J Biotechnol.* 2008; 7: 2304-2309.
17. Chikezie PC, Ojiako AO, Nwufu KC. Overview of anti-diabetic medicinal plants: The Nigerian research experience. *J Diabetes Metab.* 2015; 6: 546.
18. Middleton E, Kandaswami C, Theohardes TC. The effects of plant flavonoids on mammalian cells, implication for inflammation, heart disease and cancer. *Pharmacol Rev.* 2000; 52: 673-751.
19. Okafor JC. Development of forest tree crops for food supply in Nigeria. *Forest Ecol Manage.* 1987; 1: 235-247.
20. Udeala OK. Preliminary evaluation of dike fat a new tablet lubricant. *J Pharm Pharmacol.* 2000; 32: 6-9.
21. Iwu MM. Evaluation of the anti-hepatotoxic activity of the bioflavonoids of *Garcinia kola* seeds. *J Ethnopharmacol.* 2002; 21: 14-19.
22. Akinwunmi KF, Oyedapo OO. Evaluation of antioxidant potentials of *Monodora myristica* (Gaertn) dunel seeds. *Afr J Food Sci.* 2013; 7: 317-324.
23. Alisi CS, Nwogu LA, Ibegbulem CO, Ujowundu CU. Antimicrobial action of methanol extract of *Chromolaena odorata* Linn. is logistic and exerted by inhibition of dehydrogenase enzymes. *J Res Biol.* 2011; 3: 209-16.
24. Anyasor GN, Aina DA, Olushola M, Aniyikaye AF. Phytochemical constituent, proximate analysis, antioxidant, antibacterial and wound healing properties of leaf extracts of *Chromolaena odorata*. *Ann Biol Res.* 2011; 2: 441.
25. Chakraborty JB, Oakley F, Walsh MJ. *Chromolaena odorata* L: an overview. *J Pharm Res.* 2011; 4: 573.
26. Pandith H, Zhang X, Liggert J, Min K, Gritsanapant W, Baek SJ. Hemostatic and wound healing properties of *Chromolaena odorata* leaf extract. *ISRN Dermatol.* 2013; 2013: 168269.
27. Nwaeujor CO, Ode OJ, Nwinyi FC, Udeh NE. Effect of methanol extract of *Buchholzia coriacea* fruits on streptozotocin-induced diabetic rats. *J Pharmacol Toxicol.* 2012; 7: 181-191.
28. Amaechi NC. Nutritive and anti-nutritive evaluation of wonderful kola (*Buchholzia coriacea*) seeds. *Pak J Nutr.* 2009; 8: 1120-1122.
29. Mbata TI, Duru CM, Onwumelu HA. Antibacterial activity of crude seed extracts of *Buchholzia coriacea* E. on some pathogenic bacteria. *J Dev Biol Tissue Eng.* 2009; 1: 1-5.
30. Adisa RA, Choudhary MI, Olorunsogo OO. Hypoglycemic activity of *Buchholzia coriacea* (Capparaceae) seed in streptozotocin-induced diabetic rats and mice. *Exp Toxicol Pathol.* 2011; 63: 619-625.

31. Ibrahim TA, Fagboun ED. Phytochemical and nutritive quality of dried seed of *Buchholzia coricea*. Greener J Phys Sci. 2013; 2: 185-1891.
32. Ajibola C, Fashakin JB, Fagbemi TN, Aluko RE. Effect of peptide size on antioxidant properties of African yam bean seed (*Sphenostylis stenocarpa*) protein hydrolysate fractions. Int J Mol Sci. 2011; 12: 6685-6702.
33. Okonkwo CC, Njoku OU, Ikevude CT, Odo CE. Hepatoprotective effect of methanol extract of *Sphenostylis stenocarpa* (Hoschst ex. A. Rich. Harms) against carbon tetrachloride-induced liver toxicity in Wistar rats. J Pharm Res. 2013; 6: 293-298.
34. Ndidi US, Ndidi CU, Olagunju A, Muhammad A, Billy FG, Okpe O. Proximate, anti-nutrition, and mineral composition of raw and processed (boiled and roasted) *Sphenostylis stenocarpa* seeds from Southern Kaduna, Northwest Nigeria. ISRN Nutr. 2014; 2014: 280837.
35. Hwang YP, Choi JH, Jeong HG. Protective effect of the *Aralia continentalis* root extract against carbon tetrachloride-induced hepatotoxicity in mice. Food Chem Toxicol. 2009; 47: 75-81.
36. Karakus E, Karadeniz A, Simsek N. Protective effect of *Panax ginseng* against serum biochemical changes and apoptosis in liver of rats treated with carbon tetrachloride (CCl₄). J Hazard Mater. 2011; 195: 208-213.
37. Wolf P. Biochemical diagnosis of liver diseases. Int J Clin Biochem. 1999; 14: 59-90.
38. Ramcharran D, Wahed AS, Conjeevaram HS, Evans RW, Wang T, Belle SH, et al. Serum lipids and their associations with viral levels and liver disease severity in a treatment-naïve chronic hepatitis C type 1-infected cohort. J Viral Hepat. 2011; 18: 144-152.
39. Ibegbulem CO, Chikezie PC. Serum lipid profile of rats (*Rattus norvegicus*) fed with palm oil and palm kernel oil-containing diets. Asian J Biochem. 2012; 7: 46-53.
40. Wojcikowski K, Stevenson L, Leach D, Wohlmuth H, Gobe G. Antioxidant capacity of 55 medicinal herbs traditionally used to treat the urinary system: a comparison using a sequential three-solvent extraction process. J Altern Compl Med. 2007; 13: 103-109.
41. Harborne JB. Phytochemical methods: a guide to modern techniques of plant analysis. 1st edn, London, Chapman and Hall Ltd. 1973.
42. Boham AB, Kocipal AC. Flavonoid and condensed tannins from leaves of Hawaiian vaccinium, vaticulum and vicalycinium. Pac Sci. 1994; 48: 458-463.
43. Van-Burden TP, Robinson WC. Formation of complex between protein and tannic acid. J Agric Food Chem 1981; 1:77-82.
44. Belonwu DC, Ibegbulem CO, Nwokocha MN, Chikezie PC. Some phytochemicals and hydrophilic vitamins of *Anacardium occidentale*. Res J Phytochem. 2014; 8: 78-91.
45. Khan AA, Alzohairy M. Hepatoprotective effects of camel milk against CCl₄-induced hepatotoxicity in rats. Asian J Biochem. 2011; 6: 171-181.
46. Ibegbulem CO, Chikezie PC. Hypoglycemic properties of ethanolic extracts of *Gongronema latifolium*, *Aloe perryi*, *Viscum album* and *Allium sativum* administered to alloxan-induced diabetic albino rats (*Rattus norvegicus*). Pharmacogn Commun. 2013; 3: 12-16.
47. Hoff N. Methods of blood collection in the mouse. Lab Anim. 2000; 29: 47-53.
48. Reitman S, Frankel S. Colorimetric method for the determination of serum glutamic oxaloacetic and glutamic pyruvic transaminase. Am Clin Pathol. 1957; 28: 56-63.
49. Glogowski J, Danforth DR, Ciereszko A. Inhibition of alkaline phosphatase activity of boar semen by pentoxifylline, caffeine, and theophylline. J Androl. 2002; 23: 783-792.
50. Njoku VO, Chikezie PC, Kaoje AM. Kinetic studies of alkaline phosphatase extracted from rabbit (*Lepus townsendii*) liver. Afr J Biotechnol. 2011; 10: 3157-3162.
51. Pearlman FC, Lee RT. Detection and measurement of total bilirubin in serum, with use of surfactants as solubilizing agents. Clin Chem 1974; 20: 447-453.
52. Gornall AG, Bardawill CJ, David MM. Determination of serum protein by means of the biuret reaction. J Biol Chem. 1949; 177: 751-766.
53. Dumas BT, Watson WA, Biggs HG. Albumin standards and the measurement of serum albumin with bromocresol green. Clin Chim Acta. 1971; 31: 87-96.
54. Bonsnes RW, Taussky HH. On the colorimetric determination of creatinine by the Jaffe reaction. J Biol Chem. 1945; 158: 581-591.
55. Fawcett JK, Scott JE, A rapid and precise method for the determination of urea. J Clin Pathol. 1960; 13: 156-159.
56. Ojiako AO, Chikezie PC, Zedech UC. Serum lipid profile of hyperlipidemic rabbits (*Lepus townsendii*) administered with leaf extracts of *Hibiscus*

- rosesinesis*, *Emilia coccinea*, *Acanthus montanus* and *Asystasia gangetica*. J Med Plant Res. 2013; 7: 3226-3231.
57. Friedewald W, Levy R, Fredrickson D. Estimation of concentration of low-density lipoprotein in plasma, without use of the preparative ultracentrifuge. Clin Chem. 1972; 18: 499-502.
 58. Ibegbulem CO, Chikezie PC. Levels of acute blood indices disarrangement and organ weights of Wistar rats fed with flavour enhancer- and contraceptive-containing diets. J Invest Biochem. 2016; 5: 1-9.
 59. Bancroft JD, Stevens A, Turner DR. Theory and practice of histological techniques. 4th edn, Churchill Livingstone, New York, London, San Francisco, Tokyo, 1996.
 60. Ibegbulem CO, Chikezie PC, Dike EC. Pathological research and acute hepatic and renal tissue damage in Wistar rats induced by cocoa. J Acute Dis. 2016; 5: 51-58.
 61. Gaziano JM, Hennekens CH, O'Donnell CJ, Breslow JL, Buring JE. Fasting triglycerides, high-density lipoprotein, and risk of myocardial infarction. Circ. 1997; 96: 2520-2525.
 62. Bittner V, Johnson D, Zineh I, Rogers WJ, Vido D, Marroquin OC, et al. The triglyceride/high-density lipoprotein cholesterol ratio predicts all-cause mortality in women with suspected myocardial ischemia: A report from the Women's Ischemia Syndrome Evaluation (WISE). Am Heart J. 2009; 157: 548-555.
 63. Asare GA, Santa S, Ngala RA, Asiedu B, Afriyie D, Amoah AGB. Effect of hormonal contraceptives on lipid profile and the risk indices for cardiovascular disease in a Ghanaian community. Int J Women Health. 2014; 6: 597-603.
 64. Pellegrini N, Chiawato E, Gardama C, Mazzeo T, Continto D, Gallo M, et al. Effect of different cooking methods in color, phytochemical concentration and antioxidant capacity of raw and frozen *Brassica* vegetables. J Agric Food Chem. 2010; 58: 4310-4321.
 65. Adefegha SA, Oboh GO. Cooking enhances the antioxidant properties of some tropical leafy vegetables. Afr J Biotechnol. 2011; 10: 632-639.
 66. Kaur P, Bains K, Kaur H. Effect of hydrothermal treatment on free radical scavenging potential of selected green vegetables. Indian J Nat Prod Resour. 2012; 3: 563-369.
 67. Saeed N, Khan M, Shabbir M. Antioxidant activity, total phenolic and total flavonoid contents of whole plant extracts *Torilis leptophylla* L. BMC Compl Altern Med. 2012; 12: 221.
 68. Ojiako AO, Chikezie PC, Ogbuji CA. Radical scavenging potentials of single and combinatorial herbal formulations *in vitro*. J Tradit Compl Med. 2016; 6: 153-159.
 69. Zhang D, Hamauzu Y. Phenolics, ascorbic acid, carotenoids and antioxidant activity of broccoli and their changes during conventional and microwave cooking. Food Chem. 2004; 88: 503-509.
 70. Turkman N, Sari F, Velioglu YS. The effect of cooking methods on total phenolics and antioxidant activity of selected green vegetables. Food Chem. 2005; 93: 713-718.
 71. Thi ND, Hwang E-S. Effects of drying methods on contents of bioactive compounds and antioxidant activities of black chokeberries (*Aronia melanocarpa*). Food Sci Technol. 2016; 25: 55-61.
 72. Mate's JM. Effects of antioxidant enzymes in the molecular control of reactive oxygen species toxicology. Toxicol. 2000; 153: 83-104.
 73. Evans JL, Goldfine ID, Maddux BA, Grodsky GM. Oxidative stress and stress activated signaling pathways: a unifying hypothesis of Type 2 diabetes. Endocrinol Rev. 2002; 23: 599-622.
 74. Hye-Lin H, Hye-Jun S, Mark AF, Dae-Yeul Y. Oxidative stress and antioxidants in hepatic pathogenesis. World J Gastroenterol. 2010; 16: 6035-6043.
 75. Rodríguez-Ramiro I, Ramos S, López-Oliva E, Agis-Torres A, Bravo L, et al. Cocoa polyphenols prevent inflammation in the colon of azoxymethane-treated rats and in TNF- α -stimulated Caco-2 cells. Br J Nutr. 2012; 28: 1-10.
 76. Ranneh Y, Ali F, Esa NM. The protective effect of cocoa (*Theobroma cacao* L.) in colon cancer. J Nutr Food Sci. 2013; 3: 193.
 77. Huang Q, Zhang S, Zhang L, He M, Huang R, Lin X. Hepatoprotective effects of total saponins isolated from *Turaphochlamys affinis* against carbon tetrachloride-induced liver injury in rats. Food Chem Toxicol. 2012; 50: 713-718.
 78. Rungapamestry V, Duncan AJ, Fuller Z, Ratcliffe B. Effect of cooking *Brassica* vegetables on the subsequent hydrolysis and metabolic fate of glucosinolates. Proc Nutr Soc. 2007; 66: 69-81.
 79. Watchtel-Galor S, Wong KW, Benzie IFF. The effect of cooking on *Brassica* vegetable. Food Chem. 2008; 110: 706-710.
 80. Volden J, Borge GIA, Hansen M, Wicklund T, Bengtsson GB. Processing (blanching, boiling,

- steaming) effects on the content of glucosinolates and antioxidant-related parameters in cauliflower (*Brassica oleracea* L. ssp. *botrytis*). *LWT Food Sci Technol.* 2009; 42: 63-73.
81. Song A-S, Lim S-W, Kim S-J, Lee S-C. Effect of hydrothermal treatment on the antioxidant activity of *Sambakcho* (*Saururus chinensis*) leaves. *Food Sci Biotechnol.* 2013; 22: 825-829.
 82. Fagbemi TN, Oshodi AA, Ipinmoroti KO. Processing effects on some anti-nutritional factors and *in vitro* multi-enzyme protein digestibility (ivpd) of three tropical seeds, bread nut (*Artocarpus altilis*), cashew nut (*Anacardium occidentale*) and fluted pumpkin (*Telfairia occidentalis*). *Pak J Nutr.* 2005; 4: 250-256.
 83. Hefnawy TH. Effect of processing methods on nutritional composition and anti-nutritional factors in lentils (*Lens culinaris*). *Ann Agric Sci.* 2011; 56: 57-61.
 84. Chu C, Ho K, Hu A, Chiu C, Wu H, Ye S, et al. Toxicity attenuation of Atractyloside in traditional Chinese medicinal herbs after hydrothermal processing. *Bot Stud.* 2012; 53: 459-465.
 85. Chen F, Xiong H, Wang J, Ding X, Shu G, Mei Z. Antidiabetic effect of total flavonoids from *Sanguis draxonis* in Type 2 diabetic rats. *J Ethnopharmacol.* 2013; 149: 729-736.
 86. Mayuren C, Reddy VV, Priya SV, Devi VA. Protective effect of Livactine against CCl₄ and paracetamol induced hepatotoxicity in adult Wistar rats. *N Am J Med Sci.* 2010; 2: 491-495.
 87. Anusha M, Venkateswarlu M, Prabhakaran V, Taj SS, Kumari BP, Ranganayakulu D. Hepatoprotective activity of aqueous extract of *Portulaca oleracea* in combination with lycopene in rats. *Indian J Pharmacol.* 2011; 43: 563-567.
 88. Cordero-Pérez P, Torres-González L, Aguirre-Garza M, Camara-Lemarroy C, la Garza FG, Alarcón-Galván G, et al. Hepatoprotective effect of commercial herbal extracts on carbon tetrachloride-induced liver damage in Wistar rats. *Pharmacogn Res.* 2013; 5: 150-156.
 89. Rodwell VW, Kennelly PJ. Enzymes: Mechanism of action. In: Murray RK, Granner DK, Mayes PA, Rodwell VW. *Harper's Illustrated Biochemistry*, 26th edn, Lange Medical Books/McGraw-Hill, New York, USA. 2003: 49-59.
 90. Vozarova B, Stefan N, Lindsay RS, Saremi A, Pratley RE, Bogardus C, et al. High alanine aminotransferase is associated with decrease hepatic insulin sensitivity and predicts the development of Type 2 diabetes. *Diabetes.* 2002; 51: 1189-1195.
 91. Fraser A, Harris R, Sattar N, Ebrahim S, Smith GD, Lawlor DA. Alanine aminotransferase, γ -glutamyltransferase, and incident diabetes: the British women's heart and health study and meta-analysis. *Diabetes Care.* 2009; 32: 741-750.
 92. Ghamar-Chehreh ME, Amini M, Khedmat H, Alavian SM, Daraei F, Mohtashami R, et al. Elevated alanine aminotransferase activity is not associated with dyslipidemias, but related to insulin resistance and higher disease grades in non-diabetic non-alcoholic fatty liver disease. *Asian Pac J Trop Biomed.* 2012; 2: 702-706.
 93. de Luis DA, Aller R, Izaola O, Sagrado MG, Conde R, de La Fuente B. Role of insulin resistance and adipocytokines on serum alanine aminotransferase in obese patients with Type 2 diabetes mellitus. *Eur Rev Med Pharmacol Sci.* 2013; 17: 2059-2064.
 94. Teschke R, Vierke W, Goldermann L. Carbon tetrachloride (CCl₄) levels and serum activities of liver enzymes following acute CCl₄ intoxication. *Toxicol Lett.* 1983; 17: 175-180.
 95. Taira Z, Yabe K, Hamaguchi Y, Hirayama K, Kishimoto M, Ishida S, et al. Effects of Sho-saiko-to extract and its components, Baicalin, baicalein, glycyrrhizin and glycyrrhetic acid, on pharmacokinetic behavior of salicylamide in carbon tetrachloride intoxicated rats. *Food Chem Toxicol.* 2004; 42: 803-807.
 96. Adewale OB, Adekeye AO, Akintayo CO, Onikanni A, Saheed S. Carbon tetrachloride (CCl₄)-induced hepatic damage in experimental Sprague Dawley rats: antioxidant potential of *Xylopiya aethiopica*. *J Phytopharmacol.* 2014; 3: 118-123.
 97. Kochar DK, Singh P, Agarwal P, Kochar SK, Pokharna R, Sareen PK. Malarial hepatitis. *J Assoc Phys India.* 2003; 51: 1069-1072.
 98. Murray RK. Porphyrins and bile pigments. In: Murray RK, Granner DK, Mayes PA, Rodwell VW, eds. *Harper's Illustrated Biochemistry*, 26th edn, California, Lange Medical Books/McGraw-Hill. 2003: 270-285.
 99. da Rosa DP, Bona S, Simonetto D, Zettler C, Marroni CA, Marroni NP. Melatonin protects the liver and erythrocytes against oxidative stress in cirrhotic rats. *Exp Gastroenterol.* 2010; 47: 72-78.
 100. Ashafa AOT, Orekoya LO, Yakubu MT. Toxicity profile of ethanolic extract of *Azadirachta indica* stem bark in male Wistar rats. *Asian Pac J Trop Biomed.* 2012; 2: 811-817.
 101. Rodwell VW. Catabolism of proteins and of amino acids nitrogen. In: Murray RK, Granner DK, Mayes PA, Rodwell VM, eds. *Harper's Illustrated*

- Biochemistry, 26th edn, New York, McGraw-Hill Medical. 2003: 242-248.
102. Samra M, Abcar AC. False estimates of elevated creatinine. *Permanente J.* 2012; 16: n51-52.
103. Elgazar AF, AboRaya AO. Nephroprotective and diuretic effects of three medicinal herbs against gentamicin-induced nephrotoxicity in male rats. *Pak J Nutr.* 2013; 12: 715-722.
104. Mayes PA, Botham KM. Lipid transport and storage. In: Murray RK, Granner DK, Mayes PA, Rodwell VW, eds. *Harper's Illustrated Biochemistry.* 26th edn, California, Lange Medical Books/McGraw-Hill, 2003: 205-218.
105. Dani C, Pasquali MA, Oliveira MR, Umezu FM, Salvador M, Henriques JA, et al. Protective effects of purple grape juice on carbon tetrachloride induced oxidative stress in brains of adult Wistar rats. *J Med Food.* 2008; 11: 55-56.
106. Ismail RSA, El-Megeid AAA, Abdel-Moemin AR. Carbon tetrachloride-induced liver disease in rats: The potential effect of supplement oils with vitamins E and C on the nutritional status. *German Med Sci.* 2009; 7: 5.
107. Sokol RJ, Twedt D, McKim Jr JM, Deveraux MW, Karrer FM, Kam I, et al. Oxidant injury to hepatic mitochondria in patients with Wilson's disease and Bedlington terriers with copper toxicosis. *Gastroenterol.* 1994; 107: 1788-1798.