

AH-03

**Anatomical Characteristic of Forelimb Skeleton of Sumatran Rhino
(*Dicerorhinus sumatrensis*)**

Nurhidayat*, Ani Puji Lestari, Chairun Nisa', Danang Dwi Cahyadi, Supratikno

Department of Anatomy Physiology and Pharmacology, Faculty of Veterinary Medicine,
Bogor Agricultural University, Bogor 16680, Indonesia*Corresponding author: nhdayat@yahoo.com**Keywords:** Sumatran rhino, anatomy, forelimb skeleton**INTRODUCTION**

Sumatran rhino is one of the endangered animal species of Indonesia. This animal belongs to the order Perissodactyla, family Rhinocerotidae and genus *Dicerorhinus*. Although the animal's weight reaches 1.000 kgs, Sumatran rhino is the smallest among family Rhinocerotidae (Van Strien 1974). To support the big size and rounded body, Sumatran rhino has relatively short legs with three toes on each. The body's structure is adjusted with the animal's behavior to move quickly, even to be able to climb the sheer cliffs. In general, the forelimb get bigger burden than that the hindlimb to perform the daily activities, support the weight of the body, neck and head, so that the field wider footprint pivot (De Blasé dan Martin 1981). Therefore, Sumatran rhino's forelimb skeleton need to be studied to provide information about the relationship between the characteristics of the skeletal structure of the forelimb related to their function.

MATERIALS AND METHODS

The study was used a set of forelimb skeleton of female Sumatran rhino (named: Dusun) aged around 20 years old that received from Sumatran Rhino Sanctuary (SRS), Way Kambas National Park, Lampung, Indonesia. This study was done by observing the Sumatran rhino's forelimb skeleton in detail. Each bone parts were named base on *Nomina Anatomica Veterinaria* (2012).

RESULTS AND DISCUSSION

Sumatran rhino's forelimb skeleton has a sturdy structure, compact, and relatively short. The position of the distal part of the foot is relatively gentle to the plane of the pivot, with a relatively wide footprint. The structure was presumed as the result of forelimb skeleton's adjustment to hold the burden of Sumatran rhino's body weight that can reach 1.000 kg (Van Strien 1974), especially on the neck and the head. Forelimb skeleton was formed by scapula, humerus, radius and ulna, carpal, metacarpal, and phalanges bones. The scapula of Sumatran rhino has triangular shaped, with caudal angle that stickes to the caudal. In the scapular spine beared a big tuberosity, triangular in shaped and lead to caudolaterad. Serrated surface were relatively broad and did not separated into cranial and caudal parts. The trapezius (*pars thoracica*) and both serratus ventralis thoracis et cervicis which inserted into tuber of spine and serrated surface respectively, were highly developed in the Sumatran rhino (Susanti 2012). The humerus was relatively big and short bone. In the proximal extremity, greater and lesser tubercles were well developed and separated with wide intertubercular groove. At lateral surface, humeral crest was a developed ridge. This ridge extends to distolaterad, form a relatively large tubercle that was deltoid tuberosity. This tubercle was insertion of the brachiocephalicus (Susanti 2012), as protractor of forelimb. The radius was relatively smaller and shorter than that of the ulna. Radial tuberosity has a rough surface e and extending to the lateral and medial. The ulna was fused with radius, however still forming interosseus antebrachii proximal and distal spaces. Olecranon protrude to caudodorsad with large olecranon tuber, widened to laterad and mediad, as insertion of the triceps brachii (Susanti 2012).

Sumatran rhino have eight carpal bones, and was composed of two rows. The proximal row formed by radial, intermediate, ulnar and accessory carpal bones. While the distal row formed by the first, second, third, and fused of fourth and fifth carpal bones. Third and fourth carpal bones

have protuded to caudoventrad. The tuber and protruded of bones were well developed on the Sumatran rhino, it's suggested as attached part of tendon and ligament to strengthen the activity of forelimb muscles (Susanti 2012). This animal has four metacarpal bones, but only three are functional i.e. metacarpalia II, III and IV bones, whereas metacarpal V was small and conical bone, attached on caudal surface of fused fourth and fifth carpal bones. Digit III was located in the medial, and the digital bones were large and sturdy, on the othe hand, the digit II and IV were widened to craniomedial and craniolaterad, respectively. Skeletal structure of the Sumatran rhino's forelimb presumed as a result of adaptation to the weight of this animal and habitat.

CONCLUSION

Sumatran rhino's forelimb skeleton has a relatively short size, with a solid and compact structure. The bones of these animal have some large tuber, and large and length protude, as well as some parts of these bones have a rough surface. This structure might support the function of the forelimb for daily activities.

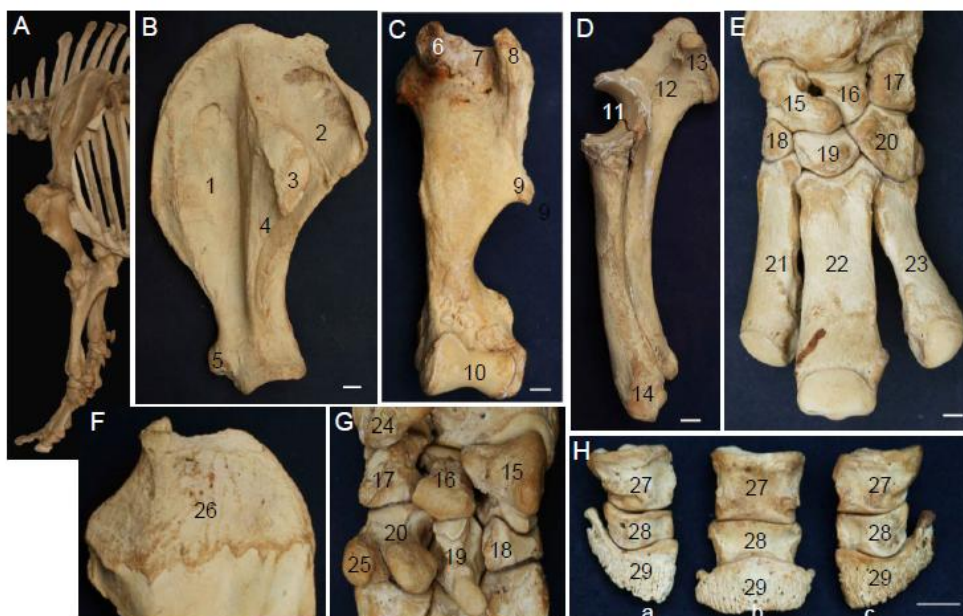


Figure 1. Forelimb skeleton of Sumatran rhino (*Dicerorhinus sumatrensis*)

A. Forelimb skeleton; B. Scapula; C. Humerus; D. Radius-ulna; E. Carpal et metacarpal; F. Scapula medial surface; G. Carpal palmar surface; H. Phalanges; 1. Supraspinous fossa; 2. Infraspinous fossa; 3. Tuber of scapular spine; 4. Scapular spine; 5. Supraglenoid tubercle; 6. Greater tubercle; 7. Intertubercular groove; 8. Lesser tubercle; 9. Deltoid tuberosity; 10. Condyle of humerus; 11. Trochlear notch; 12. Olecranon; 13. Olecranon tuber; 14. Lateral styloid process; 15. Radial carpal; 16. Intermediate carpal; 17. Ulnar carpal; 18. Second carpal; 19. Third carpal; 20. Fourth and Fifth carpal; 21. Metacarpal II; 22. Metacarpal III; 23. Metacarpal IV; 24. Accessory carpal; 25. Metacarpal V; 26. Serrated surface; 27. Proximal phalanx; 28. Middle phalanx; 29. Distal phalanx; a. Digit II; b. Digit III; c. Digit IV. Bar = 2 cm.

ACKNOWLEDGEMENT

We gratefully thanks to Sumatran Rhino Sanctuary which have donated the skeleton and Marcellus Adi, DVM who have facilitated the skeleton to be research material and collected in Laboratorium of Anatomi, Faculty of Veterinary Medicine, Bogor Agricultural University, Bogor, Indonesia.

REFERENCES

1. De Blasé AF and RE Martin. 1981. *A Manual of Mammalogy with Keys of Families of the World*. 2nd Ed. United State of America: Wm. C. Brown.
2. Nomina Anatomica Veterinaria. 2012. 5th edition. Hannover, Columbia: International Committee on Veterinary Gross Anatomical Nomenclature.
3. Susanti H. 2012. Anatomi otot daerah bahu dan lengan atas badak Sumatera (*Dicerorhinus sumatrensis*). [Thesis]. Institut Pertanian Bogor. Bogor.
4. Van Strien NJ. 1974. *Dicerorhinus sumatrensis (Fischer), the Sumatran or Two-Horned Asiatic Rhinoceros*. The Netherlands: Wageningen.