

Histological Evaluation of the Genital Tract of *Artemia parthenogenetica* in Urmia Lake Area

Sareh Najaf Asaadi^{1*}, Iraj Pousty¹, Dariush Azadi Khah²

¹Department of Basic Sciences, Science and Research branch, Islamic Azad University, Tehran, Iran

²Department of veterinary medicine, Urmia branch, Islamic Azad University, Urmia, Iran

*Email: sareh_n2002@yahoo.com

Received for publication: 04 September 2014.

Accepted for publication: 10 February 2015.

Abstract

This research aimed to study the histology of the genital tract of *Artemia parthenogenetica* in Urmia Lake area. The studied samples were put in the stabilization solutions of 10% formalin and Bowen in order to be investigated after verification of the experts of Artemia Research Center of country, during the hatching and rearing period in incubator, and during the sexual maturation. They were also examined after tissue periods and cut with microtome by Hematoxylin method and Eosin painting and by light microscopy and photomicrographs taken from them. In the histological study of simple epithelial cells, linings of the uterus gradually towards the output mouth are converted to stratified tissue. The basal lamina and the connective tissue are located under it. The smooth muscles are located out of the connective tissue, which gradually transforms into the striped muscle tissue to facilitate the passage of cysts in the uterus and outlet ducts.

Keywords: histology, genital tract, *A.parthenogenetica*, Urmia

Introduction

Artemia is a small crustacean and unelected filtering with high capability to life in salty aquatic ecosystems. In recent conducted studies 595 geographic regions has been reported for *Artemia* living in the world. In Iran, 17 locations having *Artemia* have been identified including Urmia Lake, Maharlu, Bakhtegan, Inche and Shor, Kal-ShorGonbad, Tashklake, etc. Two species of *Artemia* were identified in Iran, *A.urmiana* seen in Urmia Lake and *A.parthenogenetica* species that has been identified in addition to Urmia Lake in other habitat (Abatzopoulos, 2006). The coexistence of two species in a habitat is possible and *A.parthenogenetica* populations can live beside the bisexual types (Hafeziyeh 2003, 96). *Artemia* is known as an early indicator of arthropods, with clause-clause body and leaf-like and flattened appendages attached to it. Total body length of female adult *Artemia* is 10-12 mm and with a width of 4 mm (Agh, 2010). Total body surface of *Artemia* is covered by an infinitely thin flexible exoskeleton called chitin that is attached to it from inside of the muscles (Drewes 2002). Body is formed of the head, chest and abdomen. Six clause exist in the head that are the specialized areas of the body. A pair of sensory narrow tentacle (antenola) exists that is tube-cylindrical with flexible walls that have mobility in any direction and contains two types of sensillae hairs, a pair of compound eyes, a pair of mandibular and a upper lip are also appendices of head (Hafeziyeh 2003, 43). Female genital organs consist of a pair of ovaries, a pair of oviduct, a uterus or uterine sac (Hafeziyeh2003, 66). Ovaries start from eleventh clause of chest and continue to the sixth clause of abdomen and are located in two sides of intestines. After ovulation, ovules entered into oviduct and stored there for several hours. Sometimes, it is exposed to uterine tube secretion for a few days. Uterine tube extends and makes lateral sacs. The cells of sacs' wall are highly stretched so that they can be hardly detected as the cells of uterine tube (Criel

2001). Reproduction in species of *A. parthenogenetica* is unlimited and external conditions, is inducer of the maturation and cleavage (Hafeziyeh 2003, 68). *Artemia* is growing very fast. Maturation stage occurs after hatching during about three weeks. Mature species can survive more than four months. (Drewes, 2002).

Some studies have been done on *Artemia* in Iran and other countries. For example, in 1994, Pilla and Beardmore conducted a study entitled genetic and morphologic differentiation in bisexual *Artemia* species native to the waters of the old districts. Morphological study of genital tract of female *Artemia* was conducted in 1980 by Criel. He studied the fallopian tube in 1980 and described the fallopian tube cells and its changes during the reproduction cycle. This study indicated that the first meiosis of oocytes in metaphase was stopped during the entering into the uterine tube until the oocytes to be released from the uterine tube. In 1990, Robert Brown and his colleagues have studied the biology of *Artemia*. Agh and his colleagues (2007) have investigated the simultaneous and compound existence of bisexual and *A. parthenogenetica* species in Urmia Lake and its surrounding marshes. Asem and Rastegar Poyani (2008) have examined the identification and morphological differentiation of *A. urmiana* in different geographical stations of Urmia Lake. Asem (2009) conducted a study in which began to the biometric comparison of two groups of *A. parthenogenetica* resided in Khalij and Urmia Lake. Peykaran-Manna et al (2010) have studied the biometric characteristics of *Artemia* in the four areas of Iran. Agh et al (2010) compared the *A. parthenogenetica* of Urmia, *A. urmiana* and *A. sinica* under laboratory conditions.

Najaf Ashadi et al (2013) comparatively studied genital tract of *Artemia parthenogenetica* and *A. urmiana* in Urmia Lake. The results indicated the differentiation and separation of brown shell gland tissue, skeletal and smooth muscle cells in the wall of the uterus, and somatic cell and augunyum in both groups. No significant difference was observed in genital tissue structure although in *A. parthenogenetica*, uterine lining cells were elongate, thin, with spindle-shaped cells and cysts of nuclear heterochromatin, basophils was less intense and granules.

This study aimed to determine the histological characteristics of the female genital tract in *A. parthenogenetica* species because scientific understanding of the biological behaviors of an living organism help human to protect its life and also optimally utilize of that living organism. Histological evaluation of the genital tract of these crustacean can be the foundation of biology study of *Artemia*.

Methodology

Artemia samples after verification of the experts of *Artemia* Research Center in Urmia during the hatching and rearing period in incubator and after maturation have been transferred to the stabilization solutions of 10% formalin and Bowen and have been sent to the laboratory for histological study. Due to the small size of the samples, they are scavenged and put in autotechnicon set for tissue processing (dewatering, transparency, etc.). Samples were formed with paraffin and were cut with microtome set in 7 μ m thickness and were stained with Hematoxiline & Eosin (Pousty and Adib-Moradi, 2003, 556-540).

Results

Female *Artemia* can be easily identified by the ovaries that contain zygote that is exactly located behind the eleventh pair of tracopods in the top of intestines from the digestive tract (Figure 1).



Figure 1. Female Artemia

Zygotes are grown and evolved in two sacs of ovary in the abdominal area. Ovary is wider at the back and becomes thinner towards the head and totally is seen in the pear shape. Zygotes immediately after removal from the ovary are spherical and through two oviduct move toward the uterus and then from there by a short urethra go to the outside of the body (Figure 2)

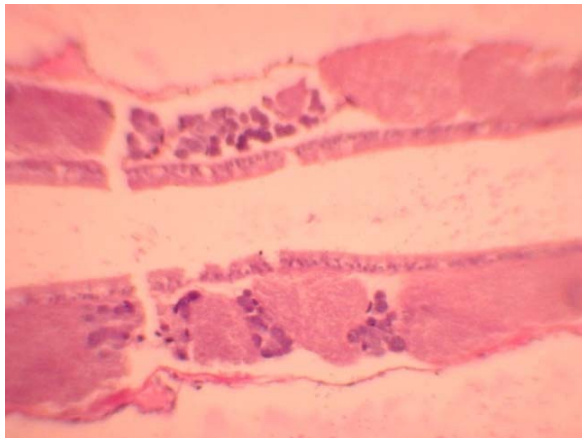


Figure 2. Longitudinal section of the uterus of *A. parthenogenetica*, H & E, 150x

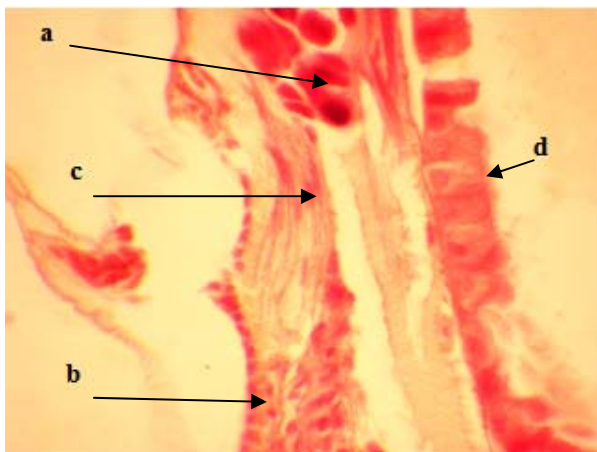


Figure 3. Uterine of *A. parthenogenetica*, H & E, 600x a.cyst, b. layer of chitin, c. smooth muscle, d. intestinal epithelial cells

In histological study of *A.parthenogenetica*, uterus contains a layer of stretched epithelial cells with bright nuclei that becomes bigger towards outlet mouth and after that basal lamina layer, loose connective tissue, smooth muscle which is completed from outside by chitin of surface of body with an infrastructure of delicate connective tissue (Figure 3).

Connective tissue with blood vessels exist around the ovary and uterine which is closer to it around the lining of the uterus and it seems vessels to be effective in feeding of cysts. After basal lamina, the smooth muscles surround it from outside which towards the outlet mouth convert to the stratified type (Figure 4, 5).

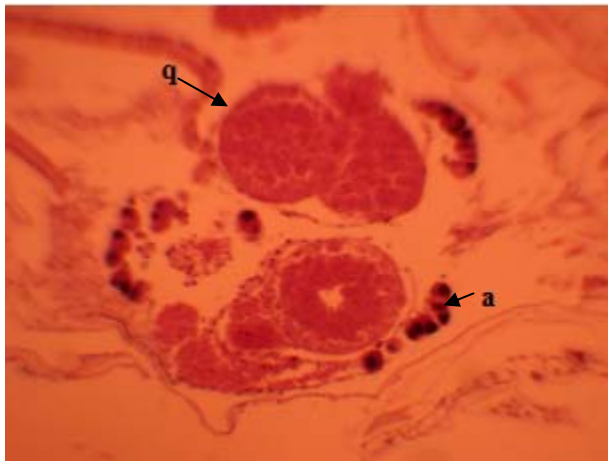


Figure 4. A part of the uterus of *A.parthenogenetica* which is divided into two parts by blood vessels H & E, 150x a. cyst, q. blood vessels

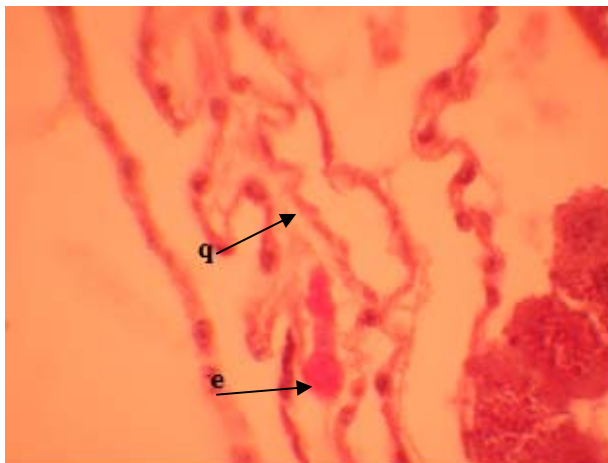


Figure 5.Construction of the uterine lining in which the blood vessel and muscle cells can be seen, H & E, 600x e- muscle cells, q- blood vessel

Cysts in the dark *A.Parthenogenetica* are heterochromatin and have a few granules (Figure 6).

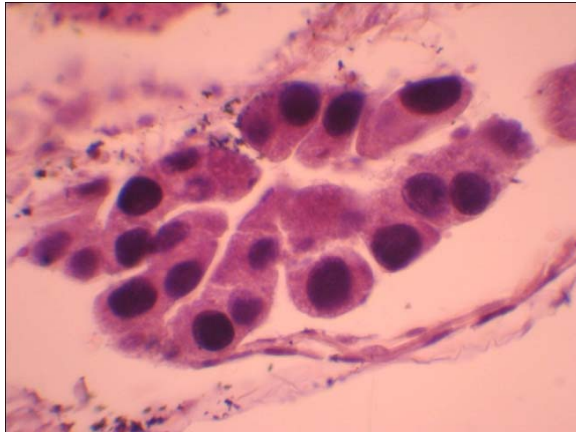


Figure 6. Ovary of *A. parthenogenetica*, heterochromatin cysts, H & E, 600x

There is a uniform and eosinophilia liquid inside the uterine in order to cysts easily exit out of the body which probably secreted by cells in the lining of the uterus (Figure 7, 8, 9).

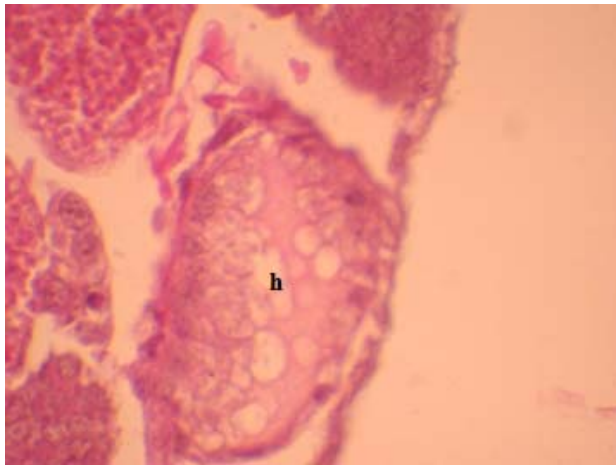


Figure 7. The cross-section image of an empty uterus from cyst, H & E, 600x h- fluid in the uterus.

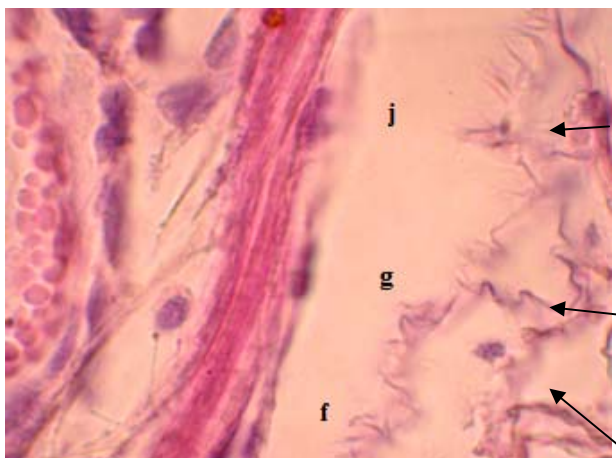


Figure 8. A part of the uterus of *A. parthenogenetica*, H & E, 600x f. stratified muscle, g. cells of the uterine lining, j. nucleus of muscle cells

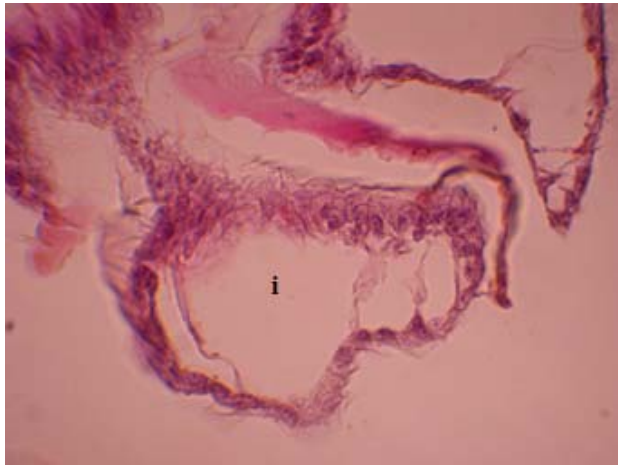


Figure 9. Outflow tract of uterus in cross-section which is shown with letter i, H & E, 600x

Conclusion

Growth and development of manufacturer organs of sexual cells start from the variation of the original generative cell during the proliferation and increasing flow and during the first part of the reproductive tract. Oviduct emerged of the ovaries that are located in the abdominal area. During the ovulation and reproduction, Zygotes are stored in a small side-sacs and spacing of the uterus (Brown et al. 1990, 141 -146). The existence of fluid in the uterus (Fig. 7) facilitates the motion of cysts from uterus into the conduit and from there into the outside of the body. Criel (1980) observed the secretory cells in the *Artemia* fallopian tubes that is correspond to our findings.

Zygote sac is surrounded by a layer of circular smooth and longitudinal muscle (Figure 3). The existence of skeletal muscle at the outlet mouth of the uterus and its conduit can be effective in exit of cysts from body (Figure 8). Robert Brown and his colleagues (1990).

The results of the current study are congruent with the study done by Najaf Ashadi et al (2013), in which they reported Circular and longitudinal smooth muscle.

References

- Abatozopoulos, & Theodore.J. (2006). *Artemia* sites in Iran. J.Mar. Biol. Ass. UK. 86.
- Agh, N. (2007). Coexistence of Sexual and A.Parthenogenetic Population in lakeUrmia and Neighbouring Lagoons. WILEY inter Science.
- Agh, N., Zahri, S., & Ehtesham, H. (2010). Biometric comparison ofA.parthenogenetica of Urmia,bisexual *Artemia* of Urmia and A.sinica under laboratory conditions, Applied Biology, 23.
- Asem, A.R., & Rastegar-Pouyani, N. (2008). Morphological Differentiation of *Artemiaurmiana* Gunther, 1899 (Crustacea: Anostraca) in Different Geographical Stations from the Urmia Lake, Iran. MedwellJournal.3(2).222-228.
- Asem,A.R. (2009). Biometric comparison of two parthenogenetic populations of *Artemia* Leach, 1819 from the Urmia Lake basin, Iran(Anostraca: Artemiidae). Zoology in the Middle East. 47. 117-120.
- Browne, R. A. (1990). Sorgeloos, Patrick. And Trotman, Clive N.A., *Artemia* Biology,141-146.
- Criel, G. (1980).Morphology of the female genital apparatus of *Artemia*: A review.
- Criel, G. (1980). Ultrastructural observations on the oviduct of *Artemia*: A review.
- Drewes,C.(2002).*Artemiafranciscana*.(<http://www.eeob.iastate.edu/faculty/DrewesC/htdocs/ARTE MIA.PDF>)

- Hafeziyeh, M. (2003). *Artemia* (brine shrimp), Iranian Fisheries Research Institute – Scientific Information Management, Aslani Cultural Institute Press, Tehran.
- Najaf asaadi, S., Pousty, I., Azadi khah, D. & Nekuie fard, A. (2013). A Comparative Study on the Histology of Reproductive Organs in *Artemia urmiana* and *Artemia parthenogenetica* in Urmia Lake Region. *Cibtech Journal of zoology*. 3(2), 7-12.
- Peykaran Mana, N. (2010). Biometrical characters of *Artemia* from four Iranian regions. *Iranian Journal of Fisheries Sciences*, 10 (2).
- Pilla, E. J. S. & Beardmore, J. A. (1994). Genetic and morphometric differentiation in old World bisexual species of *Artemia* (the brine shrimp), 73.