

Palatal Rotation Flap in Management of Oroantral Fistula with Left Maxillary Sinusitis

Surya Azani

Otorhinolaryngology Head and Neck Surgery Division
Medicine Faculty of Andalas University/ Dr. M. Djamil Hospital, Padang

ABSTRACT

The oroantral fistula (OAF) is a pathological communication between the maxillary sinus and oral cavity lined by epithelium. This condition mostly follows dental extraction of molar and premolar maxilla teeth. OAF may leads to sinusitis. Adequate management should be performed include closing the OAF and elimination of sinus infection to provide good healing and prevent recurrences. Several methods were use to close OAF but local flap mostly common choice for the surgeon such as palatal rotation flap. Antrostomy, FESS or Caldwell-Luc are procedures to eliminate maxillary pathology. A case of oroantral fistula with left maxillary sinusitis was treated by using palatal rotation flap after performed left antrostomy for maxillary sinusitis. Result : The postoperative healing was satisfactory and 7 weeks follow up there was no complain anymore. Discussion : The choice of appropriate management for OAF should consider the width and presence or absence of sinus infections. OAF with sinus infection, must be cured and pathologic tissue in sinus cavity must be removed to avoid impaired healing OAF closure. The use of palatal rotational flap for closing OAF is an acceptable and reliable alternative in OAF management. [JuKe Unila 2014;4(7):12-21]

Key words: maxillary sinusitis, oroantral fistula, palatal rotation flap

Introduction

Oroantral fistula (OAF) is a pathological communication between the maxillary sinus and oral cavity lined by epithelium.¹⁻⁴ The incidence of OAF is relatively rare (5%) and are frequently caused by dental extraction of maxillary premolar and molar and leaves a gap on the maxillary sinus floor.^{1,3,4} The thickness of the antral floor in that region ranges from 1 to 7 mm.³ It must be emphasized that unlike the oro-antral communication (OAC), OAF is characterized by the presence of epithelium.¹⁻⁴ If the OACs are left untreated and stay patent, 50% of the patients will experience sinusitis after 48 hours and 90% after 2 weeks.⁵ An OAC with diameter less than 2 mm usually will close spontaneously, but when there is more than 3 mm defect, or there is inflammation in the antrum or in the periodontal region, the OAC often persists and may become oroantral fistula (OAF).

Fistula can be closed by using alveolar, palatal or buccal flaps after the pathologic tissue and bone was removed.² Goal of surgery is to promote ventilation and aeration of the maxillary sinus, to remove pathologic bone and to resect the thickened epithelium along the borders of the fistula.¹ Surgical success rate depends on the technique, the size and site of the fistula and the presence or absence of sinus disease.¹

Case Report

A 34-years old woman presented to ENT outpatient clinic Dr. M. Djamil Hospital on November 6th 2012 with chief complain water came out from the left nostril while drinking and gargling since 6 months ago.

There was history of extracted upper left molar tooth 6 months ago, one day later, patient felt the water came out from the left nostril when the patient drink and gargle. Patient went to general practitioner and gave some medicines.

One month later, patient went to ENT doctor because there was cold for one week, nasal congestion, pain at the left cheek and there was still water came out from the left nostril while drinking and gargling, patient was diagnosed as acute sinusitis with oroantral fistula and got some medicine, she was adviced to performed computed tomography for the sinus and planned to performed operation but patient didn't followed this. One month later patient went to another dentist, than the fistula was sutured in local aneshtesia but didn't succeeded. Two months later patient went back to ENT doctor because the symptoms were persistent such as water came out from the left nostril while drinking and gargling, post nasal discharge and felt uncomfortable at the left cheek. Computed tomography for the sinus was performed and prepare for operation. The patient asked to postponed the operation until she finished her final lecture, 2 month later and only asked for medicine.

General examination revealed general condition was moderately ill, composmentis cooperative, blood pressure 110/80mmHg, pulse rate 88x/mnt, respiratory rate 18x/mnt and temperature 36.8⁰C.

Ear, nose and throat examination revealed no abnormality was detected in the ear and throat. Right nasal cavity was wide, inferior and middle turbinate was eutrophy, no discharge and no septal deviation. Left nasal cavity was wide, inferior turbinate was eutrophy, middle turbinate was eutrophy, there was mucopurulent discharge and no septal deviation. On posterior rhinoscopy revealed mucopurulent nasal discharge. Nasal endoscopy revealed that right nasal cavities no abnormality was detected, left nasal cavity was wide, inferior and middle turbinates were eutrophy, no septal deviation, the superior part of uncinata was paradox, middle meatal was

open, maxillary sinus ostium was patent and there was mucoid discharge came out from the ostium. Oral cavity revealed fistula at left maxillary alveolar process in region of 1st molar and no discharge came out from the fistula (figure 1).

Paranasal sinus computed tomography on September 5th, 2012 reveal left maxillary sinusitis and thickening the mucosa of left maxillary sinus with small defect/fistula on the floor of left maxillary sinus (figure 2)

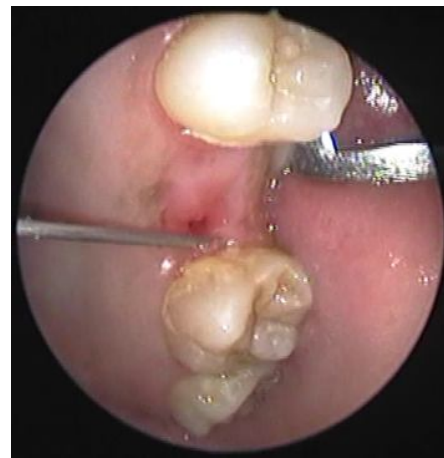

Figure 1. OAF at upper left maxillary alveolar process in region of 1st molar

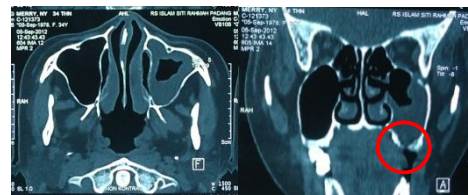


Figure 2. Axial and coronal view computed tomography of paranasal sinus. Thickening the mucosa of left maxillary sinus with small defect on the floor of left maxillary sinus.

Patient was diagnosed as oroantral fistula with left maxillary sinusitis, planned to performed operation on general anesthesia and consult to Anesthesiology departement. Laboratory examination was performed as preoperative preparation and the result

was within normal limit (haemoglobin 13.9 g/dl, leucocytes 7,500/mm³, thrombocytes 359,000/mm³, haematocrytes 43% and PT/APTT 13.3"/34.4")

On November 8th, 2012 left antrostomy followed by irrigation of left maxillary sinus and palatal rotation flap for closing OAF was performed. The operation was started with patient laid down on operating table and was performed aseptically and antiseptic procedures in operating field. Oral packing was applied. Adrenaline and lidocaine, 1:4 tampons were placed on left nasal cavity for 10 minutes. Oral cavity was evaluated and there was fistula at the upper left maxillary alveolar process in region of 1st molar and there was granulation tissue around the fistula. Nasal cavity was evaluated with endoscope 0° revealed no abnormality was detected at right nasal cavity and left nasal cavity was wide, inferior and middle turbinates eutrophic, no septal deviation, the superior part of uncinate was paradoxical, middle meatus was open, maxillary sinus ostium was patent and there was mucoid discharge came out from the ostium. Antrostomy was performed and left maxillary sinus was evaluated by using endoscope 0° and 30°, revealed minimal mucoid discharge and polypoid mucosa at 2/3 inferior part of maxillary sinus and around the fistula. Discharge in the maxillary sinuses was taken by using nasogastric tube no. 8 that was connected to 5cc syringe and sent to Microbiology Laboratory for bacterial culture and sensitivity test. In the oral cavity, granulation tissue around the fistula, epithelial layer of fistula and the bone was cleaned by using curette. Evaluation of the sinus also performed through the fistula by using an endoscope 0° and 30°. The width of fistula ± 6mm. Then, polypoid mucosa in left maxillary sinus was removed by using a curette and

sent for histopathological examination to Anatomic Pathology Laboratory. Maxillary sinus cavity then irrigated with sterile aqua through nasal antrostomy and the fistula. Palatal rotation flap was performed to close fistula. For palatal rotation flap procedures, adrenaline 1:200,000 was injected at left side of hard palate and full-thickness mucoperiosteal flaps were designed based on the greater palatine vessels. The anterior extension of the flap was determined by measuring distance from the greater palatine foramen to the lateral-anterior bony fistula border. The width of the flap was determined by the bony defect. The lateral border, about 5 mm from palatal marginal gingiva. The palatal rotation flap was rotated, advanced and sutured to the lateral alveolar mucosa that had been undermined, with interrupted sutures with vicryl suture material. Oral packing was removed and operation had been finished.

After the operations, the patient was given therapy ceftriaxone injection 2x1 gr, dexamethasone injection 3x0.5 mg and tramadol 100mg drip in 500 cc Ringer Lactat/8 hours. The patients were instructed to avoid activities that may produce pressure changes between the nasal passages and oral cavity, such as sucking on a straw, blowing of the nose and sneezing with a closed mouth. The patient also prohibited to gargle and given soft diet during this period.

Follow up post operative day 2, there was nasal congestion, brown bloody salivary discharge at left nasal cavity and posterior nasal discharge. There was pain at left nasal cavity and hard palate and no water came out from nostril while drinking. Anterior rhinoscopy revealed nasal cavity was narrow, inferior turbinate was edematous, middle turbinate couldn't be evaluated, in left nasal cavity there was brownish discharge. Nasoendoscopy revealed that left nasal cavity was narrow, inferior and

middle turbinate were edema, antrostomy window at inferior meatal was hyperemic and there was brownish discharge came out from this window and maxillary sinus ostium. In throat, there was clotting at left side posterior pharyngeal wall. In oral cavity, palatal rotation flap was good and defect at hard palate was covered by clotting and fibrin tissue (figure 3).

Patient was diagnosed post palatal rotation flap and post left antrostomy as indication of OAF with left maxillary sinusitis. Therapy for the patient was continued, ceftriaxone injection 2x1 gram, dexamethasone injection 3x0.5mg, erdostein syrup 3x350 mg, pseudoephedrine 15mg + terfenadine 20 mg syrup 3x2 teaspoon and ibuprofen syrup 3x400 mg.

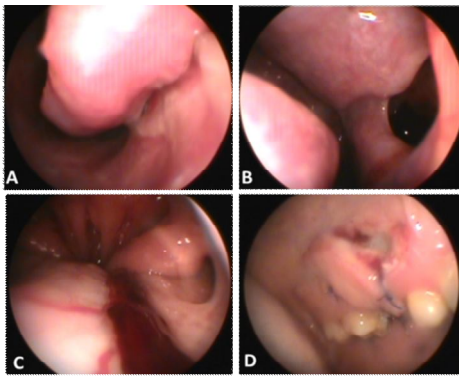


Figure 3. Post operative day 2. A. Bloody discharge came out from antrostomy window. B. Left maxillary sinus ostium with clotting. C. Clotting at nasopharynx. D. Palate rotation flap closing OAF

Follow up post operative day 4, nasal congestion was decreased, brown bloody salivary discharge from left nasal cavity and posterior nasal were decreased, pain on left nostril and hard palate were decreased and no water came out from nostril while drinking. Nasoendoscopy revealed that both of nasal cavity was wide, inferior turbinate was edema minimally and middle

turbinate was eutrophy, in left nasal cavity brownish discharge came out from maxillary sinus ostium and antrostomy window in inferior meatal was decreased. In throat, there was no clotting at posterior pharyngeal wall. In oral cavity, palatal rotation flap was good and defect at hard palate was covered by new thin mucosa (figure 4).

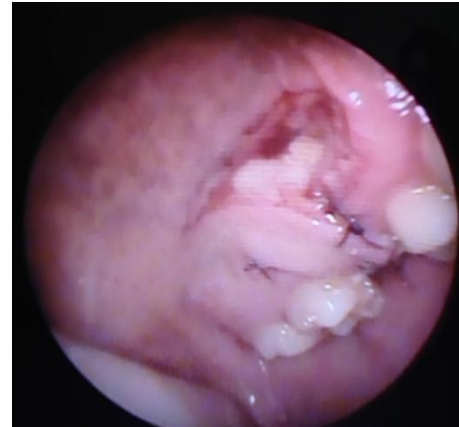


Figure 4. Palate rotation flap closing OAF.

Patient was diagnosed post palatal rotation flap and post left antrostomy as indication of OAF with left maxillary sinusitis. The patient was given therapy ceftriaxone injection 2x1gram, dexamethasone injection 3x0.5 mg, erdostein syrup 3x350, pseudoephedrine 15mg + terfenadine 20 mg syrup 3x2 teaspoon and ibuprofen syrup 3x400 mg. From Microbiology department, the results of culture and sensitivity test of left maxillary sinus discharge, found no growth of aerobic bacteria

Follow up post operative day 6, no nasal congestion, pain in left nasal cavity intermittently, brown bloody salivary discharge from left nasal cavity and posterior nasal was decreased, no pain on palatal and no water came out from nostril while drinking and gargling. Nasoendoscopy revealed that left nasal cavity was wide, inferior turbinate and middle turbinate was eutrophy, there

was brownish discharge came out from maxillary sinus ostium. In oral cavity, palatal rotation flap was good and defect at hard palate was covered by new thin mucosa. Patient was diagnosed with post left antrostomy and closed OAF with palatal rotation flap. The patient was allowed to go home and given therapy cefixime syrup 2x100mg, erdosteine syrup 3x350, pseudoephedrine 15mg + terfenadine 20 mg syrup 3x2 teaspoon, and ibuprofen syrup 3x400mg.

Follow up post operative day 15, no water came out from nostril while drinking. Anterior rhinoscopy revealed nasal cavities was wide, inferior turbinate and middle turbinate were eutrophy and no discharge. In oral cavity, palatal rotation flap was good and defect at hard palate was covered by new thin mucosa. The patient was given therapy cefixime syrup 2x100mg, erdosteine syrup 3x350, pseudoephedrine 15mg + terfenadine 20 mg syrup 3x2 teaspoon, and ibuprofen syrup 400mg if needed. Hystopathology examination of the tissue from left maxillary sinus revealed polyp impression with acute exacerbations of chronic inflammation (Figure 5).

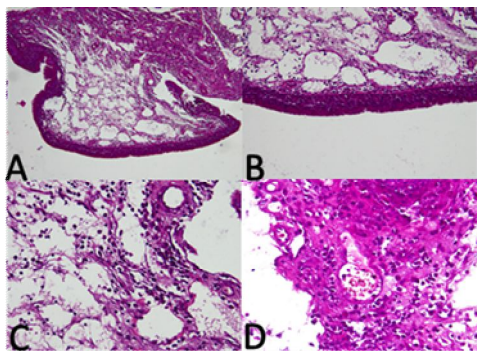


Figure 5. A&B, Tissue covered by respiratory epithelium. C, loose stroma and inflammatory cell infiltration. D, capillary hyperemia

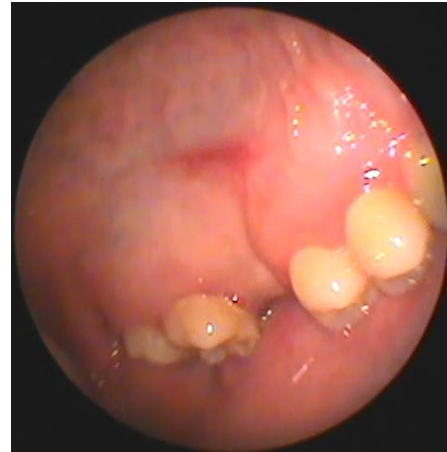

Figure 6. A. OAF was closed with palatal rotation flap and denude hard palate was covered with new mucosa completely

Follow up post operative 7 weeks, no nasal congestion, no cold, no pain in left nasal cavity, left cheek and palate, no water came out from nostril while drinking and gargling. Nasoendoscopy revealed left nasal cavity was wide, inferior turbinate and middle turbinate was eutrophy, maxillary sinus mucosa was normal and no discharge. In oral cavity, palatal rotation flap was good with defect at hard palate was covered mucosa completely (figure 6).

Discussion

Oroantral fistula (OAF) is a pathological communication between the oral cavity and the maxillary sinus that is characterized by the presence of epithelium arising from the oral mucosa and/or from the antral mucosa or filled by granulation tissue or by polyposis of the sinus membrane.¹⁻⁴ Depending on the location it can be classified as alveolo-sinusual, palatal-sinusual and vestibulo-sinusual.⁷ It must be emphasized that unlike the oroantral communication (OAC), OAF is characterized by the presence of epithelium.¹⁻⁴

The most common etiologic factor for OAF is dental extraction of maxillary premolar and molars, because of very close anatomic relationship between the

root apices of the premolar and molar teeth and the sinus floor.^{2,4,7-9} The thickness of the antral floor in that region ranges from 1 to 7mm.³ The 2nd molar roots are the closest to the maxillary sinus floor, followed by the roots of the 1st molar, 2nd premolar, and 1st premolar.¹⁰ OAF also can be caused by dentoalveolar infection, cystic lesions, maxillary tumors, Paget's disease and trauma like complication of Caldwell-Luc procedures or implant surgery.^{7,8,11} The extraction of maxillary posterior teeth is the most common cause of OAF (80%), maxillary cysts (10-15%), benign or malignant tumors (5-10%) and trauma (2-5%).^{8,9}

Fistulas are common between the ages of 30 and 60. It is considered that the loss of teeth with advancing age increases the incidence of fistula and the maxillary sinus reaches its greatest size during the third decade of life, so the incidence of OAF usually higher after that age.^{2,8} Hernando⁸ examined 12 patients with OAF and found that average age of the patients was 47.5 years old. Qureshi⁴ examined 60 patients with OAF and also found that the age of the patients ranged from 17 to 68 years with the mean age of 34.03 ± 10.56 years. Out of the 60 patients 41.6% were in the third decade of life followed by 36.76% in the fourth decade.

OAF is more frequent in males than females. In males, OAF is twice as common as in females. This is attributed to more common and more traumatic tooth extraction in men.² Qureshi⁴ in his study on 60 patients with OAF found that OAF is more common in males (61.7%) than females (38.3%), whereas the male to female ratio was 1.6:1. The study of Hirata et al, cited by Qureshi⁴ showed that the rate of oroantral fistula is significantly higher in males with a male to female ratio of 1.7:1.

Clinically, patients with OAF will complain regurgitation of food or fluid from the oral cavity into the antrum and then

into the nose, present with nasal phonation, unable to blow the wind instruments or drink through a straw due to the escape of air from the mouth into the nose and foul smelling discharge in the nose or exuding from the fistula into the mouth.^{4,12} OAF may be confirmed by observing the passage of air or bubbling from the post-extraction socket when the patient tries to exhale gently through their nose while their nostril is pinched (Valsalva test).⁹ In the oral cavity, OAF can be determined by introducing a silver probe into the antrum through the fistula.¹⁰ Sometimes an antral polyp can be found in the fistula.^{4,12} OAF on radiologic findings usually reveals discontinuity of the sinus floor, a communication between the oral cavity and the sinus, opacification of the sinus, focal alveolar atrophy and associated periodontal disease.¹

The fistula must be quickly closed because its persistence increases the possibility of inflammation of the sinus through contamination from the oral cavity. Sinus infection can occur with any size and duration of fistula.⁷ In this case we didn't find aerobic bacteria, this may be because we only got rinse water from the maxillary sinus, patients have had medicine before and unfortunately we didn't perform an anaerobic bacterial test.

The choice of appropriate therapy for OAF should consider the width and presence or absence of infection. If there is a sinus infection, it must be cured before surgery to avoid impaired healing because sinus disease impairs closure of OAF.^{7,8} According to Lore¹³, small oroantral fistula 1 to 2 mm, usually close spontaneously, fistula from 3 to 4 mm are usually successfully closed with a buccal flap and fistulae 5 mm and larger require a more extensive surgical procedure using a large palatal flap. The different results obtained by Von Wonen, cited by Meirelles¹ for 90 cases and conclude that

spontaneous closure of OAF of any size was rare and surgery was required.

There are several alternative techniques to close OAF, such as soft tissue flap, bone graft, alloplastic material and some other technique.⁵ Local soft tissue flaps, such as buccal flap, buccal fat flap and palatal flap, are the preferred technique by surgeons and more than adequate to close OAF.^{2,3,5} None of these methods were proved to be superior to the other. However, there are certain advantages and disadvantages of these methods.^{2,3} In this case we closed the OAF with palatal rotation flap.

Palatal flap for closing OAF was describe first by Ashley on 1939.⁹ Palatal rotation flap are based on the greater palatine artery and its integrity was an important success factor (figure 7).^{4,8,9,11}

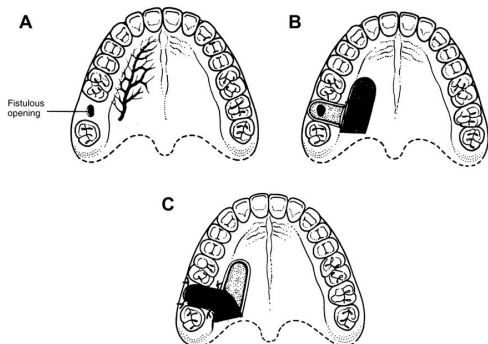


Figure 7. Palatal rotation flap. A. Fistula with outlining course of anterior palatine artery. B. Incision for palatal flap C. Flap rotated and sutured into position. Exposed palatal bone will heal by secondary epithelialization⁵

In this flaps, terminal part of the greater palatine artery is its nasopalatine branch, which ascends up through the incisive foramen into the nose where it anastomoses with the septal branches of the sphenopalatine artery. This establishes the basis for retrograde flow through the nasopalatine artery when the greater palatine neurovascular bundle is transacted. An appropriate length/width ratio is important for the success rate of random flaps. No flap necrosis is found

when the ratio is below 2.15 and significant edge necrosis and repair failure is always noted in cases with a ratio above 2.49.^{4,8,11}

Palatal flap are preferred to the buccal flap because it does not make any reduction in the depth of the maxillary buccal vestibule, and it is less vulnerable to breaking down than a buccal flap because of the thickness of the palatal mucosa and because inclusion of the artery prevents vascular compromise.⁵ Palatal flaps are preferred in larger and recurrent fistula.^{2,8} It is also particularly indicated in cases of unsuccessful of buccal flap procedure.⁴ Palatal bone at donor site of palatal flap that exposed will heal by secondary epithelialization and completely healed 2 months post-operatively and it is not necessary to use grafts.^{5,8}

The advantages of this flap include good vascularization, excellent thickness and tissue bulk and easy accessibility.^{4,7} It also allows for the maintenance of the vestibular-sulcus depth. It is particularly indicated in cases of unsuccessful buccal flap closure. Donor site necrosis is a very rare complication.⁴ The disadvantage of this flap include surgical procedure is more difficult, exposure of the bony palatal surface, pain and later surface irregularities of the surgical area due to secondary epithelialization two or three months later and the most important disadvantage is the necrosis of the palatal flap that can occur following excessive rotation of the flap.^{2,7,8} Palatal flap is also more technically challenging and may expose more of the palatal bone if the fistula is larger, requiring a longer procedure and a second operation.¹

Palatal rotation flap may be problematic in the presence of a third molar fistula, as flap rotation may affect negatively the vascular pedicle. This flap may result in arterial injury and

hemorrhage.¹ Borgonovo⁷ suggest this method is only indicate for closing fistula in the premolar area cause an excessive rotation required when operating in the molar region could cause ischemia of the flap due to the palatal artery occlusion and necrosis.

Hernando⁸ used palatal rotation-advancement flap for 4 patients and all of these patient was succes. Qureshi⁴ performed rotational palatal flap to 29 patient with OAF and only one case (3.45%) was failed. This failed was due to postoperative sinusitis.

Buccal sliding flap whis is also known as Rehrmann flap, is the common and oldest surgical technique used for the treatment of OAF. Divergen vertical incision starts from the extraction tooth socket, by undermining mucoperiosteal continue to buccal mucosa and will get trapezeum shaped flap, and the flap sewn to the palatal mucosa, medial to the defect. Removal of alveolar bone can be performed to avoid tension of the flap. Disadvantages of this method include the risk of decreasing the depth of buccal sulcus, postoperative pain, and swelling. The decrease in the depth of buccal vestibule, a procedure can be performed to help deepen the vestibule 6 to 8 months after complete healing, If needed. The overall success rate of this flap about 87.2% in a retrospective study, making it a simple, practical and reliable method for repair most of OAF. (figure 8).^{5,14}

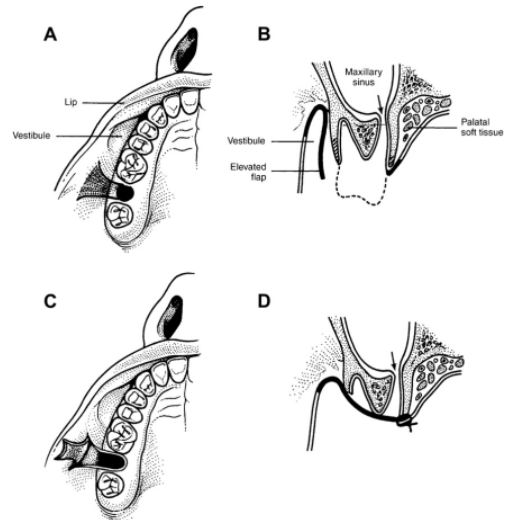


Figure 8. (A) Buccal flap for closure OAF (B) Undermining of the mucoperiosteal flap, horizontal scoring of the periosteum, and removal of bone to allow tension-free closure. (C&D) Advancement of flap into position of defect.⁵

Buccal fat flap is another surgical for closing small- to medium-sized OAF. This flap is the pedicled buccal fat pad, which was first described by Egyedi in 1977 (figure 9). Incision is made in maxillary in the distobuccal depth of the maxillary tuberosity, the buccal flap and periosteum are raised. A sharp scissors is used to cut through the periosteum, and with pressure applied to the zygomatic arch region, the buccal fat pad should easily extrude into the operative side. Blunt dissection with a Metzenbaum scissors can mobilize the fat, as much as needed to avoid tension of the flap to closure across the fistula. The tissue is fixed into bone with bur holes or screws and into adjacent palatal and buccal mucosa with resorbable sutures. The exposed buccal fat pad epithelializes in 4 to 6 weeks. A surgical splint can be secured to protect the flap.^{3,5}

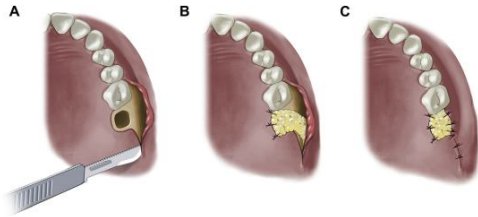


Figure 9. (A) Full-thickness mucoperiosteal flap elevated to allow access to the buccal fat pad. (B) Buccal fat pad mobilized and secured to the palatal soft tissue. (C) Mucoperiosteal flap closure with preservation of buccal vestibule.⁵

This method has a low failure rate and low morbidity. Complication of this technique such as necrosis of fat and visible change in facial contour when the buccal fat pad is used for reconstruction of large defects, but it is rare case.^{3,5}

Another technique to close fistula by using some type of alloplastic material and approximation of the flaps as over the alloplast. This material such as thin metallic foil that can be made of gold foil, titanium, aluminium foil and resorbable collagen membranes. This alloplastic material must be firmly attached to the contour of the bony surface. Metallic foil placed under the mucoperiosteal flap around the fistula then the flap was suture over metallic foil. This metallic foil acts as bridge of sinus mucosa growing and in some cases, crestal bone heal over the superior surface of the material. This metallic foil gradually exfoliates after a period of 6 weeks. The disadvantage of this technique is expensive and need relatively long period for complete closure and healing of the defect (figure 10)^{5,14}

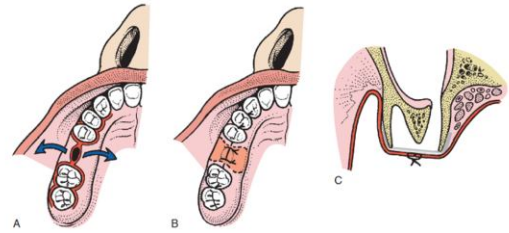


Figure 10. Subperiosteal placement of alloplastic material such as gold or titanium foil or a resorbable collagen membrane.¹⁴

The drainage and adequate aeration of the sinus should be achieved in cases with mucosal thickening and cystic or polypoid degeneration of mucosa, this is essential for successful therapy of OAF.² Del Junco et al and Bluestone as cited by Yilmaz², said that a nasotracheal window is essential for drainage and no surgical procedure is needed when the maxillary sinus is free of disease. FESS and Cadwell-Luc procedure are another most important surgical techniques used. ESS is a reliable method associated with less morbidity and lower incidence of complications than Cadwell-Luc technique.⁸ In this case, we performed antrumostomy for drainage of the sinus and remove pathologic tissue in maxillary sinus under endoscopic guidance.

There are several factors in the success of any flap operation performed for the closure of oroantral fistula include adequate vascularization of the flap, elimination of sinus infection, excision of fistulous tract, curette the infected bony structure and proper postoperative care.^{2,4} The patient is instructed to use nasal precautions for 10 to 14 days. These include opening the mouth while sneezing, not sucking on a straw or cigarettes, and avoiding nose blowing and any other situation that may produce pressure changes between the nasal passages and oral cavity.¹³ Antibiotics, oral care, and analgesics are recommended postoperatively.^{2,4}

References

1. Meirelles RC, Naves-Pinto RM. Oroantral fistula and genian mucosal flap : a review of 25 cases. *Rev Bras Otorrinolaringol* 2008;74(1):85-90.
2. Yilmaz T, Suslu AE, Gursel B. Treatment of Oroantral Fistula: Experience With 27 Cases. *American Journal of Otolaryngology* 2003;24(4): 221-3
3. Visscher SH Minnen B, Bos RR.M. Closure of Oroantral Communications: A Review of the Literature. *J Oral Maxillofac Surg* 2010;68:1384-91
4. Qureshi ZR, Khan M, Din Q. Buccal Advancement Flap Vs Palatal Rotation Flap In The Management Of Oroantral Fistula. *JKCD* 2012; 2(2):54-7
5. Dym H, Wolf JC. Oroantral Communication. *Oral Maxillofacial Surg Clin N Am.* 2012;24:239–247
6. Kamadjaja DB. Closure of oroantral fistula with rotational palatal flap technique. *Dent. J. (Maj. Ked. Gigi)* 2007;40(1):33–6
7. Borgonovo AE, Berardinelli FV, Favale M, Maiorana C. Surgical Options In Oroantral Fistula Treatment. *The Open Dentistry Journal* 2012; 6:94-8
8. Hernando J, Gallego L, Junquera L, Villarreal P. Oroantral communications. A retrospective analysis. *Med Oral Patol Oral Cir Bucal* 2010;15 (3):499-503
9. Kale TP, Urolagin S, Khurana V, Kontrashetti SM. Treatment of Oroantral Fistula Using Palatal Flap - A Case Report and Technical Note. *J. Int Oral Health* 2010;2: 77-82
10. Cankaya AB, Erdem MA, Cakarar S, Isler SC, Demircan S, Oral CK. Reliability of Two Surgical Methods for Oroantral Communication Closure; A Clinical Study of 20 Patients. *Otolaryngology* 2012;2:1-4
11. Sulastra IW. Oroantral Fistula sebagai salah satu komplikasi pencabutan dan perawatannya. *J PDGI.* 2009;58(1):7-11
12. Lee KC and Lee SJ. Clinical Features and Treatments of Odontogenic Sinusitis. *Yonsei Med J* 2010;51(6):932-93
13. Lore JM, Medina JE. *An Atlas of Head & Neck Surgery.* 4th ed. Elsevier Saunders: Phyladelphia, Pennsylvania. 2005. p. 256-57
14. Tucker MR. Odontogenic Diseases of the Maxillary Sinus. In: James R, Ellis E. Tucker R, editors. *Contemporary Oral and Maxillofacial Surgery*, Sixth Edition. New Orleans, Louisiana; Mosby, Elsevier Inc 2008: p.382-93