



## A Clinical, Radiological and IL-6 Evaluation of Subgingivally Delivered Simvastatin in the Treatment of Chronic Periodontitis.

Avita Rath<sup>1\*</sup>, Jaideep Mahendra<sup>1</sup>, Libby Thomas<sup>1</sup>, Manmeet Sandhu<sup>1</sup>, Ambalavanan Namasi<sup>1</sup>, Ramakrishna T<sup>1</sup>

### \*Corresponding author:

#### Avita Rath

<sup>1</sup>Department of Periodontology and Implantology, Meenakshi Ammal Dental College and Hospital, Alapakkam Main Road, Maduravoyal, Chennai - 600 095, Tamil Nadu, India

### Abstract

Simvastatin (SMV) are specific competitive inhibitors which are widely used to lower cholesterol for the treatment of hyperlipidemia and arteriosclerosis. They have shown to modulate bone formation by increasing the expression of bone morphogenetic protein-2, inflammation, and angiogenesis,<sup>3</sup> thus providing a new direction in the field of periodontal therapy. The aim of this randomized trial was to assess the clinical and radiographic effects of 1.2% Simvastatin gel as an adjunct to scaling and root planing in the treatment of chronic periodontitis. The IL-6 level in the sulcular epithelium was also evaluated before and after treatment with 1.2% simvastatin. 60 sites were selected with minimum one intrabony defect and probing pocket depth of >5mm and were divided into 2 groups; 30 sites were treated with SRP and placebo (Group A) and 30 sites were treated with SRP along with Simvastatin (SMV) (group B). Clinical parameters recorded at baseline before SRP and at 60<sup>th</sup>, 90<sup>th</sup> and 180<sup>th</sup> day; included plaque index (PI), modified sulcus bleeding index (mSBI), probing depth (PD), and clinical attachment level (CAL). Radiologic assessment of intrabony defect (IBD) fill was done at baseline and after 6 months using computer-aided software. Interleukin-6-mRNA (IL-6-mRNA) levels in sulcular epithelium was analysed for Group B at baseline and 3 months after the drug application. Both therapies resulted in significant improvements in the parameters however SRP along with simvastatin showed statistically significant decrease in PI, mSBI and PD and gain in CAL at 6 months. In Group B, there was greater decrease in mean IBD as compared to Group A. At the molecular level the simvastatin group showed a significant decrease in IL-6-mRNA levels. The statistically significant improvement in clinical and hard tissue parameters at sites treated with SRP plus locally delivered SMV as well as its potency in reducing IL-6-mRNA levels proved the efficacy of the drug as a local drug delivery system in the treatment of chronic periodontitis not only in clinical but as well as in molecular level.

**Keywords:** local drug delivery, chronic periodontitis, simvastatin, interleukin-6, intrabony defects

### Introduction

Periodontal disease is a major oral health problem. It is characterized by severe inflammation with loss of the supporting structures and the attachment apparatus.[1] In periodontitis, the production of proinflammatory cytokines and tissue-degradative enzymes is initiated and advanced by oral bacterial infection, ultimately resulting in the destruction of periodontal tissue.[2] Over the years, various treatment modalities have been tried with varying success to correct periodontal attachment and alveolar bone loss resulting from this disease.[1] Therapy has been aimed

primarily at reduction of etiologic factors to reduce or eliminate inflammation, thereby allowing gingival tissues to heal.

Therapeutic approaches for periodontitis falls into two major categories: 1) anti-infective treatment, which is designed to halt the progression of periodontal attachment loss by removing etiologic factors; and 2) regenerative therapy, which includes anti-infective treatment and is intended to restore structures destroyed by disease [3].

Nonsurgical periodontal therapy includes both mechanical and chemotherapeutic approaches to minimize or eliminate microbial biofilm (bacterial plaque), the primary etiology of gingivitis and periodontitis.[4]



**Various methods employed are** [5]

Mechanical non-surgical therapy  
 Hand instrumentation  
 Sonic/ ultrasonic instrumentation  
 Reciprocating instruments  
 Ablative laser therapy  
 Chemotherapeutic agents

Antibacterial agents have been used widely in the management of periodontal infection. The effectiveness of mechanical debridement and repeated topical and systemic administration of antibacterial agents are limited due to the lack of accessibility to periodontopathic organisms in the periodontal pocket. Systemic administration of drugs leads to therapeutic concentrations at the site of infection, but for short periods of time, forcing repeated dosing for longer periods [6].

The use of local delivery of antibacterial agents to sites of active periodontitis has aroused considerable interest because of the possibility of achieving a maximum antibacterial concentration with minimal side effects. The concept of local drug delivery was championed by Dr Max Goodson in the year 1979 [7]. The concept that local drug delivery of an antibiotic into the periodontal pocket achieves a greater, more potent concentration of drug than available with systemic delivery is very appealing. The amount of drug delivered often creates sulcular medication concentrations exceeding the equivalent of 1mg /ml. This level is considered bactericidal for the majority of bacteria that exhibit resistance to systemically delivered concentrations. Local application into periodontal pocket could be very advantageous, both in terms of increasing drug concentration directly in the action site, and in preventing systemic side effects such as gastrointestinal complaints, depression, and tachycardia [3].

Sustained or controlled releasing local delivery antimicrobial agents (LDAs) are available for use as adjuncts to scaling and root planning (SRP) in the treatment of periodontitis. These products are placed into periodontal pockets in order to reduce subgingival bacterial flora and clinical signs of periodontitis.

Simvastatin is a hypolipidemic drug belonging to the class of pharmaceuticals called "statins". It is used to control hypercholesterolemia (elevated cholesterol levels) and to prevent cardiovascular disease. Simvastatin is a synthetic derivative of a fermentation product of *Aspergillus terreus* [8] marketed under the trade names Zocor, Simlup, Simcard, Simvacor, and others, as well as generically.

Statins like simvastatin (SMV), lovastatin, and pravastatin are specific competitive inhibitors of 3-hydroxy-2-methyl-glutaryl coenzyme A (HMGCoA) reductase.[9-11] Statins also seem to modulate bone formation by increasing the expression of bone morphogenetic protein-2, inflammation, and angiogenesis[12], thus providing a new direction in the field of periodontal therapy.[1]

Various animal studies [13-15] have shown that SMV assists in bone regeneration and produces an anti-inflammatory effect when delivered or applied locally. It has shown to stimulate bone formation when injected subcutaneously over the murine calvaria

and also increased expression of BMP-2 mRNA in osteoblasts.[16,17] In-vitro studies[18,19] and clinical studies[12,20-22] confirmed its positive effect on bone formation and focused on bone diseases, especially osteoporosis. It also showed decrease production of IL-6 and IL-8, an effect that was reversed by adding mevalonate or geranylgeranyl pyrophosphate but not farnesyl pyrophosphate.[14,23,24] This side effect of statins could be of interest in the regeneration of periodontal defects, especially hard tissue regeneration.[25]

SMV reduced nuclear factor-kappa B and activator protein 1 promoter activity in KB cells, indicating an anti-inflammatory effect of SMV on human oral epithelial cells, apparently involving Rac1 GTPase (a hydrolase enzyme that can bind and hydrolyze guanosine triphosphate) inhibition.[14]

Simvastatin is indigenously prepared using methylcellulose and double distilled water in sterile conditions and inserted into the disease sites using a blunt cannula carrier. Periodontal therapy is aimed at the restoration of tissues destroyed by disease. However, achieving greater predictability with regenerative therapy requires the introduction of an agent which not only hampers tissue destruction but also enhances the regenerative capabilities of the periodontal tissues.

The aim of this study was to assess the clinical and radiographic effects of 1.2% Simvastatin in-situ gel as an adjunct to scaling and root planing in the treatment of chronic periodontitis.

## Materials and Methods

60 sites were selected with minimum one intrabony defect in any quadrant and probing pocket depth of >5mm in both male and female subjects (33 males and 27 females), aged 25 to 45 years, who were diagnosed with chronic periodontitis from May 2010 to June 2011. The study sample was selected from the patient pool of the Department of Periodontology, Meenakshi Ammal Dental College, Chennai, with approval from the ethical committee of MAHER university of Chennai, and followed the Declarations of Helsinki.[26] The inclusion criteria were patients who were systemically healthy with generalized chronic periodontitis with probing pocket depth (PPD) >5mm and radiographic evidence of vertical bone loss 3mm in atleast 1site and those with the ability to maintain optimum oral hygiene after the initial phase of treatment. Those with known or suspected allergy to SMV, on systemic statin therapy, patients with aggressive periodontitis, smokers and history of antibiotic or periodontal therapy in preceding 6 months were excluded from this study.

They were divided into 2 groups randomly by using coin toss method and patients were assigned to two groups by the clinician:

**Group A (Control):** 30 sites were treated with SRP and placebo

**Group B (Test):** 30 sites were treated with SRP and Simvastatin (SMV) gel

All the subjects, selected in this study received supragingival scaling and were given oral hygiene instruction prior to the commencement of the study. Customized stents were prepared



for the sites where the drug was to be administered for standardisation of the parameters throughout the course of the study. The parameters such as plaque index (PI), Modified sulcus bleeding index (mSBI), Probing pocket depth (PPD), Clinical attachment level (CAL), Radiographic assessment of intrabony defect (IBD) and level of interleukin-6 mRNA levels in the sulcular epithelium of the test site before and after the drug delivery (IL-6-mRNA) were recorded at different time points during the course of the study.

The PI, mSBI, PPD and CAL was assessed at baseline (0 day) before SRP and placebo in Group A and prior to SRP and local delivery of simvastatin in Group B (Fig .I) and again at 60<sup>th</sup> day, 90<sup>th</sup> day and 180<sup>th</sup> day. The radiographic assessment of IBD was done for both Group A and Group B at baseline (0 day) and 180<sup>th</sup> day by computer aided software. IL-6-mRNA levels were determined at baseline and 90 days after drug delivery using PCR analysis.

### Radiographic Analysis of Intrabony Defects [27]

Individually customized bite blocks and a parallel-angle technique were used to obtain standardized films. All radiographs were reviewed in a single reference center by a masked evaluator. For evaluation, radiographs were scanned at 800 dots per inch with a scanner, and IBD was evaluated using computer-aided software (*Coral Draw, Version X5*). IBD was measured on the radiograph by measuring the vertical distance from the crest of the alveolar bone to the base of the defect.

### Preparation of 1.2% Simvastatin Gel [28]

The constituents of simvastatin containing gel were simvastatin (10 or 20 mg) tablets, carboxymethylcellulose, and double distilled water. This mixture was prepared using 4% (w/v) methylcellulose gel, which served as a vehicle for the drug. The above mentioned volume of the vehicle was obtained by adding 100ml of hot double distilled water to 4g of methylcellulose powder at 50°C. 1.2g of simvastatin was then added to the homogenous phase of polymer. The vial was heated between 50°C-60°C and agitated using a mechanical shaker to obtain a clear solution. The gel was prepared at a concentration of 1.2%.

### Local Drug Delivery

Thorough scaling and root planing was done for both the groups and the areas were properly irrigated with physiologic saline. For standardization, 0.1 ml prepared SMV gel (1.2 mg/0.1 ml) was injected into the periodontal pockets in Group B using a syringe with a blunt cannula. No periodontal dressing was applied after delivery of the drug because the prepared formulation decreases in viscosity, which causes swelling and occlusion of the periodontal pocket.

After placement of the in situ gel, patients were instructed to refrain from chewing hard or sticky foods, brushing near the treated areas, or using any interdental aids for 1 week. Adverse

effects were noted at recall visits, and any supragingival deposits were removed.

### Measurement of IL-6-mRNA

Subgingival epithelial samples were collected with a sterile Gracey curette from the (preselected) deepest site in each quadrant (Fig.II). These samples were collected from the sites prior to treatment and 90 days following treatment in the Test group (Group B). Assessment of IL-6 level was carried out by PCR (Piq star universal gradient Thermocycler). After collecting the subgingival epithelial samples, it was transferred into 2ml ependroff tube containing 1ml of physiological saline (Fig.III) and kept in a freezer at -20°C. Then the DNA samples were isolated from the samples.

### Isolation of the genomic DNA

This procedure was carried out as per the protocol given by the manufacturer. The DNA templates were stored at 20 C until further use.

*Primers: Forward (Fwd) FOR IL-6: (Eurofins)*  
Forward primer design: TTGCAAGACATGCCAAA  
Reverse primer design: TCAGACATCTCCAGTCCT

17µl of master mix was mixed with 2µl of each of forward and reverse primers and 1µl of template DNA and the reaction mixture was loaded in the PCR machine and programmed.

10µl of PCR amplified samples was mixed with 1µl of dye and loaded into the gel. Electrophoresis was run at 50 to 100v till the tracking dye reached 2/3<sup>rd</sup> of the distance of gel length and gel was then visualized in gel documentation.

### Detection and analysis of the reagent product

The amplified strands were observed and compared with DNA ladder (with the known molecular weight) to find out the base pair of the unknown DNA.

### Statistical Analysis

Mean and standard deviation were estimated from the sample for each experimental site. Mean changes were compared against the null hypothesis. Student's paired t-test was employed to test the significance of mean differences between 0-day, 60<sup>th</sup> day, 90<sup>th</sup> day and 180<sup>th</sup> day. One way-ANOVA was employed to calculate the mean differences within the groups. Chi-square test was employed to calculate the IL-6-mRNA levels in the test group at 0-day and 90<sup>th</sup> day.

For all the tests, a *p*-value of 0.05 or less was considered for statistical significance.

### Results



60 patients completed the study. Sixty treatment sites (one site/subject) were evaluated for clinical parameters at baseline (before SRP) and at 60<sup>th</sup>, 90<sup>th</sup> and 180<sup>th</sup> day; radiographic parameters were recorded at baseline and at 180<sup>th</sup> day in 60 treatment sites by the assistant who did not know which group was being assessed as it was not told. IL-6-mRNA levels were evaluated for the test group before and after the drug delivery at 0-day and 90<sup>th</sup> day.

### Clinical evaluation

No adverse reaction was observed in any subject from the test group and no discomfort was reported. All subjects tolerated the drug well without any post-application complications.

### Evaluation of oral hygiene

No statistically significant differences were found between group A and group B at any time point except 180<sup>th</sup> day for site-specific plaque scores. This indicates that both groups maintained comparable levels of oral hygiene throughout the study. (Table I)

### mSBI

A statistically significant decrease in mSBI scores from baseline was found in both groups. The decrease in mSBI score was greater in group B at 90<sup>th</sup> and 180<sup>th</sup> day ( $2.5 \pm 0.6$ ) compared to group A ( $1.9 \pm 0.9$ ) ( $p < 0.05$ ). (Table II and III).

### PD

Statistically significant decrease in PD was found in both groups at the end of the study. When both the groups were compared the decrease in PD was greater in group B at all the time points compared to group A ( $p < 0.05$ ) (Table II and III).

### CAL

The difference from baseline was statistically significant within the groups in CAL gain (Fig. IV), but when compared there was no significant difference between the groups. (Table II and III).

### IBD Fill

There was greater decrease in mean IBD in group B (Fig. Va, Fig Vb) compared to group A ( $p < 0.02$ ). Both the groups showed significant decrease from baseline to 180<sup>th</sup> day. (Table IV)

### Analysis of IL6--mRNA levels in sulcular epithelium

The chi-square value for IL-6 level in group B at 0<sup>th</sup> day (Fig. VIa) and 90<sup>th</sup> day (Fig. VIb) was 42, which was statistically significant ( $p\text{-value} < 0.0001$ ) and showed a significant decrease following the application of the drug. (Fig. 6C)

### Discussion

Nonsurgical mechanical periodontal treatment is the cornerstone of periodontal therapy and the first recommended approach to the control of periodontal infections.[29] Although nonsurgical periodontal therapy has evolved over the years, it is still considered to be the gold standard to which other treatment methods are compared.

A strategy against biofilm infection has been proposed recently in which the dental plaque community is disrupted by targeting the easy-to-remove key members, leaving a biofilm community which cannot support pathogenic species. However, a wealth of evidence shows that conventional mechanical debridement cannot eradicate all periodontopathic bacteria from the subgingival environment, especially those inhabiting inaccessible areas such as furcations, grooves, concavities and deep pockets.[6]

Advances in understanding the etiology and pathogenesis have led to the development and subsequent acceptance of the use of pharmacological agents in the management of periodontal diseases. Local drug delivery systems have the ability to deliver the antimicrobial agents to the target sites, achieve a sufficient concentration, and last for a sufficient duration to be effective.<sup>3</sup>The clinician's decision to use LDAs should be based upon a consideration of clinical findings, the patient's dental and medical history, scientific evidence, patient preferences, and advantages and disadvantages of alternative therapies.[30]

Advantages of using the subgingival drug-delivery system include achieving high intrasulcular drug concentrations, avoiding its systemic side effects, and better patient compliance.<sup>3</sup> The non-surgical therapy has covered a new dimension by addition of yet another newer drug, Simvastatin, to the family of local drugs.

The purpose of this study was to determine whether non-surgical intrasulcular placement of simvastatin in methylcellulose gel can augment bone in human intrabony defects. Such a non-surgical approach is unconventional but, if successful, would provide a flexible and economical means of adding bone in periodontal therapy. Critical to this approach was thorough defect debridement involving the removal of all granulation tissue in the defect.

In this study simvastatin was used in gel form with carboxymethylcellulose as the vehicle. Researchers have found out that the gels composed of cellulose derivatives such as hydroxypropylmethyl cellulose and hydroxyethyl cellulose do not appear to have the property of sustained release. Surprisingly, despite the rapid drug release and poor retention of these gels, positive clinical results in moderate to deep periodontitis were obtained.[3]

Both the groups maintained comparable levels of oral hygiene throughout the study. In the present study there was decrease in the plaque scores in both groups from baseline to 6 months, where Group A showed a decrease from  $2.2 \pm 0.5$  to  $0.7 \pm 0.5$  and Group B showed a mean decrease from  $2.0 \pm 0.6$  to  $0.3 \pm 0.4$ . There was a significant difference in plaque scores between the two groups only at 6 months ( $p\text{-value} < 0.005$ ) showing a greater reduction in the test group. The results were similar to studies done by Pradeep et al [20] that showed comparatively greater





plaque reduction with locally administered simvastatin gel and Martha et al [31] who used systemic atorvastatin in a pilot study in chronic periodontitis patients however this could be due to increased patient's awareness of the treatment and hence better maintenance by the test group under study.

The other effects of this drug on the study group were as follows:

### Effect on gingival bleeding scores

In the present study we observed a significant reduction in gingival bleeding index scores for both the groups from baseline to 6 months, where Group A (control) showed a decrease from  $2.6 \pm 0.5$  to  $0.7 \pm 0.7$  ( $p < 0.001$ ) and Group B (test) from  $2.7 \pm 0.4$  to  $0.2 \pm 0.4$  ( $p < 0.001$ ). On comparison of both groups, statistically significant reduction of mSBI was observed in Group B ( $p < 0.005$ ) which suggests an anti-inflammatory effect of SMV. A similar anti-inflammatory effect of SMV was observed by Lindy et al in 2008 [32] using systemic statin therapy in patients with chronic periodontitis.

The soft tissue wall changes due to resolution of gingival inflammation explain the improvement in clinical parameters in this study. The magnitude of the changes is related to the initial pocket depth, tooth type, and other environmental factors.[29]

### Effect on PD and CAL

A decrease in probing depth and gain in CAL are the major clinical outcomes measured to determine the success of any periodontal treatment.

A significant decrease in PD was seen in both the groups at the end of the study, where Group A (control) showed a decrease from  $6.6 \pm 1.5$  mm to  $4.5 \pm 1.7$  mm and Group B (test) from  $6.3 \pm 1.7$  mm to  $2.3 \pm 0.6$  mm by the end of 6 months. When comparing the two groups, the decrease in PD was statistically significant at each time point, even after 6 months ( $p < 0.001$ ). Group B showed a greater reduction in pocket depth of  $4.0 \pm 1.6$  ( $p < 0.00$ ) as compared to the control group of  $2.1 \pm 0.8$  by the end of 6 months. Yazawa et al [33] studied the effect of SMV on human periodontal (PDL) cells in vitro and showed that at a low concentration SMV exhibits a positive effect on the proliferation and osteoblastic differentiation of human PDL cells, and these effects may be caused by inhibition of the melvalonate pathway thereby leading to periodontal regeneration.

Gain in CAL was seen in both the groups at the end of the study, where Group A showed a gain from  $7.4 \pm 1.0$  to  $5.1 \pm 1.2$  and Group B showed a gain from  $7.5 \pm 1.6$  to  $2.8 \pm 1.2$ . When comparing the two groups, the gain in CAL was statistically significant at all time intervals, even after 6 months ( $p < 0.001$ ) within both the groups. Group B showed a greater gain in CAL at 2 months ( $p < 0.049$ ), 3 months and 6 months. ( $p < 0.001$ ). Similar results were observed by Pradeep et al [20] showing a significant decrease in PD and gain in CAL in patients who were treated with subgingivally delivered simvastatin gel.

### Effect on Bone regeneration

Although clinical changes in the periodontal pocket have been extensively researched, the osseous changes following nonsurgical periodontal therapy have received less attention. Previous studies [4,6] have shown that intraosseous defects treated with nonsurgical periodontal therapy resulted in an increase in radiographic bone levels of 0.2 mm at 6 months, 0.3 mm at 12 months and 0.5 mm at 24 months after therapy.

This study confirms that local simvastatin upregulates bone growth. Simvastatin was chosen as the statin to be tested in the in-vivo study as in vitro studies have shown it to be among the most potent in stimulating bone growth and other predictors of osteoinduction.<sup>12,35</sup> The impact of simvastatin on bone metabolism therefore would appear to involve a complex interaction with cholesterol metabolites, growth factors, inflammatory cytokines and hormones.[13]

In the present study, there was a greater decrease in IBD for Group B of  $0.57 \pm 1.0$  as compared to Group A of  $0.08 \pm 0.1$  but the comparison was not significant at any of the time point. There was a significant reduction within the groups for Group A ( $p < 0.006$ ) and Group B ( $p < 0.007$ ) which was greater for the group with SMV ( $p < 0.02$ ). These observations were similar to that of Pradeep et al [21] who also showed a 32.5% decrease in mean IBD in chronic periodontitis patients with locally administered simvastatin gel and 2.16% in those treated with SRP alone.

Morris et al [12] studied the effect of injectable SMV in three-walled periodontal IBDs, Class II furcations defects, and edentulous alveolar ridges in beagle dogs by histomorphometric analysis; 29% greater ridge thickness was found with SMV, but bone height loss was detected in the interproximal intrabony and furcation defects. However, the present study showed effective IBD fill and a greater decrease in PD and CAL gain compared to the control group.

The possible errors in measuring the IBD fill on radiographs, such as those due to exposure settings, geometric error (e.g. radiographic techniques), and the development of films, were minimized by using a standardized paralleling technique.

### Effect on Interleukin-6-mRNA levels

The PCR analysis was used to evaluate the IL-6 levels from the sulcular epithelial cells of the periodontal pocket. IL-6 increases in the sites of gingival inflammation and plays a role in bone resorption via induction of RANKL. It also stimulates the osteoclast formation and activity [24].

In the current study the mean decrease in IL-6 level from 0 day to 90th day for Group B was statistically significant ( $p$ -value- $0.0007$ ). IL-6 was present only in 4 samples out of 30 by the end of 90th day after the placement of SMV. In this study, we are one of the few to prove that simvastatin reduces IL-1 induced production of inflammatory cytokines such as IL-6 by human oral epithelial cells. Ikeda and Shimada in 1999 [35] studied the effects of statins on the production of interleukin-6 by cultured human monocytes and smooth muscle cells.



The addition of statins significantly decreased IL-6 production by these cells. Thus, claiming their biologically significant anti-inflammatory effect which could prove beneficial in the treatment of periodontitis. Sakoda et al [14] also showed anti-inflammatory effect of SMV on human epithelial cells, apparently involving Rac1 GTPase inhibition, and found decreased IL-6 and IL-8 productions. They also confirmed inhibition of IL-8, IL-10, IL-12, and TNF production. [24] Michihiko et al [36] in 2008 showed that simvastatin decreased the expression of these inflammatory cytokines and promoted activity of downstream pathway which could also explain its anti-inflammatory effects on the bleeding scores.

With the current availability of number of intra-pocket delivery systems containing antimicrobials for periodontal therapy, questions can be raised about the efficacy of these delivery devices in periodontal regeneration.<sup>3</sup> The findings of this study involving simvastatin as a local drug delivery system has been encouraging as its effects on bone metabolism favours its use in the treatment of periodontal defects. Limitations of the study have been that of a proper control for IL-6 level analysis and its quantitative analysis and need for longer follow up period yet even then it has tried to overcome the shortcomings of previously used devices and was relevant in the present study as it provided with

significant reduction in periodontal inflammatory damage in the test group.

## Conclusion

These observations may give new direction in the field of periodontal regeneration, to achieve the goal of regeneration without any invasive procedures, thereby causing less discomfort to the patients. However, long-term studies, using different vehicles and concentrations of SMV, should be carried out to affirm the observations of our study.

## Acknowledgements

Author conveys heartfelt thanks to Dr. T. Ramakrishnan for his valuable guidance and input throughout this particular research. Dr. K. Pandi Suba and Dr. C.C. Prasanna M.Sc, Biotechnologist, and the Department of Bio-Chemistry and Pharmacology who have kindly co-operated with me during the course of the study.

## References

- [1]. Kinra P, Khan S. Simvastatin: Its potential new role in periodontal regeneration. *Biol and Med* 2011;3(2): 215-221.
- [2]. Seymour GJ, Gemmell E, Reinhardt RA, Eastcott J, Taubman MA. Immunopathogenesis of chronic inflammatory periodontal disease: Cellular and molecular mechanisms. *J Periodontal Res* 1993;28: 478-486.
- [3]. Pragati S, Ashok S, Kuldeep S. Recent advances in periodontal drug delivery systems. *Int J Drug Deliv* 2009;1:1-14.
- [4]. Patrick A, Laurence M. Effects of nonsurgical periodontal therapy on hard and soft tissues. *Periodontol* 2000 2004;36: 121-145.
- [5]. Lindhe J, Niklaus P. Lang, Thorkild Karring. *Textbook of Periodontology and Implantology*; 4th edn.
- [6]. Greenstein G. Nonsurgical Periodontal Therapy in 2000: A Literature Review. *J Am Dent Assoc* 2000;131: 1580-1592.
- [7]. Goodson JM, Haffajee.A and Socransky SS. Periodontal therapy by local drug delivery of antimicrobials, *J Clin Periodontol* 1979;6:83-92.
- [8]. U.S. National Library of Medicine: Drug Information Portal-Simvastatin: <http://druginfo.nlm.nih.gov/>.
- [9]. Henwood JM, Heel RC. Lovastatin. A preliminary review of its pharmacodynamic properties and therapeutic use in hyperlipidemia. *Drugs* 1988;36: 429-454.
- [10]. Kishida Y, Naito A, Iwado S, Terahara A. Research and development of pravastatin. *Yakugaku Zasshi* 1991; 111:469-487.
- [11]. Todd PA, Goa KL. Simvastatin. A review of its pharmacological properties and therapeutic potential in hypercholesterolemia. *Drugs* 1990;40:583-607.
- [12]. J. Cunha-Cruz, B. Saver, G. Maupome, and P.P. Hujoel. Statin Use and Tooth Loss in Chronic Periodontitis Patients. *J Periodontol* 2006;77(6):1061-1066.
- [13]. Nyan M, Sato D, Oda M. Bone formation with the combination of simvastatin and calcium sulfate in critical-sized rat calvarial defect. *J Pharmacol Sci* 2007; 104:384-386.
- [14]. Sakoda K, Yamamoto M, Negishi Y, Liao JK. Simvastatin decreases IL-6 and IL-8 production in epithelial cells. *J Dent Res* 2006;85:520-523.
- [15]. Stein D, Lee Y, Schmid MJ. Local simvastatin effects on mandibular bone growth and inflammation. *J Periodontol* 2005;76:1861-1870.
- [16]. Alam S, Ueki K, Nakagawa K. Statin-induced bone morphogenetic protein (BMP) 2 expression during bone regeneration: An immunohistochemical study. *Oral Surg Oral Med Oral Pathol Oral Radiol Endod* 2009;107: 22-29.
- [17]. Liu C, Wu Z, Sun HC. The effect of simvastatin on mRNA expression of transforming growth factor-beta1, bone morphogenetic protein-2 and vascular endothelial growth factor in tooth extraction socket. *Int J Oral Sci* 2009;1(2):90-8.



[18]. Hu F, Zhang XY, Wang CX. Effects of Simvastatin on osteoblast activity of human periodontal ligament cells. *Hua Xi Kou Qiang Yi Xue Za Zhi* 2009;27(3):313-6.

[19]. Jun-Beom P. The use of simvastatin in bone regeneration. *Med Oral Patol Oral Cir Bucal* 2009;14 (9):485-8.

[20]. Pradeep A, Manojkumar S. Clinical effect of subgingivally delivered simvastatin in the treatment of patients with chronic periodontitis: a randomized clinical trial. *J Periodontol* 2010;81(2):214-222.

[21]. von Stechow D, Susan F, Dror Y, Itai B, Chorev M. Does simvastatin stimulate bone formation in vivo? *BMC Musculoskel Dis* 2003;4:1-10.

[22]. Zhang L, Liu X, Tian F, Zhang H. Effects of simvastatin on bone formation relative factors of trabecular bone and osteogenic differentiation of bone marrow mesenchymal stem cells in young rats. *Curr Pharm Des* 2001;7(8):715-36.

[23]. Hai-Zhou R, Long-Le M, Wang. Effect of simvastatin on plasma interleukin-6 in patients with unstable angina. *Clin Invest Med* 2009;32(4):280- 284.

[24]. Sakoda K, Yamamoto M, Neigishi Y. Anti-inflammatory effects of Simvastatin on Human oral cells. *J Inflamm Regen* 2007;27(2):107-111.

[25]. Han G, Chen Y, Hou J. Effects of simvastatin on relapse and remodeling of periodontal tissues after tooth movement in rats. *Am J Orthod Dentofacial Orthop* 2010;138(5):550.e1-7.

[26]. World Medical Association Declaration of Helsinki: Ethical Principles for Medical Research Involving Human Subjects. 18th WMA General Assembly, Helsinki 1964.

[27]. Francetti L, Trombelli L, Lombardo G. Evaluation of efficacy of enamel matrix derivative in the treatment of intrabony defects: A 24-month multicenter study. *Int J Perio Rest Dent* 2005;25:461-473.

[28]. Thylin MR, McConnell JC, Schmid MJ. Effects of statin gels on murine calvarial bone. *J Periodontol* 2002; 73:1141-1148.

[29]. Ishikawa, Pierre B. Nonsurgical periodontal therapy where do we stand now? *Periodontol* 2000 2004;36: 9–13.

[30]. American Academy of Periodontology: Statement on Local Delivery of Sustained or Controlled Release Antimicrobials as Adjunctive Therapy in the Treatment of Periodontitis: Academic Report. *J Periodontol* 2006; 77(8):1458.

[31]. Martha EF, Miriam LR, Francisco JS. Effect of atorvastatin on chronic periodontitis: a randomized pilot study. *J Clin Periodontol* 2010;37(11):1016-1022.

[32]. Lindy O, Suomalainen K, Makela M, Lindy S. Statin use is associated with fewer periodontal lesions: A retrospective study. *BMC Oral Health* 2008;8:16.

[33]. Yazawa H, Zimmermann B, Asami Y, Bernimoulin JP. Simvastatin promotes cell metabolism, proliferation, and osteoblastic differentiation in human periodontal ligament cells. *J Periodontol* 2005;76:295-302.

[34]. Ozeç I, Kiliç E, Gümü C, Göze F. Effect of local simvastatin application on mandibular defects. *J Craniofac Surg* 2007;18(3):546-50.

[35]. Ikeda U, Ito T, Shimada K. Statins and C-reactive protein. *Lancet* 1999;353(9160):1274-1275.

[36]. Michihiko Usui, Reiko Suda, Yasushi Miyazawa. Statin decreases IL-1 and LPS-induced inflammatory cytokines production in oral epithelial cells. *New Frontiers in Lifestyle-Related Diseases* 2008;125-131.

Table 1. Comparison of mean values for PI (*Plaque Index*) scores for Group A and Group B at different time points.

Plaque Index	0 <sup>th</sup> day		60 <sup>th</sup> day		90 <sup>th</sup> day		180 <sup>th</sup> day	
	Grp A	Grp B	Grp A	Grp B	Grp A	Grp B	Grp A	Grp B
	2.2±0.5	2.0±0.6	1.0±0.5		0.8±0.6		0.7±0.5	
			0.8±0.4		0.4±0.6		0.3±0.4	
<b>P value</b>	0.21 (N.S.)		0.19 (N.S.)		0.051 (N.S)		0.005 (Sig.)	



Table II. PD, CAL, and mSBI for Groups A and B (mean – SD) at Different Time Intervals

Groups	Timepoint	PD (mm)	CAL(mm)	Sulcus Bleeding Index (mSBI)
<b>A</b>	<b>0<sup>th</sup> Day</b>	6.6±1.5	7.4±1.0	2.6±0.5
	<b>60<sup>th</sup> Day</b>	5.5±1.5	6.0±1.2	1.0±0.6
	<b>90<sup>th</sup> Day</b>	4.8±1.5	5.4±1.2	0.8±0.8
	<b>180<sup>th</sup> Day</b>	4.5±1.7	5.1±1.2	0.7±0.7
<b>B</b>	<b>0<sup>th</sup> Day</b>	6.3±1.7	7.5±1.6	2.7±0.4
	<b>60<sup>th</sup> Day</b>	4.4±1.6	5.2±1.7	0.7±0.6
	<b>90<sup>th</sup> Day</b>	3.2±1.2	3.8±1.4	0.2±0.4
	<b>180<sup>th</sup> Day</b>	2.3±0.6	2.8±1.2	0.2±0.4

Table III: Decrease in PD,CAL Gain and Gingival Index (mSBI) From Baseline (mean – SD) at Different Time Intervals for Groups A and B

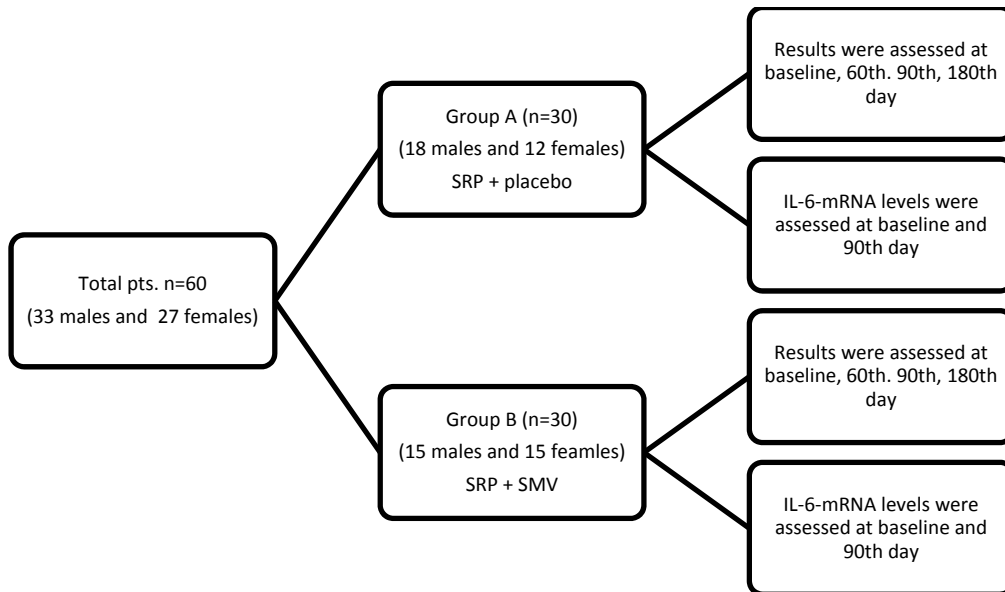
Parameters	Timepoint	Group A	Group B	P value
<b>PD</b>	<b>60<sup>th</sup> Day</b>	1.1±0.5	1.9±1.7	0.02(Sig.)
	<b>90<sup>th</sup> Day</b>	1.8±0.7	3.1±1.5	0.00(Sig.)
	<b>180<sup>th</sup> Day</b>	2.1±0.8	4.0±1.6	0.00(Sig.)
<b>CAL</b>	<b>60<sup>th</sup> Day</b>	2.2±1.5	2.2±1.5	1.00(N.S.)
	<b>90<sup>th</sup> Day</b>	3.6±1.6	3.6±1.6	1.00(N.S.)
	<b>180<sup>th</sup> Day</b>	4.6±1.5	4.6±1.5	1.00(N.S.)
<b>mSBI</b>	<b>60<sup>th</sup> Day</b>	1.5±0.7	2.0±0.9	0.052(N.S.)
	<b>90<sup>th</sup> Day</b>	1.8±0.9	2.5±0.6	0.002(Sig.)
	<b>180<sup>th</sup> Day</b>	1.9±0.9	2.5±0.6	0.005(Sig.)





Table IV: Comparison of IBD Values From Baseline to 6 Months

<i>Group</i>	<i>Time</i>	<i>IBD (mm; mean – SD)</i>	<i>IBD Decrease (mm; mean – SD)</i>	<i>P value</i>	<i>Intergroup P value</i>
<i>A</i>	<i>0<sup>th</sup> Day</i>	7.3±1.1	0.08±0.1	0.006(Sig.)	0.02 (Sig.)
	<i>180<sup>th</sup> Day</i>	7.2±1.0			
<i>B</i>	<i>0<sup>th</sup> Day</i>	7.2±1.2	0.57±1.0	0.007(Sig.)	
	<i>180<sup>th</sup> Day</i>	6.6±1.3			



Flowchart summarizing the parallel study design



