

Acta Cardiologia Indonesiana (Vol. 3 No. 2) 2017 [supplement]: S18

Acute Limb Ischemia and Pseudoaneurysm of Femoralis Artery Post Cardiac Catheterization in Pediatric

Hidayanto Perdana^{1*}, N. Kurnianingsih²

¹ Resident of Cardiology and Cardiovascular Medicine Department, ² Supervisor of Cardiology and Cardiovascular Medicine Department, Universitas Brawijaya Malang

*correspondence: haperdana@gmail.com

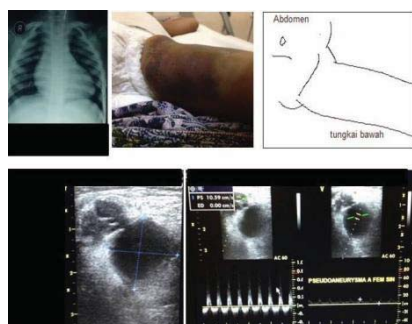
Abstract

Background: Cardiac catheterization is main intervention technique of cardiology and cardiovascular medicine in diagnostic and therapy. It can cause a variety of adverse events, ranging from minor problems without long-term sequelae to major complications requiring immediate corrective action.

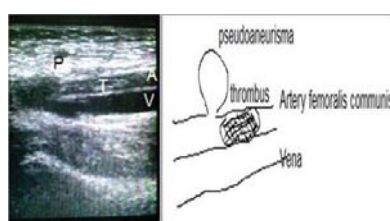
Case Illustration: A two years old little girl with BMI 18 Kg/m² underwent diagnostic cardiac catheterization for tetralogy of fallot. She has central cyanosis and secondary polycythemia. Catheterization was in general anesthesia, there was difficulties to get arterial access and puncture was done several times. The day after, left lower extremity found to be ischemic, concomitantly hematome extent to a half area of upper left femoral region and pulsating mass with bruit was in left inguinal. Duplex ultrasonography diagnosed acute limb ischemia (ALI) with thrombus at artery femoralis communis sinistra and also pseudoaneurysm 1,65 x 1,67 cm. Intravenous thrombolysis therapy was done with drip streptokinase 2000 IU/Kg/hours for 18 hours, stopped after revascularisation has been achieved. Heparin infussion was given 25 IU/Kg/hours along with streptokinase, then switched to warfarine 0,2 mg/Kg/day. During thrombolysis, tight observation for bleeding complication, diuresis, and vital sign was done in intermediate intensive care unit. Patient was sent home after eight day with persisting lump and hematome, but hematome and pseudoaneurysm healed 60 daysafterward.

Discussion: Limb threatening ischemia was prioritized in management of ALI with concomitant pseudoaneurysm. For diameter less than 2cm, pseudoaneurysm which was left untreated may spontaneously resolved. Adult guideline could not be used in pediatric patient. In spite of catheter directed thrombolysis (CDT), intravenous thrombolysis has satisfying efficacy and safe in pediatric patient. It is strongly recommended to be carefull in dosing, since paucity data of intravenous streptokinase use in pediatric.

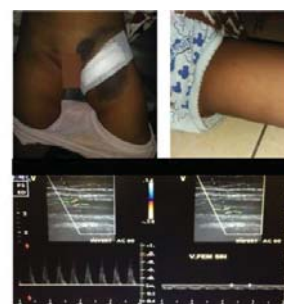Keywords: acute limb ischemia, pseudoaneurysm, cardiac catheterization, intravenous thrombolysis



a. Left lower limb



b. Long axis view pseudoaneurysm with intra-arterial thrombus



c. Doppler ultrasonography 8 days after thrombolysis and left lower limb after 60 days.